ORIGINAL ARTICLE

Diagnostic accuracy of magnetic resonance voiding cystourethrography for detecting vesico-ureteral reflux in children and adolescents

Ali Hekmatnia, Alireza Merrikhi[1], Maryam Farghadani, Roozbeh Barikbin, Farzaneh Hekmatnia[2], Nariman Nezami[3]
Departments of Radiology, [1]Pediatric Nephrology, [2]Medical Student, Isfahan University of Medical Sciences, Isfahan, Iran, [3]Department of Radiology and Radiological Sciences, The Johns Hopkins Hospital, Baltimore, MD, USA

Background: The purpose of the present study is to determine the accuracy of magnetic resonance voiding cystourethrography (MRVCUG) for diagnosis of vesicoureteral reflux (VUR) in children and adolescents with recurrent urinary tract infection (UTI). **Materials and Methods:** During the cross-sectional study from May 2009 to June 2011, 30 patients' (60 kidney-ureter units) MRVCUG findings by 1.5 T magnetic resonance imaging (MRI) were compared with voiding cystourethrography (VCUG) findings in patients with urinary tract infection. The sensitivity, specificity, positive and negative predictive values for MRVCUG were calculated. **Findings:** The sensitivity, specificity, positive and negative predictive values and accuracy for MRVCUG for detecting VUR were respectively 92.68% (95% CI: 80.57-97.48%), 68.42% (95% CI: 46.01-84.64%), 86.36% (95% CI: 71.95-94.33%), 81.25% (95% CI: 53.69-95.02%), and 85% (95% CI: 80.40-89.60%. The level of agreement between MRVCUG and VCUG findings for diagnosis VUR was very good ($P < 0.001$, according to Cohen's kappa value = 0.638). Studying correlation of low grade VUR (grade I and II) and high grade VUR (grade III-V) showed a very good agreement between MRVCUG and VCUG findings ($P < 0.001$, Cohen's kappa value = 0.754). **Conclusion:** MRVCUG could accurately reveal the presence and severity of VUR, especially in cases with high-grade (grade III-V) VUR in both children and adolescents.

Key words: Accuracy, diagnosis, magnetic resonance, vesicoureteral reflux, voiding cystourethrography

INTRODUCTION

Vesico-ureteral reflux (VUR) by causing retrograde urine flow from the bladder to the kidneys is considered as underling pathophysiology of recurrent urinary tract infections (UTI), severe renal complications and end stage renal failure.[1-4]As the kidney damage resulting from severe VUR is preventable, early detection, follow-up and proper management of underlying lower urinary tract abnormalities are desirable.[5,6]

Voiding cystourethrography (VCUG) or radionuclide cystourethrography is the gold standard for diagnosis of VUR.[6-8] However, this diagnostic test is associated with some disadvantages, likes radiation exposure and catheterization complications.[6] On account of the above mentioned risks and VCUG invasiveness,[9] common screening is not applicable and investigators tend to use the new methods with less comorbidity.[10] During recent decades, new diagnostic modalities have been introduced, including contrast-enhanced voiding ultrasonography and magnetic resonance voiding cystourethrography (MRVCUG) to detect VUR.[6,10,11] However, there is no recommendation for using these newly introduced modalities as the first line diagnostic method. These diagnostic tests are still under survey and more studies are needed to establish accuracy and reliability.

The present study was designed to determine the diagnostic accuracy of MRVCUG as an alternative diagnostic test for detection of VUR in children and adolescents with UTI.

MATERIALS AND METHODS

During the present cross-sectional study, 30 patients (60 kidney-ureter units) were enrolled into the study from May 2009 to June 2011. This examination has currently been performing at the Alzahra Hospital of Isfahan University of Medical Sciences. Samples were selected by non-probability convinced consecutive method. Patients were referred from Department of Pediatric Nephrology in Alzahra Hospital by the nephrologists in base of inclusion and exclusion criteria. Initial VCUG studies were done in the Farhangian center and then (with interval of about 1 week) patients were referred to MRI ward for MRVCUG evaluation. No medication was performed during the procedures.

Address for correspondence: Dr. Maryam Farghadani. No. 192, Second Floor, North Sheikh Sadoogh Street, Isfahan, Iran.
E-mail: dr_mar_far@yahoo.co.uk
Received: 27-09-2012; **Revised:** 18-11-2012; **Accepted:** 24-12-2012

Study population

Studied population was composed of children aged 2 to 10 years and adolescent aged 11 to 18 years, in base of one of the following inclusion criteria: First time UTI in every child younger than 5 years old, UTI in male in any age group, second episode of cystitis in female, febrile UTI in any age, every patient who have urinary control and have one of the above criteria, and patients whom their parents give consent to the imaging modality.

Exclusion criteria

If early voiding occurs or agitation of patient cannot be controlled, it was omitted from the study and replaced with another patient.

All participants' parents provided an informed written consent, and the study protocol, which was in compliance with Helsinki declaration, was approved by the Ethics Committee of Isfahan University of Medical Sciences.

Diagnostic procedures

VCUG

The VCUG was performed based on other studies[7] as following:

In the first step, the patient must be filled up to his/her estimated bladder capacity, to ensure that he/she could be assessed adequately for VUR. This was done by putting the patient through three cycles of filling and voiding, before the catheter was finally removed during voiding and the final film of the urethra was obtained. Patient should empty the bladder before the exam and then he/she should be placed in a frog leg position. Using sterile technique, drape and prepare the patient first with three swabs of an iodinated antibacterial cleansing solution, and then 2 swabs of water to clean off the iodinated antibacterial cleansing solution.

If the patient was a male, using viscous lidocaine to anesthetize the urethra was preferred. The urethra was filled with viscous lidocaine and let it 2-3 min to take affect before catheterizing the patient. Finally, the end of the catheter was placed in the specimen bottle.

The 8 French feeding tube was inserted into the bladder through the urethra, and the catheter was tape to the leg in a female, or to the abdomen and penis in a male. Then, a urine specimen was obtained and sent to the clinic by the patient. A Crede maneuver, by which a gentle pressure on applied on the lower abdomen, was done to empty the bladder of urine before starting.

The bladder was filled with contrast and afterward, anterioposterior (AP) film of abdomen with low volume filled bladder, oblique urethra voiding shot in males, AP urethra voiding shot in females, post void AP of bladder, post void AP of the kidneys, bilateral oblique views of the bladder for detecting any reflux, ureterocele or any filling defect was taken.

VUR was assessed using a five-point grading system by VCUG, according to the international system of radiographic grading of VUR.[7]Also, grade I-II reflux was considered as low-grade reflux, and grade III-V as high-grade reflux.

MRVCUG

The MRVCUG was performed based on other studies[7] as following:

MR imaging examinations were performed with 1.5-T MR imaging unit (Signa horizon LX, GE Medical Systems, San Antonio, TX, USA). The MR imaging protocol included the following sequences: T1-weighted images (repetition time (TR) ms/echo time (TE) ms, 466/19), T2-weighted images (TR/TE = 4500/120 ms; echo train length (ETL), eight). In all sequences, the field of view was 22 or 24 cm and the section thickness was 5 mm with an inter-slice gap of 2.5 mm.

The patients were asked to drink water before the examination, until had a full-bladder sensation. In male patients, diversion of urine during voiding was achieved by the use of a urine bottle or a urine collection bag. In female patients, a disposable diaper was used for the examination. The lower part of the patient's body was covered with a waterproof sheet. Young children received 80 mg/kg chloral hydrate, orally, 20 min before examination as a loading dose for sedation.

Patients were examined in the supine position in a 1.5-T scanner. A wrap-around surface coil was used for the patients. MRI (MR fluoroscopy) was executed with a non-enhanced heavily T2-weighted single-shot Fast Spin Echo (FSE) sequence with thick-slab acquisitions (flip angle 90°; slab thickness 50-100 mm; matrix (256 * 224)) to clearly reveal any anatomical or congenital abnormality and kidney, ureter and bladder anatomical structure. The slice orientation was coronal. The imaging time was less than two seconds per image until the urinary bladder expanded and the internal urethral orifice of the urinary bladder were dilated. Images were then obtained every three seconds during urination. The time duration for imaging was 10-15 min.

If the primary images quality were not good and relevant in T2 sequence, 20 min after IM application of a bolus of 1 mg/kg furosemide (to reduce waiting time needed for filling bladder), images were obtained every 10 seconds until the urinary bladder expanded and the internal urethral orifice of the urinary bladder dilated. Images have been obtained every three seconds during urination. The MR images displayed as cine loops for evaluation. The diagnosis

of VUR by MRVCUG was positive when dilation of the ureter or renal pelvis during bladder filling or micturition would be observed. The beginning of micturition is defined as the beginning of shrinking of the urinary bladder on the MR images. Evaluating images in sequence reveals normal case [Figure 1] and any abnormality in patients. While interpreting the MRVCUG studies, radiologists in charge were blinded to the VCUG results.

VUR was assessed using a five-point grading system, according to the international system of radiographic grading of VUR.[7] Furthermore, VUR was also graded using the MRVCUG findings as: 1. Mild reflux on MR indicated mild dilation of the pelvic and ureter (Grade 1) [Figure 2], cases with mild VUR have open ureterovesical junction, while the junction was closed and dicked shaped in normal cases; 2. Moderate reflux on MR indicated moderate dilation of the pelvis and ureter which is usually associated with mild ureteral tortuosity and mild calyceal blunting (Grades 2 and 3) [Figure 3]; and 3. Severe reflux on MR indicated massive dilation of the pelvis, in which ureteral tortuosity and calyceal blunting are almost always observed (Grade 4) [Figure 4].

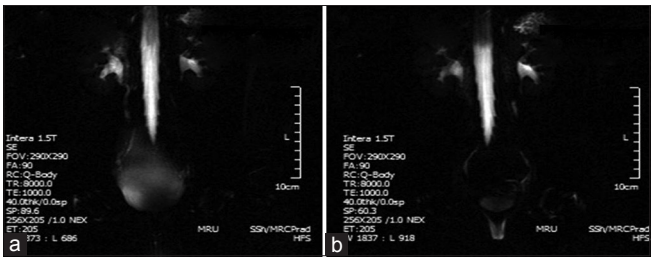

Figure 1: A coronal non-enhanced heavily T2 weighted single shot FSE, before (a) and during (b) voiding. A 7-year-old girl with normal pelvi-ureter system before and after voiding

Figure 3: A coronal non-enhanced heavily T2 weighted single shot FSE, before voiding. A 1-year-old male with bilateral vesicoureteral reflux in grade four with evidence of posterior urethral valve in full bladder view. Look at the dilated ureters in distal part. The exam is done during voiding for demonstration of vesicoureteral reflux

Statistical analysis

Statistical analysis was performed by SPSS software package for windows version 13.0 (SPSS Ins., Chicago, USA). Results are presented as mean ± standard deviation (SD). Statistical significance between compared groups was estimated using Fisher exact test. The sensitivity, specificity, positive and negative predictive values for MRVCUG were calculated in comparison with VCUG for detection of VUR. The Cohen's kappa values were used to determine the agreement between MRVCUG and VCUG findings.[12] The results were considered significant when the *P* value was less than 0.05.

RESULTS

The procedures were accepted by all subjects and there was no complication. Twenty three (76.66%) and 7 (23.34%) of recited patients were female and male, respectively.

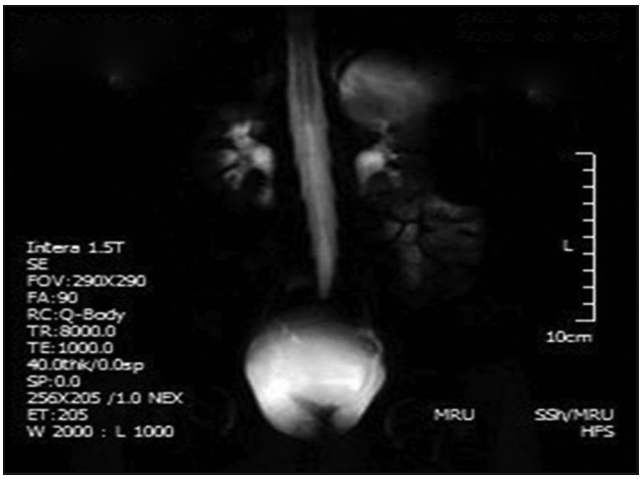

Figure 2: A coronal non-enhanced heavily T2 weighted single shot FSE, before voiding; with dilated ureters in distal part. A 5-year-old girl with bilateral vesicoureteral reflux, grade three with blunting of fornices and moderate dilatation of pelvis and calyces

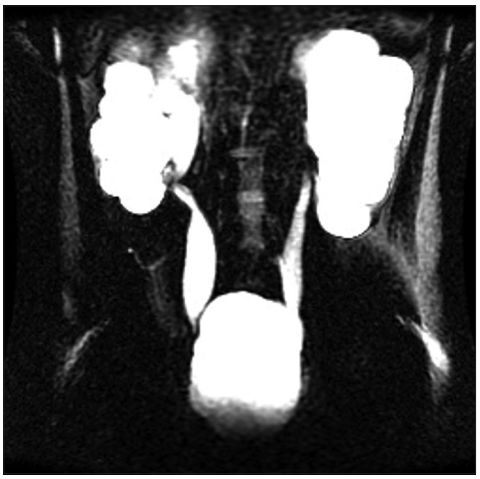

Figure 4: A coronal non-enhanced heavily T2 weighted single shot FSE, before voiding. A 4-year-old girl with bilateral ureterovesical junction stenosis and bilateral severe hydronephrosis (proven by surgery). Look at the' rat tail shape' of distal of ureters

The mean age of patients was 5.15 ± 2.22 years. The mean examination time was 40.00 ± 6.20 min.

According to the standard VCUG findings, VUR was demonstrated in 41 (68.33%) kidneys, and 19 (31.67%) kidneys had no VUR. The results regarding different VUR grade based on VCUG and MRVCU has been shown in Table 1. Among the patients with VUR, grade I was found in 14 (23.34%) kidney-ureter units, grade II in 11 (18.33%), grade III in 8 (13.33%), grade IV in 8 (13.33%), and grade V in none of the kidney-ureter units.

The sensitivity, specificity, positive and negative predictive values and accuracy for MRVCUG for detecting VUR were respectively 92.68% (95% CI: 80.57-97.48%), 68.42% (95% CI: 46.01-84.64%), 86.36% (95% CI: 71.95-94.33%), 81.25% (95% CI: 53.69-95.02%), and 85% (95% CI: 80.40-89.60%). The level of agreement between MRVCUG and VCUG findings for diagnosis VUR was very good ($P < 0.001$, according to Cohen's kappa value = 0.638). The levels of agreement (Cohen's kappa values) between MRVCUG and VCUG findings for diagnosis of VUR in male and female were respectively 0.378 and 0.727, which were higher in female [Hence, there was a very good agreement between MRVCUG and VCUG findings ($P < 0.001$, Cohen's kappa value = 0.754) in diagnosis high grade VUR (grade III-V)].

DISCUSSION

The results of the present study demonstrated that there is a high agreement between MRVCUG and VCUG in diagnosis of VUR and determining its severity in high grades, especially grade III-V reflux, despite some limitations of MRVCUG in detecting grade I-II reflux.

Imaging is the base of diagnosis and management (VUR). Recent technological advances have expanded the diagnostic capabilities of MRI to include the pediatric genitourinary tract. These advances include faster image acquisition, enhanced resolution, reduced motion artifact, improved signal-to-noise ratio, and the generation of three-dimensional reconstruction. To the best of our knowledge, only three studies have evaluated the agreement of VCUG and MRVCUG imaging methods.[13-15]

Table 1: Reflux grading according to voiding cystourethrography

Grading	Frequency	Percent
Valid		
Normal	16	26.7
Grade 1	17	28.3
Grade 2	9	15.0
Grade 3	12	20.0
Grade 4	6	10.0
Total	60	100.0

Initial study on MRVCUG has shown sensitivity about 90% for diagnosis of VUR.[13-16] This study suffered from some withdraws including lack of detailed imaging method. Following studies on 23 and 44 kidney-ureter units, however, came over to these flaws and have provided complementary data considering application of MRI in rolling out of people without VUR.

Study by Lee *et al*.[14] on 23 kidney-ureter units using VCUG as the gold standard, showed different sensitivity and specificity for MRVCUG, while the resulted positive and negative predictive values were in the same range as shown by our study. Takazakura *et al*.[15] in a comparison of MRVCUG and traditional VCUG as a standard showed that MRVCUG had a similar sensitivity, but higher specificity, positive and negative predictive values. Like our findings, the presence of high-grade VUR (grade III-V) was correctly diagnosed with MRVCUG in all cases in their study. Another newly published study,[16] comparing interactive MRVCUG accuracy, have reported higher sensitivity, specificity and NPV with lower PPV. These differences in accuracy may rise from different methods of MRI used by studies.

In base of the preset study, VUR was not diagnosed in three kidney-ureter units during MRVCUG, while diagnosed in VCUG; as same as of two major previous studies reported five[14] and two[15] false negative kidney-ureter units. All of undiagnosed kidney-ureter units had mild/grade I VUR. Some possible explanations for this false negative reports and discrepancy between VCUG and MRVC would be the paraureteral bladder diverticulum which is known to cause intermittent VUR,[17] incomplete voiding due to sedation in infants and young children during MRVCUG, prolonged scan time of MRVCUG, proficiency in MRI technique and temporal relief of VUR. Importantly, all three false negative cases were among grade I VUR in VCUG. Collectively, the higher sensitivity of MRVCUG in comparison to its specificity and also invasive nature of VCUG, make the noninvasive MRVUG a considerable tool for screening VUR in children and adolescent with recurrent UTI.

Out of 44 kidney-ureter units with VUR in MRVCUG, six diagnosed as normal in VCUG evaluation and considered as false positive in our study. All of the false positive cases reported to have mild VUR in MRVCUG. Lee *et al*.,[14] Takazakura *et al*.[15] and Arthurs *et al*.[16] reported respectively two, one and three false positive kidney-ureter units on MRVCUG, all of which were cases of mild reflux. This misdiagnosis was maybe due to newly developed or early period of development of low grade VUR.

All of false positive and negative cases are among patients with mild/grade I and II VUR. In the clinical setting, patients with low grade reflux do not have an increased

risk for recurrence of UTI/renal damage and can usually be managed conservatively;[6] therefore, such patients usually do not need further imaging for VUR. Despite this fact, the major role of imaging studies in patients with VUR is to identify the presence of high grade reflux for appropriate management to prevent complications. In this regard, MRVCUG has a significant clinical value as follow-up tools for patients who underwent surgical intervention, as well as for patients with high-grade reflux who are under conservative medical management.

Although because of dynamiting characteristic of VUR, VCUG probably has an advantage over MRVCUG in the revealing of VUR, it has limitations in the assessment of morphologic abnormalities of the kidneys, including renal damage or reflux nephropathy. Thus, MRVC has an advantage over VCUG in this regard.

Another important limitation of VCUG is radiation exposure.[18] It is estimated that as much as 25% of the radiation with potential to produce genetic alterations received by the pediatric population, is related to imaging of the urinary system, especially with VCUG. Also another imaging method is radionuclide cystography which imparts a gonadal radiation dose less than that with conventional VCUG, but it does not provide the same anatomic detail.[19] Therefore, because of the unpleasant nature of the radiographic imaging and the concerns over radiation exposure, as early as the 1960s, attempts were being made to find alternative VUR diagnostic methods in an effort to eliminate the radiation exposure intrinsic in fluoroscopic and scintigraphic reflux examinations.[20,21] Today, MRI is known as a powerful diagnostic tool giving precise anatomic detail without the use of ionizing radiation.

Although the present study among finger count studied evaluation diagnostic value of MRI in rule outing VUR, however, it suffers from some limitations like small sample size and short duration which means larger studies with longer-term follow-ups are still needed. Furthermore, carrying out of MRVCUG is limited by some factors including the need for IV sedation/anesthesia in children[22-24] and cardiopulmonary monitoring, the difficulty for children to void while supine, increased ureteral flow due to hydration and the use of diuretic may worsen the detection of VUR (increased antegrade ureteral flow), possible heavy work load on the MR equipment due to the relatively long examination time required, and the cost and limited availability of MRI scanners. In this age of cost containment, there are increased costs associated with MRI and availability remains limited. Although MRI is currently more costly, the comprehensive information obtained may justify its use, especially as it does not use ionizing radiation.

CONCLUSION

MRVCUG has the capability to reveal the presence and severity of high-grade (grade III-V reflux) VUR. In the clinical setting, MRVCUG could be used as follow-up tools for controlling post-surgical/post conservative medical management of patients with high-grade reflux.

ACKNOWLEDGMENT

Research project number: 387242

REFERENCES

1. Cooper CS. Diagnosis and management of vesicoureteral reflux in children. Nat Rev Urol 2009;6:481-9.
2. Murer L, Benetti E, Artifoni L. Embryology and genetics of primary vesico-ureteric reflux and associated renal dysplasia. Pediatr Nephrol 2007;22:788-97.
3. Murawski IJ, Gupta IR. Vesicoureteric reflux and renal malformations: A developmental problem. Clin Genet 2006;69:105-17.
4. Malaki M, Sayedzadeh SA, Shoaran M. Growth indices in urinary tract infection children with or without vesicoureteral reflux. Saudi J Kidney Dis Transpl 2011;22:723-6.
5. Merrick MV, Notghi A, Chalmers N, Wilkinson AG, Uttley WS. Long-term follow up to determine the prognostic value of imaging after urinary tract infections. Part 2: Scarring. Arch Dis Child 1995;72:393-6.
6. Nuutinen M, Uhari M. Recurrence and follow-up after urinary tract infection under the age of 1 year. Pediatr Nephrol 2001;16:69-72.
7. Lebowitz RL, Olbing H, Parkkulainen KV, Smellie JM, Tamminen-Mobius TE. International system of radiographic grading of vesicoureteric reflux. International Reflux Study in Children. Pediatr Radiol 1985;15:105-9.
8. Phillips D, Watson AR, Collier J. Distress and radiological investigations of the urinary tract in children. Eur J Pediatr 1996;155:684-7.
9. Srivastava T, Betts G, Rosenberg AR, Kainer G. Perception of fear, distress and pain by parents of children undergoing a micturating cystourethrogram: A prospective study. J Paediatr Child Health 2001;37:271-3.
10. Snow BW, Taylor MB. Non-invasive vesicoureteral reflux imaging. J Pediatr Urol 2010;6:543-9.
11. Darge K, Troeger J. Vesicoureteral reflux grading in contrast-enhanced voiding urosonography. Eur J Radiol 2002;43:122-8.
12. Ben-David A. Comparison of classification accuracy using Cohen's Weighted Kappa. Expert Syst Appl 2008;34:825-32.
13. Rodriguez LV, Spielman D, Herfkens RJ, Shortliffe LD. Magnetic resonance imaging for the evaluation of hydronephrosis, reflux and renal scarring in children. J Urol 2001;166:1023-7.
14. Lee SK, Chang Y, Park NH, Kim YH, Woo S. Magnetic resonance voiding cystography in the diagnosis of vesicoureteral reflux: Comparative study with voiding cystourethrography. J Magn Reson Imaging 2005;21:406-14.
15. Takazakura R, Johnin K, Furukawa A, Nitta N, Takahashi M, Okada Y, *et al*. Magnetic resonance voiding cystourethrography for vesicoureteral reflux. J Magn Reson Imaging 2007;25:170-4.
16. Arthurs OJ, Edwards AD, Joubert I, Graves MJ, Set PA, Lomas DJ. Interactive magnetic resonance voiding cystourethrography (iMRVC) for vesicoureteric reflux (VUR) in unsedated infants: A feasibility study. Eur Radiol 2011;21:1874-81.

17. Hernanz-Schulman M, Lebowitz RL. The elusiveness and importance of bladder diverticula in children. Pediatr Radiol 1985;15:399-402.
18. Vasanawala SS, Kennedy WA, Ganguly A, Fahrig R, Rieke V, Daniel B, *et al*. MR voiding cystography for evaluation of vesicoureteral reflux. AJR Am J Roentgenol 2009;192:W206-11.
19. Darge K. Voiding urosonography with US contrast agent for the diagnosis of vesicoureteric reflux in children: An update. Pediatr Radiol 2010;40:956-62.
20. Nolte-Ernsting C, Glowinski A, Schaeffter T, Adam G, Gunther RW. Gadolinium-enhanced magnetic resonance fluoroscopy used as micturating cystourethrography: Experiences in adult male patients. Invest Radiol 2003;38:617-24.
21. Gupta RK, Kapoor R, Poptani H, Rastogi H, Gujral RB. Cine MR voiding cystourethrogram in adult normal males. Magn Reson Imaging 1992;10:881-5.
22. Elder JS, Longenecker R. Premedication with oral midazolam for voiding cystourethrography in children: Safety and efficacy. AJR Am J Roentgenol 1995;164:1229-32.
23. Stokland E, Andreasson S, Jacobsson B, Jodal U, Ljung B. Sedation with midazolam for voiding cystourethrography in children: A randomised double-blind study. Pediatr Radiol 2003;33:247-9.
24. Edwards AD, Arthurs OJ. Paediatric MRI under sedation: Is it necessary? What is the evidence for the alternatives? Pediatr Radiol 2011;41:1353-64.

How to cite this article: Hekmatnia A, Merrikhi A, Farghadani M, Barikbin R, Hekmatnia F, Nezami N. Diagnostic accuracy of magnetic resonance voiding cystourethrography for detecting vesico-ureteral reflux in children and adolescents. J Res Med Sci 2013;18:31-6.

Source of Support: Nil, **Conflict of Interest:** The authors have no proprietary interest in any aspect of the present study.