ADVANCES IN HEPATOLOGY

Current Developments in the Treatment of Hepatitis and Hepatobiliary Disease

Section Editor: Eugene R. Schiff, MD

Fibroscan (Transient Elastography) for the Measurement of Liver Fibrosis

Nezam H. Afdhal, MD
Director of Hepatology
Beth Israel Deaconess Medical Center
Professor of Medicine
Harvard Medical School
Boston, Massachusetts

G&H How does the Fibroscan device work?

NHA The Fibroscan device (Echosens) works by measuring shear wave velocity. In this technique, a 50-MHz wave is passed into the liver from a small transducer on the end of an ultrasound probe (Figure 1). The probe also has a transducer on the end that can measure the velocity of the shear wave (in meters per second) as this wave passes through the liver. The shear wave velocity can then be converted into liver stiffness, which is expressed in kilopascals. Essentially, the technology measures the velocity of the sound wave passing through the liver and then converts that measurement into a liver stiffness measurement; the entire process is often referred to as liver ultrasonographic elastography.

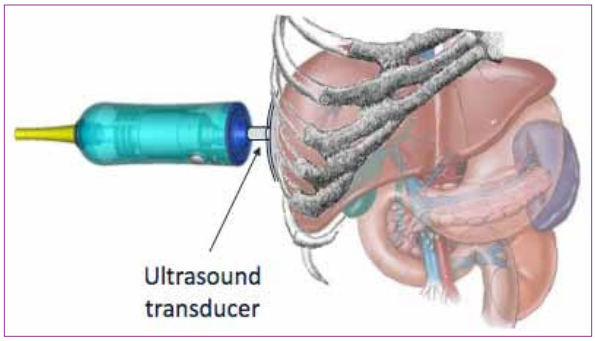

Figure 1. The probe of the Fibroscan device is positioned in an intercostal space near the right lobe of the liver, and a 50-MHz wave is passed into the liver from a small transducer on the end of the probe. The device then measures the velocity of the shear wave (in meters per second) as this wave passes through the liver, and this measurement is converted to a liver stiffness measurement. (Image courtesy of Echosens.)

G&H What are the advantages of Fibroscan testing compared to liver biopsy?

NHA Liver biopsy has long been the gold standard to stage fibrosis in the liver. In particular, liver biopsy has been used to evaluate patients with viral hepatitis (particularly those with hepatitis B virus [HBV] or hepatitis C virus [HCV] infection), to stage disease, and to determine whether treatment should be pursued. The disadvantages of biopsy are that it is an invasive test, it requires the patient to be hospitalized for half a day, it is expensive, and it is associated with certain risks, such as pain and bleeding. (While bleeding due to liver biopsy is uncommon, it poses a significant risk when it occurs.) In addition, a liver biopsy samples only a very small piece of the liver, which can lead to incorrect staging if this sample is not representative of the rest of the liver. Thus, liver biopsy can lead to sampling error, which may result in either overstaging or understaging of fibrosis; sampling error may occur in up to 25–30% of liver biopsies. Another limitation of liver biopsy is that different pathologists can interpret the same sample differently, which can result in discrepancies in liver disease staging.

Given these limitations and patients' desire to avoid invasive testing, researchers have done much work over the past 10 years to develop noninvasive tests that can measure liver fibrosis. Fibroscan is one such test, and it offers several advantages compared to liver biopsy. Because Fibroscan is a noninvasive test, it can be performed at the point of care, there is no pain,

and sedation is not required. Also, the test takes only 5–7 minutes to perform, it is significantly less expensive than liver biopsy, and it has not been associated with any side effects. Finally, the results of the test are instantaneous, so clinicians can use them to make decisions during patients' visits.

G&H Which patients are appropriate candidates for Fibroscan testing?

NHA Fibroscan is a useful test in almost any patient in whom a clinician wishes to stage liver fibrosis. The main drawback of Fibroscan testing is that it cannot be performed in all patients. Technical limitations of the test preclude its use in patients who have ascites, individuals who are morbidly obese, and/or patients who have large amounts of chest wall fat. In these groups, either the test cannot be performed or the results are not reliable. Reliability and reproducibility have been well characterized for elastography with Fibroscan, and it is important to ensure that these technical requirements are achieved to make the scan results valid. Particularly, a valid result requires 8–10 measurements with a 60% success rate and an interquartile range less than 0.3.

G&H What other noninvasive methods can clinicians use to stage liver fibrosis?

NHA Several other noninvasive methods can be used to measure liver stiffness, including both radiologic tests and serum biomarker tests. One radiologic method for measuring liver fibrosis is magnetic resonance (MR) elastography. The advantage of MR elastography is that it is very accurate for measuring liver stiffness; however, this test requires patients to undergo an MR imaging scan, and therefore it cannot be performed at the point of care. Acoustic resonance force impulse testing is another radiologic method for measuring liver fibrosis, but this method is still undergoing evaluation and has not yet been broadly adopted for clinical use either in the United States or Europe.

In addition to radiologic tests, several noninvasive tests use serum biomarkers to determine liver fibrosis. These tests make use of the fact that changes in liver stiffness lead to measurable changes in the biomarkers produced by the liver. Serum biomarker tests measure 1 or more of these biomarkers and look for elevated levels of those biomarkers that are associated with fibrosis. The most common serum tests for staging liver fibrosis are HepaScore, FibroSure, the FIB-4 index, and the European Liver Fibrosis test.

Several studies have evaluated the efficacy of these serum biomarker tests, both in terms of how they compare to Fibroscan and how they perform when used in combination with Fibroscan. These studies have shown that all of these technologies work very well for staging patients with no or minimal fibrosis; likewise, they are all very good at staging patients with advanced fibrosis or cirrhosis. However, when used to evaluate patients with midlevel disease (ie, Metavir stage F2), these tests have variable performance characteristics and do not perform as well as liver biopsy.

A key point to remember is that biomarker tests and radiologic tests are not mutually exclusive, and many guidelines now recommend that clinicians perform both a serum test and a Fibroscan. When both tests indicate mild or no disease, then the combined result is both sensitive and specific, and clinicians can be confident in this result. Likewise, when both tests indicate advanced or significant disease, this result has high sensitivity, high specificity, and a high predictive value. Thus, clinicians should not think of Fibroscan and serum biomarker tests as competing technologies; instead, they should be viewed as complementary technologies.

G&H Where is the Fibroscan device currently available?

NHA The Fibroscan device is available almost everywhere in the world besides the United States. Fibroscan testing is common throughout all of Europe, and it is also being performed in South America, Canada, and Asia, including China and Japan. In many of these areas, Fibroscan testing has been very widely adopted. In addition, both the European Association for the Study of the Liver and the Asian Pacific Association for the Study of the Liver recommend using noninvasive tests such as serum tests and/or Fibroscan, rather than liver biopsy, for the initial evaluation of patients with liver disease.

G&H Could the Fibroscan device be approved for use in the United States?

NHA Yes, the Fibroscan registration studies have been completed, and this device has been submitted to the US Food and Drug Administration (FDA) for approval. This application is currently under review.

G&H Will FDA approval of the Fibroscan device change how US clinicians manage patients with hepatitis?

NHA Yes, the availability of the Fibroscan device—in combination with the advent of new treatments for HBV and HCV infection—will likely reduce the need for liver biopsy. The absolute staging of liver disease becomes

less important if clinicians are able to cure more than 75–80% of patients using less toxic therapies, which is the trend that is developing with new hepatitis treatment regimens. In this scenario, the ability to exclude cirrhosis becomes more important, and both Fibroscan and other noninvasive technologies can exclude cirrhosis as well as, if not better than, liver biopsy. Therefore, Fibroscan and serum biomarker testing could be used in combination to exclude patients with cirrhosis, which would allow many patients to avoid biopsy: Patients who were shown to have cirrhosis would require appropriate screening with endoscopy and ultrasound for liver cancer, while patients without cirrhosis could proceed with treatment. Once Fibroscan is approved, it will most likely be used as a screening tool in all patients with liver disease, and it would absolutely change the way hepatologists manage these patients.

G&H Does the Fibroscan device have any potential applications beyond the measurement of liver fibrosis?

NHA In terms of liver-related applications, Fibroscan has been used not only to measure liver fibrosis but also to evaluate patients with portal hypertension, to assess recurrence of disease following liver transplantation, and to predict survival in patients with liver disease. In addition, this technology is being used to evaluate patients with breast cancer, prostate cancer, and other diseases in which fibrosis plays an important role.

G&H What further research is needed?

NHA One area of study that should be pursued is the investigation of how liver stiffness changes over time and what happens to liver stiffness as patients undergo treatment. A longitudinal study would need to follow patients for a long period of time to see whether liver stiffness returns to normal once their disease is cured.

Suggested Reading

Lai M, Afdhal NH. Editorial: staging liver fibrosis in hepatitis C: a challenge for this decade. *Am J Gastroenterol*. 2011;106:2121-2122.

Becker L, Salameh W, Sferruzza A, et al. Validation of Hepascore, compared to simple indices of fibrosis, in US patients with chronic hepatitis C virus infection. *Clin Gastroenterol Hepatol*. 2009;7:696-701.

Malik R, Lai M, Sadiq A, et al. Comparison of transient elastography, serum markers and clinical signs for the diagnosis of compensated cirrhosis. *J Gastroenterol Hepatol*. 2010;25:1562-1568.

Pritchett S, Cardenas A, Manning D, Curry M, Afdhal NH. The optimal cut-off for predicting large oesophageal varices using transient elastography is disease specific. *J Viral Hepat*. 2011;18:75-80.

Klibansky DA, Mehta SH, Curry M, Nasser I, Challies T, Afdhal NH. Transient elastography for predicting clinical outcomes in patients with chronic liver disease. *J Viral Hepat*. 2012;19:e184-e193.

Manning DS, Afdhal NH. Diagnosis and quantitation of fibrosis. *Gastroenterology*. 2008;134:1670-1678.

Cohen EB, Afdhal NH. Ultrasound-based hepatic elastography: origins, limitations, and applications. *J Clin Gastroenterol*. 2010;44:637-645.

Castera L, Vergniol J, Foucher J, et al. Prospective comparison of transient elastography, Fibrotest, APRI and liver biopsy for the assessment of fibrosis in chronic hepatitis C. *Gastroenterology*. 2005;128:343-350.

Ziol M, Handra-Luca A, Kettaneh A, et al. Non-invasive assessment of liver fibrosis by stiffness measurement: a prospective multicentre study in patients with chronic hepatitis C. *Hepatology*. 2005;41:48-54.