Vaccine-associated fibrosarcoma in a cat

Melanie Martin

Abstract — An 8-year-old, spayed, female domestic shorthair was diagnosed with a vaccine-associated fibrosarcoma and treated with full course radiation therapy, aggressive surgery, and post-operative chemotherapy. Histopathologic examination confirmed that excision of the tumor was complete. The cat was doing well 278 days after initial presentation.

Résumé — Fibrosarcome causé par la vaccination chez une chatte. Une chatte domestique à poil court âgée de huit ans et stérilisée présente un fibrosarcome relié à la vaccination; elle a reçu des traitements de radiothérapie, et subi une excision chirurgicale importante suivie d'une chimiothérapie postopératoire. L'examen histopathologique a confirmé que l'excision de la tumeur était complète. La chatte se porte toujours bien 278 jours après l'examen initial.

(Traduit par Docteure Andrée Lesage)

Can Vet J 2003;44:660–663

An 8-year-old, spayed, female domestic shorthair presented on day 1 to a referral clinic for a 2- × 2-cm SC mass, palpable in the left interscapular region. The mass was firm, immovable, and painful on palpation. The referring veterinarian had performed a fine needle aspirate 15 d earlier, 2 d after the owner had noticed the mass. Cytologic examination of the fine needle aspirate showed fusiform cells in tight clusters; a diagnosis of soft tissue sarcoma, possibly vaccine-associated, was considered. She had been vaccinated annually against feline viral rhinotracheitis, calicivirus infection, and panleukopenia, 6 mo before the mass was noticed, but had not been vaccinated against rabies virus- or feline leukemia virus-infection for 3 y. The owner agreed to the following in-clinic diagnostic tests: a complete blood cell (CBC) count, serum biochemical analysis, abdominal ultrasonography, thoracic radiography, computed tomography (CT), and tissue biopsy.

The CBC count revealed lymphopenia (1.2×10^9/L; reference range, 1.5×10^9/L to 7×10^9/L). There were no significant findings on abdominal ultrasonography; ventrodorsal and lateral thoracic radiographs showed no evidence of thoracic metastasis. The CT scan revealed an elongated, invasive tumor (6–8 cm × 1.5 cm) that extended into the SC tissue, muscle layers, and ribs (Figure 1). Histologic examination of the biopsy confirmed an irregular infiltrative mass, bordered by adipose and loose fibrovascular connective tissue; neoplastic cells were observed arranged in streaming and interlacing bundles in a fine fibrovascular stroma. The neoplastic cells were plump, spindle to fusiform in shape, with scant streaming eosinophilic cytoplasm and indistinct cell borders. Nuclei were oval to fusiform, varied markedly in size, and had dispersed chromatin with prominent nucleoli. Mitotic activity was moderate to high. Numerous foci of lymphocyte and mixed mononuclear inflammatory cell infiltration were present. No vascular invasion was observed, but neoplastic cells extended to the cut margins of the specimen. The diagnosis was fibrosarcoma.

The treatment protocol selected was full course radiation therapy before surgery and, possibly, chemotherapy postsurgery. Since the location of the mass ensured that a minimal dose of radiation would affect the lungs and there would be no exposure to the spine, serious toxicity was not expected. The cat was treated with 60 gray (Gy) of radiation in 20 daily fractions of 3 Gy with a view to shrinking the tumor and sterilizing the margins. Radiation was administered between days 15 and 41, in cycles of 5 d of daily treatments followed by 2 d without treatment, for a period of 4 wk. During the 5-d radiation course, the cat remained at the clinic. On day 54, 2 wk postradiation, the cat returned for reexamination. The owner reported that the cat had a good appetite and activity level. The tumor was smaller and nonpainful on palpation. Accordingly, surgery for removal of the mass was scheduled for day 79; a repeat CBC count, serum biochemical analysis, and thoracic radiographs were scheduled for day 78.

The presurgical ventrodorsal and lateral thoracic radiographs showed no evidence of pulmonary metastasis, and all CBC counts and serum biochemical parameters were normal. Surgery was uneventful. Wide margin excision was performed, with 6-cm cranial and caudal

Ontario Veterinary College, University of Guelph, Guelph, Ontario N1G 2W1.

Dr. Martin's current address is North Town Veterinary Hospital, 496 Main Street North, Brampton, Ontario L6V 1P9.

Address all correspondence and reprint requests to Dr. Melanie Martin.

Dr. Martin will receive 50 free reprints of her article, courtesy of *The Canadian Veterinary Journal.*

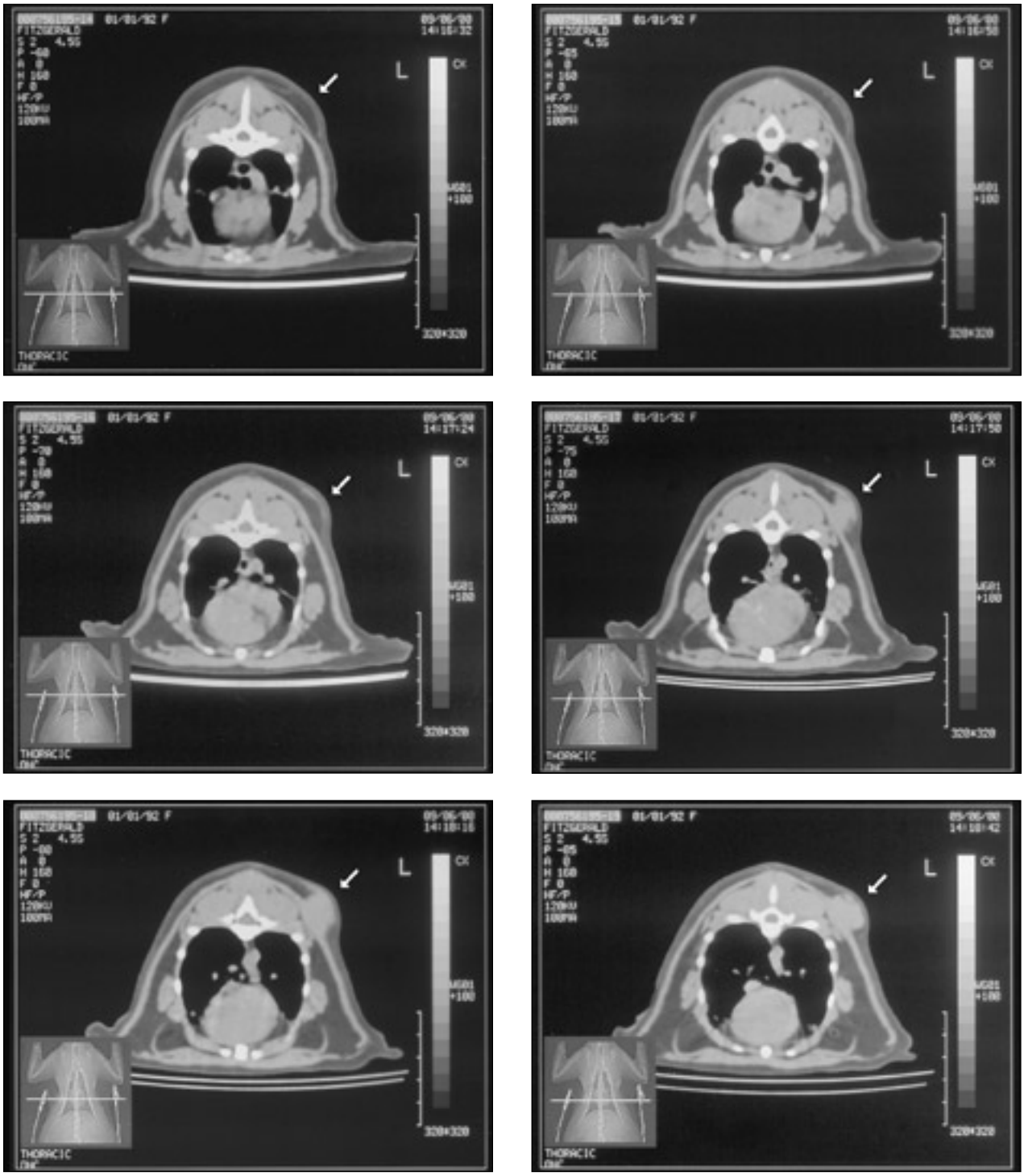

Figure 1. Computed tomographic images of the left interscapular region of an 8-year-old cat with a subcutaneous mass (arrow).

margins, and 4.5-cm dorsal and ventral margins. The expaxial and latissimus dorsi muscles were excised through to the rib. The excised tissue was examined histopathologically to assess the deep and lateral margins for the presence of neoplastic cells; excision of the tumor was observed to be complete, with clean surgical margins. The cat was discharged on day 82.

The owner elected to continue treatment with chemotherapy postsurgery. The cat was scheduled to receive alternating doses of doxorubicin (Adriamycin; Pharmacia and Upjohn, Mississauga, Ontario) and carboplatin (Paraplatin-AQ; Bristol, Montreal, Quebec) for a total of 4 treatments at 4-wk intervals. On day 96, the cat received its 1st chemotherapy treatment, doxorubicin, 0.92 mg/kg bodyweight (BW), IV. The cat had been doing well since surgery. On the CBC count done before treatment, the following values were low: red blood cells (RBC) (5.93×10^{12} g/L, reference range 6.0 to 10.0×10^{12} g/L) and hematocrit (28.9×10^{-2} L/L, reference range 29 to 45×10^{-2} L/L). The white blood cells (WBC)

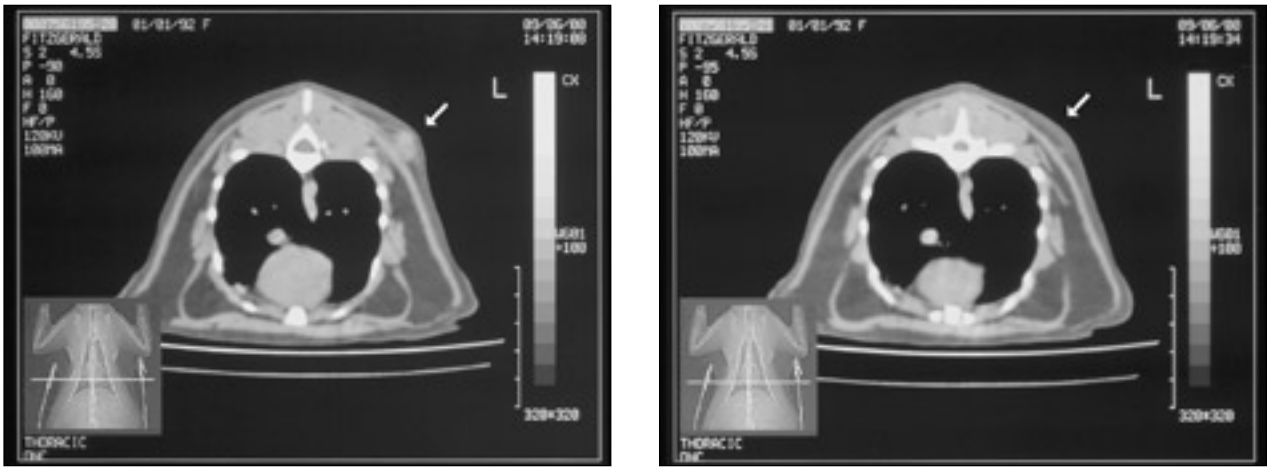

Figure 1. *(concluded).*

were within normal range. On day 124, the cat was reexamined. It had been lethargic and anorectic for 2 to 3 d after chemotherapy but had been doing well since then. For appetite stimulation, diazepam (Valium; Apotex, Weston, Ontario), 0.5 mg/kg BW, PO, was prescribed for use as needed. The WBC count on day 124 was within normal range, so the 2nd chemotherapy treatment, carboplatin, 12.4 mg/kg BW, IV, was administered. On day 155, when the 3rd chemotherapy treatment was scheduled, the WBC count was low (5.1×10^9/L; reference range 5.5 to 19.5×10^9/L), so the treatment was postponed until day 166. On day 166, the WBC count was within the normal range and doxorubicin, 1 mg/kg BW, IV, was administered. The WBC count was also within normal limits on day 180, when the last chemotherapy treatment was administered (carboplatin, 12.4 mg/kg BW, IV). When reexamined on day 278, the cat was doing well and had gained 1.3 kg.

Studies indicate a prevalence of 1:1000 to 1:10 000 for vaccine-associated sarcoma in cats vaccinated against feline leukemia virus (FeLV) or rabies virus; however, most experts believe that the prevalence is 1:2000 to 1:4000 (1–3). The adjuvant in the above vaccines may produce inflammation, stimulate fibroblasts to divide, and induce free radical formation that results in oxidative damage to DNA (1,2,4). Cats appear to be unique in their susceptibility to sarcoma development. It is believed that the unique species susceptibility of cats to oxidative injury (Heinz body anemia, acetaminophen toxicity, steatitis) is one reason for the high vaccine-associated tumor rate. Furthermore, susceptibility to sarcoma development may depend on individual susceptibility to oxidative stress, as low glutamine levels have been demonstrated in some cats with vaccine-associated sarcoma. In addition, variations in the tumor suppressor gene have been reported in some cats with vaccine-associated sarcoma (3,5).

Reports indicate that sarcoma may develop 3 mo to 11 y after vaccine administration. Those that occur sooner than 3 mo after vaccination are probably associated with previous vaccination or tissue injury. Adjuvant-containing vaccines may produce granulomas, which usually reach their maximum size 3 wk after vaccination and disappear within 3 mo. The Vaccine-Associated Feline Sarcoma Task Force (VAFSTF) (6) recommends that any lump at a vaccination site be biopsied and removed, if it meets any of the following 3 criteria: present 3 mo after vaccination; greater than 2 cm at any time after vaccination; or growing in size 4 wk after vaccination (4,6). To biopsy the mass, a wedge or punch (Tru-cut; Dyna Medical Corporation, London, Ontario) technique should be used (3). Fine needle aspirate, which was originally used in this case, is considered unreliable (3).

Prior to treatment of a vaccine-associated sarcoma, procedures should be performed as follows: 1) CT to determine the extent of the lesion, 2) thoracic radiography to assess metastatic disease, and 3) an FeLV test to eliminate the possibility of a feline sarcoma virus-associated tumor (1,4,6). Sarcomas caused by the feline sarcoma virus do not benefit from surgery (3,4).

A combination of surgery, radiation therapy, and chemotherapy, as used in this case, usually gives the best results. Significant improvement in the disease-free interval has been reported, if a referral institution performed the initial or 2nd surgery. No difference in disease-free interval has been found if multiple surgeries have been performed prior to referral (3). With surgery alone, the recurrence rate is 60%, with 86% of recurrent tumors recurring within 6 mo (2,4). Average survival with surgery alone is 1 to 1.5 y. With combined radiation and excision, the recurrence rate is 30% to 40%, and the average survival time is 700 to 800 d (1,3). Some chemotherapeutic agents are active against vaccine-associated sarcomas but are marginally effective (10%) in extending patient survival time. A wide variety of drugs have been evaluated, including doxorubicin, carboplatin, mitoxantrone, cyclophosphamide, and vincristine. Doxorubicin appears to be the most effective treatment (7).

Recommendations to prevent vaccine-associated sarcomas include avoidance of over-vaccinating or of using any medication that produces chronic inflammation and, when possible, limiting the use of vaccines containing adjuvant (2,4,6).

The subject of vaccine-associated sarcoma formation is still a very real problem. Many VAFSTF-funded studies are currently underway. Researchers are evaluating a multitude of risk factors, comparing the occurrence in cats with sarcoma with that in cats with basal cell tumors.

A comprehensive tissue bank of sarcomas, blood, and normal-appearing margins has been established. A number of sites of polymorphism in the p53 gene have been identified, including the morphologically normal areas adjacent to excised sarcomas (6). Another study has established 14 cell lines from feline sarcomas, some that were and some that were not associated with vaccines, and has initiated evaluations of levels of growth factors and the response of the cell lines to the growth factors. The tumorigenic potential of several of the cell lines has also been determined (6). Other research groups have initiated investigation of the role of local lymphocytes in tumorigenesis. Preliminary data suggests that T-lymphocytes tend to infiltrate a sarcoma, while B-lymphocytes do not (6). Ongoing work will involve molecular analysis of growth factors and their receptors. Furthermore, an investigation is underway to study a radiosensitizer to test the hypothesis that enhancing the oxygenation of the tumor enhances the cell kill rate after radiation therapy (6). CVJ

References

1. Al-Sarraf R. Update on feline vaccine-associated fibrosarcomas. Vet Med 1998;93:739–735.
2. Hendrick MJ. Feline fibrosarcoma: vaccine associated. In: Bongagura JD, ed. Kirk's Current Veterinary Therapy XIII Small Animal Practice. Philadelphia: WB Saunders, 2000:498–500.
3. Macy D. Current understanding of vaccination site-associated sarcomas in the cat. J Feline Med Surg 1999;1:15–21.
4. Hendrick MJ. Historical review and current knowledge of risk factors involved in feline vaccine-associated sarcomas. J Am Vet Med Assoc 1998;213:1422–1423.
5. Madewell BR, Griffey SM, McEntee MC, Leppert VJ, Munn RJ. Feline vaccine-associated fibrosarcoma: an ultrastructural study of 20 tumors (1996–1999). Vet Pathol 2001;38:196–202.6.
6. Dernell WS. Feline vaccine-associated fibrosarcomas. 1999 Vet Cancer Soc Miniconference Proc, Bodega Bay, California, February 4–7, 1999. Vet Cancer Soc Newslett 1999;23:2–15.
7. Barber LG, Sorenmo KU, Cronin KL, Schofer FS. Combined doxorubicin and cyclophosphamide chemotherapy for nonresectable feline fibrosarcoma. J Am Anim Hosp Assoc 2000;36:416–421.

BOOK REVIEW

COMPTE RENDU DE LIVRE

Day M, Mackin A, Littlewood J, eds. ***Manual of Canine and Feline Haematology and Transfusion Medicine.*** Iowa University Press, Ames, Iowa, USA, 2001, ISBN 0-905214-39-0. US$134.95.

This manual is written as a guide for small animal practitioners, and its contributors include specialists from several countries and disciplines, encompassing internal medicine, critical care, and clinical pathology. A handbook of just over 300 pages, it covers 3 areas that deal with the diagnosis and treatment of hematological diseases and with transfusion medicine. Approximately half of the book, the largest section, is devoted to hematology; a third deals specifically with hemostasis; and about 50 pages cover transfusion medicine.

The hematology section includes an overview of diagnostic techniques in hematology, and touches briefly on interpretation. The 2nd chapter details bone marrow sampling and interpretation. Bone marrow interpretation, while interesting and beyond the scope of a manual directed mainly towards practitioners, provides background on the indications for bone marrow evaluation. There is a chapter on anemia in general and another that covers specific erythrocyte disorders: iron deficiency anemia, anemia of chronic renal disease, and immune-mediated anemia, as well as 2 parasitic diseases, feline hemobartonellosis and canine babesiosis. Other infectious diseases that may be associated with inclusions in hematopoietic cells are mentioned briefly within chapters. Of these, leishmaniasis could have received more attention, given its geographic distribution. There are 6 sections devoted to leucocytes: disorders of leucocyte number; leucocyte function; specific leucocyte disorders, including neutropenia, eosinophilia, and leukemia; and a subsection on feline retroviral infections, which also covers retroviral-associated anemias.

The section on hemostasis is very practical and well covered. It provides chapters on a general overview of hemostasis, as well as chapters on diagnostic techniques, disorders of platelet number, function, and disorders of secondary hemostasis. Another section specifically covers immune-mediated thrombocytopenia, von Willebrand's disease, hemophilia A, anticoagulant rodenticides, and disseminated intravascular coagulation.

The final section on transfusion medicine includes a chapter on procedures, including donor selection, compatibility testing and blood product preparation, and storage and administration. A general discussion of blood groups in this chapter is followed by a final brief chapter, specifically on feline blood groups. Finally, a 1-page appendix provides common hematological reference ranges for the dog and cat.

In authoring a book that is both of broad scope and detailed, it is difficult to avoid a certain degree of redundancy when diseases are addressed in more than one section. Confusion may arise, however, in using different terms or definitions for the same or similar diseases: examples include, the term paraneoplastic polycythemia in one chapter being referred to as physiologically inappropriate secondary polycythemia in another, or varying definitions of (pure) red cell aplasia, which is touched upon in several chapters. This practical book is easy to read and very well illustrated with numerous, high quality color photographs; helpful tables; diagnostic flow charts; and a well-designed index. As such, it is an invaluable reference manual for the student or small animal practitioner. It also provides sufficient detail for trainees in the fields of internal medicine, critical care, and clinical pathology.

Reviewed by ***Anne Lanevschi-Pietersma, DMV, MSc, Diplomate ACVP, Diplomate ECVCP,*** *Associate professor, Département de pathologie et microbiologie, Faculté de médecine vétérinaire, Université de Montréal, 3200 Sicotte, CP 5000, Saint-Hyacinthe, Quebec J2S 7C6.*