Coronary Artery Reperfusion

I. EARLY EFFECTS ON LOCAL MYOCARDIAL FUNCTION AND THE EXTENT OF MYOCARDIAL NECROSIS

P. R. Maroko, P. Libby, W. R. Ginks, C. M. Bloor, W. E. Shell, B. E. Sobel, and J. Ross, Jr.

From the Department of Medicine, University of California, San Diego, School of Medicine, La Jolla, California 92037

Abstract The effects of coronary artery reperfusion 3 hr after coronary occlusion on contractile function and the development of myocardial damage at 24 hr was studied experimentally. In 14 control and 6 reperfused dogs, relationships between epicardial ST segment elevation 15 min after coronary occlusion and myocardial creatine phosphokinase activity (CPK) and histologic appearance 24 hr later were examined. The electrocardiograms were recorded from 10 to 15 sites on the left ventricular epicardium and transmural samples for CPK and histology were obtained from the same sites where epicardial electrocardiograms had been recorded. An inverse relation existed between ST segment elevation (mv) 15 min after occlusion and log CPK activity (IU/ mg of protein) 24 hr later, log CPK $= -0.06ST + 1.26$. In dogs subjected to coronary artery reperfusion, there was significantly less CPK depression (log CPK $= -0.01ST + 1.31$, [$P < 0.01$]) than that expected from the control group. In the control group 97% of specimens showing ST segment elevations over 2 mv at 15 min showed abnormal histology 24 hr later. In contrast, in the reperfused group 43% of sites exhibiting elevated ST segment at 15 min showed abnormal histology 24 hr later. In six additional dogs it was shown that the paradoxical movement of the left ventricular wall could be reversed within 1 hr of perfusion. Therefore, by enzymatic and histologic criteria, as well as by functional assessment, coronary artery reperfusion 3 hr after occlusion resulted in salvage of myocardial tissue.

Received for publication 3 April 1972 and in revised form 20 June 1972.

INTRODUCTION

Mechanical failure of the heart muscle currently appears to be the main cause of in-hospital death in patients with acute myocardial infarction (1). Such cardiac failure is most likely the result of a large myocardial infarction (2, 3), and therefore several experimental approaches have been evaluated for decreasing the size of the developing infarcts by medical therapy (4–10). These approaches tend to affect favorably the energy balance of the heart by decreasing oxygen demand relative to supply or by enhancing anaerobic metabolism; however, a more direct method of preserving myocardial cells would be to increase oxygen supply by restoring blood flow to the obstructed vessel. It is not known whether or not coronary artery reperfusion can spare myocardial cells and restore their contractile function. Accordingly, the present studies undertook to examine this problem experimentally. Coronary artery reperfusion was carried out 3 hr after occlusion. Change in left ventricular contractile function was assessed immediately after the reperfusion, and alterations in the extent of damage determined by myocardial creatine phosphokinase assay and by histologic assessment 24 hr later (4, 5). An experimental method for evaluating the size of the resulting myocardial infarction at 1 wk, together with a comparison to control animals not subjected to reperfusion, is described in the accompanying work (11).

METHODS

Studies were carried out in 20 mongrel dogs anesthetized with sodium thiamylal. With respiration maintained mechani-

cally, a lateral thoracotomy was performed through the fifth left intercostal space and the heart suspended in a pericardial cradle. The left anterior descending coronary artery or one of its branches was dissected free so that it could be occluded. The extent and severity of myocardial ischemic injury was assessed by an epicardial electrocardiographic mapping technique described previously (4). Briefly, the method consists of recording electrocardiograms from 10–14 anatomically recognizable sites on the anterior surface of the left ventricle, chosen at the onset of each experiment such that some would be within and others distant from the expected area of ischemia. Epicardial electrocardiographic maps were obtained before and at intervals after occlusion of the coronary artery. ST segment elevation over 2 mv is considered abnormal (4–6), and the number of such sites (NST)[1] provides an index of the extent of ischemic injury. NST was always zero in maps obtained before occlusion. The average ST segment elevation at all sites, ($\overline{ST}$), provides an index of the severity of myocardial damage.

The animals were divided into two groups: a control (14 dogs) and a reperfused group (6 dogs). In the control group the coronary artery was permanently occluded with a ligature and epicardial ST segment maps obtained before and up to 3½ hr after the occlusion. The chest was then closed in layers and drained by an underwater self-retaining catheter. The dogs were extubated and allowed to recover but were maintained under sedation by additional small doses of sodium thiamylal. Electrocardiograms (lead aVF) and arterial pressure (obtained from an aortic catheter inserted through the left common carotid artery) were monitored throughout the experiment. All dogs received 40 cc/kg per 24 hr of normal saline through a catheter in the left jugular vein. 24 hr after occlusion the animals were again anesthetized and placed on artificial respiration. The chest incision was then reopened and the heart excised.

Transmural specimens from the same sites where the epicardial electrocardiograms had been previously recorded were immediately obtained and prepared for creatine phosphokinase (CPK) determinations. These specimens, weighing approximately 0.4 g, were submitted to homogenization and differential centrifugation and assayed as previously described (4, 12). CPK specific activity was expressed in international enzyme units per milligram of protein in the 31,000 *g* supernatant fraction. Reaction rates were linear for at least 15 min after a 5 min equilibration period. Enzyme activity was proportional to the amount of supernatant fraction protein added to the assay system, was acid and heat labile, and duplicate determinations agreed within 3%. At the time of sacrifice transmural specimens for histologic examination were also obtained from sites at which electrocardiograms had been recorded. These specimens were fixed in 10% formaldehyde solution stained with hematoxylin-eosin, coded, and graded for presence or absence or early

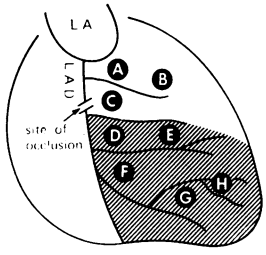

SITE	ST (mv)	CPK (I.U./mg prot)	HISTOLOGY
A	0	20.7	NORMAL
B	0	18.9	NORMAL
C	2	15.6	NORMAL
D	12	7.7	ABNORMAL
E	8	7.2	ABNORMAL
F	7	5.5	ABNORMAL
G	7	3.7	ABNORMAL
H	10	8.4	ABNORMAL

FIGURE 1 The relationship of ST segment elevation 15 min after occlusion to CPK activity and histologic structure 24 hr later in an experiment in the control group. *Left panel:* Schematic representation of the anterior surface of the heart and it's arteries. LA, left atrial appendage; LAD, left anterior descending coronary artery. The shaded area represents the area of ST segment elevation 15 min after occlusion. The circles represent sites where biopsies were taken. *Right panel:* Comparison between ST segment elevation and CPK and histologic analysis 24 hr later.

signs of necrosis by an independent observer as previously described (5).

The reperfused group was subjected to an identical protocol except that the coronary artery was occluded temporarily with one or two Schwartz intracranial arterial clamps (Pilling Surgical Instruments, Fort Washington, Pa.) and the occlusion was released after 3 hr. In both groups, additional electrocardiographic maps were recorded at ½, 1, 2, 3, and 3½ hr after occlusion. At postmortem examination, the coronary arteries were carefully opened and examined for the presence of thrombi with particular attention to the site of occlusion. Neither group received anticoagulant therapy. There was no evidence of a difference in the incidence of the ventricular tachyarrhythmias common in dogs commencing 4–6 hr after coronary artery occlusion (5, 13), and neither group received antiarrhythmic therapy since these arrhythmias were well tolerated hemodynamically.

The development of myocardial necrosis was estimated by comparing the ST segment elevation 15 min after occlusions at each site to the CPK activity and histologic appearance in transmural specimens obtained from the same site 24 hr later. This procedure was based on previous studies in which it was established that ST segment elevation at 15 min was inversely proportional to log CPK and therefore can be used to reliably predict expected CPK depletion 24 hr after occlusion (4). In a similar fashion, ST segment elevation 15 min postocclusion predicts with reasonable accuracy the histologic appearance at the same site 24 hr later (i.e. a site without ST segment elevation shows normal histology and sites with ST segment elevation of more than 2 mv show signs of necrosis). Therefore, these approaches permitted evaluation of the effects of reperfusion by observing possible deviations from the expected relationships in the treated group.

[1] *Abbreviations used in this paper:* CPK, creatine phosphokinase; EDD, end-diastolic distance; ESD, end-systolic distance; NST, number of sites exhibiting ST segment elevation over 2 mv; $\overline{ST}$, average ST segment elevation at all sites.

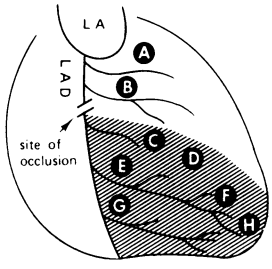

SITE	ST (mv)	CPK I U mg prot	HISTOLOGY
A	0	21.4	NORMAL
B	0	19.9	NORMAL
C	8	20.0	NORMAL
D	8	21.7	NORMAL
E	10	19.8	NORMAL
F	8	20.0	NORMAL
G	7	17.4	NORMAL
H	7	14.2	NORMAL

FIGURE 2 An example of a reperfused dog showing the effects of coronary artery reperfusion 3 hr after occlusion on the relationship of ST segment (at 15 min after occlusion) to CPK and histologic structure 24 hr later. *Left panel:* Schematic representation of the anterior surface of the heart and its arteries. LA, left atrial appendage; LAD, left anterior descending coronary artery; shaded area, area of ST segment elevation 15 min after coronary occlusion (before reperfusion); circles, biopsy sites. *Right panel:* Comparison between ST segment elevation 15 min after occlusion, i.e., before reperfusion, and CPK activity and histologic structure 24 hr later.

In six additional dogs, the effects of acute coronary artery occlusion and reperfusion on local myocardial contractile function were assessed. The dogs were anesthesized, the heart exposed, and the coronary artery isolated as described above. Three or four intramyocardial radiopaque metal beads were then inserted to lie in the left ventricular wall approximately 2 mm from the endocardium (14, 15); at least one bead was outside the zone subserved by the coronary artery to be occluded, and the rest within that area. The distance between the beads and their position in the ventricular wall were verified in the excised heart at postmortem examination. Before, and at intervals during and after release of a 3 hr period of coronary artery occlusion, biplane cineradiographs were recorded with a 16 mm Philips biplane cine system (Philips Medical Systems Inc., Shelton, Conn.) at 200 frames per sec, the dog being maintained in an identical position throughout the period of study. At the end of each experiment a 1-cm grid was filmed in the same position occupied by the heart to permit calibration and correction for X-ray distortion. The films were analyzed by identifying pairs of beads which exhibited paradoxical systolic excursion during the period of coronary occlusion, and documenting any changes that occurred up to 1 hr after the reperfusion. The change in the excursion (ΔD), that is, the difference between the end-diastolic distance (EDD) and the end-systolic distance (ESD) between paired beads was determined. A positive difference indicates normal ventricular motion, and a negative difference documents paradoxical movement.

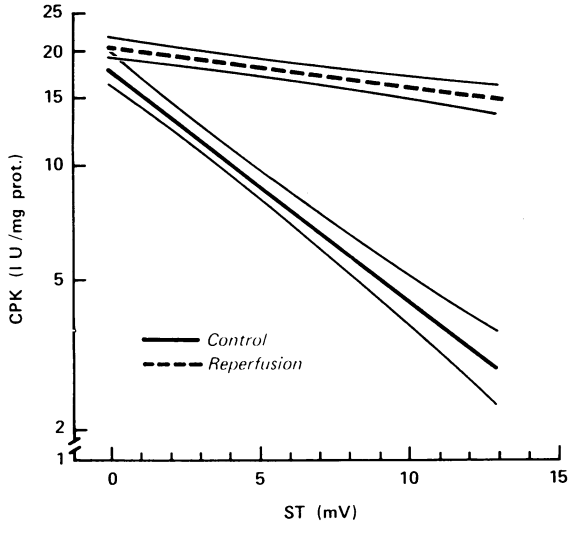

FIGURE 3 Relationship between epicardial ST segment elevation 15 min after occlusion and myocardial CPK activity 24 hr later in the same sites. In the control group (solid line) log CPK $= -0.06$ ST $+ 1.26$ ($r = 0.79$, n $= 102$ specimens, 14 dogs). In the reperfused group (dotted line) log CPK $= -0.01$ ST $+ 1.31$ ($r = 0.7$, 48 specimens, 6 dogs). 95% confidence limits are marked; difference in slopes $P < 0.01$.

RESULTS

Effects of reperfusion on the development of myocardial necrosis

CPK activity. In the control group, specimens from sites with normal ST segments had normal CPK activity, whereas specimens from sites with pathologic ST segment elevation always had depressed CPK (Fig. 1). In the group subjected to coronary artery reperfusion, sites with no abnormal ST segment elevation (0–2 mv) showed myocardial CPK activity at 24 hr within the normal range, as shown in the example in Fig. 2, but sites with abnormal ST segment elevation also showed CPK activities within the normal range (normal, 18.1±5.2, 2 SD).

In the 14 control dogs the regression equation relating ST segment elevation 15 min after occlusion to CPK 24 hr later was log CPK $= -0.06$ ST $+ 1.26$ (14 dogs, n $= 102$ specimens, $r = 0.79$, Fig. 3). In the six reperfused dogs, ST segment elevations at each site were compared to log CPK 24 hr later, and a significantly lower ($P < 0.01$) slope was found (log CPK $= -0.01$ ST $+ 1.31$, $r = 0.7$, six dogs, 48 specimens, Fig. 3). This difference in slope indicated that reperfusion prevented cells from undergoing CPK depletion.

In all experimental animals subjected to reperfusion, when average CPK activity in all sites with no ST segment elevation at 15 min was compared to average CPK in all sites which ST segment elevation at 15 min, the latter mean value was 15% lower (20.8±0.5 and 16.6±0.7 IU/mg of protein, respectively, $P < 0.01$). Therefore, despite CPK values within the normal range in the reperfused area, there were small but significant

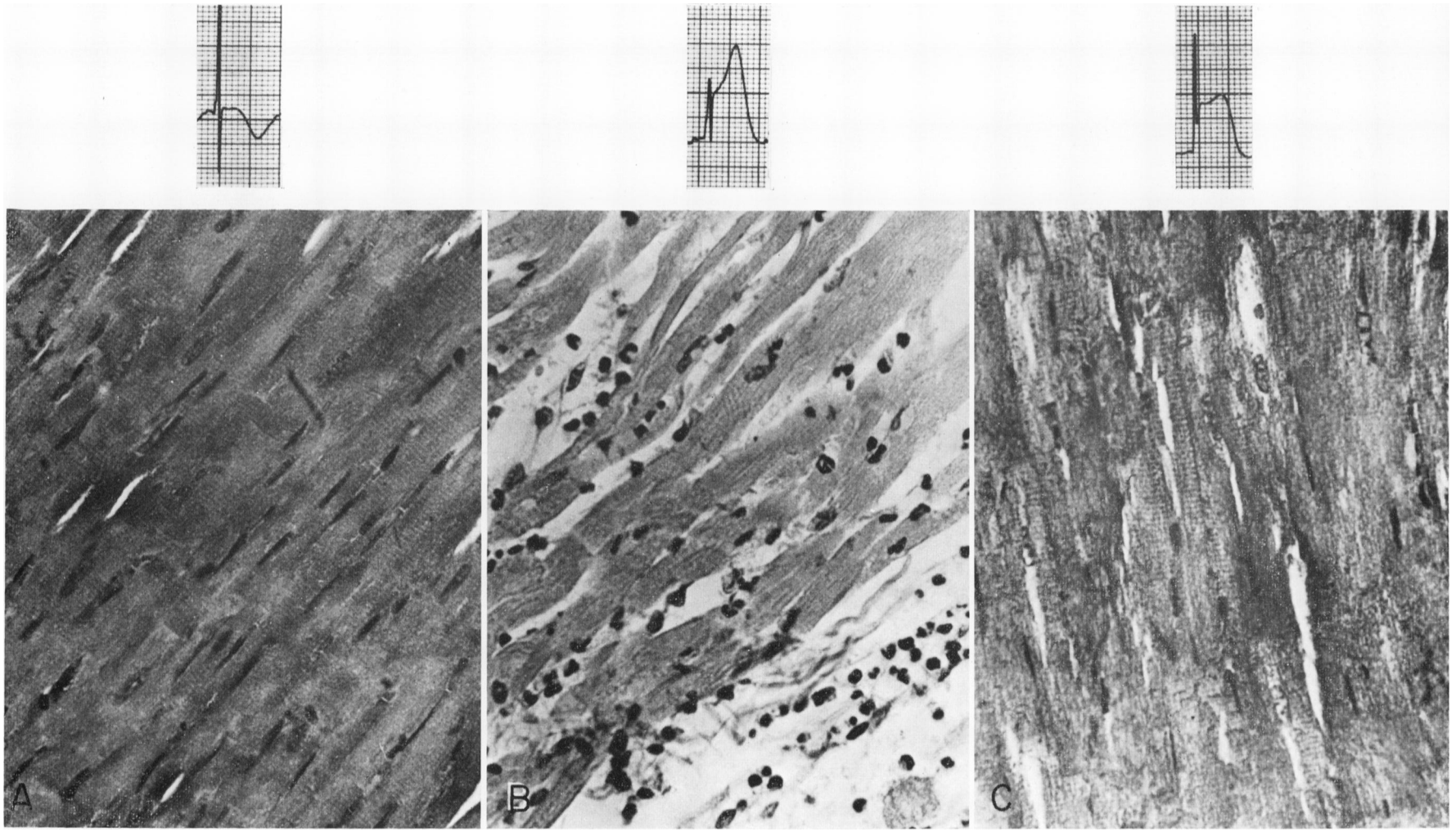

FIGURE 4 Epicardial electrocardiograms (top) 15 min after occlusion and histology 24 hr later (hemotoxylin and eosin stain × 250). (A) Site with no ST segment elevation from control group. Myocardial fibers are intact with normal nuclei and cross striations. (B) Site with ST segment elevation from the control, nonreperfused group. Note the extensive fragmentation of myocardial cells and loss of the cross striations. The myocardial nuclei show pyknosis and karyolysis. There is an extensive polymorphonuclear infiltrate. (C) Site with ST segment elevation before reperfusion obtained from a dog subjected to coronary artery reperfusion. Myocardial fibers are intact with normal cross striations and no inflammatory infiltrate.

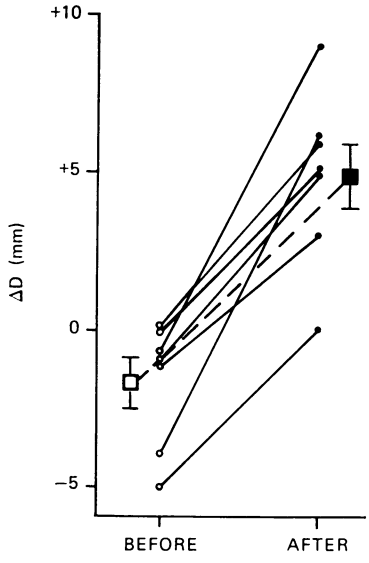

FIGURE 5 The effect of reperfusion at 3 hr on left ventricular wall motion. $\Delta D = EDD - ESD$ where EDD = distance between beads at end diastole and ESD = distance between beads at end systole. Before (open symbols): 3 hr after occlusion and just before reperfusion. After (closed symbols): 30 min after reperfusion. Squares and bars indicate means and SEM.

differences between these and control sites, values in the ischemic zone being slightly lower after the temporary ligation.

Histologic studies. In 81 sites from dogs in the control group examined histologically, 27 of 28 sites (96%) with no ST segment elevation (< 2 mv) were normal, while 51 of 53 (97%) of sites with abnormal ST segment elevations showed pathologic features compatible with early myocardial infarction (Figs. 1 and 4). In the 48 specimens obtained from the reperfused group, 19 of 20 (95%) of sites without ST segment elevation showed normal histology as in the control group. However, of 28 sites with abnormally elevated ST segments, only 12 sites (43%, $P < 0.005$) showed abnormal histologic features (Figs. 2 and 4). This finding indicates that structural integrity tended to be preserved at 24 hr as a consequence of coronary reperfusion at many sites otherwise destined to undergo necrosis.

Changes in ST segments after reperfusion

The epicardial ST segment elevation remained in four dogs during the 3 hr period of coronary occlusion and decreased greatly within 30 min after coronary reperfusion. In the reperfused animals, average ST segment elevation ($\overline{ST}$) decreased from 3.6±1.0 to 0.7±0.2 mv and NST from 5.5±1.7 to 1.0±0.4 within 30 min after reperfusion. In one instance a small, nonoccluding antemortem thrombus was present near the site of previous occlusion. This dog exhibited the lowest CPK values in the group and was the only dog in which all sites predicted to show histologic changes did so.

Effect of reperfusion on myocardial contractile function

In the six dogs studied cineradiographically, at least one pair of intramyocardial beads exhibited paradoxical systolic excursion after 3 hr of occlusion. (In one animal, two pairs of beads were analyzed). In each, paradoxical motion was evidenced by an average ΔD of −1.7±0.7 mm (Fig. 5). Within 1 hr after reperfusion significant reversal of abnormal wall motion was observed in each instance, the average ΔD increasing to 4.9±1.1 mm ($P < 0.01$) (Fig. 5).

DISCUSSION

Recent experimental studies suggest that the amount of acute tissue damage and consequently myocardial infarct size may be decreased by several interventions which favorably change the oxygen requirements of the myocardium (4–10). However, measures designed to minimize tissue damage after coronary occlusion so far have not been applied or critically evaluated clinically. Previous experimental studies aimed at increasing the oxygen supply to ischemic tissue by reopening an obstructed coronary artery were disappointing in preventing the occurrence of subsequent myocardial infarction, as discussed in detail in the accompanying report (11). However, the technique of aortocoronary bypass vein grafting has proved promising clinically (16–20), and the question has again arisen as to the maximum time interval during which myocardial cells distal to a coronary occlusion can resist ischemia and whether or not restoration of function can be accomplished. Moreover, the question of whether or not the extent of damage can be modified by reperfusion after more than 45 min of occlusion (21–25) has not been critically examined.

The development of methods for prediction of the size of a myocardial infarction 24 hr after the initial occlusion (4) has allowed a reinvestigation of these questions. The approach employed predicts myocardial CPK activity, as well as histological, histochemical, and ultrastructural changes at 24 hr (4, 5, 9), and an excellent correlation has been demonstrated between infarct size by gross anatomic measurement and myocardial CPK activity (12). The present study indicates that dogs in which reperfusion was effected at 3 hr exhibit much less CPK depletion at 24 hr than would have been predicted. These results are similar to previous findings showing that the infusion of glucose-in-

sulin-potassium solution, and propranolol, started 3 hr after coronary occlusion limits the extent of infarction (5), although to a lesser degree than reperfusion. Reduction in epicardial ST segment elevation for up to 3 hr after occlusion (4) and acute diminution in precordial ST segment elevation up to 6 hr after occlusion (7) by administration of propranolol, methoxamine, or norepinephrine also support the contention that myocardial damage can be limited by intervention several hours after occlusion. Whether or not significant differences between such effects, observed in the present study and these earlier investigations, will exist in species other than the dog remains to be established.

It was also considered important to determine whether or not reperfusion can restore impaired myocardial function. It was shown that paradoxical systolic motion could be reversed soon after reperfusion, demonstrating a clearcut functional benefit. Reversal of dyskinesia of the left ventricular wall after brief periods of induced angina pectoris has been reported using angiography (26) as well as apex cardiography (27). However, immediate improvement of function after prolonged periods of ischemia previously has not been shown to occur. Preliminary evidence obtained at postoperative cardiac catheterization studies (28) suggests that chronically impaired wall motion also may be at least partially restored in patients who have undergone saphenous vein bypass grafting procedures.

ACKNOWLEDGMENTS

This work was supported by the National Heart and Lung Institute, Myocardial Infarction Research Unit Contract No. PH-43-68-1332.

REFERENCES

1. Friedberg, C. K. 1968. General treatment of acute myocardial infarction. *Circulation.* **39**(Suppl. IV): 252.
2. Harnarayan, C., M. A. Bennett, B. L. Pentecost, D. B. Brewer. 1970. Quantitative study of infarcted myocardium in cardiogenic shock. *Br. Heart J.* **32**: 728.
3. Page, D. L., J. B. Caulfield, J. A. Kastor, R. W. DeSanctis, and C. A. Sanders. 1971. Myocardial changes associated with cardiogenic shock. *N. Engl. J. Med.* **285**: 133.
4. Maroko, P. R., J. K. Kjekshus, B. E. Sobel, T. Watanabe, J. W. Covell, J. Ross, Jr., and E. Braunwald. 1971. Factors influencing infarct size following experimental coronary artery occlusions. *Circulation.* **43**: 67.
5. Maroko, P. R., P. Libby, B. E. Sobel, C. M. Bloor, H. D. Sybers, W. E. Shell, J. W. Covell, and E Braunwald. 1972. The effect of glucose-insulin-potassium infusion on myocardial infarction following experimental coronary artery occlusion. *Circulation.* **45**: 1160.
6. Maroko, P. R., E. F. Bernstein, P. Libby, G. A. DeLaria. J. W. Covell, J. Ross, Jr., and E. Braunwald. 1972. The effects of intra-aortic balloon counterpulsation on the severity of myocardial ischemic injury following acute coronary occlusion. *Circulation.* **45**: 1150.
7. Maroko, P. R., P. Libby, J. W. Covell, B. E. Sobel, J. Ross, Jr., and E. Braunwald. 1972. Precordial S-T segment elevation mapping: an atraumatic method for assessing alterations in the extent of myocardial ischemic injury. The effects of pharmacologic and hemodynamic interventions. *Am. J. Cardiol.* **29**: 223.
8. Libby, P., P. R. Maroko, J. W. Covell, C. I. Malloch, J. Ross, Jr., and E. Braunwald. 1971. The effects of practolol on left ventricular function and infarct size following acute experimental coronary occlusion. *Clin. Res.* **19**: 116.
9. Libby, P., P. R. Maroko, W. E. Shell, C. M. Bloor, B. E. Sobel, and E. Braunwald. 1971 Decrease in the size of acute experimental myocardial infarct by hyaluronidase administration. *Circulation.* **44**(Suppl. II): 193.
10. Braunwald, E., J. W. Covell, P. R. Maroko, and J. Ross, Jr. 1969. Effects of drugs and of counterpulsation on myocardial oxygen consumption. Observations on the ischemic heart. *Circulation.* **39**(Suppl. IV): 220.
11. Ginks, W. R., H. D. Sybers, P. R. Maroko, J. W. Covell, B. E. Sobel, and J. Ross, Jr. 1972. Coronary artery reperfusion. II. Reduction of myocardial infarct size at one week after the coronary occlusion. *J. Clin. Invest.* **51**: 2717.
12. Kjekshus, J. K., and B. E. Sobel. 1970. Depressed myocardial creatine phosphokinase activity following experimental myocardial infarction in rabbit. *Circ. Res.* **27**: 403.
13. Harris, A. S. 1950. Delayed development of ventricular ectopic rhythms following experimental coronary occlusion. *Circulation.* **1**: 1318.
14. Mitchell, J. H., K. Wildenthal, C. B. Mullins. 1969. Geometrical studies of the left ventricle utilizing biplane cinefluorography. *Fed. Proc.* **28**: 1334.
15. McCullagh, W. H., J. W. Covell, and J. Ross, Jr. 1972. Left ventricular dilatation and diastolic compliance changes during chronic volume overloading. *Circulation.* **45**: 943.
16. Favaloro, R. G., D. B. Effler, C. Cheanvechai, R. A. Quint, and F. M. Sones, Jr. 1971. Acute coronary insufficiency (impending myocardial infarction and myocardial infarction). Surgical treatment by the saphenous vein graft technique. *Am. J. Cardiol.* **28**: 598.
17. Adam, M., B. F. Mitchel, C. J. Lambert. 1970. Immediate revascularization of the heart. *Circulation.* **42** (Suppl. II): 73.
18. Effler, D. B., R. G. Favaloro, L. K. Groves, and F. D. Loop. 1971. The simple approach to direct coronary artery surgery. Cleveland clinic experience. *J. Thorac. Cardiovasc. Surg.* **62**: 503.
19. Lambert, C. J., M. Adam, G. F. Geisler, E. Verzosa, M. Nazarian, and B. F. Mitchel, Jr. 1971. Emergency myocardial revascularization for impending infarctions and arrhythmias. *J. Thorac. Cardiovasc. Surg.* **62**: 522.
20. Hill, J. D., W. J. Kerth, J. J. Kelly, A. Selzer W. Armstrong, R. W. Popper, M. F. Langston, and K. E. Cohn. 1971. Emergency aortocoronary bypass for impending or extending myocardial infarction. *Circulation.* **43**(Suppl. I): 105.
21. Savranoglu, N., R. J. Boucek, and G. G. Casten. 1959. The extent of reversibility of myocardial ischemia in dogs. *Am. Heart J.* **58**: 726.
22. Fisher, S. III, and W. S. Edwards. 1963. Tissue necrosis after temporary coronary artery occlusion. *Am. Surg.* **29**: 617.

23. Yabuki, S., G. Blanco, J. E. Imbriglia, L. Bentivoglio, and C. P. Bailey. 1959. Time studies of acute, reversible, coronary occlusions in dogs. *J. Thorac. Cardiovasc. Surg.* **38**: 40.
24. Jennings, R. B. 1969. Early phase of myocardial ischemic injury and infarction. *Am. J. Cardiol.* **24**: 753.
25. Jennings, R. B., H. M. Sommers, P. B. Herdson, and J. P. Kaltenbach. 1969. Ischemic injury of myocardium. *Ann. N. Y. Acad. Sci.* **156**: 61.
26. Pasternac, A., J. I. Haft, J. R. Hampton, E. A. Amsterdam, R. Gorlin, and H. G. Kemp. 1969. Effect of ischemia induced by atrial pacing on left ventricular contraction pattern in man. *Circulation.* **40**(Suppl. III): 160.
27. Benchimol, A., and E. G. Dimond. 1962. The apex cardiogram in ischemic heart disease. *Br. Heart J.* **24**: 581.
28. Chatterjee, K., H. Marcus, R. Blum, W. Parmley, H. J. C. Swan, and J. Matloff. 1971. Left ventricular (LV) function following aortico-coronary bypass. *Circulation.* **44**(Suppl. II): 150.