Minimally Invasive Orthopedic Surgery: Arthroscopy

Robert Treuting, MD

Department of Surgery, Ochsner Clinic and Alton Ochsner Medical Foundation, New Orleans, LA

Arthroscopy, a minimally invasive alternative to standard open surgical techniques and now the most commonly performed orthopedic surgical procedure, was one of the greatest advances in orthopedic surgery of the 20th century. Minimally invasive surgeries result in less postoperative swelling than open techniques and reduce pain, risk of complications, and recovery times. Arthroscopy has evolved from a diagnostic tool to a therapeutic tool capable of treating a wide range of injuries and disorders. Many injuries, particularly those that at one time would have been career ending for athletes, can now be addressed with arthroscopy allowing a quicker return to full function. While arthroscopy has resulted in an overall decrease in morbidity compared with open techniques, it is still an invasive procedure and inherently involves risks. Almost all arthroscopic procedures can be performed in an outpatient setting. In 1999, 211 arthroscopic procedures were performed at Ochsner.

Treuting R. Minimally invasive orthopedic surgery: arthroscopy. The Ochsner Journal 2000; 2:158-163.

Orthopedic surgery, like all fields of medicine, experienced tremendous progress in the 20th century. Along with an improved understanding of basic molecular, cellular, genetic, and biomechanical factors of the musculoskeletal system, joint replacement surgery and arthroscopic surgery were the two most important innovations in orthopedic surgery in the last 100 years. These innovations, made possible by advances in technology, will continue to improve outcomes of treatment and expand the indications for usage as technology advances.

History

The origins of arthroscopy reach back to the 19th century when, in 1879, Nitze (1848-1706) devised the first modern cystoscope and demonstrated that it was possible to perform operations through this instrument (1). Jacobaeus (1879-1937) adapted the cystoscope for the examination of the pleural and peritoneal cavities in 1910 (1). Eight years later, Takagi (1888-1963) of Tokyo University became the first to apply the principles of endoscopy to a knee joint when he introduced a cystoscope into a cadaver knee (2). Professor Takagi continued to develop the arthroscope in Japan until his studies were disrupted by the outbreak of World War II. In 1921, Bircher (1882-1956) used a modified Jacobaeus laparoscope to visualize the interior of the knee in 18 patients in Switzerland and later published his findings on posttraumatic arthritis and the diagnosis of meniscal pathology (1). Kneuscher (1884-1943) published the first article on arthroscopy in the United States in 1925 but failed to pursue his studies further (3). In 1930, Burman (1901-1975) of the Hospital for Joint Disease in New York carried out extensive studies in cadavers using the arthroscope to examine every joint in the body (4). Burman published his findings in 1931, but clinical trials of his methods were met with skepticism and failed to create interest in the method. Takagi's student Watanabe (1921-1994) continued Takagi's work in the development of the arthroscope after World War II. In 1957, he introduced operative techniques using arthroscopic vision with the publication of the *Atlas of Arthroscopy* (5). A year later, Watanabe released the Watanabe #21, the first truly successful arthroscope, signaling the coming of age for modern arthroscopy.

In 1964, Dr. Robert Jackson went to Tokyo on fellowship to study tissue culture technique. After meeting and observing Watanabe, Jackson was convinced that arthroscopy offered a major

contribution in the diagnosis and treatment of joint disorders. Returning to Toronto General Hospital in 1965 with a Watanabe #21 arthroscope, Jackson began to practice arthroscopy in North America and published the first English text on the subject in 1976 (6). The University of Pennsylvania had offered the first major educational course on arthroscopy the year before. The introduction of fiberoptics and miniature television cameras in 1972 was the major technological development that led to the current widespread use of arthroscopy, and continued technologic development (of instruments, fiberoptics, electronics, lasers, etc.) has expanded the range of available techniques and indications.

Benefits

Prior to the widespread clinical use of arthroscopy and its specialized instrumentation, joint surgery required extended incisions and arthrotomies for exposure and treatment of joint pathology. Arthroscopy offers several advantages over such extended open arthrotomies. Compared with minimally invasive arthroscopic procedures, the extended exposure of joints prolongs recovery and increases pain and risk of complications, such as infection and arthrofibrosis. Minimally invasive surgeries, in general, result in less pain and postoperative swelling than open techniques. As a result, arthroscopically treated patients tend to heal faster and begin rehabilitation earlier and, subsequently, return to normal activity and work sooner.

As techniques and indications for treatment have expanded, injuries, particularly those in athletes that at one time would have been career ending, can now be addressed with arthroscopy allowing patients to return to full function. Examples include anterior cruciate knee ligament injuries in running athletes and intra-articular shoulder pathology in throwing athletes. While these problems can be addressed with extended open techniques, the comorbidity associated with open procedures often prevents such patients from returning to their pre-injury functional status. For professional athletes, these types of injuries more often led to the end of their paying careers.

Another socioeconomic benefit of arthroscopy is that almost all arthroscopic procedures can be performed in an outpatient setting. Some arthroscopists even have the facilities to perform procedures in an office setting, further reducing costs. Arthroscopy can be performed under many options of anesthesia ranging from local to general. Choice of anesthesia varies depending on the nature of the procedure and preferences of the patient and physician.

Complications

As with any invasive procedure, complications can occur with arthroscopy, now the most commonly performed orthopedic procedure. A 1983 national survey of 118,590 procedures reported 930 complications—an incidence of 0.8% (7). In this survey, equipment failure accounted for 17% of complications reported while vascular injuries accounted for 1%. Arthroscopy is a technical procedure requiring a wide range of equipment (camera and monitor, surgical equipment, pump, tourniquet, etc.) that can malfunction or break during a procedure. The surgeon should be familiar with the equipment and use it only for its intended purposes. Anesthesia problems can also occur, but this is not unique to arthroscopic surgery. When arthroscopic surgery is performed in an office setting, the surgeon must be prepared for any potential anesthesia problems that might arise.

Other complications include hemarthrosis, thrombophlebitis, arterial injury, nerve injury, compartment syndrome, and infection and metabolic complications in patients with metabolic diseases (diabetes, gout) or those using steroids. While arthroscopy has resulted in an overall decrease in morbidity compared with open techniques, it is still an invasive procedure and inherently involves risks.

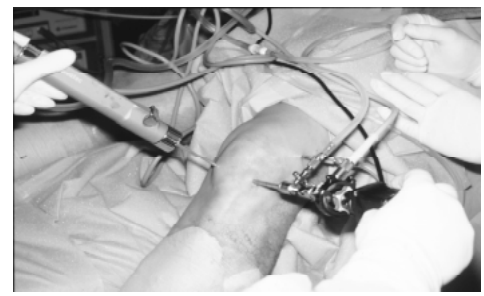

Figure 1. Dr. Lock Ochsner performs a knee arthroscopy.

Clinical Applications

The knee was the model joint for the development of arthroscopy, and the evolution of the arthroscope from diagnostic tool to therapeutic tool is common to its application to other joints. The arthroscope was initially used to clearly identify specific intra-articular pathology, thereby assisting treatment management. If treatment required surgery to address pathology such as meniscal tears, open arthrotomies were necessary. As equipment and techniques improved, arthroscopy became a surgical tool in its own right (Figure 1), reducing the comorbidity of joint surgery.

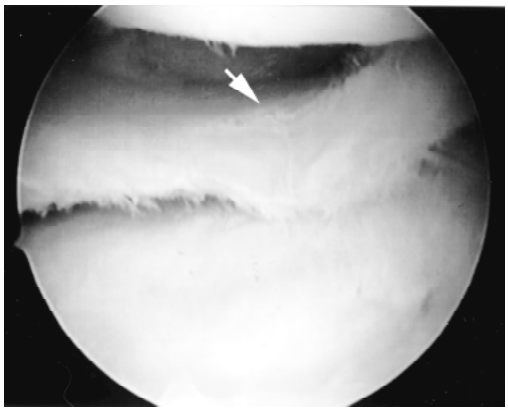

Figure 2a. Knee arthroscopy demonstrating degenerative meniscus tear.

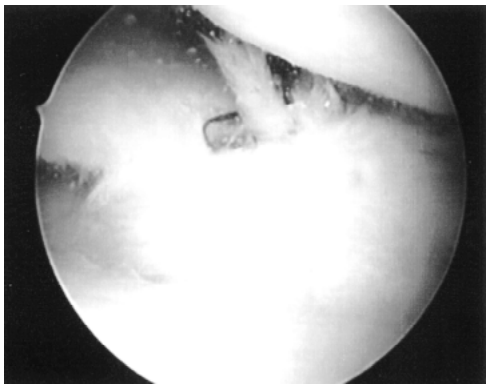

Figure 2b. Partial meniscectomy.

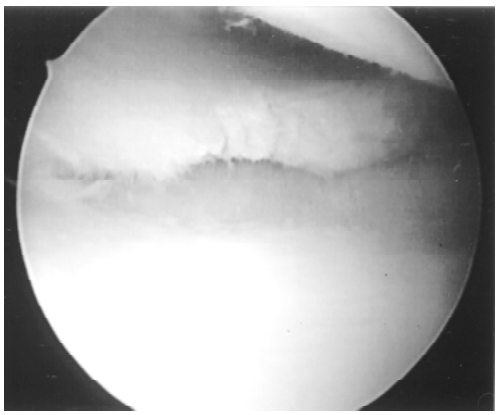

Figure 2c. Postmeniscectomy.

The Knee

The menisci of the knee, the semi-lunar shock absorbing cartilage between the femur and tibia, were the focus of most early knee arthroscopists (3). Prior to arthroscopy, total menisectomy was advocated for meniscal tears, and it was felt that a new meniscus would regenerate similar to the original (8). Subsequently, the use of arthroscopy has shown that partial meniscectomies for amenable tears provide better short- and long-term functional results and less arthritic changes than total meniscectomies (9). Currently, meniscal surgery of the knee (Figure 2) is the most commonly performed arthroscopic procedure. Peripheral tears of the menisci may be amenable to repair and today can be performed completely arthroscopically by experienced orthopedic surgeons.

With the popularity of athletics, the advent of arthroscopy has brought the treatment of the anterior cruciate ligament (ACL) of the knee to the forefront of modern orthopedics. At one time, an ACL injury could be career ending for a professional athlete. Today both the ACL and the posterior cruciate ligament can be reconstructed through an arthroscope. Such procedures now allow all athletes, from professionals to weekend warriors, to return to pre-injury levels of activity with appropriate rehabilitation.

The indications for knee arthroscopy are numerous and continue to expand. Arthroscopy has proven to be a beneficial, temporizing, and therapeutic procedure for the treatment of osteoarthritis (10). Knee arthroscopy for osteoarthritis offers an alternative pain relief option for patients who are not ready or are unwilling to undergo a major surgical procedure such as knee replacement surgery. Arthroscopic synovectomy of the knees in patients with rheumatoid arthritis and other hypertrophic synovial-producing syndromes has significantly reduced complications and improved outcomes compared with open synovectomies of the knee (11). Osteochondral injuries and osteochondritis dessicans lesions of the knee can be repaired and drilled (Figure 3) to stimulate fibrocartilaginous healing, and dissociated loose bodies (Figure 4) can easily be removed by arthroscopy.

Knee arthroscopy can also be used as an adjunct in assessing the intra-articular reduction of tibial plateau fractures and intra-

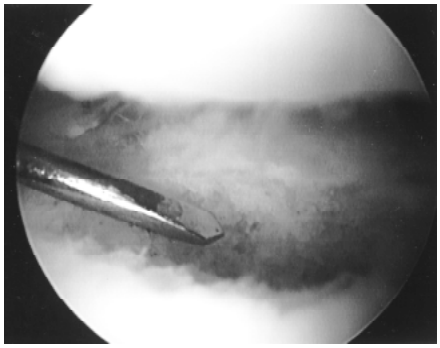

Figure 3. Drilling osteochondral defect to stimulate fibrocartilaginous healing.

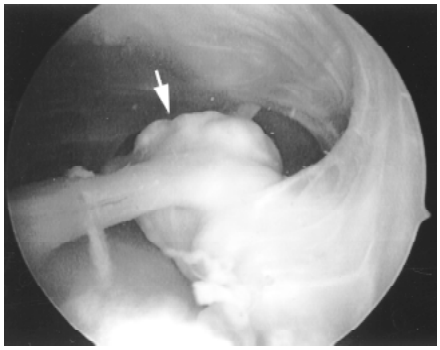

Figure 4. Knee arthroscopy demonstrating loose body.

Figure 5a. Noninvasive ankle distraction system allowing improved access in ankle arthroscopy.

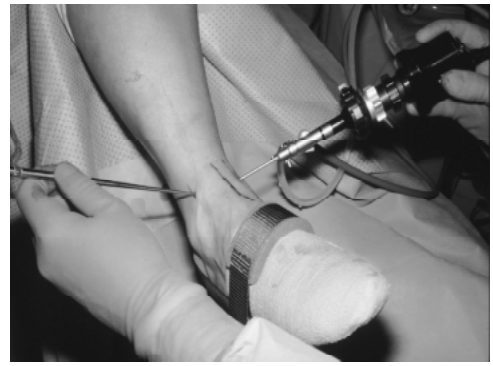

Figure 5b. Ankle arthroscopy using noninvasive ankle distractor.

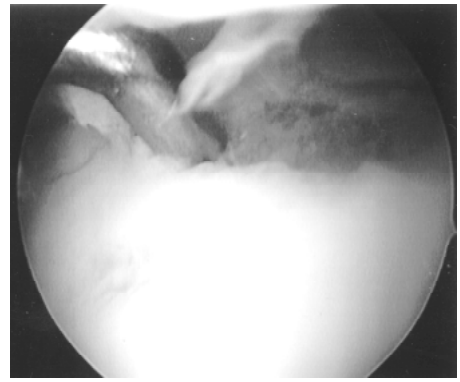

Figure 5c. Ankle arthroscopy demonstrating talar osteochondral defect.

articular distal femur fractures. Knee arthroscopy offers an effective means of draining septic knee effusions, as well as traumatic hemarthroses, while at the same time offering an excellent diagnostic examination of the intra-articular structures of the knee. More recently, exciting advances such as osteochondral and meniscal transplants have continued, and as these techniques develop will continue to use arthroscopy as a primary portal of entry.

The Shoulder

The shoulder is the second most common joint evaluated and treated by arthroscopy. As with the knee, early arthroscopy of the shoulder focused on diagnosing and understanding intra-articular joint pathology. Only in the last 2 decades has shoulder arthroscopy been recognized as both a diagnostic and therapeutic technique with a low incidence of complications (12).

Both the glenohumeral joint and the subacromial space (a common site of shoulder pathology) can be evaluated and treated using arthroscopy. In the throwing athletes, shoulder arthroscopy has greatly improved understanding of normal shoulder function and specific anatomic pathology. A review of 100 procedures in athletes noted a high percentage of concomitant pathology in patients with preoperative diagnoses such as instability and impingement of the rotator cuff (13). Shoulder arthroscopy is currently used in the evaluation and treatment of shoulder instability, rotator cuff pathology, subacromial impingement, acromioclavicular joint disorders, atypical shoulder pain with inconclusive imaging studies, adhesive capsulitis (frozen shoulder), osteoarthritis, and synovitis of the shoulder.

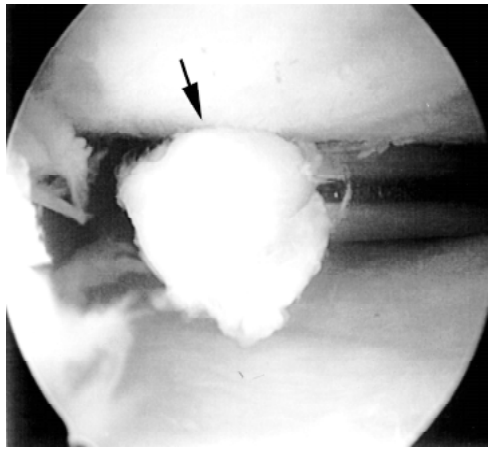

Figure 6. Ankle arthroscopy demonstrating osteochondral loose body.

The Ankle

Limitations of smaller joint arthroscopy have been overcome by the development of smaller equipment and cameras, the understanding of safe portals of entry, and the innovation of joint distraction to allow for the introduction of arthroscopic equipment. The ankle can be a difficult joint to evaluate completely because of its restrictive bony and ligamentous architecture. Due to the joint's restrictive anatomy, early ankle arthroscopy was limited to addressing anterior pathology. Smaller cameras and operator-friendly distractor devices are now available that allow for complete arthroscopic evaluation of the ankle joint from a perspective unobtainable with open exposures of the ankle (Figure 5). Current therapeutic indications for ankle arthroscopy include evaluation and treatment of anterior ankle impingement due to synovitis and/or degenerative osteophytes of the distal tibia and talar neck. Traumatic osteochondral injuries and associated loose bodies (Figure 6) are amenable to debridement and removal through arthroscopy. Arthroscopic tibiotalar fusions can be performed in selected patients with degenerative arthritis and minimal deformity (14). Synovitis of rheumatoid arthritis and other inflammatory arthritis can also be addressed with ankle arthroscopy.

Other Small Joints

The wrist is another joint that relies on distraction techniques for optimal arthroscopic evaluation, and wrist arthroscopy is felt to be the gold standard for diagnosis of intra-articular wrist pathology (15). Indications for therapeutic wrist arthroscopy include triangular fibrocartilage complex tears, adjuncts to reduction and fixation of intrarticular fractures and ligament disruptions, loose body removal, debridement of chondral defects, synovectomy, degenerative arthritis, and septic arthritis.

The elbow is surrounded by multiple nerves and vascular structures. The arthroscopic understanding of anatomy and the establishment of safe entry portals along with development of smaller instruments have allowed elbow arthroscopy to become an alternative to open procedures for the evaluation and treatment of certain disorders. Therapeutic indications include removal of osteochondral loose bodies, synovectomy, temporizing arthritis debridement, radial head excision for radial head fractures, and septic arthritis. As with the other joints, elbow arthroscopy is an

Table 1. Arthroscopic procedures performed at Ochsner Clinic in 1999.

Knee (177)	
Partial menisectomy	94
Chondroplasty/Arthroplasty	45
Anterior cruciate ligament reconstruction	10
Diagnostic exam	9
Meniscal repair	6
Synovectomy	7
Loose body removal	4
Infection drainage	2
Shoulder (23)	
Acromioplasty	18
Debridement	2
Diagnostic exam	2
Synovectomy	1
Ankle (5)	
Synovectomy	2
Osteochondritis dissecans drilling	2
Loose body removal	1
Wrist (4)	
Debridement of triangular fibrocartilagenous complex	3
Synovectomy	1
Elbow (2)	
Loose body removal	1
Synovectomy	1
Total	**211**

excellent diagnostic tool, providing a magnified view of the joint that cannot be achieved by standard open exposures.

Endoscopic techniques have also been developed and used for other orthopedic-related disorders such as carpal tunnel syndrome and plantar fasciitis. Although most of these techniques have not shown a clear therapeutic advantage over open techniques, they do offer further options for the treatment of these disorders.

Arthroscopy at Ochsner

Two hundred eleven (211) arthroscopic procedures were performed at Ochsner in 1999 (Table 1). The knee was the most common joint treated and meniscal tears and degenerative joint disease were the most common diagnoses addressed by arthroscopy. The majority of arthroscopies were performed by joint reconstruction specialists who treat a relatively older population of patients with arthritis problems. In the summer of 2000, the addition of an orthopedic sports medicine specialist to the Ochsner orthopedic staff is expected to bring an increase in the number of arthroscopic procedures for more activity-related injuries.

Conclusion

Arthroscopy, one of the greatest advances in orthopedic surgery in the 20th century, offers a minimally invasive alternative to standard open surgical techniques, which often require extended incisions for adequate joint exposure. Decreased comorbidity, shorter rehabilitation, and the resulting socio-economic benefits are proven advantages. Arthroscopic surgery has improved the understanding of joint pathology and expanded therapeutic options for previously unknown or less understood joint disorders and continues to develop into a tool vital to future advances in orthopedic surgery.

References

1. Peltier LF. Orthopedics. A History and Iconography. San Francisco: Norman Publishing, 1993.
2. Watanabe M. Memories of the early days of arthroscopy. Arthroscopy 1986; 2:209-214.
3. Kreuscher PH. Semilunar cartilage disease: A plea for the early recognition by means of the arthroscope and the early treatment of this condition. Illinois Medical Journal 1931; 47:290-292.
4. Burman MS. Arthroscopy or the direct visualization of joints: An experimental cadaver study. J Bone Joint Surg 1931;13:669-695.
5. Watanabe M, Takeda S, Ikeuchi H. Atlas of Arthroscopy. Tokyo: Igaku-Shoin Ltd., 1957.
6. Jackson RW, Dandy DJ. Arthroscopy of the Knee. New York: Grune & Stratton, 1976.
7. Complications of arthroscopy and arthroscopic surgery: results of a national survey. Committee on Complications of Arthroscopy Association of North America. Arthroscopy 1985; 1:214-220.
8. Smillie IS. Observations on regeneration of semilunar cartilages in man. Br J Surg 1944; 31:398-401.
9. McGinity JB, Geuss LF, Marvin RA. Partial or total meniscectomy: A comparative analysis. J Bone J Surgery 1977; 59A: 763-766.
10. Jackson RW, Morans HJ, Silver RS. The arthroscopic treatment of degenerative arthritis of the knee. J Bone Joint Surgery 1988; 70B:332.
11. Smiley P, Wasilewski SA. Arthroscopic synovectomy. Arthroscopy 1990; 6:18-23.
12. Ogilvie-Harris DJ, Wiley AM. Arthroscopic surgery of the shoulder: A general appraisal. J Bone Joint Surg 1986; 68B:201-207.
13. Hurley JA, Anderson TE. Shoulder arthroscopy: Its role in evaluating shoulder disorders in the athlete. Am J Sports Med 1990; 18:480-483.
14. Morgan CD. Arthroscopic tibiatalar orthrodesis. Jefferson Orthop J 1986; 16:50-52.
15. Bain G, Richards R, Roth J. Arthroscopy of the wrist: Introduction and indications. In: McGirt, JB (editor). Operative Arthroscopy. Philadelphia, PA: Lippincott-Raven, 1996: 897-903.

Dr. Treuting is a member of Ochsner's Department of Orthopedic Surgery.