www.jkns.or.kr 10.3340/jkns.2011.49.4.237
Print ISSN 2005-3711 On-line ISSN 1598-7876
J Korean Neurosurg Soc 49 : 237-240, 2011
Copyright © 2011 The Korean Neurosurgical Society

Case Report

A Ganglion Cyst in the Second Lumbar Intervertebral Foramen

Sang Woo Kim, M.D.,[1] Joon Hyuk Choi, M.D.,[2] Min Su Kim, M.D.,[1] Chul Hoon Chang, M.D.[1]
Departments of Neurosurgery,[1] Pathology,[2] College of Medicine, Yeungnam University, Daegu, Korea

Ganglion cysts usually arise from the tendon sheaths and tissues around the joints. It is usually associated with degenerative arthritic changes in older people. Ganglion cyst in the spine is rare and there is no previous report on case that located in the intervertebral foramen and compressed dorsal root ganglion associated severe radiculopathy. A 29-year-old woman presented with severe left thigh pain and dysesthesia for a month. Magnetic resonance imaging revealed a dumbbell like mass in the intervertebral foramen between second and third lumbar vertebrae on the left side. The lesion was removed after exposure of the L2-L3 intervertebral foramen. The histological examination showed fragmented cystic wall-like structure composed of fibromyxoid tissue but there was no lining epithelium. A ganglion cyst may compromise lumbar dorsal root ganglion when it located in the intervertebral foramen. Although it is very rare location, ganglion cyst should be included in the differential diagnosis for intervertebral foraminal mass lesions.

Key Words : Ganglion cyst · Radiculopathy · Lumbar vertebra · Posterior longitudinal ligament.

INTRODUCTION

Ganglion cysts usually appears to have arisen from the vertebral facet joints like synovial cysts but more exactly speaking, they arise from the tendon sheaths and tissues around the joints[11,13,25,27]. Usually, they are asymptomatic but it may cause a mass effect on the surrounding thecal sac or nerve roots[31,34].

We present a case of ganglion cyst that was unusually located in the intervertebral foramen and compressed dorsal root ganglion associated severe radiculopathy.

CASE REPORT

A 29-year-old woman presented to the outpatient clinic with the complaint of severe left thigh pain and dysesthesia for a month. The pain was not relieved by non-steroid anti-inflammatory drugs. She denied experiencing any other prior trauma. The visual analog scale score for pain was 8 out of 10 and it went down to 6 with high potent analgesics such as fentanyl patch.

Result of straight leg raising test was normal for the left leg and bilateral deep tendon reflexes of the lower extremity were also normal. There was no objective motor weakness but she could not walk due to thigh pain.

Magnetic resonance (MR) imaging revealed a dumbbell like mass in the intervertebral foramen between second and third lumbar vertebrae on the left side (Fig. 1). Gadolinium-DTPA administration increased the signal intensity at the periphery of the mass. According to its location and shape, it was thought to be a schwannoma. There was neither evidence of degenerative disc disease nor degenerative changes around the vertebrae and the facets.

When we tried to enter the intertransverse membrane, somewhat mucoid dark fluid was spilled out through the lateral part of pars interarticularis. Following exposure the foramen with drilling out the lamina around pars interarticularis, the mass was found to compress the dura and the left L2 nerve root (Fig. 2). There was no connection or communication with the dural structures and facet or ligamentum flavum, but the cyst was adhered tightly to the second lumbar dorsal root ganglion and postganglion spinal nerve root. Furthermore, it was connected to a posterior longitudinal ligament with stalk, so it was removed by excising the stalk. It was thought that this probably represented a ganglion cyst arose from the posterior longitudinal ligament and then occupied the intervertebral foramen. The mass around the second lumbar dorsal root ganglion was excised totally. The dura resumed its normal contour and the L2 root could be visualized.

Immunohistochemical stains for smooth muscle actin, CD31,

• Received : June 30, 2010 • Revised : August 12, 2010
• Accepted : March 27, 2011
• Address for reprints : Sang Woo Kim, M.D.
Department of Neurosurgery, College of Medicine, Yeungnam University, 317-1 Daemyeong-5 dong, Nam-gu, Daegu 705-717, Korea
Tel : +82-53-620-3790, Fax : +82-53-620-3770
E-mail : sw902@ynu.ac.kr

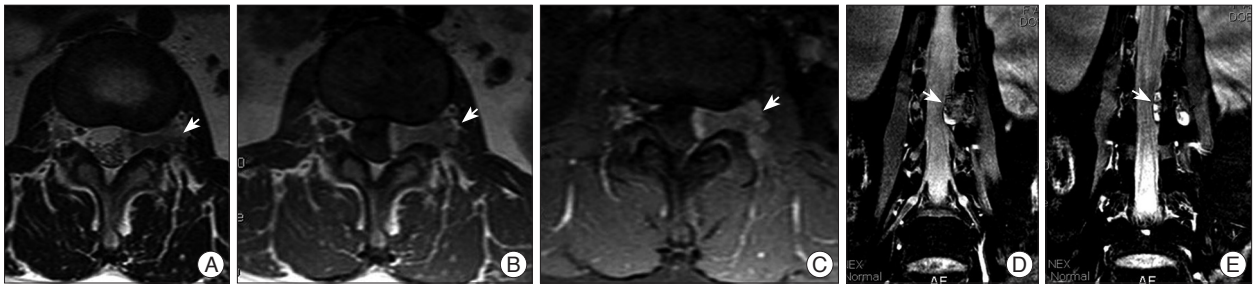

Fig. 1. A and B : MR imaging reveals a dumbbell like mass in the intervertebral foramen between second and third lumbar vertebrae on the left side (arrow). C : Gadolinium-DTPA administration increases the signal intensity at the periphery of the mass. D and E : MR coronal view shows multi-loculated extradural cysts in the intervertebral foraminen (arrows).

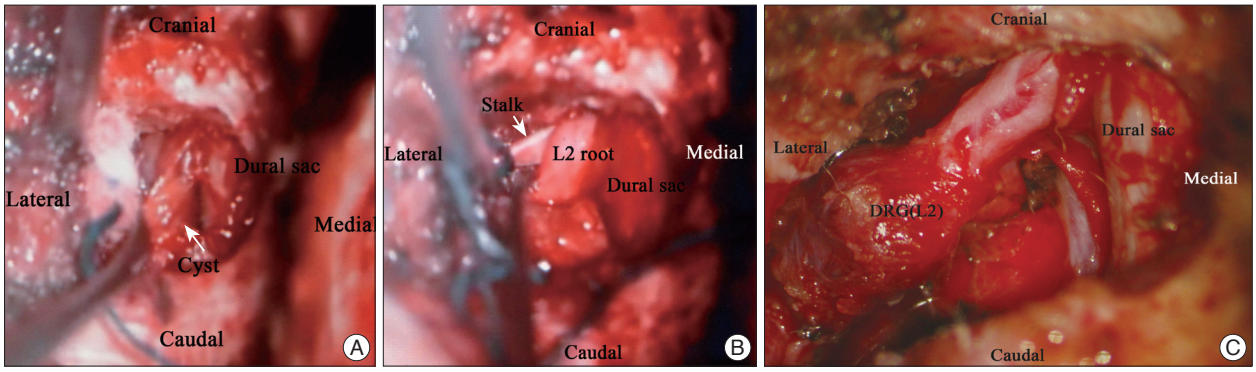

Fig. 2. A : Following the exposure of the foramen, the mass is found to compress the dura and the left L2 nerve root (arrow). B : The cyst is connected to a posterior longitudinal ligament with stalk (arrow). C : L2 nerve root and DRG is be seen after removal of the cyst.

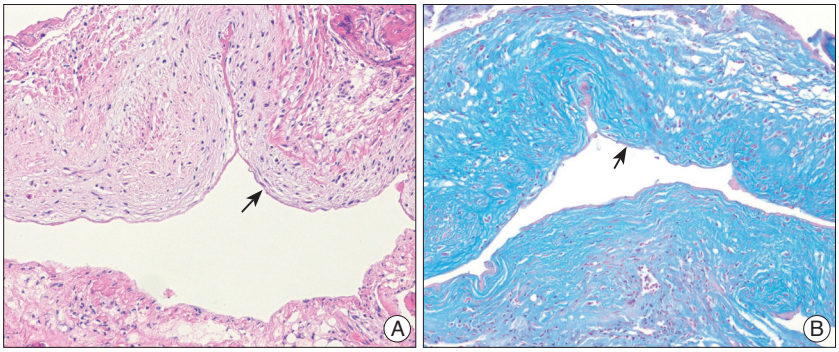

Fig. 3. Microscopic findings. A : The tissue shows cystic wall-like structure composed of fibromyxoid tissue (arrow). The lining epithelium is not present (H & E stain, ×100). B: Alcian blue stain shows blue-tinged myxoid change (arrow) (Alcian blue stain, ×100).

CD34, S100 protein, and cytokeratin (AE1/AE3) were negative. The tissue showed cystic wall-like structure composed of fibromyxoid tissue but there was no lining epithelium. Alcian blue stain highlighted myxoid change of the cystic wall (Fig. 3). These histological findings were consistent with ganglion cyst.

The patient made an excellent postoperative recovery. The leg pain disappeared completely with mild hypesthesia and the patient was discharged a week after surgery.

DISCUSSION

Ganglion cysts usually arise from around facet joints, like synovial cysts[18,34,35]. They are loosely attached to tendon sheaths or communicate with a joint capsule. The most common location is the dorsum of the wrist[18,24]. The structure can be multi-loculated. Intraspinal ganglion cysts commonly occur from the degenerative facets or the ligamentum flavum and less commonly from the posterior longitudinal ligament[4,11,13,23,25,29,32]. Most intraspinal synovial or ganglion cysts in the lumbar spine occur at L4-L5 and occasionally at L5-S1 and L3-L4[5,11,16]. It is usually associated with a degenerative arthritic changes and increased joint motion in older age groups[19,27]. The cases of ganglion cysts originating from the posterior longitudinal ligament are reported in younger than the cases occurred from facets or ligamentum flavum[22]. When the ganglion cysts occur in the spinal canal they usually induce radiculopathic complaints[6]. In current case, the patient had severe radicular pain which presumed to be caused by compression the dorsal root ganglion at L2-L3 intervertebral foramen without any evidence of degenerative disease in her spine.

The pathogenesis of the ganglion cysts is controversial. Herniation of the synovium into the surrounding tissue like synovial cysts, posttraumatic degeneration of connective tissue and inflammation have been considered as the causes[21,24]. Other possible mechanisms for the development of ganglion cysts in-

clude repeated mechanical stress, facet arthrosis, myxoid degeneration of periarticular fibrous tissues and liquefaction with chronic damage, increased production of hyaluronic acid by fibroblasts, and a proliferation of mesenchymal cells[7,15,18,27,34,35]. Ganglion cyst can develop independently from a joint.

In the differential diagnosis of the extramedullary or extradural lesions of the spine, extruded or sequestered disc fragment, schwannoma, meningioma, metastasis, arachnoid cysts, cysts of the ligamentum flavum, perineural cyst, discal cyst and rheumatoid pannus should be considered[9,10,20-22,26]. High signal characteristic with T2 weighted MR imaging and inhomgeneous enhancement is present in schwannomas[33]. Diffuse contrast enhancement with or without calcification can be observed in meningiomas. Metastatic tumors usually cause osteolysis with expanding mass. Ganglion cysts appear as low signal intensity lesions with T1 weighted MR image, high or mixed signal intensity lesions with T2 weighted image. The periphery of the cyst represents a fibrous capsule which may enhance after administration of contrast[9,17,20,22,32].

A synovial cyst has a wall lined by synovial cells with clear and xanthochromic fluid. A ganglion cyst, on the other hand has gelatinous protein material and myxoid degeneration of the fibrous adventitial tissue, but has not synovium like epithelium[3,15,18,30,31].

Ganglion cysts usually are asymptomatic because they are more common on the dorsal aspect of facet joints. When one found bleeding into the lumen of the cyst, trauma may have played a role in exacerbation of the symptoms due to bleeding[2,7,14,30]. According to its location, ganglion cyst may cause nerve root compression or myelopathy[31,34].

Although spontaneous regression of ganglion cyst could be observed like synovial cyst, surgical treatment is recommended if it is symptomatic such as intractable pain or significant neurological deficit[16,18,28,35]. Other modalities include facet injection or aspiration, epidural corticosteroid injections[1,8,16-18]. Most juxtafacet cysts are associated with facet degeneration so facetectomy with or without fusion is recommended[12,18]. But ganglion cysts are associated with lesser significant facet degeneration and allow saving the facets like this case.

CONCLUSION

A ganglion cyst in the spine should be considered a rare cause of lumbar radiculopathy. A ganglion cyst may compromise lumbar dorsal root ganglion when it is located in the intervertebral foramen. Although it is very rare location, ganglion cyst should be included in the differential diagnosis for intervertebral foraminal mass lesions. This is a rare case of ganglion cyst presumed to originate from the posterior longitudinal ligament then occupied the intervertebral foramen without any evidence of degenerative change in young woman's spine.

References

1. Abdullah AF, Chambers RW, Daut DP : Lumbar nerve root compression by synovial cysts of the ligamentum flavum. Report of four cases. **J Neurosurg 60** : 617-620, 1984
2. Arantes M, Silva RS, Romão H, Resende M, Moniz P, Honavar M, et al. : Spontaneous hemorrhage in a lumbar ganglion cyst. **Spine (Phila Pa 1976) 33** : E521-E524, 2008
3. Ayberk G, Ozveren F, Gök B, Yazgan A, Tosun H, Seckin Z, et al. : Lumbar synovial cysts : experience with nine cases. **Neurol Med Chir (Tokyo) 48** : 298-303; discussion 303, 2008
4. Barea D, Teschner D, Chouc P, Jeandel P, Briant JF : [Cyst of the lumbar posterior longitudinal ligament. an unusual cause of non-discal sciatica.] **J Radiol 77** : 579-581, 1996
5. Bhushan C, Hodges FJ 3rd, Wityk JJ : Synovial cyst (ganglion) of the lumbar spine simulating extradural mass. **Neuroradiology 18** : 263-268, 1979
6. Bloch J, Hawelski S, Benini A : [Cyst of the ligamentum flavum of the lumbar spine : description of 6 cases.] **Schweiz Med Wochenschr 127** : 728-732, 1997
7. Brish A, Payan HM : Lumbar intraspinal extradural ganglion cyst. **J Neurol Neurosurg Psychiatry 35** : 771-775, 1972
8. Bureau NJ, Kaplan PA, Dussault RG : Lumbar facet joint synovial cyst : Percutaneous treatment with steroid injections and distention--clinical and imaging follow-up in 12 patients. **Radiology 221** : 179-185, 2001
9. Charest DR, Kenny BG : Radicular pain caused by synovial cyst : an underdiagnosed entity in the elderly? **J Neurosurg 92** : 57-60, 2000
10. Chiba K, Toyama Y, Matsumoto M, Maruiwa H, Watanabe M, Nishizawa T : Intraspinal cyst communicating with the intervertebral disc in the lumbar spine : discal cyst. **Spine (Phila Pa 1976) 26** : 2112-2118, 2001
11. Chimento GF, Ricciardi JE, Whitecloud TS 3rd : Intraspinal extradural ganglion cyst. **J Spinal Disord 8** : 82-85, 1995
12. Choudhri HF, Perling LH : Diagnosis and management of juxtafacet cysts. **Neurosurg Focus 20** : E1, 2006
13. Christophis P, Asamoto S, Kuchelmeister K, Schachenmayr W : "Juxtafacet cysts", a misleading name for cystic formations of mobile spine (CYFMOS). **Eur Spine J 16** : 1499-1505, 2007
14. Gazzeri R, Canova A, Fiore C, Galarza M, Neroni M, Giordano M : Acute hemorrhagic cyst of the ligamentum flavum. **J Spinal Disord Tech 20** : 536-538, 2007
15. Giger R, Szalay-Quinodoz I, Haenggeli A, Dulguerov P : Ganglion cyst of the spinal anterior longitudinal ligament presenting as a retropharyngeal mass. **Am J Otolaryngol 23** : 390-393, 2002
16. Hagen T, Daschner H, Lensch T : [Juxta-facet cysts : magnetic resonance tomography diagnosis.] **Radiologe 41** : 1056-1062, 2001
17. Houten JK, Sanderson SP, Cooper PR : Spontaneous regression of symptomatic lumbar synovial cysts. report of three cases. **J Neurosurg 99** : 235-238, 2003
18. Hsu KY, Zucherman JF, Shea WJ, Jeffrey RA : Lumbar intraspinal synovial and ganglion cysts (facet cysts). Ten-year experience in evaluation and treatment. **Spine (Phila Pa 1976) 20** : 80-89, 1995
19. Kao CC, Uihlein A, Bickel WH, Soule EH : Lumbar intraspinal extradural ganglion cyst. **J Neurosurg 29** : 168-172, 1968
20. Koga H, Yone K, Yamamoto T, Komiya S : Percutaneous CT-guided puncture and steroid injection for the treatment of lumbar discal cyst : a case report. **Spine (Phila Pa 1976) 28** : E212-E216, 2003
21. Kornberg M : Nerve root compression by a ganglion cyst of the lumbar anulus fibrosus. A case report. **Spine (Phila Pa 1976) 20** : 1633-1635, 1995
22. Le Breton C, Garreau de Luobresse C, Awky J, Khalil A, Sibony M, Judet T, et al. : L5 radicular pain related to a cystic lesion of the posterior longitudinal ligament. **Eur Radiol 10** : 1812-1814, 2000
23. Lin RM, Wey KL, Tzeng CC : Gas-containing "ganglion" cyst of lumbar posterior longitudinal ligament at L3. Case report. **Spine (Phila Pa 1976) 18** : 2528-2532, 1993
24. Maresca L, Meland NB, Maresca C, Field EM : Ganglion cyst of the spi-

nal canal. Case report. **J Neurosurg 57** : 140-142, 1982
25. Marshman LA, Benjamin JC, David KM, King A, Chawda SJ : "Disc cysts" and "posterior longitudinal ligament ganglion cysts": synonymous entities? Report of three cases and literature review. **Neurosurgery 57** : E818, 2005
26. Milcan A, Ozdemir C, Karabacak T, Duce MN, Bağdatoğlu C : [A case of lumbar ganglion cyst causing radiculopathy.] **Acta Orthop Traumatol Turc 39** : 79-82, 2005
27. Mizutamari M, Sei A, Fujimoto T, Taniwaki T, Mizuta H : L5 radiculopathy caused by a ganglion cyst of the posterior longitudinal ligament in a teenager. **Spine J 9** : e11-e14, 2009
28. Oertel MF, Ryang Y, Ince A, Gilsbach JM, Rohde V : Microsurgical therapy of symptomatic lumbar juxta facet cysts. **Minim Invasive Neurosurg 46** : 349-353, 2003
29. Ogawa Y, Kumano K, Hirabayashi S, Aota Y : A ganglion cyst in the lumbar spinal canal. A case report. **Spine (Phila Pa 1976) 17** : 1429-1431, 1992
30. Onofrio BM, Mih AD : Synovial cysts of the spine. **Neurosurgery 22** : 642-647, 1988
31. Pendleton B, Carl B, Pollay M : Spinal extradural benign synovial or ganglion cyst : case report and review of the literature. **Neurosurgery 13** : 322-326, 1983
32. Shiono T, Yoshikawa K, Aota Y, Eguchi M, Teshima Y, Tanaka J, et al. : Two cases of ganglion cysts in the lumbar spinal canal. **Radiat Med 12** : 125-128, 1994
33. Takano Y, Homma T, Okumura H, Takahashi HE : Ganglion cyst occurring in the ligamentum flavum of the cervical spine. A case report. **Spine (Phila Pa 1976) 17** : 1531-1533, 1992
34. Vasani SS, Demetriades AK, Joshi SM, Yeh J, Ellamushi H : Traumatic intraspinal extradural ganglion cyst in a teenager : case report and review of the literature. **Clin Neurol Neurosurg 109** : 88-91, 2007
35. Yamamoto A, Nishiura I, Handa H, Kondo A : Ganglion cyst in the ligamentum flavum of the cervical spine causing myelopathy : report of two cases. **Surg Neurol 56** : 390-395, 2001