Primary mucinous cystadenocarcinoma of the pelvic retroperitoneum in a male

Andrew K. Williams, MD;[*] Shawna L. Boyle, MD;[†] Susanne M. Chan, MD;[§] Carlos H Martinez, MD;[*] Chen Lu, MD;[*] Joseph L. Chin, MD, FRCSC[*]

Abstract

Primary mucinous cystadenocarcinoma of the retroperitoneum is an extremely rare malignancy with only 2 male patients reported in the literature. We describe an unusual case presenting as a pelvic mass in a male with previous pan-proctocolectomy and end ileostomy for Crohn's disease and review the available literature.

Can Urol Assoc J 2010;4(6):E169-E171

Case report

A 51-year-old man was refered by his family practitioner to the urology outpatient department with a 2-month history of lower abdominal discomfort, difficulty voiding and a feeling of lower abdominal fullness progressing to severe pelvic pain and urinary retention. The patient also complained of nausea, anorexia and weight loss over the preceding 3 months; there was no history of fever, chills or sweats. The family practitioner organized an abdominal ultrasound which showed a 10-cm pelvic mass. Previous history was significant for Crohn's disease resulting in a pan-proctocolectomy and end ileostomy of which no operative note was available. He had no active Crohn's disease, and was on no regular medications. There was no history of hematuria and no history of blood from his ileostomy. On examination the patient was emaciated and in distress. Abdominal examination was consistent with a large pelvic mass extending above the pubic symphysis. Rectal examination was not possible due to previous surgical anal closure, but the perineum and natal cleft appeared unremarkable.

A computed tomography (CT) scan (Fig. 1) demonstrated a 14-cm heterogenous cystic pelvic mass, without evidence of nodal or metastatic disease. The radiological differential at the time included teratoma, soft tissue tumour or abscess. Subsequent aspiration of the mass revealed amorphous debris with no nuclei visible and no evidence of hemorrhage. CA 125, beta-human chorionic gonadotrophin (bHCG), urea and electrolytes, liver function test's and calcium were normal. However CA19-9 and carcinoembryonic antigen (CEA), both markers commonly elevated in intestinal or foregut malignancy, were non-specifically elevated at 458 units/mL and 7.3 mcg/mL, respectively.

Based on the significant pain the patient was having and the uncertainty of the diagnosis, it was decided to undergo laparotomy and to attempt surgical resection of this mass. Intraoperatively, the mass was noted to be lying posterior and separate to the bladder but adherent to the sacrum and pelvic autonomic nervous plexus posteriorly and seminal vesicles anteriorly rendering complete excision impossible. Posteriorly, due to a combination of previous surgery and tumour extension, the lesion was unable to be removed in its entirety and therefore a debulking procedure was performed with excision of the seminal vesicles and vasa deferentia. Gross tumour was evident posteriorly at the completion of the procedure and some spillage of gelatinous, mucinous material occurred within the pelvis.

Histology revealed a mucinous cystadenocarcinoma of non-prostatic origin (Fig 2). The tumour stained positively for CK7, CK20 and CDX2 and was negative for prostate-specific antigen and prostatic acid phosphatase consistent with a mucinous cystadenocarcinoma of non-prostatic origin. Seminal vesicles and vasa deferentia were histologically unremarkable without any invasion. CA 19-9 and CEA levels dropped following the procedure, but were still elevated at 49 and 4.4, respectively 1 month following surgery. Adjuvant chemotherapy was offered to this patient. However, this was declined by the patient given the uncertain therapeutic benefit and the absence of any symptoms postoperatively.

Eighteen months following the initial surgical resection, the patient began experiencing further pain and follow-up CT scan showed recurrence of the lesion (Fig. 3). Once again there was no evidence of metastatic disease. Further surgical debulking was performed with radical prostatectomy as the tumour now was adherent to and appeared to involve the prostate gland. Pelvic lymph node dissection and temporary suprapubic cystotomy were also performed. The same histological and immunohistological features were noted on pathological analysis with no evidence of prostatic malig-

© 2010 Canadian Urological Association

10015.indd 169 11/26/10 12:14 PM

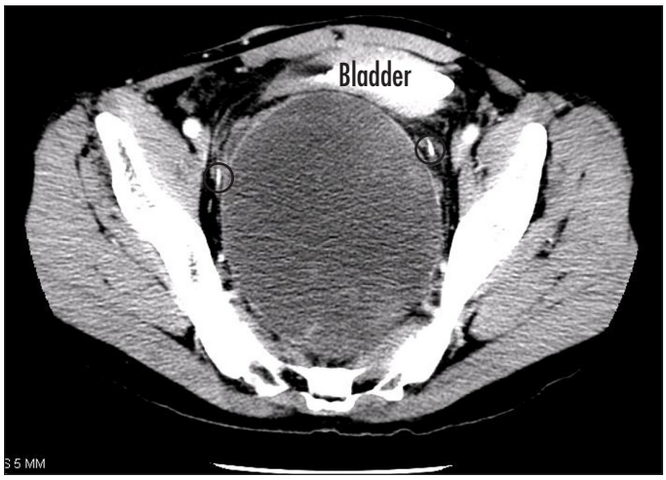

Fig. 1. A computed tomography demonstrating a large cystic pelvic mass with mixed attenuation. The relationship of the mass to the ureters (circled) and bladder is shown.

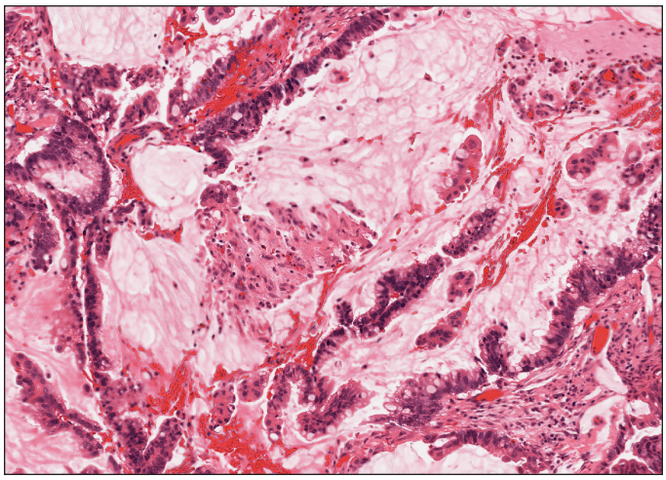

Fig. 2. Histological section at 150× magnification demonstrating adenocarcinoma with mucinous debris.

nancy or nodal disease. Symptomatic relief was attained and the patient remains symptom-free with no evidence of distant disease 2½ years following his initial presentation.

Discussion

Mucinous cystadenocarcinoma is a malignancy rarely encountered in urological practice. Reported primary sources for this malignancy include ovary, bowel and pancreas,[1-3] but may also include bladder and urachal remnants.[4] The retroperitoneum is an extremely rare location for this cancer to develop, with Thamboo and colleagues[5] and Green and colleagues[6] having reported the only other 2 cases of retroperitoneal mucinous cystadenocarcinoma in a male.

Previously authors have suggested that this malignancy is a result of ectopic ovarian tissue or ovarian teratoma undergoing malignant transformation.[7] This however does not explain the presence of this malignancy within male patients with phenotypically normal gonads. Subramony and colleagues[8] suggested that the presence of peritoneal inclusion cysts can result in mesothelial cells undergoing mucinous metaplasia and subsequently progressing to mucinous cystadenocarcinoma. This would explain the immunohistological and tumour markers being more consistent with an enteric origin for the malignancy. The absence of this patient's colon also is of interest as it provides us with an anatomical reason for the presence of a peritoneal inclusion. It is easily conceivable in our case that this mesothelial inclusion could have been created with closure of the peritoneum following the patient's proctocolectomy years before.

A recent case report by Zwaveling and colleagues[9] documented the development of a mucinous cystadenoma within the mesentery of the right hemi colon. They were unsure as to the etiology of this lesion. However, this demonstrates a "halfway" point in the transformation from benign mesothelial cells to malignant mucinous cystadenocarcinoma. At this stage, however, tumours with retroperitoneal mixed mucinous cystadenoma and cystadenocarcinoma have not been reported in the literature.

Another possible, but less likely etiology of retroperitoneal mucinous cystadenocarcinoma, would be the presence of a small amount of duplicated colonic tissue.[10] Extensive work in animal models of gastrointestinal duplication has shown a very close relationship of this duplication with the presence of notochordal and spinal abnormalities, such as spina bifida and split notochord syndrome.[11] The absence of spinal or neurological abnormalities in this patient makes this unlikely.

From a clinical point of view, this patient demonstrates that these cancers can cause significant pain due to local extension or compression into neural structures. Our patient derived significant clinical benefit on both occasions from debulking of this lesion and is still alive and pain free 2½

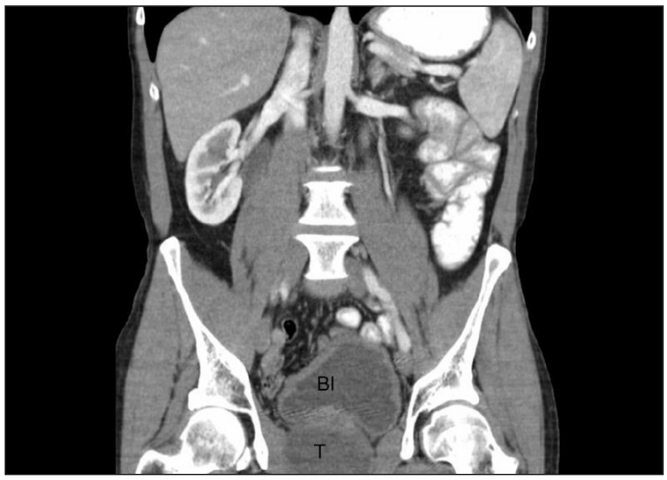

Fig. 3. A coronal computed tomography scan showing recurrence of the tumour (T) inferior to the bladder (Bl).

10015.indd 170 11/26/10 12:14 PM

years after the initial diagnosis of his tumour. He has also not yet shown any evidence of nodal or metastatic disease. This is in contrast to the aggressive behaviour demonstrated in other reports.[7] We advocate that thorough surgical debulking, when feasible, should be considered for symptomatic relief.

[*]Department of Urology, University of Western Ontario, London, ON; [†]Department of Oncology, University of Western Ontario, London, ON; [§]Department of Pathology, University of Western Ontario, London, ON

Competing interests: None declared.

This paper has been peer-reviewed.

Correspondence Dr. Joseph L. Chin, Department of Urology, London Health Sciences Centre, 800 Commissioners Rd., London, ON N6A AG5; joseph.chin@lhsc.on.ca

References

1. Cho KR. Ovarian cancer update: lessons from morphology, molecules, and mice. *Arch Pathol Lab Med* 2009;133:1775-81.
2. Hayashi T, Ishiwatari H, Yoshida M, et al. Mucinous cystic adenoma of the pancreas with short-term morphological changes due to hemorrhage [in Japanese]. *Nippon Shokakibyo Gakkai Zasshi* 2009;106:1783-91.
3. Salemis NS, Gourgiotis S, Pinialidis D, et al. Primary mucinous cystadenocarcinoma of the appendix: an unusual presentation of a rare tumor. *J Dig Dis* 2008;9:175-7.
4. Gore DM, Bloch S, Waller W, et al. Peritoneal mucinous cystadenocarcinoma of probable urachal origin: a challenging diagnosis. *J Clin Pathol* 2006;59:1091-3.
5. Thamboo TP, Sim R, Tan SY, et al. Primary retroperitoneal mucinous cystadenocarcinoma in a male patient. *J Clin Pathol* 2006;59:655-7.
6. Green JM, Bruner BC, Tang WW, et al. Retroperitoneal mucinous cystadenocarcinoma in a man: case report and review of the literature. *Urol Oncol* 2007;25:53-5.
7. Gotoh K, Konaga E, Arata A, et al. A case of primary retroperitoneal mucinous cystadenocarcinoma. *Acta Med.Okayama* 1992;46:49-52.
8. Subramony C, Habibpour S, Hashimoto LA. Retroperitoneal mucinous cystadenoma. *Arch Pathol Lab Med* 2001;125:691-4.
9. Zwaveling S, den Outer AJ, da Costa SA. A mucinous cystadenoma in the mesentery of the right hemicolon. *Acta Chir Belg* 2008;108:354-5.
10. Herman TE, Siegel MJ. Colorectal tubular enteric duplication. *J Perinatol* 2009;29:774-6.
11. Emura T, Hashizume K, Asashima M. Experimental study of the embryogenesis of gastrointestinal duplication and enteric cyst. *Pediatr Surg Int* 2003;19:147-51.

10015.indd 171 11/26/10 12:14 PM