

Short Article

The Use of Mercury against Pediculosis in the Renaissance: The Case of Ferdinand II of Aragon, King of Naples, 1467–96

GINO FORNACIARI, SILVIA MARINOZZI, VALENTINA GAZZANIGA,
VALENTINA GIUFFRA, MALAYKA SAMANTHA PICCHI,
MARIO GIUSIANI, and MASSIMO MASETTI*

Abstract: The hair samples of Ferdinand II of Aragon (1467–1496), King of Naples, whose mummy is preserved in the Basilica of San Domenico Maggiore in Naples, showed a high content of mercury, with a value of 827ppm. Furthermore, examination using a stereomicroscope and a scanning electron microscope (SEM) of head and pubic hairs of Ferdinand II, revealed a lice infestation. The reasons for the massive presence of the mercury in the king's hair are discussed and contemporary literature regarding the use of this metal in medical therapies and in cosmetic practices is analysed. As a result, the high value of mercury in the hair of Ferdinand II can be attributed to antipediculosis therapy, applied as a topic medicament. This case represents an important finding for the history of medicine, because demonstrates that in the Renaissance mercury was applied locally not only to treat syphilis, as well attested by direct and indirect sources, but also to prevent or eliminate lice infestation.

Keywords: Mercurial Therapy; Lice; Naples; Renaissance; Ferdinand II of Aragon

© Gino Fornaciari, Silvia Marinozzi, Valentina Gazzaniga, Valentina Giuffra, Malayka Samantha Picchi, Mario Giusiani, Massimo Masetti, 2011.

*Professor Gino Fornaciari and Dr Valentina Giuffra, Department of Oncology, Transplants and Advanced Technologies in Medicine, Division of Palaeopathology, History of Medicine and Bioethics, University of Pisa, Italy; Dr Silvia Marinozzi and Professor Valentina Gazzaniga, Department of Experimental Medicine, Section of History of Medicine, University of Rome 'La Sapienza', Italy; Dr Malayka Samantha Picchi and

Dr Massimo Masetti, Department of Biology, Laboratory of Entomology, University of Pisa; Professor Mario Giusiani, Department of Neuroscience, Section of Forensic Medicine, University of Pisa.

Primary address for correspondence: Professor Gino Fornaciari, Divisione di Paleopatologia, Storia della Medicina e Bioetica, Dipartimento di Oncologia, dei Trapianti e delle Nuove Tecnologie in Medicina, Università di Pisa, via Roma 57, 56126 Pisa, Italy.
Email: g.fornaciari@med.unipi.it

Introduction

The Basilica of San Domenico Maggiore, dating back to the beginning of the fourteenth century, is one of the largest and most important churches in Naples. An overhanging chamber overlooking the monumental sacristy houses a total of thirty-eight wooden sarcophagi containing the artificial or natural mummies of ten Aragonese princes and other Neapolitan noblemen, who died between the fifteenth and sixteenth centuries.¹

Ferdinand II (1467–96, Figure 1) also known as ‘Ferrandino’, ‘little Ferdinand’, was the eldest son of Alfonso II of Naples and Ippolita Maria Sforza of Calabria. In 1494, his father placed him at the head of an army against Charles VIII, King of France, but he was defeated in 1495. In the same year he ascended the throne and, after a military campaign which led to the victory against the French, he re-conquered almost all the kingdom of Naples. He then married his aunt, Giovanna of Aragon, half-sister of his father Alfonso and daughter of Ferdinand I and his second wife Giovanna of Aragon. He died of malignant tertian malaria on 7 October 1496, only a few months after his marriage.²

The mummy of Ferdinand II was badly preserved in part. The soft tissues were present at the level of the trunk, whereas the head and limbs were completely skeletonised. Strands of hair and pubic hairs still present on the mummy were sampled and then submitted to a specific procedure aimed at checking the concentration of mercury. Heavy metals, in general, and mercury in particular, tend to accumulate in the hair system and therefore the presence of these elements in the hair of the king could prove exposure to this metal. Two different techniques were used: Atomic Absorption Spectroscopy (AAS)³ and, at a later stage, Flame Emission Spectrophotometry (FES) using the hydride method to determine the exact concentration of mercury in any samples that had previously given positive results.⁴ Both types of hair were then carefully examined by means of a stereomicroscope to detect the presence of parasites.

¹ Gino Fornaciari, ‘The Mummies of the Abbey of Saint Domenico Maggiore in Naples: A Preliminary Report’, *Archivio per l’Antropologia e la Etnologia*, 115 (1985), 215–26; Gino Fornaciari, ‘The Mummies of the Abbey of Saint Domenico Maggiore in Naples: A Preliminary Survey’, in *Proceedings of the V European Meeting of the Paleopathology Association, Siena, September 1984* (Siena: University of Siena, 1986), 97–104; Gino Fornaciari, ‘Italian mummies’, in Thomas Aidan Cockburn, Eve Cockburn, Theodore A. Reyman (eds), *Mummies, Disease and Ancient Cultures* (Cambridge: Cambridge University Press, 1998), 271–80; Gino Fornaciari, ‘Renaissance Mummies in Italy’, *Medicina nei Secoli*, 11 (1999), 85–105; Gino Fornaciari, ‘Le mummie aragonesi in San Domenico Maggiore di Napoli’, *Medicina nei Secoli*, 18 (2007), 875–96; Gino Fornaciari and A. Amadei, ‘Anthropologie et paléodémographie d’une classe socialement élevée de la Renaissance italienne: la série de momies de S. Domenico Maggiore à

Naples (XVe–XVIe siècles)’, *Journal of Paleopathology Monographic Publications*, 1 (1989), 47–52.

² G. Brunelli, ‘Ferdinando II (Ferrandino) d’Aragona, re di Napoli’, in *Dizionario biografico degli italiani*, Vol. 46 (Rome: Istituto della Enciclopedia Italiana, 1996), 189–94.

³ Barbara J. Keller, Mark E. Peden and Anthony Rattonetti, ‘Graphites-Furnace Atomic Absorption Method for Trace-level Determination of Total Mercury’, *Analytical Chemistry*, 56 (1984), 2617–18.

⁴ W.M. Blakemore and S.M. Billedeau, ‘Analysis of Laboratory Animal Feed for Toxic and Essential Elements by Atomic Absorption and Inductively Coupled Argon Plasma Emission Spectrometry’, *Journal of the Association of Analytical Chemists*, 64 (1981), 284–90; G.O. Korsrud et al., ‘Trace Element Levels in Liver and Kidney from Cattle, Swine and Poultry Slaughtered in Canada’, *Canadian Journal of Comparative Medicine*, 49 (1985), 159–63.



Figure 1: The 'Knight with the Ermine', probable portrait of Ferdinand II of Aragon, King of Naples (1467–96), by Vittore Carpaccio (Lugan, Thyssen Collection).

Findings

Investigation gave a positive result for mercury in the hair, which was 827ppm. The presence of mercury also in the liquid used to wash the hair confirms the likelihood of external application of the metal. Further toxicological analyses were carried out to verify the eventual presence of mercury even on the skin, on the spongy material that filled the body cavities and on the pubic hairs; the results showed very low values, of 18ppm,

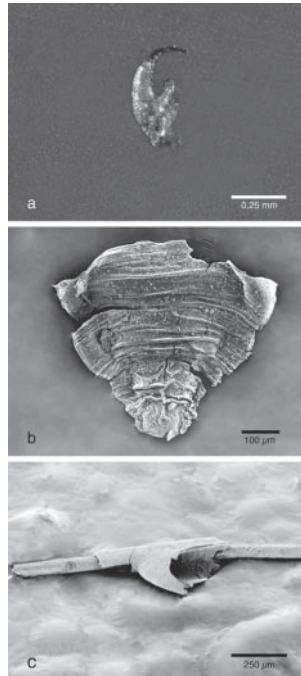


Figure 2: (a) Leg claw of a head louse at stereomicroscope; (b) terminal part of the abdomen of a male head louse at Scanning Electron Microscope (SEM); (c) incomplete nit of pubic louse attached to a hair at SEM.

7ppm and 10ppm respectively. The careful macroscopic and radiological examination showed no traces of mercury in the cranial or body cavities of Ferdinand's mummy.

Examination of Ferdinand's hair samples with a stereomicroscope revealed the presence of the terminal part of the adult leg of a head louse (Figure 2a), the terminal part of two adult abdomens, belonging to male lice (Figure 2b), seven incomplete nits attached to a hair, and another five nit fragments, not cemented to a hair. Similar tests performed on the pubic hairs revealed the presence of two hairs each bearing the fragment of a louse nit (Figure 2c). Morphologically, it is not possible to distinguish nits observed on head hairs from those on pubic hairs.

Three species of lice infest humans: *Pediculus capitis*, or head louse, *Pediculus humanus*, the louse found on clothes or on the body, and *Phthirus pubis*, the pubic or crab louse.⁵ All three species belong to the order of the Anoplura, the Pediculidae family, and are distributed worldwide.⁶ The three species are responsible for pediculosis, the

⁵ Mike W. Service, *Medical entomology for Students* (Cambridge: Cambridge University Press, 2000).

⁶ They are wingless and dorsoventrally flattened insects with short antennae and poorly developed eyes. The three strong pairs of legs terminate with a

spine and a claw that allow anchoring to the hairs or clothing of the host. The head louse and the body louse measure about 3mm in length and are morphologically so similar to each other, that still today some authors consider them as subspecies of *P. humanus*, while others prefer to see them as two

most common symptom of which is intense itching. There is no evidence that *P. capitis* and *P. pubis* are vectors of important diseases, whereas *P. humanus* is a natural vector of trench fever, louse-borne epidemic typhus and relapsing fever.⁷

On the basis of the morphology and distribution of insect fragments associated with Ferdinand's remains, it is possible to infer that the king was affected by a double infestation of lice belonging to the species of *P. capitis* and *P. pubis*. This case is of particular interest because, although archaeological findings show that pediculosis has afflicted humans since the most ancient times and that lice were distributed worldwide,⁸ this is the first time these parasites have been found in the hair of a king, demonstrating that even the wealthy social classes were subjected to lice infestation.

Use of Mercury in Mediaeval and Renaissance Medicine

Fundamental to earlier interpretation of the nature of the louse is the biological thinking of Aristotle, who claimed that some animals could be generated spontaneously from putrid or rotten matter in other animals.⁹ Lice, for example, develop and reproduce through an excess of humidity in the brain, which is wet by nature. Galen of Pergamum (129–c.216) identified the subcutaneous region as the place of development of lice, which generate through the extreme heat produced by warm excess humidity, and suggested that desiccant drugs, including nitre and alum, could counteract the excess of wet and hot vapours.¹⁰ Oribasius (325–403) advocated a topical application of nitre, stavesacre, sandarac and cedar in salt water and/or vinegar, because desiccant and evacua-tive drugs are necessary to destroy the lice that develop from an excess of humours and insufficiency of heat.¹¹

This Galenic theory, which explained both the spontaneous generation of lice and the development of dandruff and other skin complaints, formed the basis for the treatment of pediculosis and similar conditions from Antiquity onwards. On the one hand, various procedures were recommended to the patient, such as an appropriate diet, bathing, change of clothing and phlebotomy to eliminate excessive moisture and hot vapours from the body. On the other, topical drugs and ointments were to be applied externally. Although individual elements in the prescription might change—some preferring rose oil, liquid pitch, egg white, wormwood, orpiment, pyrethrum or soap among the ingre-

separate species (N.P. Leo *et al.*, 'The Head and Body Lice of Humans are Genetically Distinct (Insecta: Phthiraptera, Pediculidae): Evidence from double infestations', *Heredity*, 95 (2005), 34–40). Habitat differentiation probably arose when man adopted the use of clothing (R. Kittler, M. Kayser and M. Stoneking, 'Molecular Evolution of *Pediculus humanus* and the Origin of Clothing', *Current Biology*, 13 (2003), 1414–17). The pubic louse is about 2mm in length and is called crab louse for its big claws on the second and third pairs of legs and compacted thorax and abdomen.

⁷C.J. Ko and D.M. Elston, 'Pediculosis', *Journal of the American Academy of Dermatology*, 50, 1 (2004), 1–12; E. Orion *et al.*, 'Itch and Scratch:

Scabies and Pediculosis', *Clinical Dermatology*, 24 (2006), 168–75.

⁸See bibliography in Kosta Y. Mumcuoglu, 'Human Lice: *Pediculus* and *Pthirus*' in Didier Raoul, *Paleomicrobiology: Past Human Infections* (New York: Springer, 2008), 215–22.

⁹Cf. Aristotle, *De historia animalium*, lib. I, 5, 489a.

¹⁰Galen, *De compositione medicamentorum*, lib. I, cap. VII.

¹¹*Oeuvres d'Oribase; texte grec... traduit... par le docteurs Bussemaker et Daremberg*, Paris, Imprimerie Nationale, 1851–1876, V, lib. 4, 703–4; 6, lib. IV, ch. IX, 535–6.

dients—the use of mercury remains constant throughout the Middle Ages into the sixteenth century.¹²

Texts contemporary with Ferdinand show clearly that mercury was also frequently employed in cosmetic recipes: quicksilver and sublimate were included in the composition of products used to whiten the skin, or to remove erythema, blotches and freckles from the face, and to treat putrid ulcers and sores, warts, pocks, etc.¹³ Like cinnabar, it was included among darkening substances called ‘browning’,¹⁴ but its use as a hair dye is unlikely, as Ferdinand was only twenty-nine years old when he died and probably had no white hair to mask.

Another possible use of mercury at this period is as an antiputrefactive balm that, although not attested in the literature, is evidenced by palaeopathological findings. The mummies of Antonio of Aragon (1540–84), third Duke of Montalto, and that of the son of Antonio Carafa, a child of six months who died in 1607 and who was buried with other members of the dynasty in the Basilica of San Domenico Maggiore in Naples, bear direct witness to the use of mercury for embalming at the Aragonese court. The metal was used in such high quantities that during the unwrapping operations and the autopsy performed by Professor Gino Fornaciari, little drops of metallic mercury poured out of the body cavities of these two mummies. Under radiological examination mercury was visible as little rounded formations of radio-opaque density.¹⁵

¹² Rose oil: Abu Bakr Mohammad Ibn Zakariya al-Razi, *Continens Rasis* (Venice: Otaviano Scoto, 1529), lib. XXV, cap. 17, 521–2; Avicenna, *Avicennae arabum medico rum principis, ex Gerardo Cremonensis versione...* (Venice: Apud Iuntas, 1608), tomus I, lib. II, tract. 2, 267, cf. tomus II, lib. IV, cap. 27, p. 256; liquid pitch, Trotula, *De ornatu mulierum*, in Salvatore de Renzi, *Collectio Salernitana* (Naples: Tipografia del Filiatre-Sebezio, 1856), tome IV, lib. 2, 30–1; egg white, Henry de Mondeville, *Chirurgie de Maître Henry de Mondeville composée de 1306 à 1320* (Paris: Ancienne Librairie Germer Baillièrre et F Alcen Editeur, 1893), Traite III, ch. XIV, 596–7, cf. also Traite III, ch. XX, 634–6; wormwood, Arnaldo da Villanova, *Arnaldi de Villanova medici acutissimi opera nuperrime revisa...* (Lyons: apud Scipione de Gabiano, 1532), *De simplicibus*, cap. 48, fo. 237v., cf. also, 268r; orpiment, Pietro d’Argellata, *Cirurgia Magistri Petri de Largelata*, (Venice, 1499), 87–8, also Ambroise Paré, *Les oeuvres d’Ambroise Paré* (Paris: Gabriel Buon, 1585), VII.CL; pyrethrum, Giovanni Marinello, *Gli ornamenti delle donne* (Venice: Giovanni Valgriso, 1574), 90; soap, Giovanni Battista da Vigo, *La prattica universale in cirugia* (Venice: Bertani, 1639), 187. Similar remedies involving mercury are given by Johannes Serapion, *Practica. Index operum in hoc volumine contentorum, practica Joannis Serapionis aliter brevarium nuncupata, liber Serapionis de simplicium medicinalium...* [Lugduni, per Jacobum Myt] 1525, tract. I, cap. V., fol. IVr; Bernard de Gordon, *Cy*

commence la pratique de... Bernard de Gordon qui s’appelle fleur de lys en médecine (Lyons, 1495), lib. II, cap. VIII–IX; Guy de Chauliac, *La grande chirurgie de Guy de Chauliac... composée en l’an 1363* (Paris, Alcan, 1890), Traite VI, doct. I, cap. 3, 421–2; Gabriele Falloppio, *La chirurgia di Gabriele Falloppio Modenese* (Venice: Stefano Curti, 1655), 435–6; and Giovanni Battista Zapata, *Li maravigliosi secreti di medicina e chirurgia* (Venice: Santo Lanza, 1629), 125ff.

¹³ Avicenna, *op. cit.* (note 12), tomus II, Lib. IV, tract. 2, 243, 248; Abu Bakr Mohammad Ibn Zakariya al-Razi, *op. cit.*, (note 12), lib. XXV, cap. 12, 517v; Villanova, *op. cit.* (note 12), 269; Mondeville, *op. cit.* (note 12), Traite III, chap. XIV, 612; Gordon, *op. cit.* (note 12), li. VII, ch. XXV; Battista da Vigo, *op. cit.* (note 12), 196–7; G. Falloppio, *Secreti diversi e miracolosi...*, (Venice: Alessandro Gardano, 1578), 31–6, 53, 74–5, 109–10, 173–4; Leonardo Fioravanti, *I capricci medicinali* (Venice: Comino Gallina, 1567), 155v–151; Leonardo Fioravanti, *Il tesoro della vita humana* (Venice: Per il Spineda, 1629), 23, 28, 29–30, 36v, 43, and 283v; Zapata, *op. cit.* (note 12), 116–29; Girolamo Ruscelli, *De’ secreti del reverendo donno Alessio Piemontese...* (Pesaro: Bartolomeo Cesano, 1559), 4–10, 15–16, 37, 40, 120 and 121.

¹⁴ Pietro d’Argellata, *op. cit.* (note 12), 85; Falloppio, *op. cit.* (note 12), 321–2.

¹⁵ S. Marinozzi and G. Fornaciari, ‘Le mummie e l’arte medica nell’evo moderno’, *Medicina nei Secoli*, suppl. 1 (2005), 275–9, 282–5.

The Use of Mercury against Pediculosis in the Renaissance

However, no traces of mercury were found in the cranial or body cavities of Ferdinand's mummy, as revealed by macroscopic and radiological examination. These findings are confirmed by the toxicological analysis, which revealed very low values of mercury in the skin samples and in the sponge used as filling material in the body cavities. These results demonstrate that the high quantities of metal detected in the hair are not to be referred to the embalming method.

Mercury is also known to have been used since the end of the fifteenth century for antisyphilitic therapy, the treatment of ulcers and luetic swellings, in ointments to smear the body or in fumigations mostly based on cinnabar. However, the concentration of mercury found in the king's hair is much too high for it to be ascribed to antiluetic treatments, and suggests rather a topical usage instead.¹⁶

Conclusion

The massive presence of mercury in the hair of Ferdinand II cannot be explained by the use of quicksilver for artificial embalming of the corpse, considering that no trace of the metal was found in the mummy except in the hair. The possibility that cinnabar was employed for aesthetic purposes in hair dyes and waters for darkening the hair seems improbable, considering the young age of the king. Moreover, the indications for the treatment of other pathologies, such as *tinea* and *scabies*, prescribe a topical use of mercurial remedies on the cutaneous lesion alone, whereas traces of mercury have been found in all the hair analysed. It thus seems more reasonable to attribute the high value of mercury to the employment of solutions and ointments against lice. This hypothesis is supported by the remains of lice in Ferdinand's hair, and is confirmed by the numerous medical prescriptions related to anti-pediculosis therapy provided by mediaeval and early modern authors. The low value of mercury in the pubic hairs, which showed lice infestation as well as the head, demonstrate that this region received no anti-pediculosis treatment. These results seem to be confirmed by the literary sources, which do not mention the application of local dermatological therapies to the pubis.

This is an interesting case from an historical point of view, because it is the first time a direct attestation of topical mercury treatment to prevent or eliminate lice infestation has been found in an ancient body.

Acknowledgement

We wish to thank Simone Gabrielli at the Department of Biology, University of Pisa, Italy, for his technical assistance.

¹⁶ Gérard Tilles and Daniel Wallach, 'Histoire du traitement de la syphilis par le mercure: 5 siècles d'incertitudes et de toxicité', *Revue d'Histoire de la Pharmacie (Paris)*, 44, 312 (1996), 347–51.