Immunoglobulin in Clinically Uninvolved Skin in Systemic Lupus Erythematosus

ASSOCIATION WITH RENAL DISEASE

JAMES N. GILLIAM, DON E. CHEATUM, ERIC R. HURD, PETER STASTNY, and MORRIS ZIFF

From the Department of Internal Medicine, The University of Texas Southwestern Medical School, Dallas, Texas 75235, and the Dallas Veterans Administration Hospital, Dallas, Texas 75216

ABSTRACT 23 of 42, or 55%, of patients with systemic lupus erythematous had immunoglobulin deposits along the epidermal basement membrane of uninvolved skin (positive lupus band test [LBT]). In patients with low serum complement levels, 91% had a positive LBT), as compared with 15% in those with normal complement levels. The LBT was positive in 70% of patients with clinical and laboratory evidence of renal disease, but in only 31% of patients without renal disease. 81% of patients with the more severe histologic forms of lupus nephritis, i.e., proliferative glomerulonephritis and membranous glomerulonephritis, had positive tests, whereas only 23% with mesangial glomerulitis or normal histologic findings were positive. Immunoglobulins of the same class found in the skin were detected in the glomeruli of patients examined by renal biopsy. These results suggest that there is a relationship between the occurrence of immunoglobulin in the epidermal basement membrane and the presence of the more severe forms of lupus nephritis.

INTRODUCTION

Patients with systemic lupus erythematosus (SLE)[1] may have immunoglobulins (IgG, IgA, and IgM) and complement at the dermal-epidermal junction of clinically uninvolved skin (1–6). Although there is general agreement that this finding by the direct immunofluorescence technique is of value in establishing the diagnosis of SLE, its association with other stigmata of the disease, especially renal involvement, is not settled (5–9). In 1968, Pohle and Tuffanelli (5) suggested a possible relationship between renal involvement and the presence of immunoglobulin in normal-appearing skin of SLE patients. Subsequently, Burnham and Fine (7) substantiated this relationship by reporting a correlation between immunoglobulin deposition in the skin and the presence of renal involvement. They found kidney involvement three times more frequently in lupus band test (LBT)-positive patients than in LBT-negative patients; however, their study did not include histologic classification of the renal lesions. In contrast, Caperton, Bean, and Dick (8) observed no relationship between the LBT and the presence of renal disease in patients followed over a 1-yr period. On the basis of renal biopsies from 12 patients, they also concluded that there was no relationship between the renal pathology and the result of the LBT. This investigation, however, included only a small number of LBT-negative patients. Moreover, these investigators biopsied light-exposed skin, whereas Burnham and Fine examined skin from light-protected sites, which have a lower incidence of LBT-positivity (9).

The present report presents the results of a prospective study designed to determine whether immunoglobu-

This work was presented in part at the 37th Annual Meeting of the American Rheumatism Association, Los Angeles, Calif., June 1973 (1973. *Arthritis Rheum.* **16**: 545).

Received for publication 2 October 1973 and in revised form 3 January 1974.

[1] *Abbreviations used in this paper:* ANA, antinuclear antibody; $C'H_{50}$, total hemolytic complement; CNS, central nervous system; EBM, epidermal basement membrane; GBM, glomerular basement membrane; LBT, lupus band test; Memb GN, membranous glomerulonephritis; Mes G, mesangial glomerulitis; nDNA, native DNA; PBS, phosphate-buffered saline; PGN, proliferative glomerulonephritis; SLE, systemic lupus erythematosus.

lin deposition in the normal-appearing skin of SLE patients is associated with the presence or subsequent development of significant renal disease. The findings in the skin have been related to clinical and laboratory parameters of renal disease and to the histologic and immunofluorescent findings on renal biopsy.

METHODS

Patients and controls. 3-mm punch biopsies of normal-appearing skin from the medical aspect of the volar forearm were obtained from 40 women and 2 men. Each patient had a minimum of 4 of the 14 preliminary American Rheumatism Association criteria for the classification of SLE (10). 30 were black, 8 white, and 4 Mexican-American. The average age was 35 yr (range 15–64). Patients followed for less than 6 mo from the time of biopsy were not included unless death related to SLE supervened. Patients receiving immunosuppressive drugs before the initial biopsy were excluded from the study. All patients were seen at 1- to 2-mo intervals and examined closely for clinical and laboratory evidence of renal involvement.

As controls, normal skin was obtained from 5 healthy volunteers, 5 fresh cadavers, and 65 patients with a variety of diseases. These included: rheumatoid arthritis (10), dermatomyositis (4), scleroderma (4), secondary syphilis (4), Australia antigen-positive hepatitis (8), chronic glomerulonephritis (5), drug-induced lupus erythematosus (4), discoid lupus erythematosus (10), lupoid hepatitis (2), primary biliary cirrhosis (2), and miscellaneous skin diseases (12). Examination of hematoxylin-eosin-stained sections of the skin biopsy material by routine light microscopy showed no cellular infiltrate or evidence of tissue damage.

Criteria for renal disease. Active renal disease was considered present on the basis of: microscopic hematuria (more than five red blood cells/high power field [HPF]) and/or cylindruria (presence of granular, cellular, or red cell casts) on two or more occasions; 24-h protein excretion over 500 mg; increased level of serum creatinine and blood urea nitrogen; and creatinine clearance below 80 ml/min. A reduced creatinine clearance, plus one or more of the other abnormalities, was required for a diagnosis of significant renal involvement.

Renal biopsy was carried out on all patients with clinical evidence of active renal involvement as determined by the above criteria. 29 patients received renal biopsy. The biopsies were classified according to light microscopic findings into the following categories: proliferative glomerulonephritis (PGN), membranous glomerulonephritis (Memb GN), mesangial glomerulitis (Mes G), or normal. The criteria used for each of these classifications were: (*a*) PGN—proliferative lesions involving both endothelial and mesangial cells accompanied by cellular necrosis, fibrinoid change, wire loops, or hematoxylin bodies; closure of the capillary loops and distortion of the mesangial areas. (*b*) Memb GN—widespread thickening of the glomerular basement membrane (GBM) without cellular proliferation. (*c*) Mes G—definite mesangial sclerosis and/or hypercellularity involving either all glomeruli or only a fraction of the glomeruli in either a local or a diffuse manner in each glomerulus; usually, an increase in the mesangial matrix accompanied by an increased number of mesangial cells. (*d*) Normal—glomeruli free of lesions.

Parameters of disease activity. The following studies were carried out at the time of the skin biopsy: complete blood count, erythrocyte sedimentation rate, total hemolytic complement ($C'H_{50}$), antinuclear antibody (ANA) test using rat kidney sections as substrate (positive titer, 1/16), and the renal function studies. These tests were repeated at 2–3-mo intervals. Antibodies to native DNA (nDNA) were measured coincident with the LBT in 10 patients by using the method of Ginsberg and Keiser (11). $C'H_{50}$ was measured by microtitration, according to the technique of Nelson, Jenson, Gigli, and Tamura (12).

Processing of skin biopsies. The skin biopsy specimens were placed in 1 × 2-inch cylindrical plastic containers (Olympic Plastic Co., Los Angeles, Calif.), immersed in Tissue-Tek (Ames Co., Elkhart, Ind.), and immediately frozen in liquid nitrogen. The tissue was then stored at −70°C until processing. 4-μm cryostat sections were allowed to air-dry for 15 min and then were washed in 0.01 M phosphate-buffered saline (PBS), pH 7.2. Sectioning and staining were always done within 2–3 days after biopsy and repeated on one or more occasions if positive. Consistent morphologic and immunofluorescent findings could be observed after as long as 21 mo of storage at 70°C. However, when tissue was thawed and refrozen, the intensity of the fluorescence diminished.

Immunofluorescence tests. Washed tissue sections were incubated for 30 min at room temperature in a moist chamber with fluorescein-conjugated goat antihuman IgG, IgM, IgA, and C3. The excess antiserum was removed and the slides were washed for 30 min with three changes of PBS. A cover slip was then mounted with 90% glycerol in PBS. All skin biopsy material was examined by the same observer (J. G.) using an Ortholux fluorescence microscope equipped for epi-illumination (E. Leitz, Inc., Rockleigh, N. J.) (12). An HBO 100 ultrahigh pressure mercury lamp (E. Leitz, Inc.) and K490 and K510 filters were used. Photomicrographs were taken with a Leitz Orthomat camera on highspeed Ektachrome (Eastman Kodak Co., Rochester, N. Y.). Sections of skin from normal individuals and from patients with known positive LBT were routinely employed as controls. Blocking experiments were carried out in the initial phases of the study by preincubating the tissue with nonfluoresceinated specific antisera followed by incubation with the corresponding labeled antiserum to check the specificity of the staining. Unfixed tissue from 12 renal biopsies was available. This material was processed, stained, and examined in blind fashion as described above for the presence of immunoglobulins (IgG, IgA, IgM) and complement (C3).

Antisera. Commercial goat antihuman sera, both free and fluorescein-conjugated, were obtained from Meloy Laboratories, Springfield, Va. All had a protein content of 10 mg/ml, with fluorescein-to-protein molar ratios as follows: anti-IgG, 3.8; anti-IgA, 2.6; anti-IgM, 3.4; and anti-C3, 4.2. Dilutions of antisera were employed, as follows, in order to reduce nonspecific staining: anti-IgG 1:16, anti-IgA 1:8, anti-IgM 1:8 and anti-C3 1:8. Antisera to IgD and IgE (Meloy Labs.) were also used in a few instances. Skin specimens were designated as showing a positive LBT when any one of the immunoglobulin classes was detected along the epidermal basement membrane (EBM).

Light microscopy. Representative cryostat-sectioned tissue was fixed in 10% formaldehyde solution and subsequently stained with hematoxylin-eosin for routine light microscopy.

Statistical calculations. The log-likelihood chi-square test was used for analysis of contingency tables.

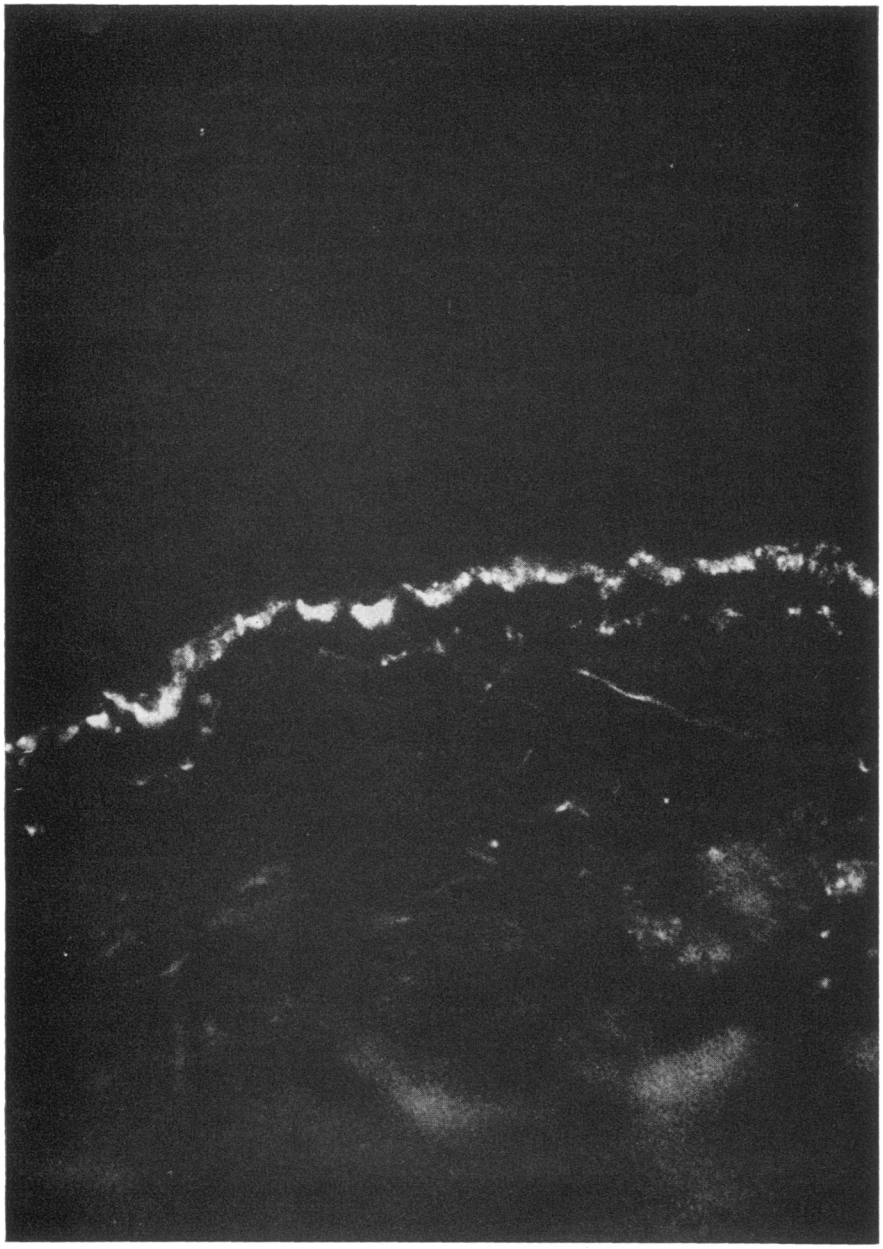

FIGURE 1 Biopsy specimen of clinically uninvolved skin from a patient with SLE stained with fluorescein-labeled antihuman IgG. A band of granular fluorescence is seen at the dermal-epidermal junction. (× 250).

RESULTS

Immunoglobulin staining of the EBM. In agreement with previous reports (7, 12), immunoglobulin was present in a thready, stippled, or granular band along the EBM in 23 (55%) of the 42 SLE patients. The most common was a granular pattern (Fig. 1) which varied in intensity and thickness from patient to patient and on repeated biopsy in the same patient.

23 patients showed positive reactions for one or more of the immunoglobulin classes (Table I). 21 stained positively for IgM, 19 for IgG, and 4 for IgA. 17 patients showed both IgM and IgG. Complement (C3) staining occurred in 10 cases, of which 8 stained also for IgG and IgM. The other two had either IgG or IgM staining. Positive sections from five patients were stained with antisera to human IgD and IgE. IgE

was absent in all; however, one specimen stained for IgD.

Of the control biopsies, specimens from 10 normal subjects and 63 of 65 patients with miscellaneous diseases were LBT-negative. The two subjects in the disease control group who were LBT positive had bullous pemphigoid, a common finding in this disease. In each case, the linear staining pattern characteristic of pemphigoid was observed.

Immunoglobulin staining of the GBM. In 12 patients, LBT were performed simultaneously with renal biopsy. All of the renal biopsy specimens examined had positive GBM staining (Table II). 11 of 12 stained for IgG, 11 for IgM, and 7 for IgA. 10 showed both IgG and IgM staining. Complement (C3) staining occurred in 11 of 12. The single exception (M. S.) showed only IgG in the GBM, had a normal serum complement level, and showed no EBM staining. 10 of the 11 with complement had both IgG and IgM staining; 1 had IgM alone.

Table II shows the EBM-staining reaction in the 12 patients in whom GBM staining was done. It can be seen that in all instances in which an immunoglobulin of a particular class was present in the skin, it was also found in the kidney. The reverse was not true, however, since in 4 of the 12 patients, immunoglobulin classes detected in the kidney were not present in the skin. Negative GBM-staining reactions invariably corresponded with negative EBM staining.

LBT in relation to clinical and laboratory features of SLE. The LBT was uninfluenced by the presence of acute skin lesions elsewhere (Table III). Of 14 patients with such lesions, 7 were LBT positive and 7 LBT negative. However, the frequency of chronic scarring (discoid) skin lesions bore an inverse relationship to the LBT, since of 12 patients with such lesions, 10 were LBT negative and only 2 were LBT positive. Central

TABLE I

Immunofluorescence Data on LBT-Positive Skin Biopsy Specimens of SLE Patients

Patient	IgG	IgM	IgA	C3
R. M.	+	+	−	ND*
D. P.	+	+	+	ND
B. L.	+	+	−	+
J. U.	+	+	−	ND
M. H.	+	+	−	ND
T. R.	+	+	−	+
J. W.	−	±‡	−	−
J. A.	+	+	+	−
L. S.	+	+	−	+
G. H.	−	±	−	−
M. G.	+	+	+	+
M. D.	+	+	−	+
R. A.	+	+	−	−
L. T.	+	+	−	−
L. D.	−	+	−	−
M. G.	+	−	+	−
J. V.	+	+	−	+
D. A.	+	+	−	−
T. S.	+	−	−	+
M. A.	+	+	−	+
V. P.	+	+	−	−
C. P.	+	+	−	+
J. M.	−	+	−	+

* ND—not done.
‡ ±—weakly positive.

TABLE II

Immunofluorescence Data on Skin and Renal Biopsy Specimens in the Same SLE Patient in Relation to Other Laboratory Features

Patient	Renal histologic classification	LBT	Immunofluorescent staining				ANA pattern	$C'H_{50}$*
			IgG	IgA	IgM	C3		
			FBM/GBM					
D. P.	PGN	+	+/+	+/+	+/+	+/ND	Periph.	18
M. A.	PGN	+	+/+	−/+	+/+	+/+	Periph.	20
M. D.	PGN	+	+/+	−/+	+/+	+/+	Retic.	40
P. G.	PGN	+	+/+	−/±	−/±	+/+	Periph.	35
T. S.	PGN	+	+/+	−/±	−/±	+/+	Homog.	40
J. U.	PGN	+	+/+	−/−	+/+	+/ND	Homog.	21
B. M.	PGN	−	−/+	−/−	−/+	−/+	Homog.	110
R. W.	Memb GN	−	−/+	−/−	−/+	−/+	Homog.	100
B. L.	Memb GN	+	+/+	+/+	+/+	+/+	Homog.	43
M. G.	Mes G	+	+/+	+/+	+/+	+/+	Periph.	17
M. S.	Mes G	−	−/+	−/−	−/−	−/−	Neg.	120
G. D.	Normal	−	−/−	−/−	−/+	−/+	Homog.	60

* $C'H_{50}$, total hemolytic complement, normal range 55–110 hemolytic units.

TABLE III
Extrarenal Clinical Features in Relation to the LBT

Clinical features	Number of patients	Number LBT positive	Number LBT negative
Arthritis	36	21	15
Skin involvement			
Acute lesions	14	7	7
Chronic scarring lesions	12	2	10
Alopecia	9	5	4
Serositis	21	11	10
Vasculitis	9	3	6
Recurrent thrombophlebitis	3	0	3
CNS involvement	8	2	6
Lymphadenopathy	5	3	2
Raynaud's phenomenon	5	2	3
Myositis	3	3	0

nervous system (CNS) involvement, which occurred in eight patients, was also less common in LBT-positive patients, since six of these patients were LBT negative and two were LBT positive. Vascular complications, other than in the CNS, were also less frequent in LBT-positive patients; of nine cases with vasculitis, three were LBT positive and six were LBT negative. Recurrent thrombophlebitis was a prominent clinical feature in three LBT-negative patients. The incidence of arthritis, serositis, alopecia, Raynaud's phenomena, and lymphadenopathy was similar in both the LBT-negative and -positive groups.

The LBT was uninfluenced by prednisone therapy in the dosages administered. 13 of the 23 LBT-positive patients (57%) received prednisone in an average dosage of 34 mg daily (range 10–100 mg), while 12 of the 19 LBT-negative patients (63%) received this drug in an average dosage of 25 mg of prednisone daily (range 5–90 mg). It appears unlikely from these data that corticosteroid therapy influenced the results of the LBT.

38 of the 42 patients tested gave positive antinuclear fluorescence tests. The LBT was associated with a positive ANA test at the time of biopsy in 21 of the 23 LBT-positive patients and 17 of the 19 LBT-negative patients, indicating no differences in frequency of ANA reactions in LBT-positive and -negative patients. The homogenous staining pattern, which was the most common, occurred with equal frequency in both groups (Table IV). The sera of six patients gave a reticular pattern; four were LBT positive and two negative. However, among seven with a peripheral staining pattern, all but one was LBT positive. LBT test and determinations of anti-nDNA were simultaneously carried in 10 patients. Seven had anti-nDNA in significant concentration (greater than 1.4 μg/ml). Six of these seven (86%) were LBT positive.

TABLE IV
ANA Tests in Relation to the LBT in 42 Patients

Staining pattern	Number of patients	LBT Number positive	LBT Number negative
Homogenous	25	12	13
Peripheral	7	6	1
Reticular	6	4	2
Negative	4	2	2

Depressed serum complement levels ($C'H_{50}$) were almost invariably associated with a positive LBT (Table V). 20 of the 22 patients (91%) with low serum complement levels were LBT positive, whereas only 3 of 20 (15%) with normal complement levels were positive ($P > 0.001$).

LBT in relation to renal disease. The LBT was positive in 18 of the 26 patients (70%) with renal involvement, as compared with 5 LBT-positive patients (31%) of the 16 without evidence of renal involvement (Table VI). The difference was significant ($P < 0.025$). Four of nine LBT-positive patients who initially had no clinical or laboratory evidence of renal disease subsequently developed overt renal disease after an average period of 4 mo, suggesting that the LBT may have predictive value in this regard. All four had depressed serum complement levels at the time of the initial positive LBT. Three of these patients were submitted to renal biopsy. PGN was found in two and Mes G in one. In contrast, none of 11 patients with initial negative skin biopsies later developed renal involvement during an average follow-up period of 16 mo.

Table VII summarizes the relationship between the LBT and the histopathologic findings on 29 renal biopsy specimens. These were classified in two groups based on the known correlation of renal histopathologic changes in SLE with subsequent progression and prognosis (15). In group I are included the patients with relatively more severe and progressive forms of SLE renal disease, PGN and Memb GN. Group II contains those with Mes G or with normal findings. Mes G is a relatively mild focal lesion which has been shown to be associated with a good prognosis (16). 10 of the 11 patients with PGN and 3 of the 5 with Memb GN were LBT positive. Thus, in the group with more severe renal involvement, 13 of 16 patients, or 81%, had positive LBT. On the other hand, only 3 of the 13 group II patients (23%) were positive. The difference between the two groups was significant. The only patient with PGN who had a negative LBT had end-stage renal disease when tested. In contrast to the other patients with PGN, her serum complement levels were consistently normal during the

6-mo period over which she was followed before her death. Renal tissue obtained at autopsy showed diffuse sclerosis of almost all of the glomeruli.

DISCUSSION

In these studies, significant relationships were observed between the presence of immunoglobulin deposits along the EBM of normal-appearing skin of SLE patients and the occurrence of hypocomplementemia, clinical evidence of renal disease, and pathologic evidence of either PGN or Memb GN. While 91% of patients with low serum complement levels showed positive tests, only 15% with normal levels were LBT positive. Furthermore, 70% of patients with clinical evidence of renal disease were positive, while only 31% without such evidence showed positive tests. Finally, the LBT was positive in 81% of SLE paitents with either PGN or Memb GN, but only 23% with the relatively benign renal biopsy finding of Mes G or with normal findings were LBT-positive. These relationships suggest that the immunoglobulin deposits in the skin and kidney may share a common pathogenic mechanism. This concept is further strengthened by the finding of a close correlation between the immunoglobulin classes in the skin and in the kidney. It is also of interest that most of the patients with anti-nDNA in the serum or with a peripheral antinuclear staining pattern were LBT positive, since these findings are correlated with the occurrence of activity (18) and renal disease (19) in SLE.

TABLE V
Relationship Between Serum Complement Level (C'H50) and the LBT

$C'H_{50}$	Number of patients	Number LBT positive	% Positive
Low	22	20	91
Normal*	20	3	15

$P < 0.001$.
* Normal range, 55–110 hemolytic U.

Further evidence of a relationship between the LBT and renal involvement was the finding that 4 of 9 LBT-positive patients, who initially, had no evidence of renal disease, subsequently developed renal involvement confirmed by renal biopsy, while none of 11 LBT-negative patients developed renal disease during a similar follow-up period. The latter observation raises the possibility that a positive LBT may help identify the patient at risk with respect to later renal involvement.

Kidney damage in SLE is believed to be mediated by immune complex deposition (20–22). It is associated with depressed serum complement levels (19, 23) and circulating immune complexes (22–24). Our finding of an association between immunoglobulin deposition in uninvolved skin and the presence of serious renal disease and low serum complement levels suggests that immune complex deposition is also occurring in the skin. Direct evidence for this supposition has been provided by elution studies of SLE skin (25), which have demonstrated the presence of antinuclear antibody in eluates, and by ultrastructural studies (26) which have shown electron-dense deposits beneath the EBM of SLE skin. The recent finding in this laboratory of immunoglobulin deposits in the laryngeal basement membrane of an LBT-positive patient with SLE (27) offers further evidence for the systemic character of this phenomenon and minimizes the significance of local factors in its production. It is of interest that discoid lupus erythematosus, in which renal involvement does not occur, is not associated with deposits in the uninvolved skin, although deposits are found in lesional skin (14).

TABLE VI
Relationship Between the LBT and the Presence of Clinical Renal Disease

Clinical evidence of disease	Number of patients	Number LBT positive	% Positive
Present	26	18	70
Absent	16	5	31

$P < 0.025$.

A plausible explanation for the presence of immunoglobulin in the EBM would appear to be the deposition of circulating immune complexes resembling those found in the kidney, i.e., DNA combined with an anti-DNA antibody. The association of the skin deposits with hypocomplementemia, serum antibody to native DNA, and lupus nephritis would suggest that the antibody in the skin may in large part be anti-nDNA, since it is this antibody which is critically associated with hypocomplementemia and renal involvement in SLE (19).

TABLE VII
Relationship Between the LBT and Renal Histologic Findings

Group	Classification	Patients	LBT positive	Total positive	% Positive
I	PGN	11	10	13	81
	Memb GN	5	3		
II	Mes G	9	3	3	23
	Normal	4	0		

$P < 0.005$.

ACKNOWLEDGMENTS

This investigation was supported by grants from the U. S. Public Health Service (AM 09989, AM 05154), the Dallas Veterans Administration Hospital, The Dermatology Foundation, and an Arthritis Foundation Clinical Study Center Grant.

REFERENCES

1. Burnham, T. K., T. R. Neblett, and G. Fine. 1963. The application of the fluorescent antibody technic to the investigation of lupus erythematosus and various dermatoses. *J. Invest. Dermatol.* **41**: 451.
2. Cormane, R. H. 1964. "Bound" globulin in the skin of patients with chronic discoid lupus erythematosus and systemic lupus erythematosus. *Lancet.* **1**: 534.
3. Burnham, T. K., T. R. Neblett, and G. Fine. 1966. Immunoglobulins in the skin of patients with lupus erythematosus. *Acta Derm.-Venereol.* **46**: 356.
4. Tan, E. M., and H. G. Kunkel. 1966. An immunofluorescent study of the skin lesions in systemic lupus erythematosus. *Arthritis Rheum.* **9**: 37.
5. Pohle, E. L., and D. Tuffanelli. 1968. Study of cutaneous lupus erythematosus by immunohistochemical methods. *Arch. Dermatol.* **97**: 520.
6. Percy, J. S., and C. J. Smyth. 1969. The immunofluorescent skin test in systemic lupus erythematosus. *J. Am. Med. Assoc.* **208**: 485.
7. Burnham, T. K., and G. Fine. 1971. The immunofluorescent "Band" test for lupus erythematosus. III. Employing clinically normal skin. *Arch. Dermatol.* **103**: 24.
8. Caperton, E. M., Jr., S. F. Bean, and F. R. Dick. 1972. Immunofluorescent skin test in systemic lupus erythematosus. Lack of relationship with renal disease. *J. Am. Med. Assoc.* **222**: 935.
9. Burnham, T. K. 1973. Immunofluorescent test for lupus erythematosus: relation to renal disease. *J. Am. Med. Assoc.* **223**: 798.
10. Cohen, A. S., W. E. Reynolds, E. C. Franklin, J. P. Kulka, M. W. Ropes, L. E. Shulman, and S. L. Wallace. 1971. Preliminary criteria for the classification of systemic lupus erythematosus. *Bull. Rheum. Dis.* **21**: 643.
11. Ginsburg, B., and H. Keiser. 1973. A millipore filter assay for antibodies to native DNA in sera of patients with systemic lupus erythematosus. *Arthritis Rheum.* **16**: 199.
12. Nelson, R. A., J. Jenson, I. Gigli, and N. Tamura. 1966. Methods for the separation, purification and measurement of nine components of hemolytic complement in guinea pig serum. *Immunochemistry.* **3**: 111.
13. Ploem, J. S. 1971. A study of filters and light sources in immunofluorescence microscopy. *Ann. N. Y. Acad. Sci.* **177**: 414.
14. Tuffanelli, D. L. 1972. Lupus erythematosus. *Arch. Dermatol.* **106**: 553.
15. Baldwin, D. S., J. Lowenstein, N. F. Rothfield, G. Gallo, and R. T. McCluskey. 1970. The clinical course of the proliferative and membranous forms of lupus nephritis. *Ann. Intern. Med.* **73**: 929.
16. Cheatum, D. E., E. R. Hurd, S. W. Strunk, and M. Ziff. 1973. Renal histology and clinical course of systemic lupus erythematosus: a prospective study. *Arthritis Rheum.* **16**: 670.
17. Ten Have-Opbroek, A. A. W. 1966. Demonstration of immunoglobulins and complement in the skin of patients with lupus erythematosus. *Acta Derm.-Venereol.* **46**: 68.
18. Gonzalez, E. N., and N. F. Rothfield. 1966. Immunoglobulin class and pattern of nuclear fluorescence in systemic lupus erythematosus. *N. Engl. J. Med.* **274**: 1333.
19. Schur, P. H., and J. Sandson. 1968. Immunologic factors and clinical activity in systemic lupus erythematosus. *N. Engl. J. Med.* **278**: 533.
20. Koffler, D., V. Agnello, R. I. Carr, and H. G. Kunkel. 1969. Variable patterns of immunoglobulin and complement deposition in the kidneys of patients with systemic lupus erythematosus. *Am. J. Pathol.* **56**: 305.
21. Tan, E. M., P. H. Schur, R. I. Carr, and H. G. Kunkel. 1966. Deoxyribonucleic acid (DNA) and antibodies to DNA in serum of patients with systemic lupus erythematosus. *J. Clin. Invest.* **45**: 1732.
22. Koffler, D., P. H. Schur, and H. G. Kunkel. 1967. Immunological studies concerning the nephritis of systemic lupus erythematosus. *J. Exp. Med.* **126**: 607.
23. Lewis, E. J., C. B. Carpenter, and P. H. Schur. 1971. Serum complement component levels in human glomerulonephritis. *Ann. Intern. Med.* **75**: 555.
24. Townes, A. S., C. R. Stewart, Jr., and A. G. Osler. 1962. Immunologic studies in systemic lupus erythematosus. Proceedings of the 2nd International Symposium on Immunopathology. P. Graber and P. Miescher, editors. Schwabe and Co., Basel. 315.
25. Landry, M., and W. M. Sams, Jr. 1973. Systemic lupus erythematosus. Studies of the antibodies bound to skin. *J. Clin. Invest.* **52**: 1871.
26. Grisham, E., and J. Churg. 1970. Ultrastructure of dermal lesions in systemic lupus erythematosus. *Lab. Invest.* **22**: 189.
27. Gilliam, J. N., and D. E. Cheatum. 1973. Immunoglobulin in the larynx in systemic lupus erythematosus. *Arch. Dermatol.* **108**: 696.