Endoscopic Management of Adnexal Masses

Liselotte Mettler, Prof Dr med, Kurt Semm, Prof Dr med, Dr med vet h c, Kourosh Shive

ABSTRACT

Background: The laparoscopic management of suspicious adnexal masses and early ovarian malignancies is discussed with the aim of maintaining accepted oncologic treatment principles. Comparative survival data of patients with gynecological malignancies managed by laparoscopy or laparotomy are still very scarce and the survival of cancer patients must not be compromised by new techniques. It is time to closely analyze laparoscopy and determine if it has a positive impact on the diagnosis and treatment of ovarian malignancies. In this paper we will address the following points:

1) Which ovarian cysts can be surgically treated by laparoscopy (pelviscopy)?
2) Is staging laparoscopy an accepted technique?
3) Is laparoscopy, as a second-look procedure, of benefit?
4) Is laparoscopic staging, together with histologic tissue sampling, adequate surgical technique in inoperable ovarian cancer with ascites and peritoneal carcinomatosis?
5) Does endoscopic biopsy of ovarian cancer stage Ia change the destiny of a patient into ovarian cancer Ic?

Data Base: The above questions are analyzed based on our experience with the laparoscopic treatment of 1,225 patients with ovarian cysts and 165 ovarian cancer patients stage I to IV treated immediately by laparotomy during the years 1992-1995.

Conclusions: Ovarian cystic tumors with no signs of malignancy can be dealt with by laparoscopic means with the option of immediate conversion to laparotomy or within one week if an ovarian malignancy is diagnosed. Today sampling laparoscopic lymphadenectomy of both pelvic and para-aortic is feasible and adequate. On a curative level, the number of lymph nodes to be resected has yet to be determined. The adnexa can be extracted from the abdominal cavity with bag extraction without the danger of spillage. The uterus can be removed transvaginally with laparoscopic assisted vaginal hysterectomy (LAVH). We must be cautious to advocate laparoscopy for ovarian cancer. However, it is an excellent tool when used as a staging procedure. A careful preoperative screening of the patient and an exact definition of existing cysts with imaging techniques allows us to frequently apply laparoscopic surgery for ovarian cysts, leaving only readily detectable cancer cases for laparotomy. Many gynecological oncologists employing staging and second-look procedures for ovarian cancer agree that initiating a case with laparoscopy may preclude laparotomy for many patients. Tumor propagation by performing a biopsy in FIGO stage Ia ovarian cancer patients does not occur if the patient receives adequate radical surgical treatment within one week. According to the reports of Sevelda et al. and Dembo et al., the degree of differentiation and the existence of ascites are more relevant to decreasing the five-year survival rate of patients with ovarian cancer stage I than the rupture of capsule or penetration of the tumor.[16,17] A dependency on the first two parameters was found in these two large statistical studies.

As the question of endoscopic operations for adnexal mass is predominantly put for the sanitation of small ovarian tumors (ovarian tumors with solid particles in the cysts can be put into the section of primary laparotomies) there remains a wide field of indications for the laparoscopic treatment of adnexal mass and ovarian cysts with benign indications. For many young patients with non-malignant ovarian lesions such as endometriosis, benign cysts, benign cystic proliferations and fibromas, a laparotomy can be avoided and these lesions treated by laparoscopy.

Key Words: Laparoscopy, Adnexal mass, Ovarian malignancy, Second-look laparoscopy.

INTRODUCTION

Ovarian tumors occur in all stages of female life: during childhood they arise mostly as dysgerminomas; after menarche as functional cysts; and around menopause as carcinomas, although carcinomas also appear during reproductive age. The histological picture of ovarian tumors is quite characteristic, but the exact histological classification is often difficult to determine as ovarian tumors may grow very rapidly. A precise early diagnosis is not always possible. The spectrum of therapy for ovarian cancer has changed a great deal over the past several years as more radical oper-

Address reprint request to: Prof Dr med L. Mettler, Michaelisstr. 16, 24105 Kiel, Germany.

Table 1.
Prerequisites in Judging Ovarian Cysts Prior to Laparoscopic Surgery

Ultrasound	vaginal abdominal Doppler 3 dimensional	no solid - echo dense structures (exception dermoid cyst)
Tumor markers	CA 125	always in-patients > 40 years
Size of cyst	larger than 15 cm in diameter difficult to judge	
Hematological parameters		
In some cases	NMR - nuclear magnetic resonance CT - computer tomogram	

ations are performed in the early stages of the disease, new chemotherapeutic strategies with agents such as paclitaxel have been initiated, and stem cell transplantation during high dose chemotherapy has been investigated. However, the general prognosis remains poor. Only women with an early ovarian cancer, stage I, which is not easily discovered, have a significant chance for survival. In order to guarantee the healing process, surgical procedures for ovarian tumors have to be performed as carefully as possible. The oncologic principles of ovarian surgery have to be applied during laparoscopic surgery. Unfortunately the rupture of an ovarian cancer stage Ia during laparoscopy, as in laparotomy, sometimes cannot be avoided. Since the beginning of the 1980s, world-wide laparoscopic procedures have increased and the question of tumor dissemination, especially in ovarian cancer, is being newly discussed.

For those gynecologic oncologists employing second-look procedures it appears that beginning with laparoscopy may preclude laparotomy in many patients. Therefore, it has been frequently suggested that the role of laparoscopy as a second-look procedure in ovarian cancer can avoid laparotomy. Comparative survival data for patients with gynecological malignancies managed by laparoscopy or laparotomy, however, are still very scarce. Sound surgical practice and medical ethics demand that the survival of patients must not be compromised by the investigation of new techniques.

Historical Background:

Very little has been published concerning the role of laparoscopy in patients with invasive ovarian carcinoma. In the late 1970s and early 1980s laparoscopy was used for pre-treatment evaluation (in patients whose initial staging laparotomy was felt to be inadequate) to replace a staging laparotomy in patients with presumed stage III and IV disease. Laparoscopy could detect diaphragmatic metastases in a significant number of patients and be applied in a far more precise way than laparotomy.[1] In Bagley's series of cases suspicious for ovarian cancer, metastases were discovered in 62.5% of patients (10 of 16) who were originally felt to have stage I or stage II ovarian cancer.[2]

Semm, along with others, suggested laparoscopy for a second-look procedure in ovarian cancer.[1,3,4] Although the identification of persistent disease, as based on second-look laparotomies, was lower than expected in these early reports, the technique is advised if the whole abdomen is visible laparoscopically. If the entire abdomen is not visible one can always convert to a laparotomy. None of the early investigators sampled pelvic or para-aortic lymph nodes. We always suggested routine blind biopsies and abdominal washings. The importance of washings for cytological evaluations has been reported by several investigators.[5]

Basic Principles:

In women beyond the menopausal age an adnexectomy is the procedure of choice for the prevention of rupture in those with an ovarian tumor. During the reproductive years we primarily have to think of treating cystic ovarian structures to preserve the ovaries and to preoperatively exclude cancer. In the early 1990s, laparoscopic procedures for ovarian surgery reported a 2-4% incidence of ovarian cancer cases, which were biopsied and subsequently underwent definitive surgical treatment. It is felt that this number can be reduced to 0.2-0.6% with intensive, thorough preoperative testing. Each ovarian tumor should

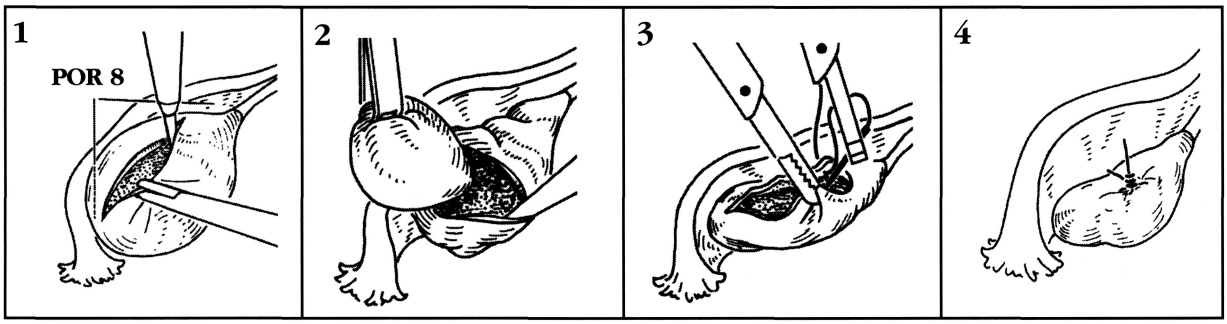

Figure 1. Pelviscopic enucleation of an ovarian cyst and suture of the ovarian lining.
1. Capsular incision
2. Cyst resection
3. Ovarian suture
4. Final aspect after endoscopic ovarian cyst resection

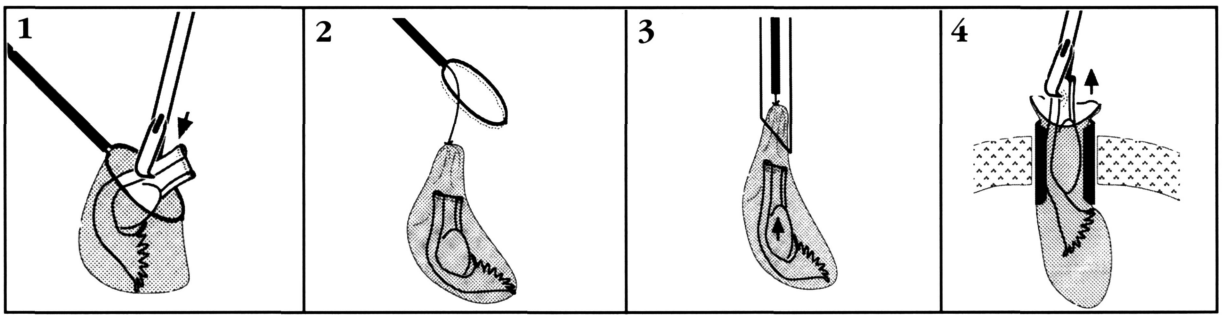

Figure 2. Bag extraction of endoscopically resected adnexa.
1. Positioning of adnexa into an endobag
2. Closing the bag by pulling the string
3. Insertion of bag into the trocar
4. Bag extraction

be investigated preoperatively with all available imaging methods, so that laparoscopy for the surgical correction of functional cysts can be avoided.

Preoperative Diagnosis:

Prior to therapy an extensive and wide anamnesis and clinical investigation is necessary to establish a differential diagnosis. Endometriotic cysts are differentiated from carcinomas. This is performed by careful ultrasound diagnosis transvaginally and, if available, with Doppler ultrasound and three-dimensional ultrasound. Special consideration has to be given to the tumor size, to the presence of uniloc-ular or bilateral ovarian cysts, the existence of septa, the existence of solid particles, papillomatous structures, hematological hints for malignancies, etc. The result of ultrasound is put together as sonomorphology with a diagnosis towards dignity or malignancy. Tumor markers, especially CA 125, have a special predictive value in premenopausal patients. False positive values are expected in cases of endometriosis and uterine fibromas. During the postmenopausal period, endometriosis and uterine fibromas have a certain draw towards malignancies. Prerequisites for a planned ovarian surgery in benign cysts are the following items **(Table 1)**.

Intraoperative Diagnosis:

Intraoperatively, after initial laparoscopic survey, the situation is evaluated with loop augmentation or video magnification. In cases of suspected malignancy the surgical procedure is converted into a laparotomy. Intraoperatively, one has the capability of taking a fluid sample from the pouch of Douglas for cytological examination and performing a careful look for metastases. An opening of cysts for diagnostic purposes is not recommended as this could provoke cell dispersion in cases of malignancy. The result of cytological examination of fluid from the pouch of Douglas should be available prior to manipulation of ovarian tumors, if the surgeon has any suspicion of malignancy. That is to say if the surface of the ovary shows increased vascularization or other changes that suggest the possibility of malignant tumor, conversion to laparotomy should occur even if the histology does not later show a malignancy.

In the case of minor alterations on the surface of the ovary, a biopsy should be taken and a histological diagnosis done intraoperatively. The frozen section, however, can present difficulties for the pathologist. If a clear-cut diagnosis can-

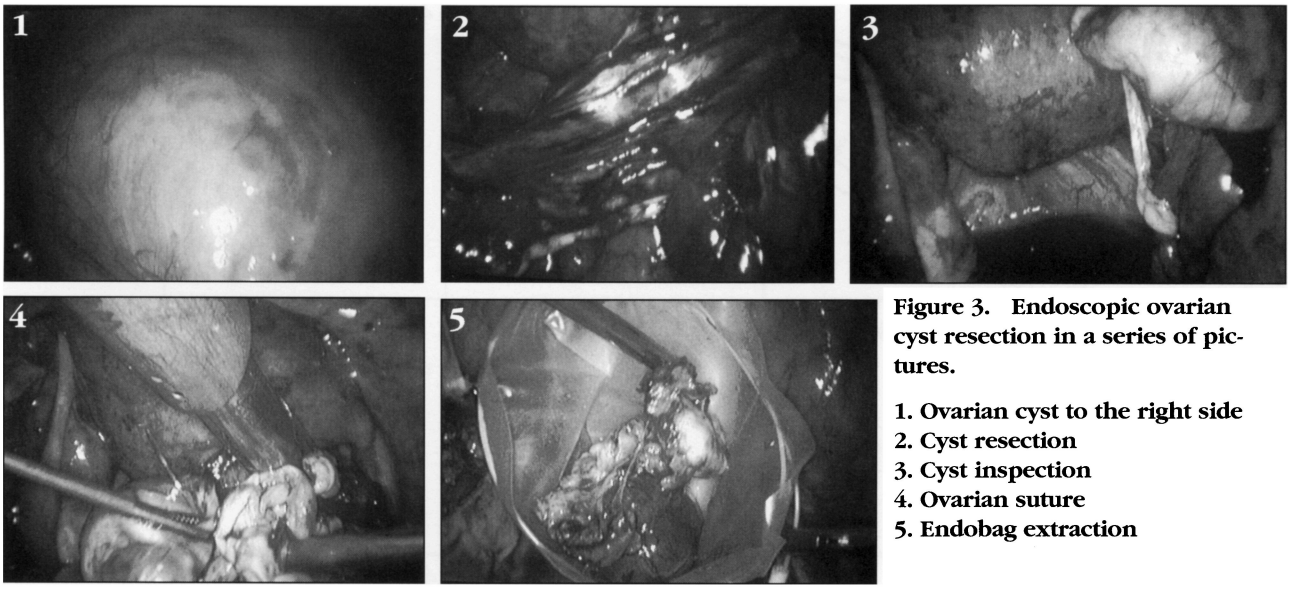

Figure 3. Endoscopic ovarian cyst resection in a series of pictures.

1. Ovarian cyst to the right side
2. Cyst resection
3. Cyst inspection
4. Ovarian suture
5. Endobag extraction

not be given or if the diagnosis does not fit the anatomical situation, it is better to stop the surgery, not to go to laparotomy but wait for the final histology. Once the histology is clear, laparoscopic adnexectomy or laparotomy has to be performed at that time during the same operation. In cases of malignancies, the extended open (laparotomy) surgery, if not performed at the same intervention, must be performed within one week of the primary diagnosis. Laparotomy performed later carries the risk of having delayed too long.

If there is no sign of malignancy, the ovarian tumor is resected according to the age and life situation of the patient. During an adnexectomy, an ovariectomy, partial ovariectomy or cystectomy, all ovarian tumors should be precisely excised. This is also difficult during laparotomy but must be considered if one wishes to preserve the organ. The extraction of the ovarian tumor must be into an appropriate endoscopic bag, which is passed through a working channel through the abdominal layers. As impermeable bags are readily available, the extraction of an unprotected ovarian tumor through the trocar is no longer appropriate. After extirpation of the specimen, hemostasis may be secured by coagulation, use of sutures or by clips followed by an adequate rinsing and aspiration procedure leaving clear wound conditions.

Functional Cysts:

In order to avoid unnecessary operations for functional cystic ovarian tumors, all patients should be managed initially-with an estrogen suppressive treatment program. Prerequisites are the existence of one or two chamber cysts smaller than five centimeters in diameter and causing no pain to the patient. It is easy to follow the cyst by vaginal ultrasound examinations at intervals of no longer than four weeks. If the cysts increase in size, change their shape or do not diminish in size, the patients should be operated upon according to the criteria described for laparoscopy or laparotomy. An increase in size as well as an increase in abdominal pain calls for immediate surgical intervention.

Treatment of Ovarian Tumors at the Department of Obstetrics and Gynaecology, University of Kiel 1992-1995:

Endoscopic surgical procedures were performed in 1,225 patients who presented cystic ovarian tumors between 1992 and 1995 at the Department of Obstetrics and Gynaecology, University of Kiel. One hundred and sixty-five new patients with ovarian cancer stage I to IV were treated according to accepted criteria with an operative radical laparotomy debulking, lymphadenectomy and omentectomy. Consecutive chemotherapeutic courses or radiation therapy were given according to accepted parameters. The operative procedure mandated in our institution is that of direct laparotomy in cases of possible malignancies. In the cases presented during these four years none of the endoscopically performed biopsies and frozen sections suggested an ovarian cancer. If biopsy would have indicated a malignancy, we would have performed the corresponding radical operation during the same surgical procedure after converting to laparotomy. We converted more cases to laparotomy than necessary in order to take a biopsy. Laparoscopic transabdominal extraction of an adnexectomy, an ovariectomy or an ovarian cyst resection, was always performed in an endobag.

Figures 1 to **3** demonstrate ovarian cyst resection and adnexal bag extraction via laparoscopy (pelviscopy) in line

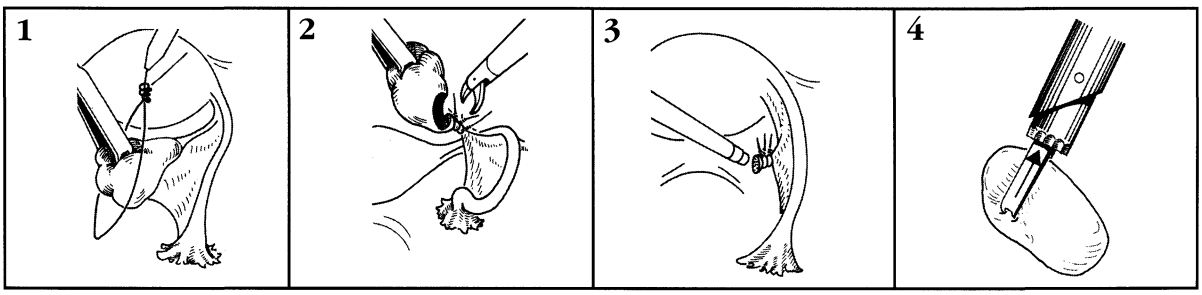

Figure 4a. Endoscopic oophorectomy using the 3-loop ligation technique in four steps.

1. Positioning of the frist Roeder loop
2. After placement of 3 loops ovarian resection
3. Endocoagulation of the ovarian stump
4. Ovarian morcellation using 15 or 20 mm trocars

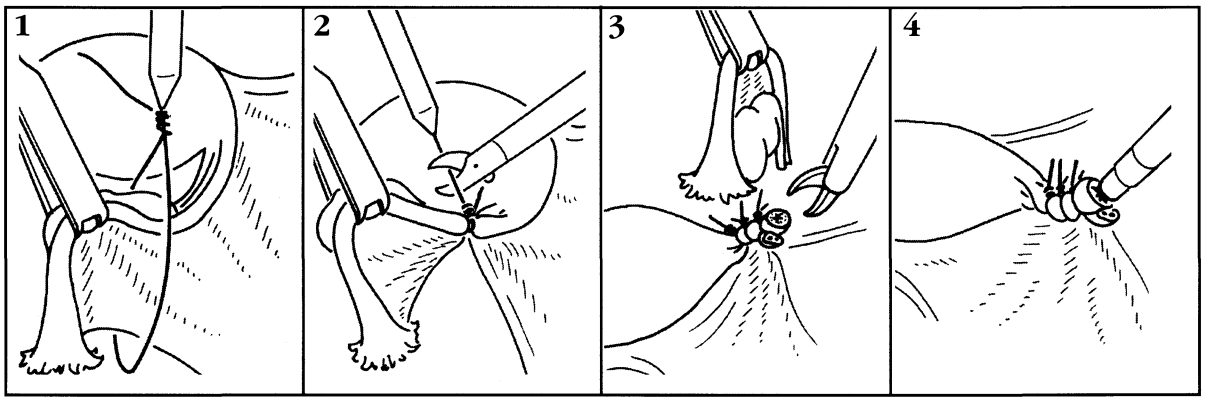

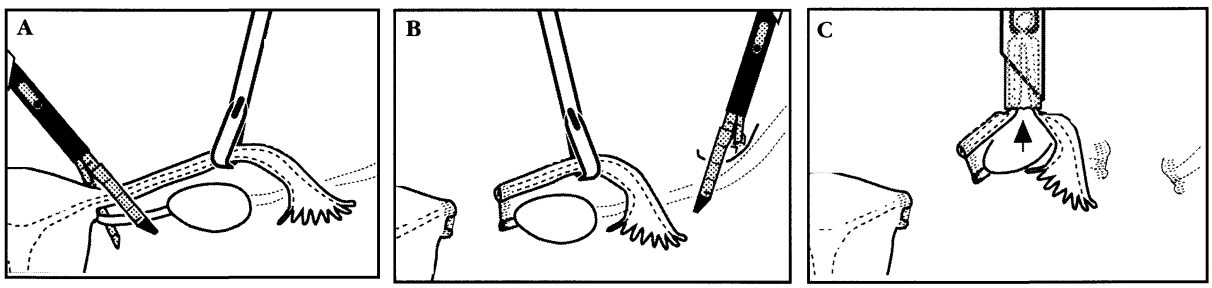

Figure 4b. Endoscopic adnexectomy using the 3-loop ligation technique in four steps (1-4) or in three steps using stapling techniques (A-C).

1. Placement of first loop
2. Cutting the loop
3. After positioning of 3 loops adnexal resection
4. Endocoagulation of the stump

A. Adnexal resection using a stapling device at the ovarian ligamnet
B. Dissection of infundibulo pelvic ligament
C. Adnexal resection

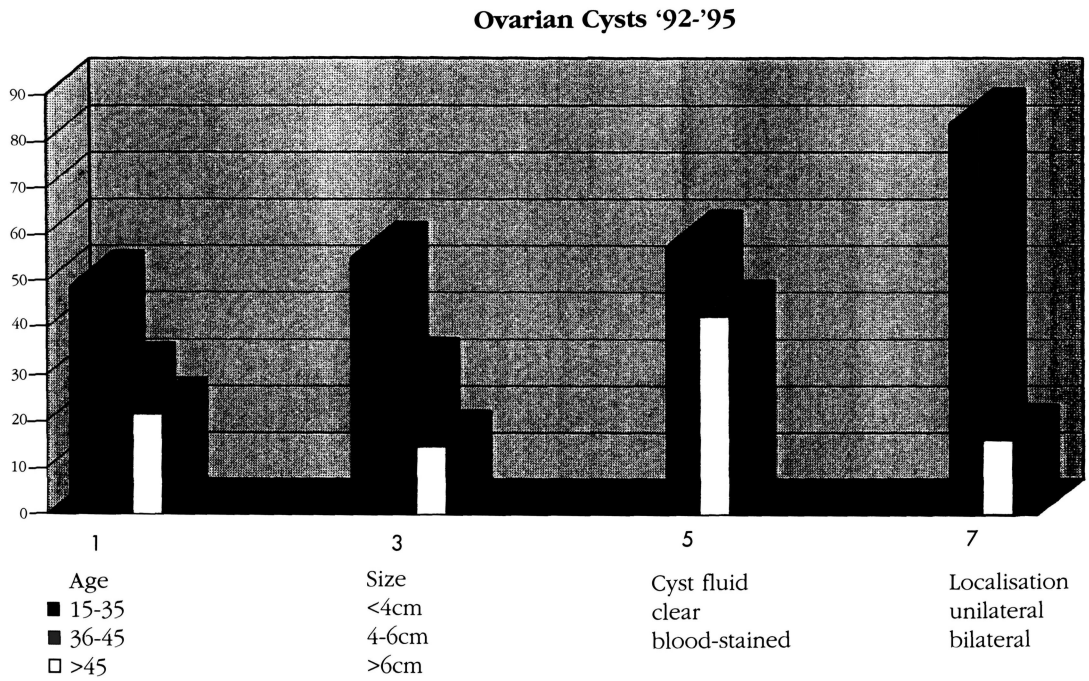

Figure 5. Statistical evaluation of 1225 patients treated by endoscopic ovarian surgery according to their ages, size of ovarian cysts, color of cyst fluid and uni- or bilateral localization.

drawings as well as endoscopic pictures. Oophorectomies **Figure 4a** or adnexectomies **Figure 4b** were performed with the three-loop suture ligation technique, by stapling devices or after bipolar coagulation of the ovarian ligament. All these techniques facilitate an easy adnexectomy, which was predominantly performed in patients beyond the reproductive age. **Figure 5** details the operative patients according to their ages, the size of the ovarian cyst, if the cysts were septated, if they contained clear or bloodstained fluid and if they were unilateral or bilateral. Histological results revealed the broad spectrum of diagnosis and also included functional cysts of patients who were referred to us by their doctors for persistent ovarian cysts. Carcinomas were detected in 2.4%. **Figure 6** specifies the patients in 1992, 1993, 1994 and 1995 in which we converted the operation into a laparotomy. However, of those patients only two in 1992, five in 1993, two in 1994 and four in 1995 eventually presented with malignancies. **Figure 7** details the benign and malignant patients who were diagnosed as suspect at the first-look staging laparoscopy. **Figure 8** gives the histological results of nine patients who did present malignancies after conversion to laparotomy. These cancers were not recognized preoperatively but during the conversion to laparotomy. In one case, laparoscopic biopsy of the ovary revealed a borderline lesion. Only later in the histopathological evaluation of the paraffin section was the diagnosis of a non-Hodgkin's lymphoma confirmed.

We do not intend to say that we will never find a malignancy when we do a biopsy laparoscopically, but it will happen rarely. Had we continued in the above patient with a borderline lesion, we would not have performed the correct therapy. The diagnosis, which was received not at frozen section but two days later, revealed a Hodgkin's lymphoma. The patient then received the adequate treatment. The frozen sections indicated a borderline lesion which did not seem to fit the picture of that patient. Therefore, in this case we waited for the final diagnosis and elected to perform a laparotomy after we had the final result two days later. The Hodgkin's lymphoma then required a different treatment.

Patients treated endoscopically should follow the principles of open oncologic surgery. The tumors should be taken out without rupture of the capsule and without contamination. Considering these regulations, staging endoscopic surgery with the possibility of converting to laparotomy in the few specific cases that reveal ovarian cancer does not present a higher risk for the patient than primary laparotomy. Any consecutive radical operation has to be done immediately or within the first week of diagnosis. This includes all malignant adnexal tumors, ovarian cancer, tubal cancers, dysgerminomas, malignant teratomas and borderline cancers of the ovary. According to current oncologic criteria, an endoscopic biopsy of malignant adnexal tumors should be avoided. In patients with non-suspicious lesions preoperatively, a laparoscopic biopsy may be indicated. The appropriate consecutive operation has to follow within the discussed time limit. The question arises whether in a 25-year-old patient undergoing infertility treatment should one do a biopsy of a pea-sized abnormal looking ovarian lesion or take out the whole ovary at laparotomy.

However, in such a young patient, even at a laparotomy, one would hesitate to do more than a biopsy at the primary intervention.

For these cases we would like to propose the following:

If there is a suspicion of a non-benign lesion of the ovary prior to and after laparoscopy, serological examination of a fluid sample from the pouch of Douglas should be performed.

Frozen section is indicated for unexpected, potentially malignant alterations in an ovarian cyst.

With unexpected malignant lesions, the patient has to be operated on during the same intervention with definitive resection of ovaries, adnexa, uterus, lymph nodes and omentum, or at least within the next five days.

In all patients with an ovarian cyst, explanation prior to the operation must include a discussion of malignant alterations that may require a laparotomy with hysterectomy, bilateral adnexectomy, omental resection and possibly lymphadenectomy.

With unexpected suspicious lesions (and a well-informed patient) the diagnosis is confirmed with a biopsy; the corresponding laparotomy has to follow within the next five days.

Endoscopic organ extraction of an adnexal tumor has to be performed with an impermeable endobag.

If in spite of the described security examinations or prerequisites for endoscopic ovarian surgery an ovarian cancer has been biopsied, depending on the stage it has to be operated as quickly as possible and followed by chemotherapy. This has to be done within one week of the first procedure.

The Role of Laparoscopy in Stage I Ovarian Carcinoma:

The role of laparoscopy in stage I ovarian carcinoma has been addressed by different authors. Some surgeons have incorporated the use of routine procurement of washings and blind biopsies in their staging procedures. Of great

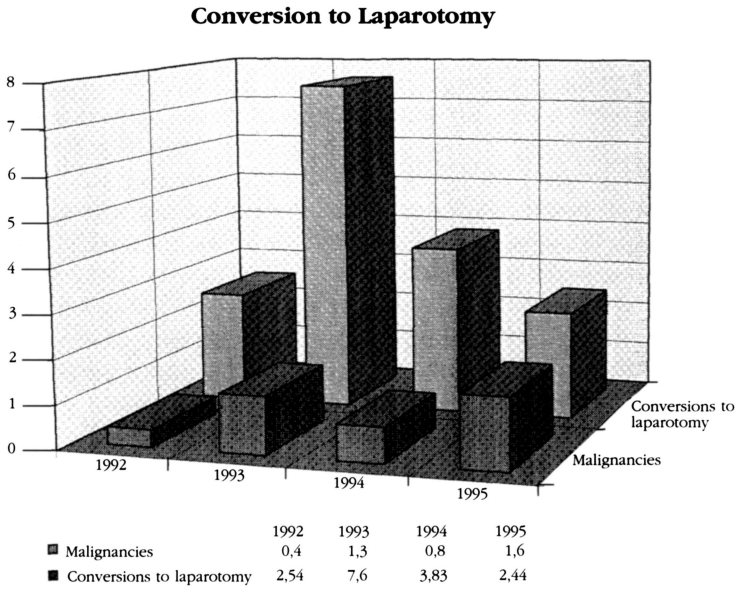

Figure 6. Conversion rate of pelviscopy to laparotomy between 1992-1995 at ovarian endoscopic surgery.

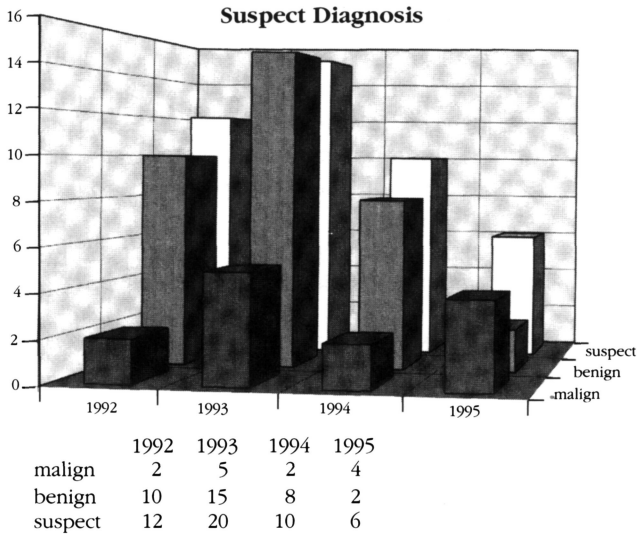

Figure 7. Suspect diagnosis at pelviscopic screening for ovarian surgery.

Specification of ovarian malignancies 1992-1995			
1992	**1993**	**1994**	**1995**
1 X adenocarcinoma	3 X adenocarcinoma	3 X adenocarcinoma	4 X adenocarcinoma
1 X granulosacell-tumor with sarcoma	1 X Krukenbergtumor	1 X Krukenbergtumor	
	1 X metastasis of non-Hodgkin lymphoma		

Figure 8. Specification of ovarian malignancies screened endoscopically but treated surgically by laparotomy.

importance is the possibility of magnification with video laparoscopy and the ability to perform pelvic and para-aortic lymphadenectomy. This makes laparoscopic staging potentially a very accurate technique. At the present time there are only a few case reports available describing laparoscopic staging of estimated stage I invasive carcinoma of the ovary. Reich et al. (1990) were the first with their report of a 56-year-old woman with a five-centimeter left ovarian neoplasm.[6] After removing the adnexa through a colpotomy incision and confirming malignancy by a frozen section, they performed a laparoscopic assisted vaginal hysterectomy and right salpingo-oophorectomy along with a transvaginal infra-colic omentectomy, a left pelvic lymphadenectomy and biopsy of the left pelvic sidewall. The histological examination showed both ovaries contained grade II serous papillary adenocarcinoma but 11 pelvic nodes and pelvic sidewall biopsies were all negative for malignancy. This group has been criticized for puncturing a malignant cyst, not obtaining intraperitoneal washings for cytology or multiple blind biopsies, especially of the right hemidiaphragm, and not sampling para-aortic lymph nodes. However, they should also be congratulated for their innovativeness in using this technique in a patient who refused laparotomy. In 1992, Nezhat and colleagues reported on four ovarian cancers diagnosed during laparoscopic management of 1,011 women with adnexal masses.[7] In this series they described a six-centimeter right ovarian cyst that was opened and biopsied for papillary growth and revealed necrotic tissue with atypical glands. They performed a right salpingo-oophorectomy, appendectomy and peritoneal and omental biopsies laparoscopically.

Querleu outlined what is today considered an adequate laparoscopic surgical staging procedure for ovarian carcinoma. In his report, he described laparoscopic infrarenal para-aortic node dissection in a 39-year-old woman with a serous tumor of low malignant potential.[8] He successfully staged this patient laparoscopically by oncologic standards and performed washings, multiple biopsies, omentectomy and a pelvic and para-aortic lymphadenectomy. Twelve pelvic lymph nodes, nine para-aortic lymph nodes and all biopsies were negative for metastatic disease. In 1994 Querleu and Le Blanc reported on laparoscopic infrarenal para-aortic node dissection for staging of carcinoma of the ovary or Fallopian tube.[9] Four patients with presumed stage Ia ovarian cancer of low malignant potential were restaged following inadequate staging procedures. Three other patients had invasive cancer and were staged laparoscopically for presumed stage I disease. Endometrioid cancer of the ovary was found in two patients and one patient had a Fallopian tube carcinoma. They described an adequate staging procedure including pelvic and para-aortic lymphadenectomy up to the renal veins, with an average of 10 para-aortic lymph nodes to be removed. Many staging laparotomies performed, for example, at our department do not include such a detailed field. Childers et al. in 1992 and in 1993 described para-aortic lymphadenectomies and gynecological malignancies in 18 patients with ovarian cancer.[10] In the majority of patients these were second-look procedures for advanced disease, but in six patients they presumed stage I ovarian cancer. It is of great concern that laparoscopic staging of presumed stage I ovarian carcinoma may miss extra ovarian disease that would have been detected at laparotomy. As the screening possibility with the 4-8 times magnification during laparoscopy in an adhesion-free abdomen is even better than that at a laparotomy, this concern is unnecessary.

Fifteen years ago we already started to use video laparoscopy primarily for second-look procedures for advanced disease prior or during chemotherapy. We investigated the effectiveness of laparoscopy in this combination.

Laparoscopic Diagnosis and Surgery in Advanced Ovarian Cancer and Second-look Laparoscopies:

Whenever possible advanced ovarian carcinoma should be treated with a primary debulking laparotomy. In cases of an ovarian cancer without enlargement of the tumor within the minor pelvis, laparoscopic diagnosis and histological verification is justified. Especially in those cases with ascites, however, it must be possible to perform either a laparotomy with radical surgery including deperitonization, bowel resection, omentectomy, etc., or chemotherapy immediately after diagnosis. These interventions must be done in oncologic centers that have the infrastructure for radical operations and adequate medical therapy of ovarian carcinomas.

Our present experience of second-look laparoscopies has not been previously reported and consists of 62 interventions performed on 48 patients with advanced ovarian carcinomas. All patients were primarily operated on with maximal surgical debulking and had received platinum-based chemotherapy. Clinically, they showed no evidence of malignant disease. All tumor-markers were negative (CA 125) with the exception of four cases. If at laparoscopy no obvious disease was noted immediately, intraperitoneal washings were obtained and slices of adhesions and biopsies were taken of many suspicious and non-suspicious areas. Persistent disease was documented laparoscopically in 20 of our 62 procedures. Only in seven patients did we find metastatic disease with intraperitoneal metastases. In five patients we had to convert to laparotomy as the abdominal cavity, even after adhesiolysis, was not really visible. Our results of second-look laparoscopies are encouraging. We could avoid a laparotomy in over 90% of our patients. The positive rate was similar to that found at second-look laparoscopies, and the patients certainly had a shorter hospitalization time and less physical pain than in

Table 2.

Possibilities of judgement at pelviscopy/upper abdominal laparoscopy.

Ovarian surface texture
Vascularization of tumor
Papillomatous or suspicious structures
Adhesions
Ascites
Cytology in rinsing fluid
Tumor sites at the peritoneum, intestines, liver, diaphragm
Size of primary tumor
Mobilization of tumor
Amount of adhesions of intestines
Mobilization of intestines
Indication for laparotomy with the possibility of 90% tumor reduction
Biopsy of primary tumor, peritoneum, omentum, intestines, liver diaphragm

a repeat laparotomy. In these patients to date, only two lymphadenectomies have been performed. However, with growing experience this should be included more often into our second-look laparoscopies. As reported by Childers in 1995 in a series of 42 procedures performed in 38 patients with advanced ovarian or Fallopian tube carcinoma in second-look laparoscopies, if no persistent disease was documented by frozen section, they performed multiple blind biopsies and laparoscopic lymphadenectomy routinely.[11,12] With this combination of procedures at second-look laparoscopy they found a 58% positive rate, which is similar if not higher than the reported rate for second-look laparotomy. Extrapolating these data, they presumed one could infer that laparoscopic staging of presumed early ovarian carcinoma would disclose metastatic disease at a rate similar to that of laparotomy.[13] Dargent in 1993 and Spirtos in 1993 described laparoscopic interventions in gynecological cancer as clear-cut alternatives to laparotomy.[14,15]

Structural Prerequisites for Laparoscopic Operations of Ovarian Tumors:

Ovarian tumors in which malignancy has been excluded by preoperative diagnosis can be operated on where the personal and apparative prerequisites for laparoscopic operations are present. In all other cases, however, if one cannot exclude malignancy and possible laparotomy based on the preoperative investigations, intervention should be carried out at clinics where the prerequisites for an adequate and correct surgery for laparotomy are present.

CONCLUSION

As already indicated in the catalogue of indications for advanced laparoscopic surgery by Semm in 1984, diagnosis and therapy of ovarian cancer by laparoscopy can be considered. First reports on the role of laparoscopy in gynecological malignancies have centered around staging procedures and second-look laparoscopies. Today, regarding tissue sampling, laparoscopic lymphadenectomy of both pelvic and para-aortic nodes is feasible and adequate. On a curative level the number of lymph nodes to be resected, however, has yet to be determined. We must be cautious to advocate laparoscopy for ovarian cancer treatment; however, it is a valuable and worthwhile tool in the staging of malignancies. Careful preoperative screening of the patient and an exact definition of existing cysts with imaging techniques allows us to frequently apply laparoscopic surgery for ovarian cysts, leaving only readily detectable cancer cases for laparotomy.

It may be safe to say that gynecological oncologists employing staging and second-look procedures for ovarian cancer have to admit that beginning with laparoscopy may preclude laparotomy for many patients. Survival data for patients with gynecological malignancies managed by laparoscopy instead of laparotomy are of course still lacking and this is the predominant question. In no way must survival be compromised just to employ a new surgical technique. According to the reports of Sevelda et al. and Dembo et al., the degree of differentiation and the existence of ascites are more relevant to decreasing the five-year survival rate after ovarian cancer stage I than the rupture of capsule or the penetration of the tumor. A dependency on the first two parameters was found in two large statistics.[16,17]

As the question of endoscopic operations in adnexal mass is predominantly put for the sanitation of small ovarian tumors (ovarian tumors with solid particles in the cysts can be put into the section of primary laparotomies), there remains a wide field of indications for the laparoscopic treatment of adnexal mass and ovarian cysts with benign indications. For many young patients with non-malignant ovarian lesions such as endometriosis, benign cysts, benign cystic proliferations and fibromas, a laparotomy can be spared and they can be treated by laparoscopy. The laparoscopic therapeutic management of ovarian malignancy and suspicious adnexal masses cannot be recommended at the present time, but must be investigated by carefully controlled studies. Different possibilities of judgement at pelviscopy including upper abdominal laparoscopy are given and have to be included in any discussion **(Table 2)** on the laparoscopic treatment of ovarian cysts.

References:

1. Semm K. Operative Manual for Endoscopic Abdominal Surgery. Chicago, IL, London, UK: Yearbook Medical Publishers, 1984:339-340.

2. Bagley CM, Young RC, Schein PS, Chabner BA, DeVita VT. Ovarian cancer metastatic to diaphragm frequently underdiagnosed at laparotomy, a preliminary report. *Am J Obstet Gynecol.* 1973;116:397-400.

3. Ozols RF, Fisher RI, Anderson T. Peritoneoscopy in the management of ovarian carcinoma. *Am J Obstet Gynecol.* 1981;140:611-623.

4. Berek JS, Griffiths CT, Levanthal JM. Laparoscopy for second-look evaluation in ovarian carcinoma. *Obstet Gynecol.* 1992;58:192-198.

5. Mettler L, Caesar G, Neunzling S, Semm K. Stellenwert der endoskopischen Ovar-Chirurgie - kritische Analyse von 626 pelviskopisch operierten Ovarialzysten an der Universitätsfrauenklinik Kiel 190-1991. *Geburtshilfe Frauenheilkunde.* 1993;53:253-257.

6. Reich H, McGlynn F, Wilkie W. Laparoscopic management of stage I ovarian carcinoma. A case report. *J Reprod Med.* 1993;35:601-604.

7. Nezhat F, Nezhat C, Welander CE, Benigno B. Four ovarian cancers diagnosed during laparoscopic management of 1,011 women with adnexal masses. *Am J Obstet Gynecol.* 1992;167:790-796.

8. Querleu D. Laparoscopic para-aortic lymph node sampling in gynecologic oncology: a preliminary experience. *Gynecol Oncol.* 1993;49:24-29.

9. Querleu D, LeBlanc E. Laparoscopic infrarenal para-aortic node dissection for restaging of carcinoma of the ovary or fallopian tube. *Cancer.* 1994;73:1467-1471.

10. Childers JM, Surwit EA, Hatch KD. The role of laparoscopy in the management of cervical carcinoma. *Gynecol Oncol.* 1992;47:38-43.

11. Childers JM, Brzechffa PR, Hatch KD, Surwit EA. Laparoscopically assisted surgical staging (L.A.S.S.) of endometrial cancer. *Gynecol Oncol.* 1993;51:33-38.

12. Childers JM, Hatch KD, Tran AN, Surwit EA. Laparoscopic para-aortic lymphadenectomy in gynecologic malignancies. *Obstet Gynecol.* 1993;82:741-747.

13. Childers JM. Operative Laparoscopy in Gynecologic Oncology. In Cusumano PG, Deprest JA, eds. Advanced Gynecologic Laparoscopy. 1995:201-217.

14. Dargent D. Laparoscopic surgery in gynecologic cancer. *Curr Opin Obstet Gynecol.* 1993;5:294-300.

15. Spirtos NM. Letter. Laparoscopic radical hysterectomy with para-aortic and pelvic lymph node dissection? *Am J Obstet Gynecol.* 1993;168:1643.

16. Dembo AJ, Davy M, Stenwig AE, Berle EJ, Bush RS, Kjorstad K. Prognostic factors in patients with stage I epithelial ovarian cancer. *Obstet Gynecol.* 1990;75:2.

17. Sevelda P, Varra N, Schemper M, Salzer H. Prognostic factors for survival in stage I epithelial ovarian carcinoma. *Cancer.* 1990;65:10.

Acknowledgements: The authors wish to acknowledge the cooperation of the doctors of the Department of Obstetrics & Gynaecology, University of Kiel, for their participation in the surgical procedures: D. Weisner, E. Lehmann-Willenbrock, M. Ibrahim, G. Caesar, T. Schollmeyer, D. Vogler, G. Meyer-Haass, K. Brandenburg and U. Schüppler.
Source of financial support: Dept. of Obstetrics & Gynecology, University of Kiel.