Clin Orthop Relat Res (2010) 468:3240–3247
DOI 10.1007/s11999-010-1367-8

SYMPOSIUM: PAPERS PRESENTED AT THE 2009 CLOSED MEETING OF THE INTERNATIONAL HIP SOCIETY

Cemented Total Hip Arthroplasty With Subtrochanteric Osteotomy in Dysplastic Hips

Colin R. Howie FRCSEd, Nicholas E. Ohly MRCSEd, Ben Miller FRACS

Published online: 12 May 2010
© The Association of Bone and Joint Surgeons® 2010

Abstract

Background Total hip arthroplasty (THA) in the presence of developmental dysplasia of the hip (DDH) can be technically challenging. Restoring the anatomic center of hip rotation may require femoral osteotomy. Techniques using cementless components are widely reported but less is known about using cemented components that may be more appropriate with osteopenic bone.

Questions/purposes We therefore determined the rate of union, complications, and early functional score in a series of patients with DDH who underwent cemented THA and simultaneous subtrochanteric osteotomy.

Methods We retrospectively reviewed 28 patients (35 hips) who underwent a cemented THA for DDH at a mean age of 47.3 years. Two patients (two hips) died within 12 months of surgery of unrelated conditions. The clinical notes and radiographs were reviewed with a minimum followup of 2 years (mean, 5.6 years; range, 2–14 years). Complications were noted. SF-12 and Oxford hip scores (OHS) were recorded for 18 patients preoperatively and after 6 and 12 months.

Results Union occurred in 32 of 33 femora (97%); one patient had an infected nonunion. The overall revision rate was 20% (9% femoral revision rate). There were three dislocations, two of which had further surgery. Two patients had a transient neuropraxia. The mean SF-12 physical component score increased from 32 to 52 and mean SF-12 mental component score increased from 48 to 51. The mean OHS decreased from 40 to 27.

Conclusion Combined subtrochanteric osteotomy and cemented THA is technically demanding with a higher complication rate than routine THA. The rate of union, complications, implant survival, and early OHS were comparable to those for similar techniques using cementless components.

Level of Evidence Level IV, therapeutic study. See Guidelines for Authors for a complete description of levels of evidence.

One or more of the authors (BM) or a member of his or her immediate family received, in any 1 year, payments or benefits in excess of $10,000 or a commitment or agreement to provide such benefits from a commercial entity (Stryker Australia).
Each author certifies that his or her institution approved the human protocol for this investigation, that all investigations were conducted in conformity with ethical principles of research, and that informed consent for participation in the study was obtained.

C. R. Howie (✉), N. E. Ohly, B. Miller
Department of Orthopaedic Surgery, Royal Infirmary of Edinburgh, 51 Little France Crescent, Edinburgh, EH16 4SA, UK
e-mail: colin.howie@luht.scot.nhs.uk; nickohly@gmail.com

Introduction

THA in the presence of severe developmental dysplasia of the hip (DDH) is technically demanding and presents many challenges to the surgeon on both the femoral and acetabular sides. During acetabular reconstruction of the dysplastic adult hip, it is acknowledged that the anatomic center of hip rotation should be restored [20, 27, 36], although the difficulties in identifying and preparing the true acetabulum and achieving stable fixation of the acetabular component are well described [7, 10, 13, 16, 28]. On the femoral side, there are further technical challenges, including excessive femoral neck anteversion resulting in a posterior position of the greater trochanter and chronic shortening of the surrounding soft tissue structures. Restoration of the proximal femoral anatomy is important to allow enhanced abductor function. In restoring the center of hip rotation, the leg may be lengthened by over 4 cm

leading to difficulty in reducing the hip and a major risk of neurologic traction injury [7], particularly where there is scarring from previous surgery [15] which increases the risk of direct or indirect neurologic injury [12]. Furthermore, the femoral canal diameter is frequently narrow, which adds to the difficulty of obtaining stable implantation of an adequately sized femoral component [18, 25, 26, 34].

To address these concerns during THA for severe dysplasia, many surgeons advocate subtrochanteric femoral osteotomy [1–4, 6, 13, 19, 21, 22, 24, 26, 28–32, 35]. Using this technique, femoral length, angulation, and greater trochanter position can be addressed concurrently. Furthermore, osteotomy at this level allows easier access to plates and screws retained from previous osteotomies that may need to be removed. The majority of published series reporting THA with proximal femoral osteotomy have used exclusively cementless femoral components (Table 1). The studies suggest using cementless components leads to a high rate of union and major improvements in the postoperative Harris hip score, although the relatively high complication rate when compared with THA alone is acknowledged. A further five published series include the results of THA combined with subtrochanteric osteotomy using a mixture of cemented and cementless femoral components (Table 1); however, there are only 22 cemented femoral stems in these studies combined. These reports suggest similar union rates, complication rates, and survivorship for cemented stems compared with cementless components; however, the number of cemented components in these series was very small. Techniques using cemented components may be more appropriate in the presence of osteopenic bone or if the surgeon is not familiar with cementless components.

Therefore, our purpose was to determine the rate of union, complications, and the early SF-12 health survey [33] and Oxford Hip Score (OHS) [8] in a series of cemented THA and simultaneous subtrochanteric osteotomy in dysplastic hips.

Patients and Methods

This was a retrospective longitudinal cohort study of all 28 patients (35 hips) who underwent primary cemented THA with simultaneous subtrochanteric osteotomy between March 1995 and August 2006. The indication for surgery was painful osteoarthritis secondary to severe DDH (Crowe Grade III or IV [7]) in all cases. The mean age at surgery was 47.3 years (range, 26–75 years). Previous osteotomies had been performed in 19 patients (24 hips [69%]), nine femoral, five pelvic, and 10 both femoral and pelvic. Retained femoral metalwork was present in five hips (14%). Twenty-six of the 28 patients (33 hips) were last followed up between 2 and 14 years after surgery (mean, 5.6 years). Two patients (two hips) died within 12 months of unrelated causes.

Subtrochanteric osteotomy was performed either to shorten the femur (28 hips [80%]) or to correct proximal femoral deformity (varus or rotational) and/or to allow access to retained intramedullary metalwork (seven hips [20%]). In the 28 hips in which the femur was shortened, the average length of bone removed was 2.4 cm (range, 1–7 cm).

All operations were performed by the senior author (CRH) using a modified version of the technique described by Reikeraas et al. [30] with cemented femoral and acetabular components and using an all-polyethylene cup and a polished tapered stem in all cases. No custom-made implants were required. A posterior approach to the hip was used with distal extension to access the proximal femoral shaft. The sciatic nerve was identified and carefully protected but not formally dissected unless adherent to a pelvic osteotomy. After identification of the true acetabulum, the acetabulum was prepared in the standard manner with a structural femoral head autograft to provide adequate superior coverage where necessary (12 hips [34%]). The acetabular component was then implanted after cement pressurization.

Femoral osteotomy was delayed until after implantation of the acetabular component to allow easy control of the femur for acetabular and proximal femoral preparation. The vastogluteal sling was kept intact, but the iliopsoas tendon was released and a total capsulectomy performed. A transverse osteotomy was performed just distal to the lesser trochanter and perpendicular to the femoral shaft. A high-speed burr was used retrogradely to prepare the proximal femoral fragment and occasionally the distal fragment to allow insertion of the femoral rasps. The femoral component with the largest offset, which best fit the proximal fragment, was chosen. The proximal fragment was reduced to ensure the abductors allowed normal positioning of the femoral component. An abductor release or trochanteric slide was not required in this series. Traction was applied to the distal fragment, the amount of overlap between the proximal and distal fragments was noted, and the corresponding length of bone was resected from the distal fragment to allow reduction of the final construct (Fig. 1). Any required angular correction was achieved by incorporating a wedge into the resection perpendicular to the axis of the greater trochanter. Using standard femoral rasps, the distal fragment was prepared taking into account any rotational correction that was necessary to position the greater trochanter in the same plane as the epicondylar axis of the knee. The fragments were reduced and the appropriate femoral trial was introduced across the osteotomy, which was compressed with bone reduction forceps. Using a short one-third tubular plate applied posteriorly, temporary fixation was achieved

Table 1. Overview of previous studies of THA with subtrochanteric osteotomy

Author	Number	Mean age (years; range)	Mean followup (years)	Stem type	Union (%)	Total revisions (%)	Femoral revisions (%)	Dislocations (%)	Deep infections (%)	Neurologic injury (%)	Intraoperative femoral fracture (%)	Preoperative HHS	Postoperative HHS
Paavilainen et al. 1990 [26]	46	50 (22–78)	3.2 (1–5.9)	Cementless	44 (96%)	8 (17%)	3 (7%)	2 (4%)	1 (2%)	NS	5 (11%)	N/A	N/A
Becker et al. 1995 [1]	7	61 (48–72)	2.7 (0.3–6)	Cementless	7 (100%)	1 (14%)	0	0	0	0	0	N/A	N/A
Reikeraas et al. 1996 [30]	21	54 (17–67)	5 (3–7)	Cementless	21 (100%)	0	0	0	0	1 (4%)	0	43 (29–69)	93 (65–98)
	4			Cemented	4 (100%)								
Papagelopoulos et al. 1996 [28]	15	51 (24–82)	4.8 (2–11)	Cementless	12 (80%)	6 (30%)	3 (20%)	3 (15%)	1 (5%)	N/A	4 (20%)	51 (34–76)	77 (40–98)*
	5			Cemented	5 (100%)		1 (20%)						
Yasgur et al. 1997 [35]	7	42 (22–77)	3.6 (2–6.9)	Cementless	6 (86%)	1 (14%)	1 (14%)	1 (14%)	0	0	0	N/A	N/A
	2			Cemented	2 (100%)	0	0	0					
Chareancholvanich et al. 1999 [6]	14	54 (21–74)	5.5 (2–8.5)	Cementless	14 (100%)	1 (7%)	0	0	0	0	0	49 (37–79)	86 (63–95)
	1			Cemented	1 (100%)								
Bruce et al. 2000 [3]	9	53 (26–77)	4.7 (0.5–7.2)	Cementless	9 (100%)	2 (22%)	1 (11%)	1 (11%)	0	0	2 (22%)	31 (20–25)	81 (60–98)
Sener et al. 2002 [31]	28	43 (26–64)	4.0 (0.6–7.7)	Cementless	26 (93%)	2 (7%)	2 (7%)	0	2 (7%)	3 (11%)	0	37 (20–65)	95 (82–100)
Masonis et al. 2003 [21]	11	49 (21–70)	5.8 (2–11.2)	Cementless	10 (91%)	5 (24%)	1 (9%)	0	0	0	0	33 (22–45)	74 (42–100)
	10			Cemented	9 (90%)		2 (20%)	3 (30%)					
Carlsson et al. 2003 [4]	22	55 (23–80)	2.1 (0.7–7.8)	Cementless	22 (100%)	5 (23%)	2 (9%)	3 (14%)	0	0	0	42 (25–68)	86 (60–97)
Onodera et al. 2006 [24]	14	55 (44–69)	5 (3–7.9)	Cementless	13 (93%)	1 (7%)	1 (7%)	1 (7%)	0	NS	6 (43%)	38 (15–56)	82 (35–93)
Eskelinen et al. 2006 [13]	61	54 (29–74)	12.3 (9–15)	Cementless	58 (95%)	29 (43%)	5 (7%)	3 (4%)	0	5 (7%)	4 (6%)	54 (13–85)	84 (34–100)†
Park et al. 2007 [29]	24	49 (20–66)	4.7 (2–7.6)	Cementless	21 (88%)	4 (17%)	3 (13%)	1 (4%)	0	0	3 (13%)	35.6	81.7‡
Bernasek et al. 2007 [2]	23	43 (17–67)	8 (5–14)	Cementless	23 (100%)	4 (18%)	0	4 (18%)	0	0	0	42	82
Nagoya et al. 2009 [22]	20	55 (44–69)	8.1 (4–11.5)	Cementless	19 (95%)	2 (10%)	2 (10%)	0	0	0	2 (20%)	N/A	N/A
Krych et al. 2009 [19]	28	48 (30–72)	4.8 (2–13.4)	Cementless	26 (93%)	7 (25%)	4 (14%)	4 (14%)	0	0	5 (18%)	N/A	N/A
Howie et al. (current study)	35	47 (26–75)	5.6 (2–14)	Cemented	33 (97%)	7 (20%)	3 (9%)	3 (9%)	1 (3%)	2 (6%)	0	40.2§	26.7§

* Score for the 14 patients who did not require revision; †Harris hip scores for cohort of 68 patients (seven did not undergo shortening osteotomy and were not included in other analyses); ‡score for the 20 patients who did not require revision; §Oxford Hip Score; HHS = Harris hip score; NS = nonsignificant; N/A = data not given by authors.

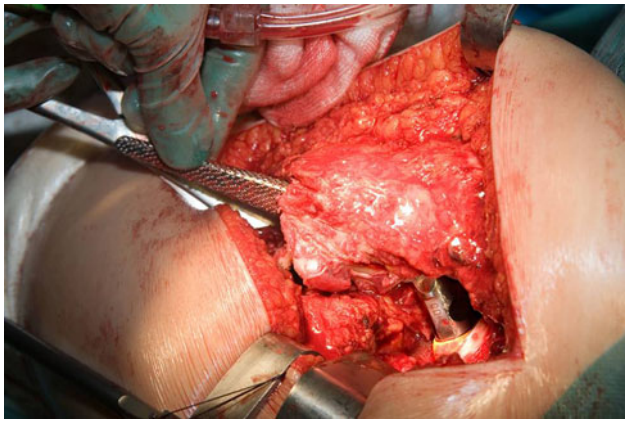

Fig. 1 Intraoperative photograph showing the proximal fragment reduced, traction being applied to the distal fragment, and the amount of overlap for femoral resection measured.

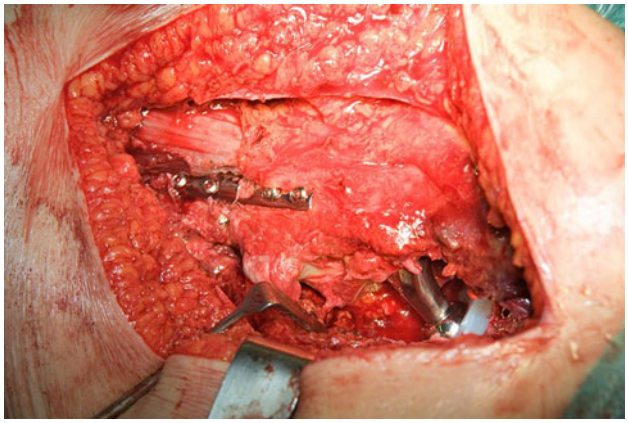

Fig. 2 Intraoperative photograph showing the final construct with definitive implants and one-third tubular plate in situ.

with a combination of uni- and bicortical screws (Fig. 2). The definitive component was then implanted using a third-generation cementing technique. The assistant's fingers were wrapped around the anterior aspect of the osteotomy to prevent cement escape and to provide compression of the anterior aspect by pulling gently in a posterior direction, thereby applying some tension to the third tubular plate. After curing, excess cement was removed with an osteotome and the osteotomy site was packed with an autologous morselized bone graft. The plate was left in situ.

The patients were mobilized from the first postoperative day under the supervision of the physical therapy team who attended for 30 minutes at least twice daily during the inpatient stay. Patients were allowed to partially weight-bear for the first 6 weeks with the aid of a walking frame or two walking sticks and could use these aids thereafter as desired. Formal outpatient physical therapy was arranged after discharge on an individualized basis and focused on abductor strengthening exercises. Most of this rehabilitation was patient-led after the initial physical therapy sessions as an inpatient.

Patients were reviewed in the outpatient department 6 weeks, 3 months, 6 months, and 12 months after surgery. Further followup was on an individualized basis and some of the patients who were referred from outside our region declined to attend for further review. In 18 patients (64%), the OHS [8] and SF-12 scores [33] were recorded preoperatively and at 6 and 12 months after surgery. At each followup visit, the patients were assessed clinically and AP and lateral radiographs of the hips were obtained. For the purposes of this study, union of the osteotomy and complications were evaluated after review of the clinical notes and radiographs of these patients in August 2009. Union was defined as the presence of mature bone bridging the osteotomy on at least three of four cortices as seen on AP and lateral radiographs and confirmed independently by two of the authors (CRH, BM) (Fig. 3A–B). Complications were defined as deep infection (requiring reoperation), dislocation, neurologic injury (temporary or permanent), intraoperative fracture, periprosthetic fracture, revision for any reason, or death for any reason.

Results

Thirty-two of 33 osteotomies in the 26 living patients united (97%); there was one infected nonunion (two patients died and were not included in the analysis of bony union). The nonunion was the result of a recrudescent infection at the osteotomy site and the pathogenic organism was the same Staphylococcus aureus isolated at the time of previous proximal femoral osteotomy, which became infected. This patient had retained metalwork embedded in the lateral femur and attempted removal at the time of surgery had caused major iatrogenic trauma to the femoral cortex and its blood supply. The patient underwent single-stage revision to a proximal femoral replacement at 8 months and remained on suppressive antibiotics with no clinical sign of infection 5 years later.

There were 12 complications in nine patients (26%) (Table 2). Two patients died within 12 months of surgery; one had a periprosthetic femoral fracture after 3 weeks, which was revised to a proximal femoral replacement. Having recovered from this procedure, the patient died from pneumonia 12 months later. The other patient died from pneumonia 6 weeks after surgery. There were three dislocations, all in the early postoperative period. One patient was treated with a brace and had no further dislocations. The second had recurrent dislocations and underwent acetabular revision 9 days postoperatively. After trimming the posterior lip of the all-polyethylene

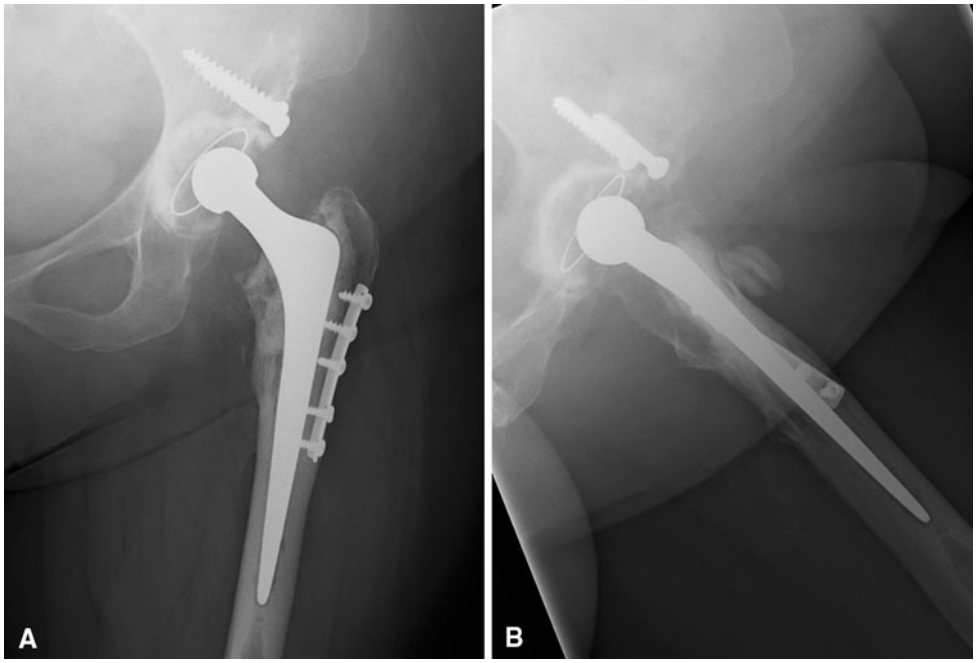

Figs 3A–B (**A**) AP and (**B**) lateral radiographs taken 13 years after surgery showing union as confirmed by the presence of mature bone bridging the osteotomy site on all four cortices.

Table 2. Major complications

Complication	Total	Requiring revision
Infected nonunion	1	1
Dislocation	3	2
Transient neuropraxia	2	0
Death	2	0
Aseptic acetabular loosening	2	2
Periprosthetic fracture	2	2
Total	12	7

acetabular component, there were no further dislocations; however, this patient sustained a Vancouver Type B1 fracture 5 months later, which required open reduction and internal fixation. The osteotomy was noted to have united at this time. The third patient with recurrent dislocations underwent acetabular revision 4 weeks postoperatively, placing the lip superiorly and reducing the anteversion. There were three further dislocations in the 4 months after revision, which were treated without reoperation; however, after 6 years, further acetabular revision was required for aseptic loosening. There was one other acetabular revision for linear wear and aseptic loosening after 8 years. There were no revisions for aseptic femoral loosening. In the 33 surviving hips, the femoral components remained well fixed at last followup. The total revision rate was 20% at 5.6 years (9% femoral revision rate). There were two transient nerve palsies, one sciatic and one femoral, both of which resolved with no residual deficit. Both patients had undergone previous pelvic surgery and were noted not to have been excessively lengthened (less than 3 cm).

Within the subgroup of 18 patients, the mean SF-12 physical component score increased from 31.6 to 52.1 and mean SF-12 mental component score increased from 48 to 51.2. The mean OHS decreased from 40.2 to 26.7 (Table 3).

Discussion

Although series describing this technique using cementless components are widely reported in the literature (Table 1), there is little reported on the technique using cemented components, which we believe has a useful role in the presence of poor-quality bone or in the hands of a surgeon who is unfamiliar with cementless components. The purpose of our study was therefore to determine the union rate, complications, and early OHS and SF-12 scores in a single-surgeon series of patients undergoing cemented THA and simultaneous subtrochanteric osteotomy for hip dysplasia.

We recognize there are a number of major limitations to the current study. First, the number of patients is relatively small. However, the indication for this procedure is relatively uncommon and it is difficult to obtain a larger series from a single institution. Second, the method of assessing radiographic union was not robust because there was no analysis of interobserver reliability; however, other recent studies [13, 19, 24, 29] used similar nonrobust methods to assess union and while healing times cannot be determined, we believe our final assessment of union is valid given the radiographic appearances and absence of symptoms. Third, leg lengths were not routinely recorded in these patients and hence were not included as part of this study; therefore, we cannot comment on restoration of limb length. Fourth,

Table 3. Clinical scores before and after surgery

Outcome measure	Preoperative		6 months postoperative		12 months postoperative	
	DDH	Case-matched	DDH	Case-matched	DDH	Case-matched
SF-12–physical	31.6	29.1	37.7	41.1	52.1	42.2
SF-12–mental	48.0	45.9	49.1	52.4	51.2	50.2
Oxford Hip Score	40.2	43.0	28.7	23.6	26.7	24.0

DDH = developmental dysplasia of the hip.

SF-12 and OHS were available for only 18 patients and for only the first 12 months postoperatively; hence, the data may not reflect that of the entire group and are limited for comparison to other series. However, the union rate, complications, and survivorship arise from the full series.

Our union rate of 97% is similar to reported figures for both cemented and cementless stems (Table 1) and suggests, in terms of achieving union, our technique is comparable to those previously reported.

We had similar complication rates after simultaneous subtrochanteric osteotomy and THA to those of others for both cemented and cementless stems (Table 1). All three dislocations were anterior, which occurred early in our series and were believed to be secondary to excessive acetabular component anteversion, which had been an attempt to reduce the risk of posterior dislocation subsequent to using the posterior approach. Consequently, and with an increased appreciation of the importance of restoring the abductor lever arm through the derotation element of the osteotomy, we were able to avoid further dislocations by restoring the proximal femoral anatomy and aiming to place the acetabulum in anatomic version.

The sole nonunion was the result of reactivation of latent infection at the osteotomy site after attempted removal of ingrown metalwork. Consequently, in the other four hips in this series with retained femoral metalwork, the screws were burred just enough to allow the femoral component to be implanted with cement and no attempt was made to completely remove the metalwork. Onodera et al. [24] noted similar problems and likewise recommended removal of preexisting metalwork only when it was essential to be able to implant the new component. We recognize this may be unsuitable with cementless stems because it may give rise to stress concentrations and possible galvanic corrosion. The specific additional difficulties in performing THA in the presence of retained metalwork after previous pelvic and femoral osteotomy have been formally acknowledged in a recently published paper [14] in which femora and acetabula with retained metalwork are given a separate classification, and we believe this may provide some advantages to current systems [7, 17], which use a combined assessment of the acetabulum and femur and which ignore femoral geometry.

There were two transient nerve palsies in our series. By shortening the femur during THA of the dysplastic hip, it is hoped that the incidence of nerve palsy is reduced [10]. Various authors have recommended lengthening the femur less than 4 cm [11, 23], although Eggli et al. [12] noted mechanical trauma, rather than limb lengthening, most commonly caused nerve injury in this situation. It is nonetheless recognized that this procedure does carry an inherent increased risk of nerve palsy.

There were no intraoperative femoral fractures in our series. Reported rates of using cementless stems in dysplastic femora are as high as 20% [3, 22, 24, 28]. Paavilainen et al. recommended prophylactic splitting of the proximal femoral shaft [26] and in poor-quality bone, Bruce et al. [3] recommended using cement. Despite the increased risk of intraoperative fracture, most authors have preferred cementless fixation [1–4, 13, 19, 22, 24, 26, 29, 31], possibly because patients with DDH require arthroplasty at a relatively young age and early reports of cemented THA in younger patients described problems with aseptic loosening [5, 9, 16]. Furthermore, some authors believe cementless femoral components allow greater control of anteversion, independent of the stability of both fragments [24]. The overall revision rate was 20% at a mean of 5.6 years, which is comparable with the published data (Table 1).

To give context to the SF-12 and OHS in our series, they were compared with an age- and gender-matched group of 110 patients undergoing primary THA in our institution over the same period (Table 3). It is noteworthy that the improvement in outcome was most evident after 12 months rather than by 6 months as seen after routine primary hip arthroplasty and we believe this represents the slower rehabilitation after what is as much a soft tissue procedure as an arthroplasty procedure.

THA with subtrochanteric osteotomy is an infrequently performed procedure (0.1%–0.3% of all THAs at the Mayo Clinic [19, 28]), and even in specialist centers, it is associated with increased complication rates (Table 1). Ours is a relatively large series of cemented THA with subtrochanteric osteotomy and suggests the rate of union, complications, and revision rate using this technique are comparable to those for cementless techniques. We found

high functional scores (SF-12 and OHS) and survival, at least in the short- to midterm. There is little known on the long-term survival of these complex arthroplasties, regardless of the fixation technique, and further followup is required. We believe the surgeon should implant his or her usual prosthesis to obtain the best long-term results for this uncommon and challenging procedure, and the findings of this study support the use of cemented components.

References

1. Becker DA, Gustilo RB. Double-chevron subtrochanteric shortening derotational femoral osteotomy combined with total hip arthroplasty for the treatment of complete congenital dislocation of the hip in the adult. *J Arthroplasty.* 1995;10: 313–318.
2. Bernasek TL, Haidukewych G, Gustke K, Hill O, Levering M. Total hip arthroplasty requiring subtrochanteric osteotomy for developmental hip dysplasia: 5- to 14-year results. *J Arthroplasty*. 2007;22(Suppl 2):145–150.
3. Bruce WJM, Rizkallah SM, Kwon Y-M, Goldberg JA, Walsh WR. A new technique of subtrochanteric shortening in total hip arthroplasty. *J Arthroplasty.* 2000;15:617–626.
4. Carlsson A, Bjorkman A, Ringsberg K, von Schewelov T. Untreated congenital and posttraumatic high dislocation of the hip treated by replacement in adult age: 22 hips in 16 patients followed for 1–8 years. *Acta Orthop Scand*. 2003;74:389–396.
5. Chandler HP, Reineck FT, Wixson RL, McCarthy JC. Total hip replacement in patients younger than thirty years old: a five-year follow-up study. *J Bone Joint Surg Am*. 1981;63:1426–1434.
6. Chareancholvanich K, Becker DA, Gustilo RB. Treatment of congenital dislocated hip by arthroplasty with femoral shortening. *Clin Orthop Relat Res*. 1999;360:127–135.
7. Crowe JF, Mani VJ, Ranawat CS. Total hip replacement in congenital dislocation and dysplasia of the hip. *J Bone Joint Surg Am*. 1979;61:15–23.
8. Dawson R, Fitzpatrick J, Carr A, Murray D. Questionnaire on the perceptions of patients about total hip replacement. *J Bone Joint Surg Br*. 1996;78:185–190.
9. Dorr LD, Takei GK, Conaty JP. Total hip arthroplasties in patients less than forty-five years old. *J Bone Joint Surg Am*. 1983;65:474–479.
10. Dunn HK, Hess WE. Total hip reconstruction in chronically dislocated hips. *J Bone Joint Surg Am*. 1976;58:838–845.
11. Edwards BN, Tullos HS, Nobel PC. Contributory factors and etiology of sciatic nerve palsy in total hip arthroplasty. *Clin Orthop Relat Res*. 1987;218:136–141.
12. Eggli S, Hankemayer S, Müller ME. Nerve palsy after leg lengthening in total replacement arthroplasty for developmental dysplasia of the hip. *J Bone Joint Surg Br*. 1999;81:843–845.
13. Eskelinen A, Helenius I, Remes V, Ylinen P, Tallroth K, Paavilainen T. Cementless total hip arthroplasty in patients with high congenital hip dislocation. *J Bone Joint Surg Am*. 2006;88:80–91.
14. Gaston MS, Gaston P, Donaldson P, Howie CR. A new classification system for the adult dysplastic hip requiring total hip arthroplasty: a reliability study. *Hip Int.* 2009;19:96–101.
15. Haddad FS, Masri BA, Garbuz DS, Duncan CP. Primary total replacement of the dysplastic hip. *Instr Course Lect*. 2000;49: 23–39.
16. Halley DK, Wroblewski BM. Long term results of low-friction arthroplasty in patients 30 years of age or younger. *Clin Orthop Relat Res*. 1986;211:43–50.
17. Hartofilakidis G, Stamos K, Karachalios T, Ioannidis T, Zacharakis N. Congenital hip disease in adults. Classification of acetabular deficiencies and operative treatment with acetabuloplasty combined with total hip arthroplasty. *J Bone Joint Surg Am*. 1996;78:683–692.
18. Koulouvaris P, Stafylas K, Sculco T, Xenakis T. Distal femoral shortening in total hip arthroplasty for complex primary hip reconstruction. A new surgical technique. *J Arthroplasty*. 2008;23:992–998.
19. Krych AJ, Howard JL, Trousdale RT, Cabanela ME, Berry DJ. Total hip arthroplasty with shortening subtrochanteric osteotomy in Crowe type-IV developmental dysplasia. *J Bone Joint Surg Am*. 2009;91:2213–2221.
20. Linde F, Jensen J, Pilgaard S. Charnley arthroplasty in osteoarthritis secondary to congenital dislocation or subluxation. *Clin Orthop Relat Res*. 1988;227:164–171.
21. Masonis JL, Patel JV, Miu A, Bourne RB, McCalden R, Macdonald SJ, Rorabeck CH. Subtrochanteric shortening and derotational osteotomy in primary total hip arthroplasty for patients with severe hip dysplasia 5-year follow-up. *J Arthroplasty*. 2003;18(1):68–73.
22. Nagoya S, Kaya M, Sasaki M, Tateda K, Kosukegawa I, Yamashita T. Cementless total hip replacement with subtrochanteric femoral shortening for severe developmental dysplasia of the hip. *J Bone Joint Surg Br*. 2009;91:1142–1147.
23. Nercessian OA, Macaulay W, Stinchfield FE. Peripheral neuropathies following total hip arthroplasty. *J Arthroplasty*. 1994;9:645–651.
24. Onodera S, Majima T, Ito H, Matsuno T, Kishimoto T, Minami A. Cementless total hip arthroplasty using the modular S-ROM prosthesis combined with corrective proximal femoral osteotomy. *J Arthroplasty*. 2006;21:664–669.
25. Paavilainen T, Hoikka V, Paavolainen P. Cementless total hip arthroplasty for congenitally dislocated or dysplastic hips. Technique for replacement with a straight femoral component. *Clin Orthop Relat Res*. 1993;297:71–81.
26. Paavilainen T, Hoikka V, Solonen KA. Cementless total replacement for severely dysplastic or dislocated hips. *J Bone Joint Surg Br.* 1990;72:205–211.
27. Pagnano MW, Hanssen AD, Lewallen DG, Shaughnessy WJ. The effect of superior placement of the acetabular component on the rate of loosening after total hip arthroplasty: long-term results of patients who have Crowe type II congenital dysplasia of the hip. *J Bone Joint Surg Am*. 1996;78:1004–1014.
28. Papagelopoulos PJ, Trousdale RT, Lewallen DG. Total hip arthroplasty with femoral osteotomy for proximal femoral deformity. *Clin Orthop Relat Res*. 1996;332:151–162.
29. Park M-S, Kim K-H, Jeong W-C. Transverse subtrochanteric shortening osteotomy in primary total hip arthroplasty for patients with severe hip developmental dysplasia. *J Arthroplasty*. 2007;22:1031–1036.
30. Reikeraas O, Lereim P, Gabor I, Gunderson R, Bjerkreim I. Femoral shortening in total arthroplasty for completely dislocated hips: 3-7 year results in 25 cases. *Acta Orthop Scand*. 1996;67:33–36.
31. Sener N, Tozun I, Asik M. Femoral shortening and cementless arthroplasty in high congenital dislocation of the hip. *J Arthroplasty*. 2002;17:41–48.
32. Symeonides PP, Pournaras J, Petsatodes G, Christoforides J, Hatzokos I, Pantazis E. Total hip arthroplasty in neglected congenital dislocation of the hip. *Clin Orthop Relat Res*. 1997; 341:55–61.

33. Ware JE, Kosinski M, Keller SD. A 12-item Short-Form health survey: construction of scales and preliminary tests of reliability and validity. *Med Care*. 1996;34:220–233.
34. Woolson ST, Harris WH. Complex total hip replacement for dysplastic or hypoplastic hips using miniature or micro-miniature components. *J Bone Joint Surg Am*. 1983;65: 1099–1108.
35. Yasgur DJ, Stuchin SA, Adler EM, DiCesare PE. Subtrochanteric femoral shortening osteotomy in total hip arthroplasty for high-riding developmental dislocation of the hip. *J Arthroplasty*. 1997;12:880–888.
36. Yoder SA, Brand RA, Pederson DR, et al. Total hip acetabular component position affects acetabular loosening rates. *Clin Orthop Relat Res*. 1988;228:79–87.