Article

Gastropexy with an automatic stapling instrument for the treatment of gastric dilatation and volvulus in 20 dogs

Gerardo A. Belandria, Michael M. Pavletic, James P. Boulay, Dominique G. Penninck, Leslie A. Schwarz

Abstract — Surgical stapling equipment was used to create a gastropexy in 20 dogs undergoing emergency surgery for gastric dilatation and volvulus (GDV). The technique involved creation of a tunnel between the seromuscular layer and the submucosa of the pyloric antrum, and a matching tunnel beneath the right m. transversus abdominis. The arms of a gastrointestinal anastomosis stapling device were introduced into the tunnels, and the device was fired to create the gastropexy. One dog died of systemic sequelae of GDV during the early postoperative period. None of the remaining 19 dogs developed a recurrence of GDV during follow-up periods ranging from 5 to 43 months. In 11 dogs, the integrity of the gastropexy was evaluated by abdominal ultrasonography and either negative contrast gastrography or double contrast gastrography; in these dogs, the radiographic and/or the ultrasonographic findings were suggestive of an intact gastropexy. There were no complications involving the gastropexy staple line. The results of this study indicate that an effective and consistent permanent gastropexy can be created, using surgical stapling equipment.

Résumé — Gastropexie avec un instrument d'agrafage automatique pour le traitement de la dilatation gastrique et du volvulus chez 20 chiens. De l'équipement d'agrafage chirurgical a été utilisé pour créer une gastropexie chez 20 chiens subissant une chirurgie d'urgence pour dilatation gastrique et volvulus (DGV). La technique a consisté à créer un tunnel entre la couche séromusculaire et la sous-muqueuse de l'antre du pylore et un tunnel correspondant sous le muscle transverse droit de l'abdomen. Les bras du dispositif d'agrafage pour l'anastomose gastro-intestinale ont été introduits dans les tunnels et le dispositif a été actionné pour créer la gastropexie. Un chien est mort de séquelles systémiques de DGV au début de la période postopératoire. Aucun des 19 autres chiens n'a développé une rechute de DGV durant les périodes de suivi allant de 5 à 43 mois. Chez 11 chiens, l'intégrité de la gastropexie a été évaluée par une échographie abdominale à contraste négatif ou par une gastrographie à double contraste; chez ces chiens, les résultats de la radiographie et/ou de l'échographie ont suggéré une gastropexie intacte. Il n'y a pas eu de complications liées à la ligne d'agrafage de la gastropexie. Les résultats de cette étude indiquent qu'une gastropexie permanente efficace et constante peut être créée en utilisant de l'équipement d'agrafage chirurgical.

(Traduit par Isabelle Vallières)

Can Vet J 2009;50:733–740

Introduction

Gastric dilatation and volvulus (GDV) is an acute, often fatal, syndrome of uncertain etiology occurring primarily in large, deep-chested breeds of dogs. The condition affects approximately 60 000 dogs annually in the United States (1). The pathophysiology and clinical course of acute GDV have been investigated extensively (2–8).

Various techniques of gastropexy have been used to prevent GDV in the dog (9–16). The basic goals of surgical treatment are 1) decompression and derotation of the stomach, and 2) permanent fixation of the stomach in a manner that does not interfere with gastric function (11). Surgical repositioning of the stomach without gastropexy has been reported to result in recurrence of GDV in 80% of cases (17,18). The overall mortality

Department of Clinical Sciences, School of Veterinary Medicine, Tufts University, 200 Westboro Road, North Grafton, Massachusetts 01536, USA (Belandria, Pavletic, Penninck, Schwarz); Department of Surgery, Angell Animal Medical Center, 350 South Huntington Avenue, Boston, Massachusetts 02130, USA (Boulay).

Address all correspondence to Dr. Gerardo A. Belandria; e-mail: vsp111@msn.com

Reprints will not be available from the author.

Use of this article is limited to a single copy for personal study. Anyone interested in obtaining reprints should contact the CVMA office (hbroughton@cvma-acmv.org) for additional copies or permission to use this material elsewhere.

Figure 1. Auto Suture GIA 50 PREMIUM surgical stapling instrument and Auto Suture GIA 50 PREMIUM disposable loading unit.

rate for dogs with GDV has been reported to range from 10% to 60% (2,8,19–25). Aggressive pre- and post-operative medical management lowers the mortality rate (21). The high mortality and recurrence rate make gastropexy an important aspect of the management of this disease.

Currently, the most widely used gastropexy techniques are incisional gastropexy (10,12), belt-loop gastropexy (14), and circumcostal gastropexy (15). Each of these techniques requires hand-suturing to produce a permanent adhesion of the stomach to the abdominal wall and do not require entrance into the gastric lumen. In 1999, Coolman (16) reported the use of a skin stapler for belt-loop gastropexy in dogs. Recently, gastropexy techniques that use laparoscopic instrumentation have been reported (26–29).

The use of automatic surgical stapling equipment gained widespread acceptance in human surgery during the 1970s (30). Stapling instruments are now used routinely in small animal surgery for a wide variety of abdominal and thoracic procedures (31–37). These instruments provide consistent, secure, and accurate mechanical apposition of tissues. Automatic stapling instruments have been documented to reduce anesthetic and operating time for a number of procedures (32–33,37).

In this paper, results of long-term follow-up evaluation of 20 dogs in which a gastropexy was performed with a gastrointestinal anastomosis stapling instrument as a part of the treatment of GDV are described.

Materials and methods

A gastrointestinal anastomosis stapling instrument (Auto Suture GIA 50 PREMIUM surgical stapling instrument; Covidien, Norwalk, Connecticut, USA) (Figure 1) was used to perform gastropexy in 20 dogs undergoing emergency surgery for the treatment of acute gastric dilatation-volvulus.

The gastrointestinal anastomosis stapling instrument used in this study is one of the most common and readily available stapling devices used in veterinary medicine. The instrument consists of 2 interlocking components that form a flat handle with 2 straight limbs. One limb accommodates the anvil; the opposing limb houses a presterilized disposable staple cartridge (38). The bladeless cartridge contains 52 staples of 0.20-mm diameter stainless steel wire arranged in 4 parallel staggered staple lines 53-mm long. Cartridges for the instrument are also available with a blade that divides between the 2nd and 3rd staple row. In this study, the bladeless cartridge was employed to create the staple gastropexy.

The stapling instrument is activated by following the manufacturer's recommendations. The stapler is partially coupled, the tissues to be anastomosed are placed between the 2 jaws, and the instrument is locked and fired. The staple leg length is 3.85 mm before closure and the staple height is approximately 1.50 mm when closed. The metallic staples consist of inert stainless steel that bends into a B shape when fired. The staples provide a degree of hemostasis without collapsing the vital

Table 1. Clinical data from 20 dogs treated with a stapling instrument for gastric dilatation and volvulus (GDV).

Case No.	Breed	Age (years)	Sex[a]	Ancillary procedures	Complications	Hospital days	Length of follow-up months	Outcome
1	Doberman	8	F/S	None	None	4	—	Discharged. Lost to follow-up.
2	Boxer	9	F/S	Splenectomy	Cardiac arrhythmias. Hypoalbuminemia. Melena. One episode of dilatation.	4	—	Arrested and died 4 d after surgery. No necropsy.
3	German shepherd	4	F/S	Gastrotomy	None	3	24	Discharged. Doing well. No GDV recurrence.
4	Great dane	7	M/C	None	None	3	19	Discharged. Doing well. No GDV recurrence. Flatulence.
5	Great dane	7	F/S	None	None	3	24	Discharged. Doing well. No GDV recurrence.
6	Golden retriever	7	M/C	None	Melena. Dilatation once.	3	27	Discharged. No GDV recurrence. Flatulence. Dilatation occasionally.
7	Neopolitan mastiff	8	M	Gastrotomy	Iatrogenic gastric perforation.	3	13	Discharged. Doing well. No GDV recurrence.
8	Great dane	6	F/S	None	None	3	42	Discharged. Doing well. No GDV recurrence.
9	Greyhound	8	M/C	None	Anemia	4	20	Discharged. Did well. No GDV recurrence. Euthanized 20 mo after surgery for seizures and DJD.
10	St. Bernard	1.5	F	Postoperative nasogastric tube	Dilatation twice	3	43	Discharged. No GDV recurrence. Dilatation occasionally.
11	Malamute	9	F/S	Partial gastrectomy	Anemia. Fever. Vomited once. Urinary tract infection.	6	5	Discharged. No GDV recurrence. Died of splenic hemangiosarcoma 5 mo after surgery.
12	German shepherd	5	M	None	None	4	19	Discharged. No GDV recurrence. Dilatation occasionally.
13	Mastiff	7	M/C	None	Anemia. Thrombocytopenia.	3	22	Discharged. No GDV recurrence. Flatulence. Dilatation occasionally. Infrequent vomiting and diarrhea.
14	Poodle	8	F/S	None	Melena	4	17	Discharged. Doing well. No GDV recurrence.
15	German shepherd	5	F/S	None	Iatrogenic gastric perforation.	3	16	Discharged. Doing well. No GDV recurrence. Flatulence.
16	Golden retriever	11	M/C	None	Melena	5	19	Discharged. No GDV recurrence. Flatulence. Dilatation occasionally. Infrequent vomiting and diarrhea.
17	Golden retriever	10	M/C	None	Melena	3	18	Discharged. Doing well. No GDV recurrence.
18	German shepherd	9	F/S	Splenectomy	Dilatation once	3	8	Discharged. Did well. No GDV recurrence. Euthanized for a mesenteric volvulus 10 mo post operatively. Necropsy performed.
19	Gordon setter	9	M	Blood transfusion	Hemoabdomen. Anemia. Incisional infection.	4	16	Discharged. Doing well. No GDV recurrence.
20	Samoyed	8	F/S	Plasma transfusion	Cardiac arrhythmias. DIC. Melena.	5	17	Discharged. Doing well. No GDV recurrence.

[a] F: female, F/S: female spayed, M: male, M/C: male castrated.
DIC — disseminated intravascular coagulation.
DJD — degenerative joint disease.

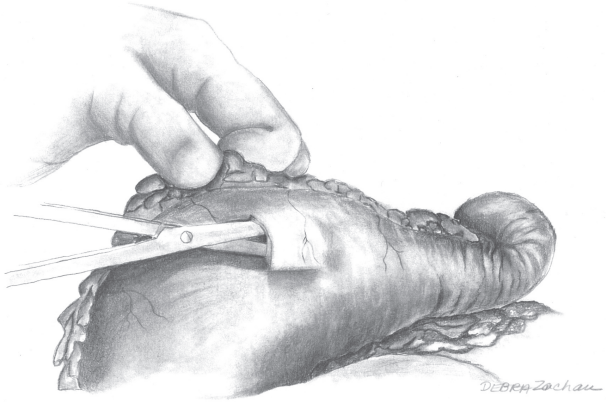

Figure 2. Dissection of the seromuscular tunnel in the pyloric antrum with Metzenbaum scissors.

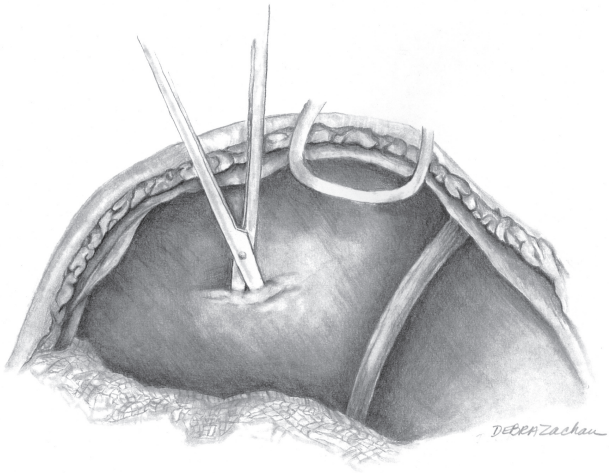

Figure 3. Dissection of the abdominal musculature tunnel beneath the right m. transversus abdominis with Metzenbaum scissors.

microcirculation of the apposed tissues, as they allow blood to flow in small vessels through the semicircular openings of each staple. The staggered double row of staples also allows consistent mechanical accuracy of tissue apposition and blood circulation between the individual staples to assure viability of the 2 or 3 mm of tissue beyond the staple line (38).

Thirteen dogs were treated at Tufts University School of Veterinary Medicine (TUSVM) and 7 dogs were treated at the Angell Animal Medical Center (AAMC). The signalments of the dogs are given in Table 1. Seven of the dogs had had 1 or more prior episodes of gastric dilatation or GDV, which had been managed medically in each case by the referring veterinarian.

Preoperative care

All dogs were presented to the emergency service with a history and physical examination findings consistent with GDV. Diagnostic confirmation was accomplished by abdominal radiography with the patient in right lateral recumbency. Radiographs showing gastric compartmentalization and dorsal displacement of the gastric pylorus relative to the gastric fundus confirmed the diagnosis of GDV. Emergency treatment in all dogs consisted of rapid IV infusion of an isotonic electrolyte solution at a rate of 45 mL/kg body weight (BW)/h via 1 or 2 cephalic vein catheters over the first 2 h. Gastric decompression was accomplished by orogastric intubation, or when orogastric intubation was unsuccessful, by percutaneous gastrocentesis with 1 or 2 20-gauge hypodermic needles. Intravenous fluid therapy was adjusted, thereafter, based on response to therapy. Surgery was performed after patient stabilization, usually within 4 h of presentation.

Preanesthetic evaluation included a physical examination, a complete blood cell count, and a serum biochemical profile to establish initial baseline values. Preoperatively, each dog was given cefazolin sodium (Faulding Pharmaceuticals, Elizabeth, New Jersey, USA), 20 mg/kg BW, IV. The anesthetic protocol consisted of premedication with butorphanol (Torbugesic; Fort-Dodge, Fort Dodge, Iowa, USA), 0.2 mg/kg BW, IM, and glycopyrrolate (Robinul; Robins, Richmond, Virginia, USA), 0.01 mg/kg BW, IM. Anesthesia was induced with diazepam (Valium; Roche, Nutley, New Jersey, USA), 0.3 mg/kg BW, IV, and ketamine (Vetalar; Parke-Davis, Morris Plains, New Jersey, USA), 5 mg/kg BW, IV, and maintained with isofluorane (Abbott Hospital, Abbott Park, Illinois, USA) in 100% oxygen via endotracheal tube. Lactated Ringer's solution (Abbott Hospital) was given, IV, at a rate of 10 mL/kg BW/h. Anesthetic monitoring included temperature, respiratory rate and effort, pulse, mucous membrane color and capillary refill time, electrocardiography, pulse oximetry, and indirect arterial blood pressure measurements.

Surgical technique

The dog was placed in dorsal recumbency and the abdomen was prepared for aseptic surgery. A ventral midline celiotomy was performed, with the incision extending caudally from the xiphoid cartilage to midway between the umbilicus and the pubis. Retraction of the abdominal incision was maintained with a Balfour retractor. The stomach was decompressed further by orogastric intubation or by gastrocentesis with 1 or more 20-gauge hypodermic needles attached to surgical suction to prevent leakage of gastric contents into the abdominal cavity. The stomach and spleen were returned to their correct anatomic positions and the peritoneal cavity was briefly lavaged with warm isotonic saline. A systematic evaluation of the abdominal cavity was performed. The remaining stomach contents were removed via orogastric intubation and repeated gastric lavage with isotonic saline solution. If gastric contents could not be removed, a gastrotomy was performed. Splenectomy was performed when thrombosis or avulsion of splenic vessels had resulted in splenic necrosis. Assessment of gastric wall viability was performed. Blackened or gray areas of the stomach wall that did not bleed or were thin on palpation were considered to be devitalized. Partial gastrectomy was performed when areas of devitalized gastric wall were identified. The pylorus was also inspected and palpated for abnormal thickening or stenosis.

The stomach was then elevated and retracted with stay sutures or Babcock forceps. A 1-cm long seromuscular incision was created on the parietal surface, perpendicular to the long axis of the stomach and equidistant between the greater and lesser

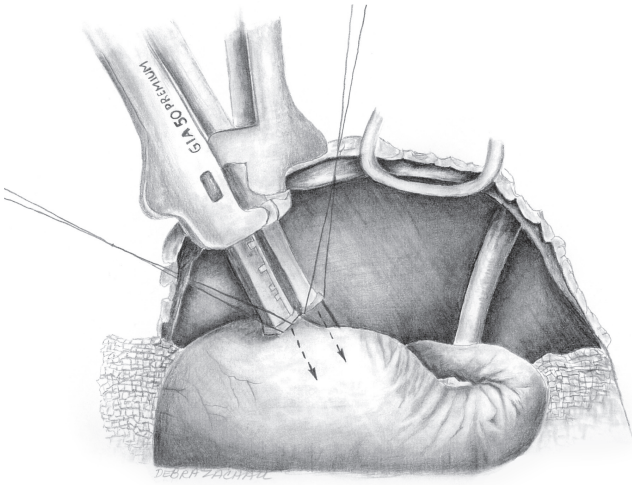

Figure 4. Insertion of the stapling instrument in the seromuscular tunnel of the stomach and the right abdominal wall tunnel.

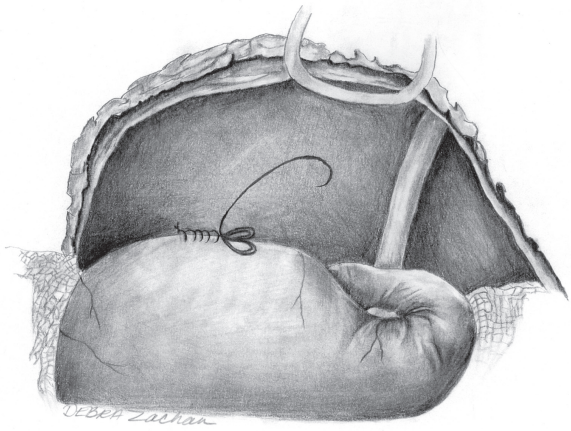

Figure 5. Closure of the openings of the tunnels in a simple continuous pattern with nonabsorbable suture material.

curvatures, in the center of the incisura angularis (the junction between the fundus and the pyloric antrum). A 6.0-cm long tunnel was carefully developed between the seromuscular layer and the submucosa by dissecting toward the pylorus using Metzenbaum scissors (Figure 2).

Fibers of the m. transversus abdominis and costal arch on the right side were identified. A 1-cm long stab incision was made through the parietal peritoneum and the m. transversus abdominis. The incision was made parallel to the ventral midline, centered approximately 3-cm caudal to the costal arch in the ventral 1/3rd of the abdominal wall. A 6.0-cm long tunnel was bluntly created with Metzenbaum scissors between the m. transversus abdominis and the m. obliquus internus abdominis, parallel to the last rib (Figure 3).

Stay sutures were placed in the borders of the gastric seromuscular tunnel and the m. transversus abdominis tunnel to facilitate insertion of the stapling device. The peritoneal and serosal surfaces overlying the tunnels were scarified with a scalpel blade.

The stapling instrument was loaded with a disposable cartridge (SGIA 50 PREMIUM, Auto Suture SGIA 50 PREMIUM disposable loading unit; Covidien), which does not contain a knife blade. One jaw of the instrument was inserted into the gastric tunnel and the other jaw was inserted into the abdominal musculature tunnel (Figure 4). Care was taken to assure that abdominal viscera and the omentum were not caught between the jaws prior to locking the instrument.

The instrument was closed and fired, delivering 4 53-mm long parallel rows of staples through the m. transversus abdominis and the seromuscular layer of the stomach (Figure 4). The staple line was inspected for staple security to prevent failure of the technique. The gastropexy was completed by apposing the access incisions with 2-0 nonabsorbable monofilament material (Prolene; Ethicon, Somerville, New Jersey, USA) in a simple continuous pattern to prevent undesirable abdominal adhesions (Figure 5). All surgical sites were reexamined before final abdominal lavage, and the laparotomy incision was closed in a routine manner.

Postoperative care

Dogs were transferred to the intensive care unit immediately after surgery, where they were monitored continuously for mucous membrane color, capillary refill time, hydration status, heart rate and rhythm, respiratory rate and effort, rectal temperature, urine output, and indirect arterial blood pressure, if necessary. Postoperative gastrointestinal function was also monitored, including signs of gastric distention, frequency and character of emesis, and bowel movement.

Electrocardiographic monitoring was performed continuously for a minimum of 72 h. When indicated, treatment of cardiac arrhythmias was instituted, based on currently accepted treatment standards (39). Hematologic and biochemical parameters, electrolytes, and arterial blood gases were monitored as necessary. Adequately hydrated patients were administered lactated Ringer's solution with potassium chloride (20 mEq/L) (Ceva, Overland Park, Kansas, USA, IV, at a maintenance rate (44–66 mL/kg BW/d). The rate of administration of IV fluids was reduced as dogs resumed eating and drinking and the hydration status was maintained. Additional supportive care, including blood products, synthetic colloids, dextrose, and oxygen, was supplemented as needed. Systemic antibiotics were continued until the patients were discharged from the hospital. In all dogs, analgesics were administered during the first 72 h postoperatively.

Twenty-four hours postoperatively dogs were offered small quantities of water PO, if no emesis or other gastrointestinal abnormalities had occurred. If the water trial was well tolerated, small amounts of a high digestible-low residue food (I/D; Hill's Pet Products, Topeka, Kansas, USA) were offered every 6–8 h. If vomiting occurred after oral intake of food or water, patients were given nothing PO for an additional 24 h and IV fluid therapy was continued. Dogs with persistent vomiting were treated with metoclopramide (Reglan; Robins, Richmond, Virginia, USA), 0.2 mg/kg BW, SC, q8h, often in combination with cimetidine (Tagamet; Glaxo Smithkline Pharmaceuticals, Philadelphia, Pennsylvania, USA), 10 mg/kg BW, IV, q8h, if there were no existing contraindications. Dogs were discharged from the hospital when cardiac arrhythmias were controlled, eating and drinking were normal, and no additional complications

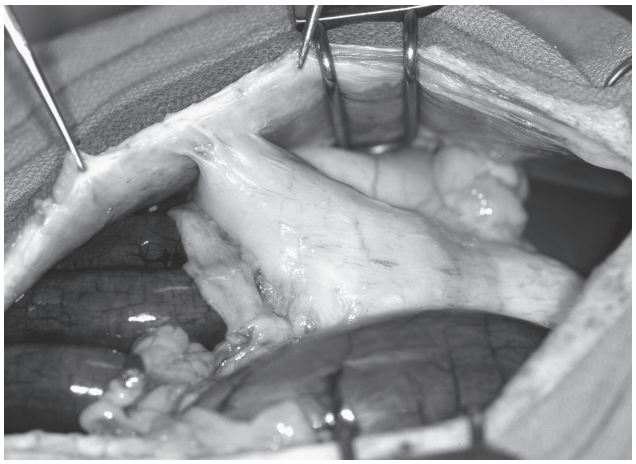

Figure 6. Intact gastropexy 10 mo after surgery in necropsy patient that died from a mesenteric volvulus.

were noted. Instructions to owners included exercise restriction for 7–10 d to allow healing of the incisions, dividing the dog's daily food requirement into 2 or 3 equal meals, and avoiding vigorous exercise 1 h before and 2 h after meals. Additional recommendation included water restriction after feedings, if overconsumption was a problem.

Follow-up examinations

Follow-up information was obtained in 17 dogs that were discharged from the hospital. Owners were asked by telephone questionnaire about the frequency of postoperative vomiting, diarrhea, eructation, weight loss, and recurrence of gastric dilation or GDV. For those dogs that had died, causes of death were determined by contacting the referring veterinarian or by postmortem evaluation at one of our hospitals.

In 11 dogs (8 at TUSVM and 3 at AAMC), an abdominal ultrasonograph and either negative contrast gastrography (n = 1) or double contrast gastrography (n = 10) was performed to evaluate the integrity of the gastropexy. A board certified radiologist carried out the ultrasonograph evaluations to determine the position of the stomach, the integrity of the metallic staples, and the absence of sliding motion at the gastropexy site. For the contrast study, air was introduced into the stomach via an orogastric tube at a dose of 20 mL/kg BW, or until the stomach was distended (40). In the double contrast gastrogram the air was followed by a 30% liquid barium sulfate suspension (Liquid Polibar, Westbury, New York, USA), 3 mL/kg BW, was then administered through the orogastric tube. Dorsoventral, ventrodorsal, and right and left lateral radiographs were obtained. Gastrograms were evaluated to determine gastric size and gastric positioning pre- and post-distention, staple line integrity, and the positioning of the staple line in relationship to the gastric and abdominal walls.

Results

The results of the study are summarized in Table 1. Of the 20 dogs, 1 dog (No. 2) died during the early postoperative period due to systemic sequelae of GDV. Two dogs were discharged from the hospital and lost to follow-up (No. 1, 7).

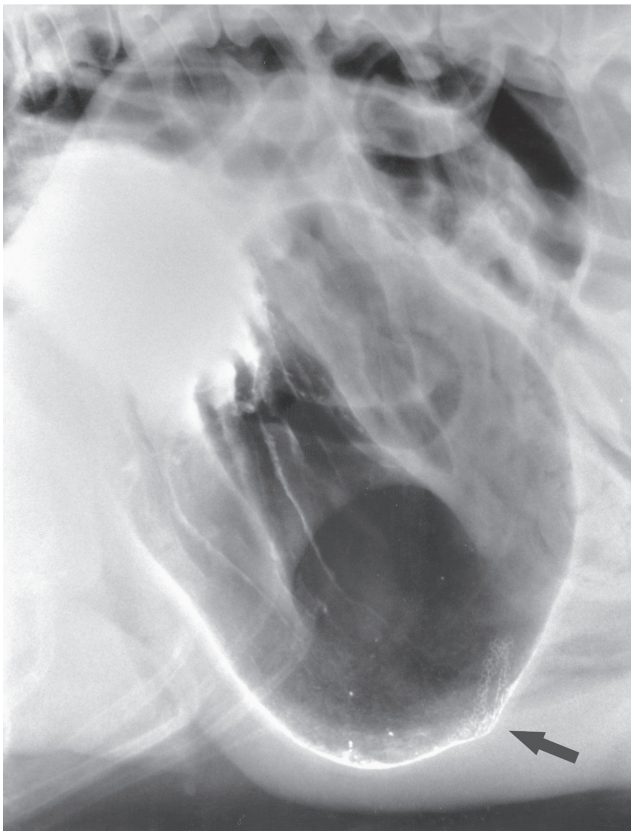

Figure 7. Right lateral radiograph of the abdomen indicating the staple line and a pointed appearance of the stomach suggesting an intact gastropexy.

Owners of the remaining 17 dogs were contacted by telephone to complete a questionnaire. Follow-up periods ranged from 5 to 43 mo with a mean of 20.9 mo. None of the 17 dogs had a recurrence of GDV. Three of these dogs died several months after surgery of conditions unrelated to the gastropexy. One dog (No. 9) was euthanized 20 mo after surgery due to seizures and severe arthritis. One dog (No. 11) died of splenic hemangiosarcoma 5 mo after surgery. One dog (No. 18) was euthanized 10 mo after surgery because of mesenteric volvulus. A necropsy in this dog confirmed an intact gastropexy (Figure 6). Histologic examination of the gastropexy site revealed well-organized, mature fibrous connective tissue forming broad adhesions between the peritoneal surface of the m. transversus abdominis and the gastric serosa. Fourteen dogs were still alive at the completion of the study.

The gastropexy technique was technically simple to perform, and typically required 20 to 30 min to dissect both tunnels and complete the gastropexy. In 2 dogs (No. 7, 15), the gastric mucosa was inadvertently perforated during the initial dissection of the tunnel while separating the seromuscular layer from the gastric submucosa. In both cases, the opening in the gastric mucosa was closed with simple interrupted sutures, and the surgical procedure was continued without further difficulty. None of the dogs experienced postoperative complications associated with the gastric perforation. A gastrotomy was performed in 2 dogs (No. 3, 7) in the parietal surface of the body of the

stomach, because solid stomach contents could not be removed through the orogastric tube. Both dogs recovered uneventfully and were discharged from the hospital. Splenectomy was performed in 2 dogs (No. 2, 18), because thrombosis or avulsion of splenic vessels had resulted in splenic necrosis. Partial gastrectomy was performed in the fundus of the stomach of 1 dog (No. 11) due to stomach wall necrosis; it did not interfere with the gastropexy procedure or increase its difficulty. The dog recovered uneventfully and was discharged from the hospital.

The mean patient hospital stay was 3.65 d (range, 3 to 6 d). Systemic sequelae of GDV noted during the early postoperative period included ventricular arrhythmias necessitating antiarrhythmic therapy (No. 2, 20) and moderate to severe anemia (dogs 9, 11, 13, 19). Dog 19 required a blood transfusion. Dog 20 developed increases in prothrombin time (PT) and activated partial thromboplastin time (aPTT), and decreases in platelet numbers and serum fibrinogen, consistent with disseminated intravascular coagulation. The dog responded well to plasma transfusion. One dog (No. 2) died of severe ventricular arrhythmias and cardiac arrest 4 d after surgery. Transient melena was noticed in 6 dogs (No. 2, 6, 14, 16, 17, 20). Four dogs (No. 2, 6, 10, 18) developed transient gastric dilatation during the hospitalization period that responded to orogastric intubation or placement of a nasogastric tube. Five dogs (No. 6, 10, 12, 13, 16) had episodes of transient abdominal distention, possibly consistent with gastric dilatation, several months after surgery. These episodes resolved without veterinary assistance.

Eleven dogs that underwent clinical, ultrasonographic, and radiographic follow-up evaluations did not have abnormalities on physical examination. Follow-up periods ranged from 16 to 42 mo, with a mean of 22 mo. In all 11 dogs, radiographic findings on gastrography were suggestive of an intact gastropexy. The staple lines were visible and intact in 10/11 dogs; in 1 dog, 3 staples appeared open. The staple lines were positioned in the right abdominal wall caudal to the last rib with the pyloric antrum displaced caudoventrally and closely associated with the staple line (Figure 7). In all cases, the position of the metallic staples and the pyloric antrum remained unchanged with gastric distention. On abdominal ultrasonography, the staple line was accurately visualized in 1 case (No. 5). Reduced or absent sliding motion of the stomach relative to the body wall in the region of the gastropexy site was noted in only 5/8 dogs (from TUSVM). This localized reduction of sliding motion between the gastric wall and the adjacent abdominal wall appeared to be the most reliable ultrasonographic finding in evaluation of the integrity of the gastropexy site.

Discussion

Gastric dilatation and volvulus remain a common life-threatening problem in dogs. Rapid, appropriate emergency medical therapy followed by prompt definitive surgical treatment and postoperative intensive care is required to successfully manage the pathophysiological alterations that occur with GDV. Minimizing anesthetic and surgical time is critical to improving the chance of patient survival (41). Until more is known about the etiology of GDV, gastropexy has to be relied on to prevent the disease and its recurrence (42).

The gastropexy procedure described in this report is technically simple to perform. Like the hand-sutured gastropexies, the stapled gastropexy is situated on the parietal surface of the pyloric antrum, an area unlikely to incur vascular compromise as a result of GDV. Although scarifying the peritoneal and serosal surfaces to be apposed may improve the quality of the adhesion (43), the authors do not consider this step to be essential to obtain an effective stapled gastropexy. A potential limitation of the technique is the occasional difficulty that may be encountered in creating the gastric tunnel between the seromuscularis and the submucosa. When the gastric wall is severely thinned as a result of dilatation, it may be difficult to dissect between these 2 planes, predisposing to accidental perforation of the gastric mucosa. This difficulty may also be encountered in performing belt-loop or circumcostal gastropexies, which require creation of a gastric seromuscular flap; however, visualization of the appropriate dissection plane is improved when creating a flap versus creating a tunnel. When available, an assistant can greatly facilitate creation of the gastric tunnel by applying gentle traction to the seromuscular layers overlying the tunnel with stay sutures as the dissection is performed. If the mucosa is inadvertently penetrated, gastric content leakage is avoided, and the mucosa is reapposed with 1 or more simple interrupted sutures to prevent peritonitis, abscessation, or both, within the tunnel. The site is copiously lavaged with isotonic saline, and the surgery is completed as planned, and the patient is monitored closely postoperatively for any signs of infection.

None of the dogs in this study developed a recurrence of GDV, further suggesting that all of the stapled gastropexies remained intact during the study period. The postoperative gastrointestinal signs reported by the owners were mild and self-limiting. All dogs either gained body weight or returned to pre-GDV body weight. The occasional episodes of gastric dilatation noted in 5 dogs were mild and transient, therefore, they were unlikely to have been caused by breakdown of the gastropexy and recurrent volvulus. The complication of gastric dilatation is consistent with all gastropexy procedures, as the underlying etiology of GDV remains untreated.

Results of diagnostic imaging studies provided further evidence that the stapled gastropexies were intact. Abdominal radiography confirmed that the pyloric antrum was positioned in close proximity to the right ventral abdominal wall, pre- and post-gastric distention, supporting an intact gastropexy. The metallic staple line is easily assessed on radiographs. The ultrasonographic finding most supportive of the integrity of the gastropexy site is the reduced or absent sliding motion between the stomach and body wall in the region of the gastropexy. Ultrasonographic detection of iatrogenic adhesions can have a variable success rate (44–45). This variability may due to the location, shape and length, and type of gastropexy technique, as well as being an operator-dependent procedure.

In conclusion, our results indicate that an effective and consistent permanent gastropexy can be created by using surgical stapling equipment. In our experience, the operative times required for stapled versus hand-sutured gastropexies are similar. Although use of the surgical stapling equipment is very affordable in clinical practice, purchase of the equipment and

supplies do make stapled gastropexy more expensive than the hand-sutured techniques. The choice between this technique and the previously described hand-suturing techniques is largely a matter of individual preference. Creation of a gastropexy by using a surgical stapling device is an alternative to consider when treating patients with GDV.

Authors' contributions

Dr. Belandria developed the gastropexy technique, conducted the surgical procedures and follow-up examinations, and wrote the manuscript. Dr. Pavletic assisted in developing the gastropexy technique and was involved with the preparation of the manuscript. Dr. Boulay suggested the gastropexy technique and was involved in its development and in the preparation of the manuscript. Drs. Penninck and Schwarz conducted the radiographic and utlrasonographic studies and were involved with the preparation of the manuscript. CVJ

References

1. Burrows CF, Ignaszewski LA. Canine gastric dilatation — volvulus. J Small Anim Pract 1990;31:495–501.
2. Brockman DJ, Washabau RJ, Drobatz KJ. Canine gastric dilatation/volvulus syndrome in a veterinary critical care unit: 295 cases. J Am Vet Med Assoc 1995;207:460–464.
3. Glickman LT, Glickman NW, Perez MS, Schellenberg DB, Lantz GC. Analysis of risk factors for gastric dilatation and dilatation-volvulus in dogs. J Am Vet Med Assoc 1994;204:1465–1471.
4. Glickman LT, Glickman NW, Schellenberg DB, Raghavan M, Lee T. Non-dietary risk factors for gastric dilatation-volvulus in large and giant breed dogs. J Am Vet Med Assoc 2000;217:1492–1499.
5. Glickman LT, Glickman NW, Schellenberg DB, Simpson K, Lantz GC. Multiple risk factors for the gastric dilatation-volvulus syndrome in dogs: A practitioner/owner case-control study. J Am Vet Med Assoc 1997;33:197–204.
6. Schellenberg DB, Yi Q, Glickman NW, Glickman LT. Influence of thoracic conformation and genetics on the risk of gastric dilatation-volvulus in Irish setters. J Am Vet Med Assoc 1998;34:64–73.
7. Hosgood G. Gastric dilatation — volvulus in dogs. J Am Vet Med Assoc 1994;204:1742–1747.
8. Matthiesen DT. The gastric dilatation/volvulus complex: medical and surgical considerations. J Am Anim Hosp Assoc 1983;19:925–932.
9. Betts CW, Wingfield WE, Rosin E. "Permanent" gastropexy — as a prophylactic measure against gastric volvulus. J Am Anim Hosp Assoc 1976;12:177–181.
10. MacCoy DM, Sykes GP, Hoffer RE, Harvey HJ. A gastropexy technique for permanent fixation of the pyloric antrum. J Am Anim Hosp Assoc 1982;18:763–768.
11. Flanders JA, Harvey HJ. Results of tube gastrostomy as treatment for gastric volvulus in the dog. J Am Vet Med Assoc 1984;185:74–77.
12. Meyer-Lindenberg A, Harder A, Fehr M, et al. Treatment of gastric dilatation-volvulus and a rapid method for prevention of relapse in dogs: 134 cases (1988–1991). J Am Vet Med Assoc 1993;203:1303–1307.
13. Schulman AJ, Lusk R, Lippincott CL, et al. Muscular flap gastropexy: A new surgical technique to prevent recurrences of gastric dilation-volvulus syndrome. J Am Anim Hosp Assoc 1986;22:339–346.
14. Whitney WO, Scavelli TD, Matthiesen DT, et al. Beltloop gastropexy: Technique and surgical results in 20 dogs. J Am Anim Hosp Assoc 1989;25:75–83.
15. Leib MS, Konde LJ, Wingfield WE, et al. Circumcostal gastropexy for preventing recurrence of gastric dilation-volvulus in the dog: An evaluation of 30 cases. J Am Vet Med Assoc 1985;187:245–248.
16. Coolman BR, Marretta SM, Pikanowski GJ, Coolman SL. Evaluation of a skin stapler for belt-loop gastropexy in dogs. J Am Anim Hosp Assoc 1999;35:440–444.
17. Andrews AH. A study of ten cases of gastric torsion in the bloodhound. Vet Rec 1970;86:689–693.
18. Betts CW, Kneller SK, Rosin E. Recurring gastric volvulus in a dog. J Small Anim Pract 1975;16:433–438.
19. Betts CW, Wingfield WE, Green RW. A retrospective study of gastric dilation-torsion in the dog. J Small Anim Pract 1974;15:727–734.
20. Muir WW. Gastric dilatation-volvulus in the dog, with emphasis on cardiac arrhythmias. J Am Vet Med Assoc 1982;180:739–742.
21. Walshaw R, Johnston DE. Treatment of gastric dilatation-volvulus by gastric decompression and patient stabilization before major surgery. J Am Anim Hosp Assoc 1976;12:162–167.
22. Funkquist B, Obel N. Gastric torsion in the dog-II. Nonsurgical treatment by aspiration of gastric contents during repeated rotation of the animal. J Small Anim Pract 1979;20:93–102.
23. Wingfield WE, Betts CW, Green RW. Operative techniques and recurrence rates associated with gastric volvulus in the dog. J Small Anim Pract 1975;16:427–432.
24. Glickman LT, Lantz GC, Schellenberg DB, Glickman NW. A prospective study of survival and recurrence following the acute gastric dilatation-volvulus syndrome in 136 dogs. J Am Anim Hosp Assoc 1998;34:253–258.
25. Brourman JD, Schertel ER, Allen DA, Birchard SJ, DeHoff WD. Factors associated with perioperative mortality in dogs with surgically managed gastric dilatation-volvulus: 137 cases (1988–1993). J Am Vet Med Assoc 1996;208:1855–1858.
26. Hardie RJ, Flanders JA, Schmidt, P, Credille KM, Pedrick TP, Short CE. Biomechanical and histological evaluation of a laparoscopic stapled gastropexy technique in dogs. Vet Surg 1996;25:127–133.
27. Wilson ER, Henderson RA, Montgomery RD, et al. A comparison of laparoscopic and belt-loop gastropexy in dogs. Vet Surg 1996;25:221–227.
28. Rawlings CA, Foutz TL, Mahaffey MB, et al. A rapid and strong laparoscopic-assisted gastropexy in dogs. Am J Vet Res 2001;62:871–875.
29. Sanchez-Margallo FM, Diaz-Guemes I, Uson-Gargallo J. Intracorporeal suture reinforcement during laparoscopic gastropexy in dogs. Vet Rec 2007;160:806–807.
30. Steichen FM, Ravitch MM. Stapling in Surgery. Chicago: Year Book Med Publ, 1984;79–112:173–219.
31. Clark GN, Pavletic MM. Partial gastrectomy with an automatic stapling instrument for treatment of gastric necrosis secondary to gastric dilatation-volvulus. Vet Surg 1991;20:61–68.
32. Hess JL, DeYoung DW, Grier RL. Use of mechanical staples in veterinary thoracic surgery. J Am Anim Hosp Assoc 1979;15:569–573.
33. Hess JL, McCurnin DM, Riley MG, Koehler KJ. Pilot study for comparison of chromic catgut suture and mechanically applied staples in enteroanastomoses. J Am Anim Hosp Assoc 1981;17:409–414.
34. Wykes PM, Rouse GP, Orton EC. Removal of five canine cardiac tumors using a stapling instrument. Vet Surg 1986;15:103–106.
35. Lewis DD, Ellison GW, Bellah JR. Partial hepatectomy using stapling instruments. J Am Anim Hosp Assoc 1987;23:597–602.
36. Ahmadu-Suka F, Withrow SJ, Nelson AW, et al. Billroth II gastrojejunostomy in dogs: Stapling technique and post-operative complications. Vet Surg 1988;17:211–219.
37. LaRue SM, Withrow SJ, Wykes PM. Lung resection using surgical staples in dogs and cats. Vet Surg 1987;16:238–240.
38. Pavletic MM. Surgical stapling devices in small animal surgery. Compend Contin Educ Pract Vet. 1990;12:1724–1741.
39. Muir WW, Bonagura JD. Treatment of cardiac arrhythmias in dogs with gastric distention-volvulus. J Am Vet Med Assoc 1984;184:1366–71.
40. Burk RL, Ackerman N. Small Animal Radiology and Ultrasonography: A Diagnostic Atlas and Text. 2nd ed. Philadelphia: WB Saunders, 1996:247.
41. Leib MS, Martin AR. Therapy of gastric dilatation-volvulus in the dog. Compend Contin Educ Pract Vet 1987;12:1155–1165.
42. Johnson RG, Barrus J, Greene RW. Gastric dilatation-volvulus: Recurrence rate following tube gastrostomy. J Am Anim Hosp Assoc 1984;20:33–37.
43. Fox SM, McCoy CP, Cooper RC, et al. Circumcostal gastropexy versus tube gastrostomy: Histological comparison of gastropexy adhesions. J Am Anim Hosp Assoc 1988;24:273–279.
44. Wacker CA, Weber UT, Tanno F, Lang J. Ultrasonographic evaluation of adhesions induced by incisional gastropexy in 16 dogs. J Small Anim Pract 1998;39:379–384.
45. Tanno F, Weber UT, Wacker CA, et al. Ultrasonographic comparison of adhesions induced by two different methods of gastropexy in the dog. J Small Anim Pract 1998;39:432–436.