Maxillary Tuberosity Fracture Associated with First Molar Extraction: A Case Report

Hidayet B. Polat[a], DDS, PhD
Sinan Ay[b], DDS, PhD
M. Isa Kara[c], DDS

ABSTRACT

Maxillary tuberosity fractures during molar teeth extraction can occur commonly in dental practice; however, very few cases are reported and discussed in the literature. This article presents a case of large fracture of maxillary tuberosity during extraction of first maxillary molar tooth and its conservative treatment outcomes. (Eur J Dent 2007;1:256-259)

Keywords: Maxillary molar extraction; Dentoalveolar trauma; Maxillary tuberosity fracture; Conservative approach.

INTRODUCTION

The extraction of a tooth requires that the surrounding alveolar bone be expanded to allow an unimpeded pathway for tooth removal. However, in generally the small bone parts are removed with the tooth instead of expanding.[1-4] Fracture of a large portion of bone in the maxillary tuberosity area is a situation of special concern. The maxillary tuberosity is especially important for the stability of maxillary denture.[2,3] Large fractures of the maxillary tuberosity should be viewed as a grave complication. The major therapeutic goal of management is to salvage the fractured bone in place and to provide the best possible environment for healing.[3]

Routine treatment of the large maxillary tuberosity fractures is to stabilize the mobile part(s) of bone with one of rigid fixation techniques for 4 to 6 weeks. Following adequate healing, a surgical extraction procedure may be attempted. However, if the tooth is infected or symptomatic at the time of the tuberosity fracture, the extraction should be continued by loosening the gingival cuff and removing as little bone as possible while attempting to avoid separation of the tuberosity from the periosteum. If the attempt to remove the attached bone is unsuccessful and the infected tooth is delivered with the attached tuberosity, the tissues should be closed with watertight sutures because there may not be a clinical oroantral communication. The surgeon may elect to graft the area after 4 to 6 weeks of healing and postoperative antibiotic therapy. If the tooth is symptomatic but there is no frank sign of purulence or infection, the surgeon may elect to attempt to use the attached bone as an autogenous graft.[5]

There are many reports about complication of the tooth extraction in the literature, but only a few

[a] Res. Assist., Dept. of Oral and Maxillofacial Surgery, Cumhuriyet University, Faculty of Dentistry, Sivas, Turkey.
[b] Assoc. Prof., Dept. of Oral and Maxillofacial Surgery, Faculty of Dentistry, Gaziantep University, Gaziantep, Turkey.
[c] Dept. of Oral and Maxillofacial Surgery, Faculty of Dentistry, Cumhuriyet University, Sivas, Turkey.

Corresponding Author: Dr. Hidayet B. Polat
Cumhuriyet Üniversitesi Diş Hekimliği Fakültesi
ADÇH ve Cerrahisi AD. 58140, Sivas, Turkey
E-mail: hidayetpolat@yahoo.com

cases are about maxillary tuberosity fractures. The purpose of this paper is to present a case of maxillary tuberosity large fracture during extraction of first maxillary molar tooth, because of high possibility in dental practice but being rare in literature.

CASE REPORT

A 28-year-old Caucasian male was referred to our clinic by the patient's general dental practitioner (GDP) after the practitioner attempted to extract the patient's upper right first molar tooth with forceps. He was a healthy young man with no history of significant medical problems.

In dental examination; the maxillary right first, second and third molars were elevated and mobile, so the patient was unable to close his mouth (Figure 1). An oroantral communication and bleeding from right nostril were present. Of interest was that no caries was observed on right first molar. Based on detailed anamnesis, GDP's indication of extraction was guessed only from the sensitivity of the right first molar or misdiagnosing of any referral pain. The intraoral and radiographic examination revealed a maxillary right tuberosity fracture including three molar teeth (Figure 2). The patient also stated that while the GDP was extracting the tooth, he had used the forceps with his both hands without supporting the alveolar bone segment.

After local anesthesia, the tuberosity and all molar teeth were repositioned to their original location and fixed by an arch bar and lacerations were sutured. Because utilizing an arch bar to maxillary teeth did not provide enough stabilization of the tuberosity, intermaxillary fixation was used (Figure 3).

Postoperatively, a 7-day course of co-amoxyclav, a 7-day course of chlorhexidine gluconate mouthwash and a 3-day course of pseudoephedrine were prescribed together with adequate analgesics. In addition to the usual postextraction instructions the patient was advised to avoid blowing his nose for two weeks to prevent an oroantral fistula from developing. The patient had an uneventful recovery.

After the 2-month healing period of the tuberosity (Figure 4), because vitality test was negative, maxillary right first molar was treated by root canal treatment and by an apical resection

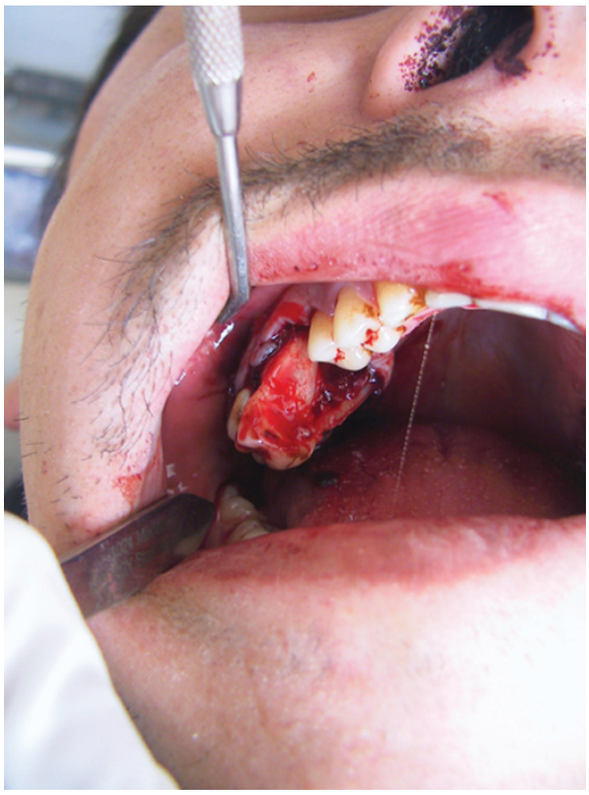

Figure 1. Preoperative photograph shows luxated maxillary molar teeth.

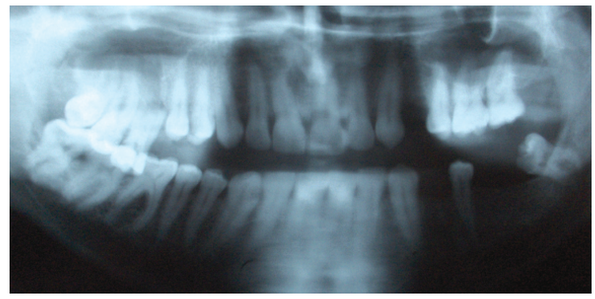

Figure 2. Panoramic radiograph shows large fracture of right maxillary tuberosity.

Figure 3. Intraoperative photograph shows bimaxillary fixation with arch bar and elastics.

of mesiobuccal root due to being obliterated of the mesiobuccal canal.

DISCUSSION

The etiologic factors responsible for fractured maxillary tuberosity during extraction of upper molars are a large maxillary sinus with thin walls, a tooth with large divergent roots or an abnormal number of roots and dental anomalies such as tooth fusion, tooth isolation, over-eruption, ankylosis, and hypercementosis of upper molar teeth. A chronic apical infection of the affected tooth may result in bone sclerosis and render the bone of the tuberosity more liable to fracture.[1-4] All of the etiologic factors are responsible but in the literature the malpractice has not been mentioned. In this report the patient stated that the general dental practitioner did not support alveolar bone segment of the maxillary molar teeth during extraction procedure. Besides, according to what the patient said, the dentist applied excessive strength stopping to support alveolar bone segment of the teeth with his one hand as he had difficulty during the extraction of the tooth.

Cohen[1] reported two cases that he presented about the removal of the tuberosities because of pain in maxillary molars and stated that the removal of a tuberosity will increase the difficulty of the fitting a denture at some future date, but this is not an insurmountable problem and the conservative treatment of a fractured tuberosity with surgical removal of the affected tooth after two months will not markedly affect the shape of the alveolus and will give better retention of a denture.

Shah and Bridgman[4] presented a case about the fact that an extraction complicated by lateral and medial pterygoid tethering of a fractured maxillary tuberosity and delivery of the tooth and bone fragment under local anesthesia were unable to be achieved because of pain brisk bleeding and tethering by lateral and medial pterygoid muscles. He emphasized that when this complication is recognized by the general dentist the maxillary tuberosity should not be removed and the patient must be referred to a special unit.

Figure 4. Follow-up period photograph shows maxillary molar teeth in original position.

Although many authors[2-6] justify that if the fractured tuberosity is small with a tooth or two teeth or if the tooth is infected or symptomatic at the time of the tuberosity fracture, it can not be left in situ and the only course available is to remove the molar tooth together with the attached tuberosity. In our case we decided to leave the alveolar bone complex of the tuberosity with the patient approval. The authors[2-6] may believe that the symptoms of the tooth decided to get extracted will continue or the fractured complex can not recover because of the infection after tuberosity fracture, but in our case the patient had no complaints like before the tuberosity fracture.

Ngeow[7] defended the conservative approach to the large tuberosity fractures and reported an alternative method that if the bony fragment is large, the tooth is grasped with a pair of molar forceps. In this way, the fractured tuberosity fragment is stabilized and a sharp Coupland periosteal elevator is then inserted into the distobuccal cervical area of the tooth and used to separate the alveolar bone segment from the roots of the tooth.

In conclusion, clinicians must inform the patient of the potential risks and possible benefits of treatment alternatives before making the final treatment plan; and early diagnosis of impacted teeth is essential for treatment. We experienced that large tuberosity fractures should be attempted to be salvaged but immediate removal of the small fractures including a tooth or two teeth with small bone complex may be a better choice because of the difficulty in attempting to retain the bone.

Not only forceps extraction of a resistant second or third molar but also first molar may result in fracture of the maxillary tuberosity. According to our knowledge, in the literature no maxillary tuberosity fracture case was reported to be associated with the upper first molar extraction. It is suggested that during the forceps

extraction of the upper molar teeth, supporting alveolar bone segment must be performed. Once these complications may occur unavoidably as a result of routine dental procedure under local anesthesia, the patient should refer to a specialist. To use simple fixation techniques, start appropriate medication decrease the complications and the patient's complaints, accelerate the healing process.

REFERENCES

1. Cohen L. Fractures of the maxillary tuberosity occurring during tooth extraction. *Oral Surg Oral Med Oral Pathol* 1960:13:409-411.
2. Norman JE, Cannon PD. Fracture of the maxillary tuberosity. *Oral Surg Oral Med Oral Pathol* 1967:24:459-467.
3. Peterson LJ. Prevention and management of surgical complications. In: Peterson LJ, Ellis III E, Hupp JR, Tucker MR, eds.: Contemporary Oral and Maxillofacial Surgery. 3rd ed. St Louis: Mosby Year Book, Inc, 1998:261.
4. Shah N, Bridgman JB. An extraction complicated by lateral and medial pterygoid tethering of a fractured maxillary tuberosity. *Br Dent J* 2005:198:543-544.
5. Fonseca RJ. Oral and Maxillofacial Surgery. Vol 1. Pennsylvania: W.B. Saunders, 2000:430.
6. Hardman EG. Surgical emergencies in the dental office. *Int Dent J* 1984:34:245-248.
7. Ngeow WC. Management of the fractured maxillary tuberosity: an alternative method. *Quintessence Int* 1998:29:189-190.