www.jkns.or.kr 10.3340/jkns.2008.44.1.40
Print ISSN 1225-8245 On-line ISSN 1598-7876
J Korean Neurosurg Soc 44 : 40-42, 2008
Copyright ⓒ 2008 The Korean Neurosurgical Society

Case Report

Spontaneous Spinal Epidural Hematoma

Byung Suck Baek, M.D., Jin Woo Hur, M.D., Ki Young Kwon, M.D., Hyun Koo Lee M.D.
Department of Neurosurgery, Cheongju Saint Mary's Hospital, Cheongju, Korea

Spontaneous spinal epidural hematoma (SSEH) is a relatively rare but significant spinal condition. Urgent surgical evacuation of a hematoma is generally indicated to prevent serious permanent neurological deficits. We encountered three cases of spontaneous spinal epidural hematomas associated with motor weakness that were treated successfully by surgical intervention.

KEY WORDS : Spinal epidural hematana · Laminectomy.

INTRODUCTION

Spontaneous spinal epidural hematoma (SSEH) is a relatively rare disease. Its incidence as estimated by Holtas et al was 0.1 per 100,000 people and less than 1% of people with the condition, the spinal epidural space was occupied by lesions[3]. The usual clinical presentation of SSEH is sudden neck or back pain that progresses toward paraparesis or quadriparesis, depending on the level of the lesion. Its etiology is related to coagulopathy, vascular malformation, neoplasms, infections, minor vertebral traumas and idiopathic causes. The authors encountered three cases of SSEH that were treated successfully through surgical intervention.

CASE REPORT

Case 1

A 19-year-old man was admitted to the hospital because of posterior neck pain, left upper extremity sensory changes, and mild weakness that developed 4 hours prior to admission. He denied any past medical history or trauma. MRI of the cervical spine revealed a flat and oval shaped lesion in the dorsal and left lateral side of the epidural space from the C3 to C7 levels showing mildly high signal intensity on T1-weighted images and heterogeneous signal intensity on T2-weighted images (Fig. 1A). A definite signal change in the spinal cord was not seen on MRI (Fig. 1B). Spinal angiography was checked, but no vascular abnormality was observed. We could not find any abnormal laboratory data, such as coagulopathy or, infection.

We performed partial hemilaminectomy of C3, 4, 5 and removed the epidural hematoma compressing the spinal cord. The patient was discharged without any further neurological problems.

Case 2

A 64-year-old man was admitted to the hospital because of low back pain and weakness in both legs (grade IV) that developed 2 hours prior to admission. He did not have a specific past medical history or trauma. No abnormal laboratory data were found. MRI of the thoracolumbar spine showed an elongated dorsal epidural mass lesion with slightly high signal intensity on T1-weighted images and heterogenous low signal intensity on T2-weighted images from T5 to L2 (Fig. 2A). The lesion displaced the spinal cord toward the right side (Fig. 2B). No definite vascular abnormalities were noted on spinal angiography.

We performed a total laminectomy from T6 to T10 and could identify a dark brownish epidural hematoma compressing the spinal cord, which was then removed. He was discharged without any further neurological problems.

Case 3

A 69-year-old woman was admitted to the hospital because of posterior neck pain and left upper extremity weakness (grade III) that developed 2 hours prior to admission. She had a history of hypertension and had taken aspirin for 5 years. Laboratory data and PT and, aPTT were in the

• Received : April 11, 2008 • Accepted : July 7, 2008
• Address for reprints : Jin Woo Hur, M.D.
Department of Neurosurgery, Cheongju St. Maty's Hospital, 589-5 Jujung-dong, Sangdang-gu, Cheongju 360-568, Korea
Tel : +82-43-219-8152, Fax : +82-43-211-7925
E-mail : somalh@nate.com

normal range. An elongated spindle shaped lesion at the left dorsolateral epidural space of the upper cervical level was identified on cervical spine MRI (Fig. 3A). There was no definite signal change in the spinal cord on MRI even though the lesion displaced the spinal cord toward the right side (Fig. 3B).

A partial hemilaminectomy of C2, 3, and 4 was performed. We identified an epidural hematoma compressing the spinal cord and removed it. Her left arm weakness improved from grade III to grade IV.

DISCUSSION

A spinal epidural hematoma is a rare but significant neurological condition. The spontaneous development of spinal epidural hematomas is most frequent after the fourth or fifth decade[5]. However, it has been reported to occur in all age groups, and it is a very rare clinical entity in children. Only 30 pediatric cases of SSEH have been documented in the medical literature[10,15]. The male/female ratio is 1.4 : 1[7]. Certain precipitating factors, including anticoagulant therapy for prosthetic cardiac valves, therapeutic thrombolysis for acute myocardiac infarction, hemophilia B, factor XI deficiency, long-term aspirin using as a platelet aggregation inhibitor, and vascular malformation, are suggested to be correlated with spontaneous spinal epidural hematomas[1,13]. It is also a rare occurrence during pregnancy, with only six cases reported in the literature[2]. Statistically, idiopathic cases account for approximate 40% of all cases[7]. The most common site of a spontaneous spinal epidural hematoma is the cervicothoracic region or thoracolumbar region[5,12].

Up to now, there have been disputes about the origin of these hematomas. Most researchers assert that SSEHs arise from the epidural venous plexus in the spinal epidural space because it lacks venous valves, and undulating pressure from the thoracic and abdominal cavities can impact it directly[5,7,11]. Several authors have prop-osed the spinal epidural arteries as a source of hemorrhage[13]. A more likely explanation is that pressure from arterial bleeding compresses the spinal cord, because the intra-thecal pressure is higher than the venous pressure[5,9].

The usual clinical presentation of a spontaneous spinal

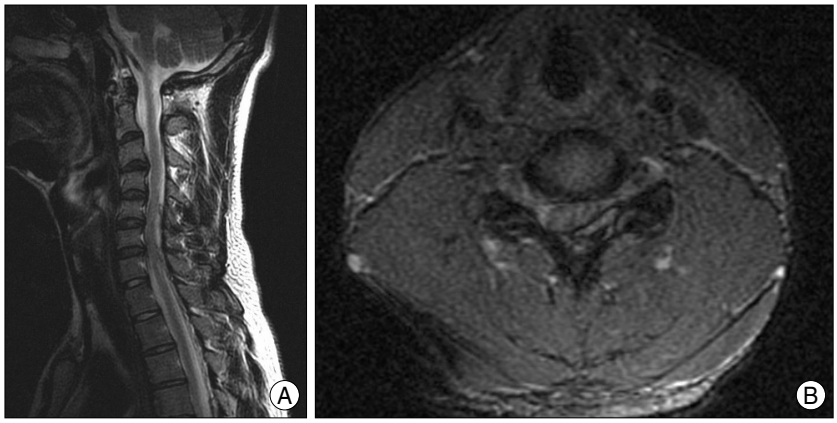

Fig. 1. Preoperative T2-weighted image shows an spontaneous spinal epidural hematoma located from C3 to C7 (A) and spinal cord compression on the dorsal and left lateral sides (B).

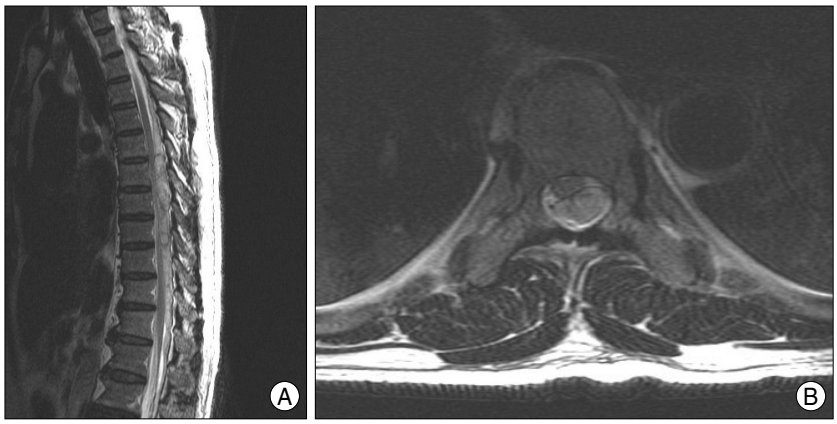

Fig. 2. Preoperative T2-weighted image shows an spontaneous spinal epidural hematoma located from T5 to L2 (A) and spinal cord compression on the dorsal and left lateral sides (B).

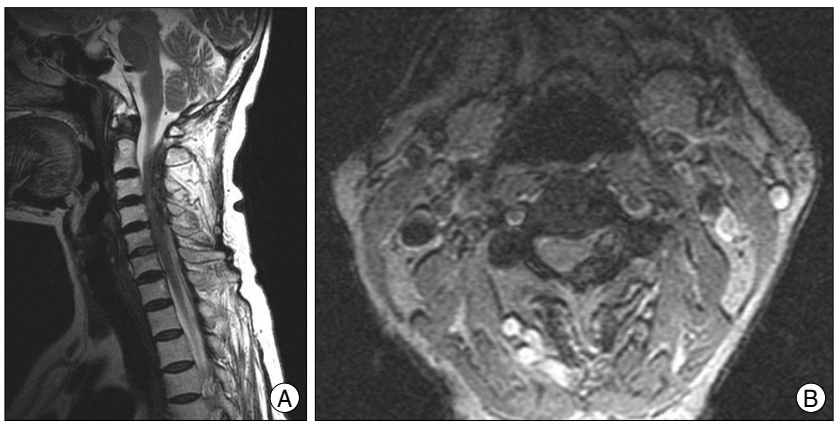

Fig. 3. Preoperative T2-weighted image showing an spontaneous spinal epidural hematoma located from C2 to C5 (A) and spinal cord compression on the dorsal and left lateral sides (B).

epidural hematoma is sudden stabbing neck or back pain that progresses toward paraparesis or quadriparesis, depending on the level of the lesion and the nerve root[6]. Children often suffer from additional symptoms of irritability, and occasionally urinary retention[10]. In high cervical region, SSEHs could cause spinal shock, leading to fatal condition[3].

Currently, MRI is considered as the first choice diagnostic method for SSEH[8,14]. It typically shows biconvex hematomas in the epidural space with welldefined borders tapering superiorly and inferiorly[4]. Subacute hematomas show characteristic high signal intensity on T1-weighted images[4]. A CT scan should be obtained if MRI is unavailable[11].

The differential diagnosis of spontaneous spinal epidural hematoma includes an acute herniated intervertebral disc, acute ischemia of the spinal cord, epidural tumor or abscess, spondylitis, transverse myelitis, or even a dissecting aortic aneurysm and acute myocardial infarction.

Early surgical intervention is the general treatment for spontaneous spinal epidural hematomas[8]. The procedure includes decompressive laminectomy and hematoma removal. If the exact location of the hematoma cannot be detected and confirmed by MRI, the dura should be opened to exclude the subdural hematoma. In cases with incomplete neurological deficits, the operation should be performed within 48 hours of the onset of the initial symptoms[7]. If the initial neurological deficits are complete, the operation should be performed within 36 hours[7]. Conservative treatment has also been documented, and it was employed only when neurological deficits improved in the early phase or with the coexistence of coagulopathy[15]. Multilevel acute epidural hematomas may be difficult to treat operatively in patients with coagulopathy[16]. Although the functional recovery of these patients may not be complete, the SSEH can be treated without surgery, and the patient should be protected from the significant risk of surgical intervention[15].

CONCLUSION

We report three rare cases of spontaneous spinal epidural hematomas. For the treatment of SSEHs, operation should be considered as soon as possible unless the neurological deficit takes a favorable turn in the earlier period or the patient also has coagulopathy.

References

1. Bisson EF, Dumont T, Tranmer B : Spontaneous Spinal Epidural Hematoma in a Child with Hemophilia B. **Can J Neurol Sci 34** : 488-490, 2007
2. Bose S, Ali Z, Rath GP, Prabhakar H : Spontaneous spinal epidural hematoma : a rare cause of quadriplegia in the post-partum period. **Br J Anaesth 99** : 855-857, 2007
3. Chan DT, Boet R, Poon WS, Yap F, Chan YL : Spinal shock in spontaneous cervical spinal epidural haematoma. **Acta Neurochir (Wien) 146** : 161-1162; discussion 1162-1163, 2004
4. Fujiwara H, Oki K, Momoshima S, Kuribayashi S : PROPELLER diffusion-weighted magnetic resonanace imaging of acute spinal epidural hematoma. **Acta Radiol 46** : 539-542, 2005
5. Guzel A, Simsek O, Karasalihoglu S, Kucukugurluoglu Y, Acunas B, Tosun A, et al : Spontaneous spinal epidural hematoma after seizure : a case report. **Clin Pediatr 46** : 263-265, 2007
6. Hangping Y, Shunwu F, Huilin Y, Tiansi T, Feng Z, Xing Z : Early diagnosis and treatment of acute or subacute spinal epidural hematoma. **Chin Med J 120** : 1303-1308, 2007
7. Liu Z, Jiao Q, Xu J, Wang X, Li S, You C : Spontaneous spinal epidural hematoma:analysis of 23 cases. **Surg Neurol 69** : 253-260; discussion 260, 2008
8. Matsumura A, Namikawa T, Hashimoto R, Okamoto T, Yanagida I, Hoshi M, et al : Clinical management for spontaneous epidural hematoma : diagnosis and treatment. **Spine J 8** : 534-537, 2007
9. Park J, Lee JB, Park JY, Lim DJ, Kim SD, Chung YK : Spinal cord infarction after decompressive laminectomy for spontaneous spinal epidural hematoma. **Neurol Med Chir (Tokyo) 47** : 325-327, 2007
10. Poonai N, Rieder MJ, Ranger A : Spontaneous spinal epidural hematoma in an 11-month-old girl. **Pediatr Neurosurg 43** : 121-124, 2007
11. Riaz S, Jiang H, Fox R, Lavoie M, Mahood JK : Spontaneous spinal epidural hematoma causing Brown-Sequard syndrome : case report and review of the literature. **J Emerg Med 33** : 241-244, 2007
12. Shin JJ, Kuh SU, Cho YE : Surgical management of spontaneous spinal epidural hematoma. **Eur spine J 15** : 998-1004, 2006
13. Solheim O, Jorgensen JV, Nygaard OP : Lumbar epidural hematoma after chiropractic manipulation for lower back pain : Case Report. **Neurosurgery 61** : E170-171; discussion E171, 2007
14. Song KJ, Lee KB : The poor outcome of the delayed diagnosis of acute spontaneous spinal epidural hematoma : two cases report. **J Korean Med Sci 20** : 331-334, 2005
15. Tailor J, Dunn IF, Smith E : Conservative treatment of spontaneous spinal epidural hematoma associated with oral anticoagulant therapy in a child. **Childs Nerv Syst 22** : 1643-1645, 2006
16. Ziyal IM, Aydin S, Inci S, Sahn A, Ozagen T : Multilevel acute spinal epidural hematoma in a patient with chronic renal failure- case report. **Neurol Med Chir (Tokyo) 43** : 409-412, 2003