BURKITT'S LYMPHOMA WITH ILEOCECAL AND SUBDIAPHRAGMATIC MASSES

Hubert A. Johnson, MD, and Willard C. Johnson, MD
Boston, Massachusetts

Approximately 25 new cases of American Burkitt's lymphoma (ABL) are diagnosed and reported yearly. Black patients presenting with ABL occur in less than 5 percent of the reported cases. A 47-year-old black man with ABL and ileocecal masses typical of the disease is presented. Symptoms, physical findings, and radiologic features of the disease are assessed. The combined modality of aggressive surgical extirpation and chemotherapy may improve remission and survival time by reduction of tumor burden.

Burkitt's lymphoma represents an undifferentiated, highly malignant tumor of the B lymphocytes. Since its discovery in 1958, two forms of the disease have been recognized: an endemic variety confined to the African continent and a nonendemic, sporadic American form. Approximately 25 new cases of American Burkitt's lymphoma (ABL) are diagnosed and reported yearly.

Although pathologic and immunologic descriptions of the tumor are similar, there are important differences in presentation, epidemiology, and clinical features between the endemic and nonendemic form. American Burkitt's lymphoma is most frequently noted in children aged 11 to 17 years. The American Burkitt's Lymphoma Registry has found that between the ages of 10 and 19 years, 0.7 cases per one million children can be found in the United States. Of 421 patients in that study, only 10 patients older than 41 years of age were found.[1] Paradoxically, black patients presenting with ABL occur in less than 5 percent of the reported cases. A case of American Burkitt's lymphoma in a 47-year-old black man and a review of the recent literature are presented in the following report.

From the Tufts University School of Medicine, and the Boston Veterans Administration Hospital, Boston, Massachusetts. Requests for reprints should be addressed to Dr. Hubert Johnson, Department of Surgery, Tufts-New England Medical Center Hospital, 171 Harrison Avenue, Boston, MA 02110.

CASE REPORT

R.M. is a 47-year-old black man with a three- to six-month history of malaise, anorexia, diarrhea, night sweats, melena, and hematochezia. He experienced a 15-lb weight loss over that period. Approximately one month prior to admission, the patient noted a mass in his right lower abdomen. On physical examination there was a large hard mobile mass in the right lower quadrant. The stools tested positive for occult blood.

Laboratory examination revealed a white blood cell count of 11,300 mm^3 ($11.3\times 10^3/\mu L$), a hematocrit of 29 percent, uric acid of 11.1 mg/dL, and a lactic dehydrogenase level of 339 units. The chest x-ray film was normal. Only a "mass effect" in the right lower quadrant was seen on abdominal films (Figure 1). The carcinoembryonic antigen level was 21.9 units. A 17-cm, nodular, deforming mass in the area of the ileocecal valve, with extrinsic compression of the cecal lumen, was seen on barium enema examination. The presence of the ileocecal mass extending to the proximal ascending colon was confirmed on computed tomography scanning (Figure 2). A separate discrete subdiaphragmatic mass was noted compressing the liver (Figure 3). Colonoscopy and biopsy of the cecum was notable for ulceration and edema of the right colonic mucosa. Biopsy was diagnostic for malignant lymphoma of the Burkitt's type. Immunotyping confirmed a B-cell lymphoma with free lambda chains. Bone marrow aspirate was negative.

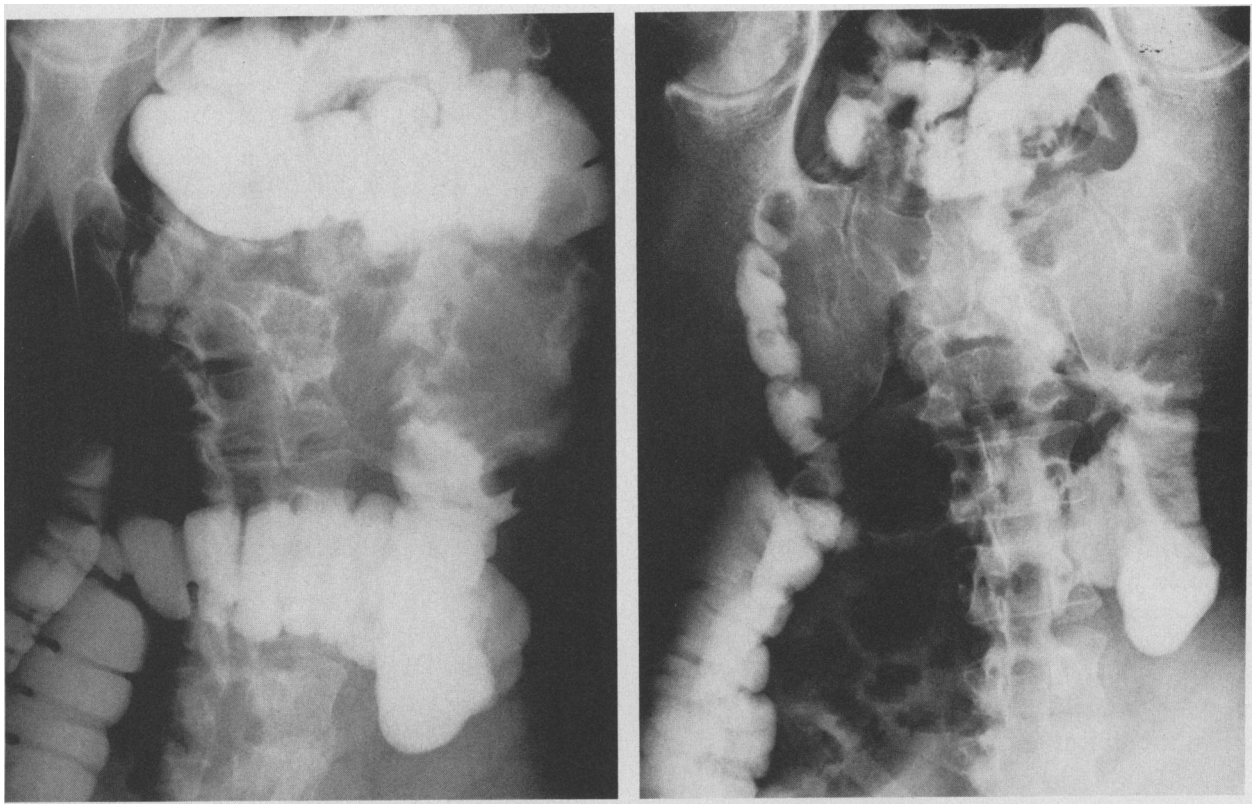

Figure 1. Right lower quadrant mass effect demonstrated on two views of single-contrast barium enema

Epstein-Barr virus titer was positive at 1:2,560.

At laparotomy, a large 13 × 17 × 11 cm mass was found encompassing the right colon and greater omentum (Figure 4). There was celiac and retroperitoneal nodular enlargement. A secondary 11 × 11 × 3.5 cm mass, present in the subdiaphragmatic area, was also excised. The postoperative course was uneventful.

Final pathology confirmed Burkitt's lymphoma, American type (Figure 5). A marked decrease in tumor bulk was revealed in postoperative CT scanning (Figure 6). Lumbar puncture was negative. The patient is well and undergoing chemotherapy with M-BACOP and with intrathecal methotrexate and leukovorin rescue.

DISCUSSION

Burkitt's lymphoma was described in the African malaria belt by British surgeon Denis Burkitt as a "round cell sarcoma" in the jaws of African children.[2,3] Through serendipity and sheer determination, the epidemiology and immunology of the disease have been characterized.[2-5] It is now well established that the Burkitt's lymphoma is one of the undifferentiated lymphomas of the bursa-derived, B-cell variety.[4-7] A high incidence of IgM antibodies to the Epstein-Barr virus (EBV) capsid antigen has been noted in the serum of patients with Burkitt's lymphoma on immunochemical examination.[2,4,8] Although these viral antibodies are present in the serum of the patients with Burkitt's lymphoma, a causal relationship has not been established.

The endemic (African) and nonendemic (American) forms are immunologically similar,[6] but differences exist in their anatomic and epidemiologic manifestations. The African variety presents, on the average, in a younger age group (approximately age 6 years), is more likely to have a positive antibody titer to EBV, to involve the jaw, and to appear in clusters.[2-5] The American Burkitt's lymphoma appears to have a predilection for the gastrointestinal tract.[1,4,5,9-17]

Gastrointestinal lesions accounted for 75 percent of the cases seen at the National Cancer Insti-

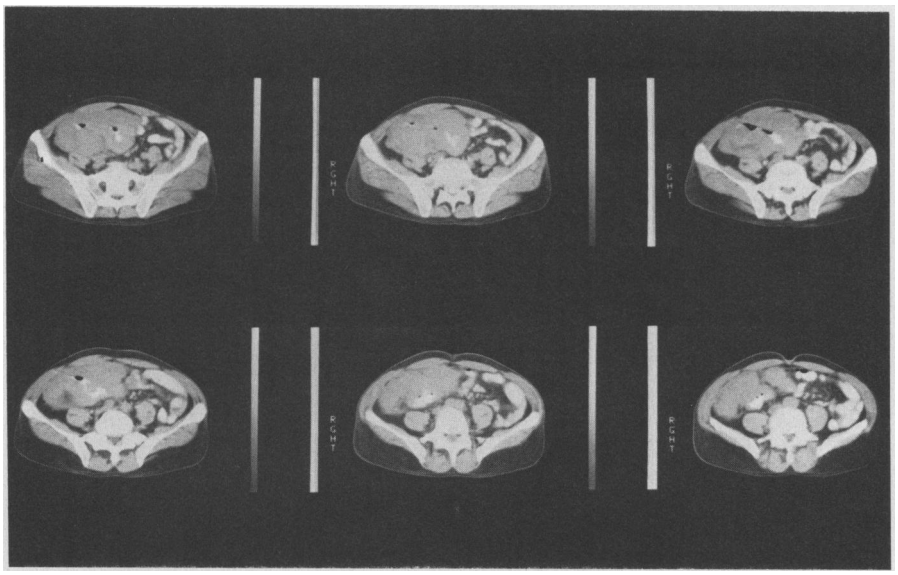

Figure 2. Preoperative CT scan with contrast, large right lower quadrant mass in iliac fossa. Note luminal dilitation and false channel caused by tumor necrosis

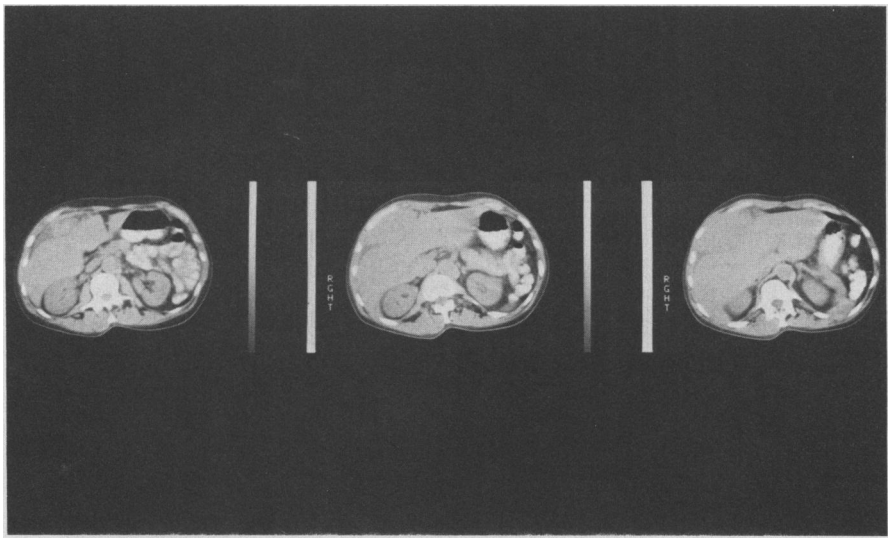

Figure 3. A preoperative CT scan: subdiaphragmatic mass compressing and indenting liver

tute (NCI)[14] and 56 percent in the series presented by Arsenau et al.[13] Specifically, ABL most commonly presents in the area of the ileocecal valve.[12,15,16] This phenomenon is thought to be related to the confluence of immunoproliferative lymph nodes and Peyer's patches in this area.[4-6] The American variety is also less likely to be associated with EBV antibodies than the African endemic type. When EBV antibodies are present in patients with ABL, this is thought to indicate a more favorable prognosis.[1] Instances of American Burkitt's lymphoma associated with other organs have also been described.[8,12-14,16-19]

Although the primary treatment of Burkitt's lymphoma is chemotherapy,[4,5,11,14,18,20] studies have suggested that the American nonendemic variety may be best managed by a combined modality of chemotherapy and surgical extirpa-

Figure 4. Operative specimen showing massive enlargement of the cecum with tumor invasion and extension to omentum

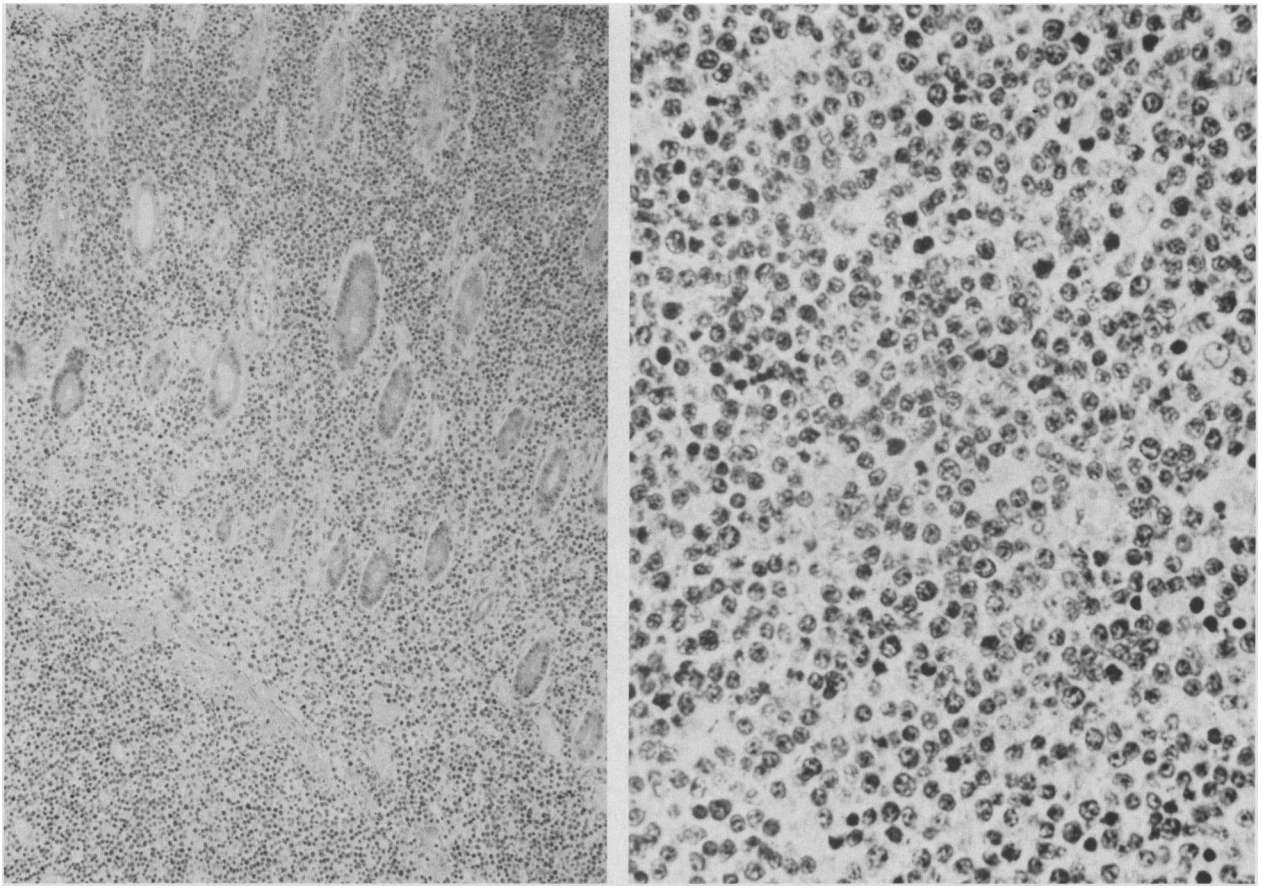

Figure 5. Bowel wall with Burkitt's lymphoma cells (left) invading the mucosa of bowel (H & E ×100). Bowel wall with lymphocytic infiltration, small noncleaved cells, mitoses, and many dying cells (right). Note characteristic "starry sky" pattern of Burkitt's lymphoma (H & E ×400)

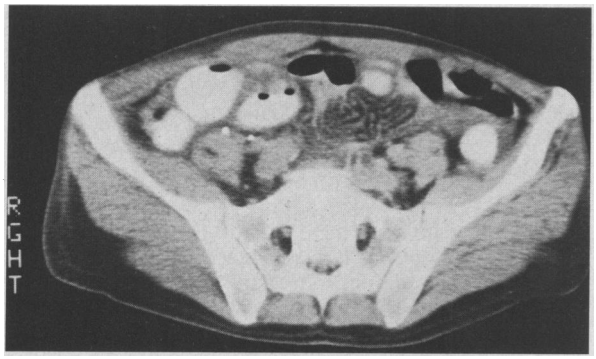

Figure 6. Postoperative CT scan: demonstrates removal of right lower quadrant mass

TABLE 1. STAGING OF BURKITT'S LYMPHOMA*

Stage	Extent of Tumors
A	Localized extra-abdominal mass
B	Two or more extra-abdominal masses
C	Intraabdominal tumor with or without facial bone involvement
D	Intraabdominal tumor with multiple extra-abdominal sites
AR	90% resection of intraabdominal mass

*From Zeigler[5]

tion.[4,11,13] Kemeny et al[14] have further derived that 75 percent of their patients with ABL had intraabdominal disease that required celiotomy for diagnosis and treatment. Despite the latter belief, very little has been written in the surgical literature on approaches to patients with Burkitt's lymphoma. This may be because this tumor was included in other surgical series,[21] or because of the rare presentation of the disease. Extirpative resection of the tumor mass in Burkitt's lymphoma has a direct effect on staging,[20,21] treatment,[13] and survival.[5,13,14,20,21] If untreated, ABL is uniformly fatal, but Zeigler[11] found that when surgical ablation preceded chemotherapy, two-year survival rates greater than 54 percent can be achieved.

The role of radiotherapy in addition to surgery and chemotherapy has not been completely defined, but radiotherapy may assist in reduction of tumor burden.[4,5,22]

The staging of Burkitt's lymphoma currently in vogue is one described by Magrath[21] and modified by Zeigler[5] (Table 1). Using his staging system, Magrath has shown that in patients with intraabdominal Burkitt's lymphoma there is improved prognosis and survival time if greater than 90 percent of the tumor burden can be removed.[21] This improved survival time also was confirmed by Zeigler,[11] Arsenau et al,[13] and Janus et al.[20] Surgical ablation prior to chemotherapy may also increase the incidence of remission.[13,14,21] Hende et al[22] at the National Cancer Institute have also alluded to aggressive surgical extirpation that may prevent continued gastrointestinal hemorrhage or perforation secondary to necrosis.[22] Importantly, debulking reduces the incidence of the highly lethal acute tumor lysis syndrome.[13,14,18] Burkitt's tumors have been shown to be highly proliferative, and kinetically, may represent the most rapidly growing tumor in man.[4,13,18] The systemic application of cell-cycle inhibitors (chemotherapeutic agents) to sensitive rapidly growing cells results in cellular lysis and release of content. The manifestations of this acute lysis of cells results in hyperuricemia, hyperkalemia, and hyperphosphatemia.[18] Sudden deaths as a result of electrolyte imbalance have been reported.

Documentation of reduction in tumor burden may be monitored by measurement of serum lactate dehydrogenase (LDH) levels. Elevated serum concentration of LDH has been shown to reflect a large volume of tumor mass.[5,13,23]

In patients in the AR stage (Table 1), a "second look" laparotomy for reexamination after a course of chemotherapy has not been studied in any prospective fashion but should be considered if relapse or regrowth of tumor can be demonstrated intraabdominally.[4]

Abdominal masses related to Burkitt's lymphoma can involve multiple organs and portions of the gastrointestinal tract.[1,9,12,14,20] Radiographs of the abdomen are useful in preoperative assessment of gastrointestinal pathology. In this regard, although there are no specific radiologic findings associated with Burkitt's lymphoma, computed tomography scanning (because of its ability to simultaneously visualize multiple organ systems) is ideal for preoperative evaluation.[10,16,19] The utilization of oral and intravenous contrast agents allows bulky tumor deformities to be better defined. By calculation of Hounsfield numbers, attenuation coefficient, and the tissue density of nonopacified tissue relative to opacified intestinal loops, a useful comparison of organ density or ex-

trinsic compression can be defined.[10,16,19]

In the patient presented, preoperative evaluation of the abdominal mass by colonoscopy with biopsy revealed a tumor of lymphomatous origin. The combination of barium enema and computed tomography clearly provided a good estimate of tumor bulk that allowed for planning the surgical approach. An arteriogram was performed to define vascularity in the tumor, and a vena cava gram was also helpful in deciding resectability. Ultimately, a more urgent approach to surgery was required because of continuing gastrointestinal blood loss. As shown by Kemeny et al,[14] gastrointestinal bleeding is a major cause of morbidity in patients with abdominal Burkitt's lymphoma. The tumor mass was almost entirely in the right colon, very bulky and with numerous excrescent growths. The omentum was grossly involved and a separate subdiaphragmatic growth was noted. Standard right colectomy, omentectomy, and iliotransverse colostomy were performed. A portion of the muscular diaphragm was resected with the tumor and repair was accomplished with nonabsorbable sutures. The postoperative course was uneventful.

As stated earlier, favorable prognosis in patients with American Burkitt's is expected with high EBV capsid antibodies.[1,24] This patient's antibody titer was markedly elevated at 1:2,560. The lactate dehydrogenase level also decreased to 211 units postoperatively, indicating a decrease in tumor burden.[13,23] Lumbar puncture was negative but the patient received intrathecal methotrexate in addition to M-BACOP because of the high incidence of silent central nervous system relapse in Burkitt's lymphoma.[4,5,12,13]

CONCLUSIONS

The case described here reveals many of the findings characteristic of American Burkitt's lymphoma. It is the authors' contention that after adequate preoperative workup, aggressive surgical extirpation should be performed to reduce tumor burden.

Literature Cited

1. Levine PH, Kamaraju LS, Connelly RR, et al. The American Burkitt's Lymphoma Registry—8 years experience. Cancer 1982; 49:1016-1022.

2. Burkitt DP. The discovery of Burkitt's lymphoma. Cancer 1983; 51:1777-1786.

3. Burkitt DP. A sarcoma involving the jaws in African children. Br J Surg 1958; 46:218-223.

4. Zeigler JL. Burkitt's lymphoma. N Engl J Med 1981; 305:735-745.

5. Zeigler JL. Burkitt's lymphoma. Med Clin North Am 1977; 61:1073-1082.

6. Mann RB, Jaffe ES, Braylan RC. Nonendemic Burkitt's lymphoma. AB cell tumor related to germinal centers. N Engl J Med 1976; 295:685-691.

7. Binder RA, Janatas JA, Chun B, Rath CE. "B" cell origin of malignant cells in a case of American Burkitt's lymphoma. Characterization of cells from a pleural effusion. Cancer 1975; 36:161-168.

8. Giere JW, Binder RA. Burkitt's lymphoma involving ovary and jaw. Obstet Gynecol 1976; 48(suppl 1):639-668.

9. Collins J, Katon RM, Harty-Golder B. Burkitt's lymphoma presenting with gastroduodenal involvement. Endoscopic description and review of literature. Gastroenterology 1983; 85:425-429.

10. Krudy AGM, Dunnick NR, Magrath IT, et al. CT of American Burkitt's lymphoma. AJR 1981; 136:747-754.

11. Zeigler JL. Treatment result of 54 American patients with Burkitt's lymphoma are similar to the African experience. N Engl J Med 1977; 297:75-80.

12. Banks PM, Arsenau JC, Gralnick HR, et al. American Burkitt's lymphoma: A clinicopathological study of 30 cases. II. Pathological correlations. Am J Med 1975; 58:322-329.

13. Arsenau JC, Canellos GP, Banks PM, et al. American Burkitt's lymphoma: A clinicopathological study of 30 cases. I. Clinical factors relating to prolonged survival. Am J Med 1975; 314-321.

14. Kemeny MM, Magrath IT, Brennan MF. The role of surgery in the management of American Burkitt's lymphoma and its treatment. Ann Surg 1982; 196:82-86.

15. Alford BA, Coccia PF, L'Heureux PR. Roentogenographic features of American Burkitt's lymphoma. Radiology 1977; 124:763-770.

16. Dunnick NR, Reaman QH, Head GL, et al. Radiographic manifestation of Burkitt's lymphoma in American patients. AJR 1979; 132:1-6.

17. Levine PH, Connolly RR, Berard CW, et al. The American Burkitt's Lymphoma Registry. A progress report. Ann Med 1975; 83:31-36.

18. Cohen LF, Ballow JE, Magrath IT, et al. Acute tumor lysis syndrome. A review of 37 patients with Burkitt's lymphoma. Am J Med 1980; 68:486-491.

19. Krudy AG, Long JL, Magrath IT, Paling M. Gastric manifestations of North American Burkitt's lymphoma. Br J Radiol 1983; 56:697-702.

20. Janus C, Edwards BK, Sariban E, Magrath IT. Surgical resection and limited chemotherapy for abdominal undifferentiated lymphomas. Cancer Treat Rep 1984; 68:599-605.

21. Magrath IT, Lwanga S, Carswell W, Harrison N. Surgical reduction of tumor bulk in management of abdominal Burkitt's lymphoma. Br Med J 1974; 11:308-312.

22. Hende KR, Fisher RL, Devita VT, et al. Diffuse histocytic lymphoma involving the gastrointestinal tract. Cancer 1978; 41:1984-1989.

23. Osako G, Magrath IT, Elin RJ. The serum total and isoenzyme LDH activity in American Burkitt's lymphoma patients. Am J Clin Pathol 1982; 78:712-717.

24. Benjamin D, Magrath IT, Maguire R, et al. Immunoglobin secretion by cell lines derived from African and American undifferentiated lymphoma of Burkitt's and non-Burkitt's type. J Immunol 1982; 129:1336-1342.