Dermacase

Christopher J. Watt, MD H. Chih-ho Hong, MD

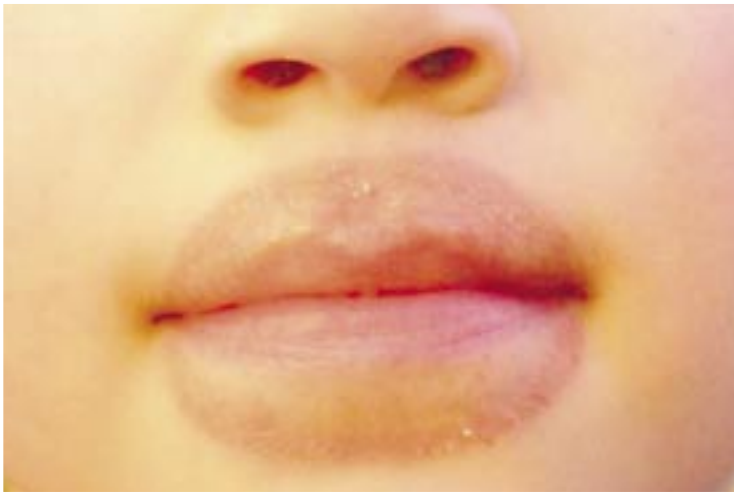

CAN YOU IDENTIFY THIS CONDITION?
A healthy 7-year-old girl presented with recurrent dermatitis around her mouth. The dermatitis worsened during the winter. No previous treatment had been initiated. There was no associated pain and only slight pruritus.

The most likely diagnosis is:
1. Perioral dermatitis
2. Iron deficiency
3. Primary herpes simplex gingivostomatitis
4. Lip licker's dermatitis

Answer on page 1059

Dr Watt *is in private practice in Vancouver, BC.* **Dr Hong** *is a senior resident in dermatology at the University of British Columbia in Vancouver.*

Answer to Dermacase

continued from page 1051

4. Lip licker's dermatitis

There are many causes of eczematous dermatitis[1] in the perioral region. Lip licker's dermatitis is commonly seen in children[2] and is caused by repeatedly licking the lips and the adjacent skin surrounding the vermilion. This leads to the classic distribution of the eruption, with erythema and scaling around the mouth. The condition is actually irritant contact dermatitis caused by saliva. The saliva macerates the skin and removes the protective oils secreted by the skin's sebaceous glands.

Differential diagnoses

Perioral dermatitis is manifested by erythematous papules and pustules. Lesions typically spare the vermilion. It is most commonly seen in women of childbearing age. Iron deficiency presents with angular cheilitis or inflammation of the angle of the mouth. It is sometimes seen in conjuction with atrophy of the oral epithelium and the distinctive koilonychia change in the nails (spoon-shaped nails). Herpes virus outbreaks classically appear as grouped vesicles and erosions on an erythematous base.

Diagnosis and treatment

In this case, diagnosis became clear only toward the end of the visit when the patient was observed to briefly suck her lower lip with her upper lip. Her father confirmed this was a regular habit.

Treatment consists of liberal use of a bland emollient, such as petroleum jelly. Patients with severe inflammation can be treated with a short course of topical low-potency corticosteroids, such as 1% hydrocortisone ointment. Patients (and parents) should be made aware that habitual lip licking will perpetuate the problem and that efforts to minimize or stop the licking will greatly improve the dermatitis.

References

1. Rogers RS III, Bekic M. Diseases of the lips. *Semin Cutan Med Surg* 1997;16(4):328-36.
2. Schachner LA, Hansen RC. *Pediatric dermatology.* 2nd ed. New York, NY: Churchill Livingstone; 1995.