(16 F gauge) is threaded on a curved stylet. The tip is passed through the glottis by indirect laryngoscopy. With the stylet *in situ* the catheter is slipped forward until some three inches have entered the trachea. The stylet is then withdrawn, and the catheter advanced till only the proximal two inches project from the mouth. At this stage there is generally some coughing, which soon subsides, but if it persists a little local anaesthetic should be injected through the catheter. This will prevent recurrence of cough when the oil is injected. The upper end of the catheter should now be anchored to the cheek with adhesive strapping and the patient transferred to the *x*-ray department.

I have found that the use of a catheter with a malleable radio-opaque tip is a great advantage in directing it by fluoroscopic guidance into the lobe chosen. Such a catheter was made for me by Messrs. Down Bros. (See Fig.) It consists of an ordinary rubber catheter into the distal two inches of which is inserted a fine lead tube with a hole corresponding to the eye of the catheter. This is very malleable and is readily detected on the fluoroscopic



screen. A slight bend at the tip facilitates introduction into the selected bronchus. The technique of introduction is the same. I have found no contraindication to its use in adults.

In children the method must be modified owing to the difficulties of indirect laryngoscopy and to the risks of local anaesthesia. It is generally easy to pass a catheter through the nose to the larynx and trachea, introduction being facilitated by extension of the head and flexion of the neck. If this route is chosen the lead-tipped catheter cannot be used.

Bronchography is rarely called for in children under the age of 5, but if it has to be carried out it is better to pass the catheter by direct laryngoscopy.

The positioning of the catheter and the oil injection are controlled by fluoroscopy: 5 to 10 c.cm. will delineate a lobe; 15 to 20 c.cm. is required to outline an entire lung. The position of the patient will vary with the lobe to be dealt with. The erect posture is the most suitable for the lower and middle lobes, and for the upper lobe the patient lies on the back with the opposite shoulder raised. To exclude cavitation of the lingula the anterior part of the upper lobe has to be filled, and the patient should be rolled slightly over on the face.

The film should be made immediately after the lobe has been filled, as even one cough may so spread the oil that definition of the bronchial tree is impaired. For this reason it is advisable to make the exposure on the screening stand. Some loss of accuracy results, but compensation is found in a higher percentage of successes. If coughing has been avoided the patient can then be taken to the usual photographic unit and a second exposure made. The catheter should be left *in situ* till all necessary films have been taken. The depth of exposure is of great importance. The standard exposure is too short to provide the necessary contrast, particularly if the lesion lies behind the cardiac shadow or below the dome of the diaphragm. Increase is obtained by doubling the penetration, and, if necessary, the time also. By this method lesions have been demonstrated which were not visible in plates taken with the usual exposure. Two weeks should elapse before a second bronchogram is taken, so as to allow the lipiodol to be eliminated.

Conclusions

Bronchography is not a substitute for bronchoscopy; it is an adjuvant.

In most cases bronchoscopy should precede bronchography, but in some patients it may be advantageous to reverse the order. In young or nervous subjects, for example, the manipulations of bronchography will prepare them for the more trying ordeal of bronchoscopy.

References

Iglauer, S. (1926). *J. Amer. med. Ass.*, **86**, 1879.
Jackson, Chevalier L., and Bonnier, M. (1937). *Ann. Oto-rhino-laryng.*, **46**, 773.
Lafay, L. (1901). *Ann. Derm. Syph.*, Paris, 4s, **2**, 448.
Sicard, J. A., and Forestier, J. (1922). *Bull. Soc. Chir.*, Paris, **46**, 463.

CRATAEGUS OXYACANTHA IN HYPERTENSION

BY

JAMES D. P. GRAHAM, M.D.

(From the Institute of Physiology and the Medical Wards, Stobhill Hospital, attached to the Department of Materia Medica, University of Glasgow)

Crude extracts of hawthorn (*Crataegus oxyacantha*) have been used as a curative agent for cardiac disease, hypertension, and morbid conditions of the chest since the Middle Ages. The claims of the few who advocate the use of crataegus in such conditions have never been satisfactorily tested. The drug was introduced to medicine in Britain about 1880 by Green, a non-registered practitioner in Ireland. Subsequently it was adopted by the homoeopathic school and incorporated in their authoritative works (Assmann, 1930). In America, Jennings (1906) advocated the use of tincture of crataegus as an adjuvant to and even a substitute for digitalis in the treatment of cardiac disease, while Reilly (1910) recommended its use in cases of cardiac failure with arteriosclerosis and high blood pressure. In France it has long had a certain vogue, and Huchard (1903), Leclerc (1912), and Renon (1915) recommend the use of five minims of the tincture of hawthorn twice daily in order to keep the blood pressure of cases of hypertension within reasonable bounds.

Pharmacology

A series of investigations into the pharmacology of *Crataegus oxyacantha* was undertaken; they may be summarized as follows:

Tincture of crataegus causes sterile abscesses in guinea-pigs into which it is injected subcutaneously. Intravenous infusion of dilutions of the tincture from which the alcohol has been removed increases the gastric motility in anaesthetized guinea-pigs. The motor gradient of the isolated bowel of rabbits is reversed. In mammals intravenous infusion of similar dilutions of the tincture leads to slowing of the heart-beat, prolongation of the diastole with a tendency to idio-ventricular rhythm, and heart-block. The vagal centre in the

medulla is stimulated, the early effects on the heart being inhibited by atropine. The isolated mammalian heart exhibits interference with the conducting system, while the avian heart reacts in a similar way to the mammalian heart. The coronary arteries of the sheep and rabbit and the pulmonary arteries and bronchi in the guinea-pig are constricted by crataegus. The carotid blood pressure of cats anaesthetized with 0.5 grain of nembutal per kilogramme of weight is profoundly depressed by 0.5 c.cm. of non-alcoholic tincture of crataegus per kilogramme of weight. This effect is unaltered by atropinization of the animal, and agrees with the findings of Martini (1932) on the blood pressure of dogs. Subcutaneous injection of tincture of crataegus has an antidiuretic effect on rats. The tincture is toxic to the liver of mammals if repeatedly administered subcutaneously, but does not induce morphological changes in the heart.

It is interesting to note the considerable similarities between the actions of tincture of crataegus and tincture of digitalis.

Pharmacy

A large volume of the tincture of *Crataegus oxyacantha* was made by macerating two kilogrammes of dry powdered whole fruits of hawthorn with 5 litres of 70 per cent. alcohol for seven days, with occasional stirrings, filtering, pressing the marc, and mixing the fluids.

This was assayed against international standard (1926) tincture of digitalis prepared from samples of leaf provided by the National Institute for Medical Research, Hampstead. Biological assay was carried out by the frog and the cat methods on tincture of crataegus from which the alcohol had been removed by maintaining a temperature of 50° C. until the volume was reduced to 20 per cent. of the original volume. The average result of these investigations was that tincture of crataegus has a potency of 14.5 per cent. of standard (1926) tincture of digitalis.

Therapeutics

With the knowledge obtained from the investigations into the pharmacology of *Crataegus oxyacantha* clinical trial of the efficacy of the tincture in cases of cardiac failure and cases of hypertension was begun. Tincture of crataegus is unpleasant to take in large quantities, but does not cause vomiting. It is rejected by the rectum even when given in considerable dilution.

Auricular Fibrillation and Cardiac Failure

In two cases of auricular fibrillation and two of mitral stenosis with orthopnoea, oedema, and tachycardia, massive dosage with tincture of crataegus was employed. Half an ounce of tincture of crataegus was administered six-hourly up to a total amount of twenty ounces in ten days. There was no improvement in the cardiac condition, and oedema advanced steadily. The drug was therefore abandoned as a competitor of digitalis, administration of which rapidly led to improvement in these same patients. The blood pressure of these cases was not affected by the treatment with crataegus.

Hypertension

A series of ten cases of men and women with high blood pressure was chosen. These were in part cases of arteriosclerosis of unknown origin, in part cases of chronic nephritis. All had old-standing hemiplegic lesions and several suffered from mild dementia. The blood pressure in the unaffected arm was recorded daily by the one observer using the same instrument. Only those cases which had been shown to have a stable blood pressure over several weeks were chosen for intensive investigation, and the blood pressure was registered daily for ten consecutive days to establish a basic or normal level for each case. Tincture of crataegus, 1 drachm three times daily in water, was then administered by mouth. The daily readings of the pressure were charted, and the drug was discontinued when it was felt that the pressure had been reduced enough. No ill effects were complained of by any of the patients as a result of this administration. In every case the systolic and diastolic pressure was reduced, often sharply, and returned to its former level some fourteen days after stopping medication. No other treatment was given, the patients being at rest in bed on a light diet. The results of the treatment with tincture of crataegus are summarized in the table and illustrated in the diagram.

Table showing the Effect of Tincture of Crataegus on the Blood Pressure in Ten Cases of Hypertension

Case No.	Age in yrs.	Diagnosis	Systolic B.P.		Diastolic B.P.		Time to Return to Initial Value (Days)
			Initial	During Crataegus Therapy	Initial	During Crataegus Therapy	
1	82	Cerebral haem.	190	150	105	90	10
2	71	,,	195	150	115	80	14
3	84	Arterio-sclerosis	210	150	120	90	14
4	76	,,	200	140	110	80	14
5	67	Cerebral thrombosis	200	150	100	85	12
6	65	Cerebral haem.	240	165	120	90	16
7	66	Chronic nephritis	200	175	115	100	10
8	63	,,	215	160	150	90	17
9	75	,,	195	110	110	70	6 (death)
10	68	,,	200	150	70	55	14

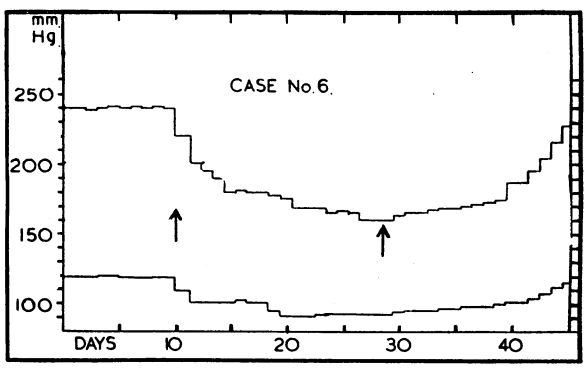

Diagram showing daily blood-pressure readings in a case of hypertension in a man, aged 65, with old-standing hemiplegia. Tincture of crataegus, half a drachm three times daily, was given during the period between arrows.

While the number of cases reviewed is small and the difficulties of adequate control in any investigation on hypertension are notorious, it is felt that a prima facie case has been made which justifies further investigation of tincture of crataegus as a depressor of the elevated blood pressure. In therapeutic doses digitalis produces slowing of the heart, promotes diuresis, and rapidly removes oedema of cardiac origin. The blood pressure in patients so treated is not affected, nor is it appreciably affected in cases of hypertension. Tincture of crataegus, on the other hand, has but little effect in slowing the heart rate, and diuresis is not induced by it. It, however, reduces elevated blood pressures, though large quantities may be taken with but little effect on the normal blood pressure. It is noteworthy that there is no sign of cumulative action, and that after cessation of the drug the blood pressure returns to its previous level.

Summary

The published work on *Crataegus oxyacantha* is briefly reviewed.

The pharmacology of crataegus is summarized and its resemblance in action to digitalis discussed.

The effect of tincture of crataegus in massive doses on cardiac failure, if there is any, is slight.

Ten cases of hypertension are reviewed and the result of treatment with 1 drachm of tincture of crataegus three times daily is shown to be that of a uniform lowering of the systolic and diastolic blood pressure.

This work was carried out with the aid of a grant from the Medical Research Council. Grateful acknowledgments are due to Professors E. P. Cathcart and N. Morris of the Departments of Physiology and Materia Medica for help and advice.

REFERENCES

Assmann, K. (1930). *Dtsch. Z. Homoeopath.*, **10**, 72.
Huchard, J. (1903). *Rev. gén. chim. Thér.*, **3**, 103.
Jennings, J. (1906). *N.Y. med. J.*, **27**, 743.
Leclerc, H. (1912). *Courrier méd.*, 114.
Martini, E. (1932). *Biochem. Terap. sper.*, **19**, 289.
Reilly, T. F. (1910). *J. Amer. med. Ass.*, **54**, 103.
Renon, L. (1915). *Pharm. Zeit.*, **1**, 181.

Clinical Memoranda

Treatment of Pneumonia in Children with Sulphapyridine and Vaccines

Recent evidence (experimental, not clinical) indicates that in pneumonia treatment by sulphapyridine (M & B 693) is enhanced by vaccines, because it was found that the resulting antibodies were bactericidal while the drug was merely bacteriostatic (Maclean, Rcgers, and Fleming, 1939 ; Fleming, 1939).

CLINICAL EVIDENCE

I now submit the clinical evidence of combined sulphapyridine and vaccine treatment in fifty-two cases of pneumonia (lobar and lobular) under Dr. F. C. Eve at the Victoria Children's Hospital, Hull, during the first half of this year. These were all children between the ages of 1 and 12 years. The results have been remarkably good, as indicated by the reduction of oxygen treatment almost to *nil*. In all cases the temperature fell within three days and remained down, except in the case of one patient to whom the full dose of sulphapyridine had not been given. Sequels arose in only two cases. In one there was an empyema in an infant aged 2 years, which was due to pneumococci only ; this disappeared without operation after one small aspiration (clear, according to *x*-ray examination, after six weeks). In the other case spontaneous pneumothorax occurred twice in a child aged 4 years, with complete recovery.

The average stay in hospital of these fifty-two cases was ten days and there were no deaths, whereas in the corresponding six months of 1938 ten cases of pneumonia were treated, with one death and an average stay in hospital of 16.6 days. In 1937 eleven cases were treated, with one death and an average stay in hospital of 18 days. In 1937 and 1938 vaccine treatment alone was given.

Regardless of the age of the child Wynn's vaccine was given as follows: 1/3 c.cm. on the first day ; 2/3 c.cm. on the second day ; 1 c.cm. on the third day. Sulphapyridine was administered in the following doses, four-hourly, and was stopped after three days' absence of fever: ¼ tablet under 6 months ; ½ tablet under 2 years ; ¾ tablet under 5 years ; 1 tablet under 12 years.

Clear cases of bronchitis were not thus treated, but in children it is often impossible to be sure of a diagnosis on admission, and it was felt safer to treat all cases thought to be of pneumonia rather than to wait and see. In this series there was no evidence of any harmful effects from sulphapyridine except in two cases in which mild vomiting occurred, which stopped on omission of the drug, and one mild rash, which also subsided quickly.

In conclusion, our impression of sulphapyridine used in combination with Wynn's vaccine is that (1) the pneumonia is shortened ; (2) the drug is entirely harmless ; (3) the death rate is probably reduced ; (4) it is necessary to give full doses of sulphapyridine.

My thanks are due to Dr. F. C. Eve for suggesting the publication of these cases.

DEIRDRE M. LEWIS, M.B., Ch.B.,
House-physician, Victoria Hospital for Sick Children, Hull.

REFERENCES

Fleming, Alexander (1939). *British Medical Journal*, **2**, 99.
Maclean, I. H., Rogers, K. B., and Fleming, A. (1939). *Lancet*, **1**, 562.

A Wound of the Left Common Carotid Artery

The following case seems interesting enough to be placed on record.

An engineer aged 26 was admitted to the Willesden General Hospital on the afternoon of July 30, 1939, about twenty minutes after an accident sustained while at work. It is understood that a workmate, being of an inquiring disposition, had screwed up a boxful of phosphorus match heads in a vice, thereby producing an interesting explosion. The explosion, however, was considerably more violent than expected: a small piece of steel was projected some yards and struck the patient violently on the left side of the neck, causing him to fall unconscious. He soon recovered consciousness, and was given first-aid treatment and then removed to hospital. It is stated that there was profuse arterial bleeding.

CONDITION ON ADMISSION

On admission the patient was grey and shocked, and arterial blood was spurting from a small punctured wound over the left sterno-mastoid muscle at the level of the hyoid bone. The casualty officer, Mr. Campbell, suspected a wound of one of the major vessels, and while waiting for me applied a firm pad and bandage. When I saw the man a few minutes later he was complaining of a tight feeling in his neck and a difficulty in breathing. I removed the bandage and found that the external haemorrhage had ceased ; but his symptoms continued, and it became obvious that the dyspnoea was due not to the tight bandage but to marked displacement of the larynx to the opposite side of the neck. The history and physical signs certainly suggested that the carotid artery had been punctured, and although it appeared that haemorrhage had ceased there remained a definite possibility that this might recur either when the blood pressure rose to normal or when some sudden movement was made. I concluded, therefore, that immediate exploration was the safest procedure.

OPERATION

One hour after admission operation was performed under gas-and-oxygen anaesthesia preceded by intravenous pentothal sodium. The skin edges of the wound were excised and the wound enlarged. An ill-defined track passing vertically through the sterno-mastoid muscle was visible and was very gently palpated for the presence of a metallic foreign body. The result of this manœuvre was a sudden and furious arterial haemorrhage, so severe as to indicate that either the common carotid artery or one of the main terminal branches was involved. Direct pressure through the sterno-mastoid by means