colleagues of the Oldham and District General Hospital for their help in the management of the patient.

S. JAWAHEER, M.B., Ch.B., B.Sc.,
Late House-physician,
Oldham and District General Hospital.

REFERENCES

Cope, O., Culver, P. J., Mixter, C. G., and Nardi, G. L. (1957). *Ann. Surg.*, **145**, 857.
Hellström, J. (1954). *Acta endocr. (Kbh.)*, **16**, 30.
Smith, F. B., and Cooke, R. T. (1940). *Lancet*, **2**, 650.

A Case of Pulmonary Acariasis—Histopathological Findings of Resected Lungs

The medical literature contains three incidental observations on pulmonary acariasis in the monkey (Landois and Hoepke, 1914; Weidman, 1916; Davis, 1945), but there have been few reports of attempts to ascertain the histopathological findings in man. We have had an opportunity of seeing a patient with this disease who was operated on, and the resected lung was used for microscopical examination. The purpose of this paper is to present the pathological findings of pulmonary acariasis and to explain the route of infestation of the mite, the behaviour of the parasite, and its pathophysiology.

CASE REPORT

A 53-year-old housewife entered hospital on December 6, 1958, with sharp pain in her left chest and blood-tinged sputum. *X*-ray examination of the chest showed a localized lesion in the anterior segment of the left upper lung lobe (S 3). Leucocytes numbered 8,400/c.mm. (17% eosinophils). Sputum examination was negative for malignancy and tubercle bacillus, but positive for the mite. This was thought to be one of the Tyroglyphidae (Fig. 1). The patient seemed to respond to treatment with emetine and oxytetracycline; she was afebrile, and the eosinophilia returned to normal. The chest pain, cough, and sputum subsided. Radiological features showed some regression, and she was allowed to return home on February 16, 1959.

On March 26 she was readmitted to hospital with a history of blood-tinged sputum of five days' duration and an attempt was made to initiate a segmental resection. An *x*-ray film taken before operation showed the diffuse infiltration to be resolved, leaving the striated shadow with small nodules. The leucocyte count was 6,000 (eosinophils 2.5%, lymphocytes 43%).

Operative Findings.—When the chest was opened the anterior segment of the left upper lobe was found to be fixed by fibrous adhesions to the anterior thoracic wall accompanied by increased vascularization. When removed, fairly extensive haemorrhages were seen and S 3 was somewhat atrophied and firm in consistency.

Macroscopic Findings.—The resected segment was atrophied. Its surface was considerably congested and an area of pleural thickening was present in the antero-inferior aspect of the resected lung. The cut section revealed the fibrotic element projecting into the hilus. The peripheral area, especially beneath the thickened pleura, showed the dilated bronchioles and multiple small yellow nodules, millet-seed to pin-head in size, scattered throughout the terminal area.

Histological Findings.—The bronchioles were distended with homogeneous material stained by eosin, a few erythrocytes, leucocytes, and ova with eggshell stained by haematoxylin, measuring 0.06 mm. in diameter (Fig. 2). The epithelium was destroyed and desquamated or disappeared. In the peribronchial area the lymph apparatus was well developed. Some parts of the alveolar walls were composed of fibrous tissues by which the lumen became narrowed, whereas the alveolar epithelium showed a dice-shaped metaplasia. Some other alveolar walls consisted either of clumps of lymphocytes or of histiocytes which became inflated and frothy (Fig. 3). In some areas similar cells were found to be filled in the alveoli. These may be the result of fatty degeneration. However, the majority of histiocytes that did not undergo fatty degeneration were also found, but some of them became confluent to form foreign-body giant cells here and there. These histiocytes contained black-brown pigment granules which were not stained by iron. The small blood-vessels were dilated and congested, and haemorrhages in the alveoli were also found in some areas. Intralobular connective tissues were markedly fibrotic and oedematous.

CONSIDERATIONS

The macroscopic pathology in our case is similar to that in the monkey published by others, except for nodule formation in which, according to Davis (1945), the mite was centrally located. Although we were unable to demonstrate positive evidence of the mite in several sections of the specimen, many ova were found in the bronchioli. In the light of this fact, it is more

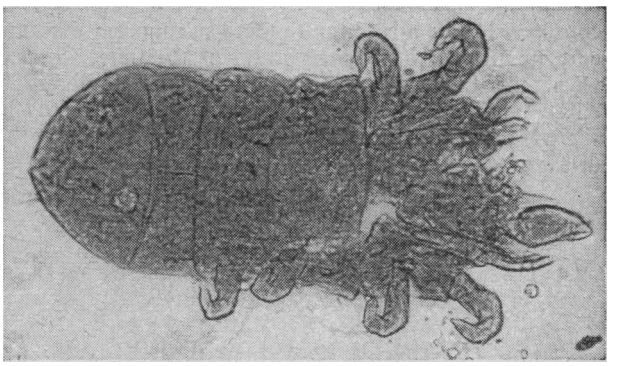

FIG. 1.—Tyroglyphus mite in the sputum.

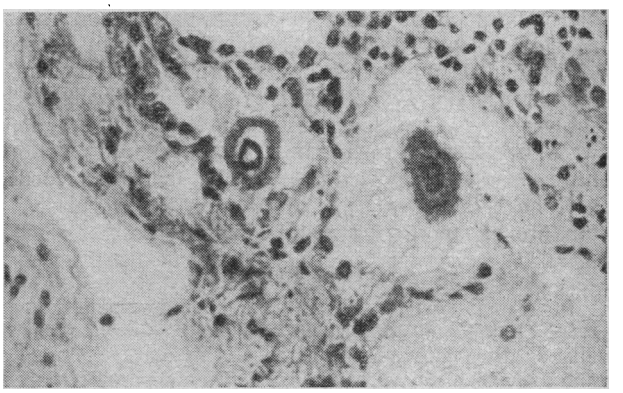

FIG. 2.—Microscopical appearance of ova in the dilated respiratory bronchioles.

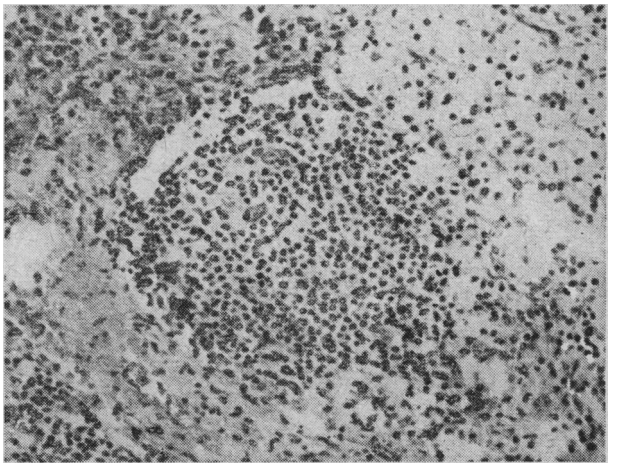

FIG. 3.—Lymphocytic, histiocytic infiltration in alveolar walls and desquamated cells with fatty degeneration in alveoli.

profitable to think of the damaged bronchus as a lodging-place where the tyroglyphus mite may grow by ingestion of secretions and products of inflammation in the bronchus, because the mite develops in a disintegration product of organic matter. The possible route of infection through the alimentary tract cannot be entirely dismissed if the mite is located in a nodule that does not communicate with the bronchus. Such a finding was not observed.

The lesions in the alveolar and peribronchial areas were composed of histiocytic or lymphocytic infiltration without leucocytes being seen, indicating the presence of subacute inflammation. Large quantities of black-brown pigment granules were present either free or taken up in the histiocytes. It was supposed by Landois and Hoepke (1914) that the pigment granules were produced by the mite. Bronchopneumonia accompanied by pulmonary acariasis is considered to be a reaction to these substances. Natural cure may occur by expectoration of the mite, whereas when the bronchus becomes damaged and loses its ciliated epithelium, as in our case, the mite remains in the bronchus for a long time, to delay the course of the disease.

S. KIJIMA, M.D.,
Kobe Municipal Central Hospital, Kobe, Japan.

REFERENCES

Davis, L. J. (1945). *Brit. med. J.*, **1**, 482.
Landois and Hoepke (1914). *Zbl. Bakt.*, **73**, 384.
Weidman, F. D. (1916). *J. Parasit.*, **2**, 37.

Reaction to "Varidase"

Streptokinase is used as a fibrinolytic agent in a variety of conditions (Symposium on Fibrinolysis, 1960; *British Medical Journal*, 1962). Pyrexial reactions to streptokinase and streptodornase have been reported frequently (Ambrus *et al.*, 1960). These preparations were early shown to be antigenic (Christensen, 1949), but reactions were then thought to be rare. Anaphylactoid reactions have since been reported (Blix, 1961). Below is recorded a Henoch–Schönlein type of reaction to "varidase," a mixture of streptokinase and streptodornase.

CASE REPORT

In March, 1961, a 47-year-old soldier developed a right renal abscess. There was no previous history of renal or allergic disease. No renal tissue was found at exploration, and a biopsy of the abscess wall showed non-specific granulation. Since this time there has been a discharging sinus from the area. Repeated cultures have grown a coagulase-positive staphylococcus; neither tubercle bacilli nor actinomyces have been recovered. Antibiotics, local toilet, and re-exploration in December, 1961, failed to heal the sinus.

Varidase therapy has been reported to be useful in the management of chronic abscesses. On January 26, 1962, daily instillations into the sinus were begun with topical varidase (one ampoule in normal saline). On March 5 the patient reported the development over the previous two days of a rash and vague joint pains. The rash was a generalized purpura. Pain and stiffness affected first the ankles and later the knees, wrists, and fingers. One or two joints would be affected for 24 to 48 hours and then gradually settle, only to flare up again some days later. On March 9 instillations were stopped but there was little change in his condition. Two further instillations were given on March 22 and 23. Four days later an exacerbation occurred and he was admitted to Auckland Hospital.

On examination the lower trunk, legs, and forearms were covered with purpuric spots up to 2 mm. in diameter. The face and mucous membranes were unaffected. Temperature was 100° F. (37.8° C.). Fluctuating joint pains continued during his stay in hospital. The affected joints were tender, warm, and sometimes swollen, and movement was extremely painful.

No streptococci were found in the throat or urine or in swabs from the sinus. Bleeding-time, clotting-time, platelet count, Owren's prothrombin clotting-time, prothrombin consumption index, clot retraction, and capillary fragility tests were normal. Bone-marrow examination showed a moderate increase in lymphocytes, eosinophils, and plasma cells.

Antistreptolysin-O titres at 5, 15, and 51 days from the exacerbation were 1 in 12, 1 in 625, and 1 in 500. Precipitin tests were performed three weeks after the first episode and two days after the exacerbation. One ampoule of topical varidase was dissolved in 15 ml. of sterile water. This was titrated against the patient's serum diluted with normal saline. Prompt precipitation occurred at 56° C. maximal on both occasions with a dilution of 1 in 50 of antigen solution and 1 in 20 of serum. No precipitation occurred with two controls.

Repeated mid-stream urine specimens contained 20 to 50 red cells and 20 to 30 leucocytes per high-power field, with a trace of protein but no organisms. Blood urea was raised to a maximum of 120 mg./100 ml.

The condition settled spontaneously after four weeks, although the abnormal urine findings persisted. Two weeks later an intradermal test with varidase produced a violent response. A local weal developed within minutes, spreading to an area of 10 by 5 cm. At 24 hours the whole forearm was red, swollen, and painful. This settled without treatment over three days.

DISCUSSION

Topical varidase is a partly purified preparation which contains in each ampoule 100,000 Christensen units of streptokinase and 25,000 units of streptodornase, together with smaller amounts of hyaluronidase, ribonuclease, and enzyme inhibitors. The occurrence of allergic reactions is not surprising. Better-purified fibrinolytic agents produce fewer reactions. After therapy there is a variability in antibody levels which may be related to previous streptococcal infections. Antibodies which can persist for many months may render further therapy useless and occasionally dangerous (Blix, 1961). Specific antigen-antibody precipitin reactions have not been reported.

In the present case treatment with varidase was continued for longer than the usual period. An allergic reaction developed after six weeks' therapy with an exacerbation following readministration two weeks later. The results of precipitin tests and a subsequent intradermal test suggest that varidase was the cause of the allergic reaction. Although the antigen is unknown, the rise in antistreptolysin-O titre suggests that it was one of the enzymes. It is possible that the reaction could have affected the kidneys, but other features make it more likely that the abnormal urine findings and raised blood urea were the result of chronic pyelonephritis.

There is no previous record in the literature of a Henoch-Schönlein reaction to varidase.

We thank Dr. F. R. Chisholm, under whom the patient was admitted to hospital, for permission to publish this case.

J. M. NEUTZE, M.B., Ch.B.,
Medical Registrar, Auckland Hospital, New Zealand.
A. R. BEAN, M.B., Ch.B.,
Resident Medical Officer, Camp Hospital, Papakura, Auckland New Zealand.

REFERENCES

Ambrus, J. L., *et al.* (1960). *Amer. J. Cardiol.*, **6**, 462.
Blix, S. (1961). *Acta med. scand.*, **170**, 201.
Brit. med. J., 1962, **1**, 1398.
Christensen, L. R. (1949). *J. clin. Invest.*, **28**, 163.
Symposium on Fibrinolysis (1960). *Amer. J. Cardiol.*, **6**, 367 *et seq.*