INFECTION OF HUMAN SKIN, GRAFTED ON THE CHORIOALLANTOIS OF CHICK EMBRYOS, WITH THE VIRUS OF HERPES ZOSTER *

ERNEST W. GOODPASTURE, M.D., and KATHERINE ANDERSON, Ph.D.
(From the Department of Pathology, Vanderbilt University School of Medicine, Nashville, Tenn.)

Although herpes zoster has not been undoubtedly transmitted to experimental animals there is good evidence that its causative agent has been successfully inoculated into human beings and that it is a virus. The first to accomplish human inoculation was Kundratitz[1] in 1925. In his first experiments three children were inoculated after scarification on the upper arm, with clear contents of zoster vesicles. In two of these, after 11 days, there appeared in the area of inoculation several clear vesicles with a slight reddening of the periphery. The appearance corresponded quite completely with inoculatory vesicles of varicella first induced locally in man by Kling[2] in 1913. The vesicles healed during 2 or 3 days and became dry.

Following these first positive results Kundratitz inoculated material from nine typical cases of thoracic zoster into human skin. Material from four of these resulted in typical vesiculation locally in the skin of several children. The reaction appeared 9 to 12 days after inoculation.[1]

In 1921, Lipschütz[3] described acidophilic intranuclear inclusions in the cutaneous lesions of zoster which he considered to be specific. His observations have been repeatedly confirmed and now the presence of acidophilic intranuclear inclusions is regarded as the most specific characteristic of the zoster lesion, although the inclusions are indistinguishable from those first described by Tyzzer[4] in cutaneous lesions of varicella. Their presence is taken to signify the effect of a virus. Kundratitz removed some of his experimental lesions and submitted them for histological study to Lipschütz who demonstrated in them the characteristic inclusions. The successful inoculations were in children under 5 years of age, some of them nurslings; those in older children were negative.

The etiological agent of herpes zoster has never been successfully inoculated into any animal in series other than man, although Lipschütz[3] and Marinesco and Draganesco[5] reported the presence of acidophilic intranuclear inclusions in the corneal epithelium of rabbits after inoculation with vesicular contents. Others, including Cole and Kuttner,[6] who reviewed the subject, failed to confirm these results.

* Aided by a grant from the John and Mary R. Markle Foundation.
Received for publication, July 31, 1943.

Further light on the nature of zoster virus and its relation to other viruses, especially that of chicken-pox which some investigators believe to be identical, awaits the discovery of a susceptible experimental animal other than man, or the development of a technic by means of which these important problems can be studied.

In attempts to devise a method of this sort, Goodpasture, Douglas and Anderson,[7] in 1938, succeeded in grafting human skin onto the chorioallantois of chick embryos so that it would survive for several days. Such human skin grafts were successfully inoculated with the viruses of herpes simplex, variola and vaccinia, but all of our attempts to infect the grafts with the virus of chicken-pox failed and in only one set of experiments, out of several, in which human skin grafts were inoculated with the clear fluid from zoster vesicles, did we succeed in inducing specific lesions of this disease. Inoculations of grafts of human fetal membranes (amnion, chorion) with material from vesicles of varicella and zoster were all unsuccessful.[8]

Although we succeeded only once after several attempts in infecting with zoster virus human skin grafted on the chick's chorioallantois, we decided to describe our positive results in the hope that others might have more favorable opportunity to use the method with success. The problem of obtaining suitable skin for grafting and at the same time to be in possession of uncontaminated fluid from zoster vesicles we found to be a difficult one, especially because our facilities permitted us to obtain only minimal quantities of fluid from occasional cases of zoster.

Human Skin Grafts

The technic for grafting human skin onto the chorioallantois of chick embryos we have previously published[7] in detail and it need not be repeated here. We will therefore describe only the materials and conditions of our successful experiments with zoster, the circumstances of which possess some points of interest.

Source of Human Skin for Grafts. The patient was a white woman, 57 years of age, upon whom a radical mastectomy was performed for scirrhous carcinoma of the right breast. The defect was closed with a single Thiersch graft taken from the right thigh. Pieces of this skin were used to graft on the chorioallantois of 12 9-day-old chick embryos.

It is of interest that the donor gave a history of an attack of shingles in the right thoracic region 8 months previous to her operation.

Source of Herpes Zoster Virus. Clear, vesicular fluid was removed from a band of eruption extending across the right side of the back and into the axilla of a child, 2½ years old. This child had experienced a typical attack of chicken-pox 1 year before admission for zoster.

The clinical description of the zoster eruption was as follows: Starting at the midline in the back at about the second thoracic vertebra there was a band of splotchy erythema about 2 cm. in width extending anteriorly to the midsternal line. There was one small erythematous patch, 1.5 cm. in diameter, high in the axilla upon which were multiple small vesicles not larger than 1 mm. in diameter. Several more patches of blisters were situated anteriorly in which the vesicles were much larger. It was from the latter, especially, that material was obtained for inoculation of the grafts. There was no pustulation.

Inoculation of the Grafts

The skin was prepared by the surgical routine for grafting consisting of scrubbing with soap and water and the application of tincture of iodine which was followed by alcohol. After removal, pieces of skin were delivered to us in moist sterile gauze. These pieces were spread out on sterile cork blocks with the epidermis upward. They were cut into 1 cm. squares. Upon the epidermis of each was placed a drop of undiluted vesicular fluid from the syringe in which it was aspirated. With the syringe needle (size 27) multiple punctures were made through the fluid into the surface of the skin. An attempt was made to keep all of the fluid confined to the central portion of the graft. After puncturing, the graft was left for 1 hour on the cork, moistened along the edges with sterile saline solution and lightly covered with moist gauze. This was done in order to allow the vesicular fluid to be absorbed by the skin while the underlying corium was kept in a moist state.

Each graft was then placed upon the chorioallantois of a 9-day-old chick embryo in the manner we have previously described. The grafts adhered successfully and the eggs were incubated for 4, 6, 7 and 8 days, at which intervals living eggs were opened and the grafts with the adherent chorioallantois were removed and fixed in Zenker's solution for histological study. Suggestive but indefinite pin-point lesions were seen grossly on some of the grafts.

After paraffin embedding, sections were stained with hematoxylin and eosin.

Description of the Lesions

Five grafts removed from this series of embryos showed microscopical lesions which were interpreted as evidence of infection with the virus of herpes zoster. One of these was fixed 4 days after inoculation and grafting, 1 on the sixth day, 2 on the seventh day and 1 on the eighth day. Grafts made on the fourth and sixth day showed small foci in an early stage of development; the 8-day graft contained larger

and pustular foci, as many as three being present in a single section. That the foci of infection corresponded with points of puncture at the time of inoculation was indicated in some by the presence of a foreign body reaction beneath the center of the lesion in the chorion or underlying chorioallantois, where evidently a minute fragment of keratin was forced through.

The earliest lesions consisted of small groups of hyperplastic epithelial cells situated in or near the basal layer and free from inflammation. Both cytoplasm and nuclei were swollen and each of the latter contained within its clear nucleoplasm a large, compact acidophilic body. The nuclear chromatin and often the nucleolus were situated peripherally next to the thin nuclear membrane. In older lesions the number of cells involved was much greater, the individual cells were enormously swollen, the enlargement involving both cytoplasm and nucleus. In the center of such a focus the epithelial cells were separated one from another by inflammatory fluid and cellular exudate consisting largely of chick leukocytes. Cellular exudate was present in the corium and underlying chorioallantois, especially abundant about blood vessels. Lying here and there in the purulent exudate of the infected epithelial layer were occasional multinucleated epithelial giant cells, each nucleus or nuclear lobule of which contained an acidophilic inclusion.

The lateral margins of these larger foci showed an extension of the infection to adjacent groups of epithelial cells. These cells were swollen, pushed apart by fluid and contained intranuclear acidophilic inclusions, but there was no cellular exudate.

Few of the involved epithelial cells, even in the most advanced lesions, were evidently necrotic; only rare ones stained so deeply with eosin as to indicate death. In none of the lesions had sufficient fluid accumulated to cause gross vesiculation.

In none of the specimens was there evidence of infection of chick cells as would be indicated by the presence of intranuclear inclusions. In spite of numerous attempts we have never been able to induce in any chick tissue lesions indicative of infection with material from herpes zoster. This is in contrast with the susceptibility of chick embryo tissues, including the chorioallantois, to the virus of herpes simplex.

Discussion

There is acceptable evidence that the characteristic lesion of both varicella and herpes zoster can be induced locally by direct inoculation of the respective vesicular fluid in scarified human skin.[1, 2] Our failures thus far with chickenpox, and similar numerous failures with zoster,

in attempts to infect grafts of human skin and fetal membranes, amnion and chorion, leave us without an adequate explanation. Although it might be assumed that the original grafts were immune to these viruses, we have demonstrated in other experiments with skin of chickens immune to fowl-pox and human skin immune to vaccinia that, when grafted onto the chorioallantois, the acquired immunity is lost and susceptibility returns.[9] In the successful experiments herein reported there was good reason to believe that the donor was immune to zoster inasmuch as she had experienced an attack of shingles only 1 year previously.

Reports of successful human transmission of cutaneous infections with the viruses of chicken-pox and of herpes zoster have indicated the first appearance of lesions in 8 to 11 days, whereas following inoculation with herpes simplex lesions appear in 2 to 4 days. In our successful experiments with zoster the first lesions without inflammation appeared in grafts of 4 days' duration, whereas with herpes simplex full-blown lesions occur in 2 to 3 days.

Most successful transmission experiments with zoster fluid have been in infants or children under 5 years of age, possibly because of lack of acquired immunity. In our experiment skin grafts were from an adult 57 years of age, and presumably these grafts lost their acquired immunity as a result of transplantation to the chick embryo. As is the case in infection of grafts of human amniotic epithelium with the virus of mare abortion, the successful inoculations of human skin with zoster fluid demonstrate that a natively susceptible tissue grafted on a naturally insusceptible host (chick embryo) does not thereby lose its susceptibility.[8]

In view of our negative results in several similar attempts to infect human grafts with zoster fluid the thought has occurred to us that the skin of some persons might be especially susceptible to this virus as indicated possibly by a previous attack of shingles in our donor. On the other hand, our successful experiment occurred in the only series in which both fresh zoster fluid and fresh skin were obtained and used on the same day; and this fact might have contributed in some way to the positive outcome.

In spite of several attempts we have not yet succeeded in infecting human skin or fetal membrane grafts with the virus of chicken-pox. If this technic were developed so that both varicella and herpes zoster could be uniformly induced in grafts of human tissue, there would be the possibility of using it to determine the relationship of these viruses to each other, and to discover some of their properties in the absence of a susceptible experimental host other than man.

Our experiments indicate that the epithelial cells of human skin may be immediately susceptible to the zoster virus and that an initial infection of nervous tissue is not essential to the development of a cutaneous eruption.

Notwithstanding the development of a local pustular lesion in the grafted skin, associated with swelling and disruption of cellular contacts and the appearance of multinucleated epithelial giant cells, the final criterion of infection with the zoster virus is the presence of intranuclear acidophilic inclusions indistinguishable from those in the lesions of chicken-pox, as first described by Tyzzer,[4] and those of zoster, as noted first by Lipschütz.[3]

Because of the fact that clinically and histologically the eruptive cutaneous lesions of chicken-pox and zoster may be indistinguishable, and the further fact that clinically chicken-pox may be associated with a zosteriform lesion and that zoster may be associated with a generalized nonneural cutaneous eruption, it is of great importance to use typical clinical cases of these diseases in experimental attempts to demonstrate and transmit a specific virus.

The lesions induced in human skin grafts inoculated with zoster fluid do not closely resemble those of herpes simplex in similar tissue. In the latter the inclusions become much larger, often filling the nucleus; and they acquire a basophilic staining reaction.[8] Simplex virus rapidly kills the cell, causing ulceration and an excessive purulent exudation.

Experimental zoster lesions in grafted human skin serve to throw some light on the pathogenesis of the zoster eruption, a subject which is still a matter of controversy. Only recently a review by Baird[10] so overemphasizes the participation of a neurovascular mechanism as to imply a denial of the local presence of a virus in the skin. No mention is made in that paper of cellular inclusions in the vesicles of zoster.

It is clear from our experiments that lesions composed of epithelial cells containing the zoster inclusions and later infiltrated with chick leukocytes can follow inoculation of human skin removed from its normal nervous and vascular connections. The failure of these lesions to develop completely as vesicles indicates the importance of neurovascular connections for the formation of the abundant serous exudate in the human eruption, but these relations to nerves and vessels do not determine the specific character of the lesions.

Conclusions

1. Grafts of human skin on the chorioallantois of chick embryos were successfully infected with the virus of herpes zoster.

2. The experimental lesions did not vesiculate grossly but became pustular, and otherwise resembled those in the natural disease, including the presence of intranuclear acidophilic inclusions, first described by Lipschütz,[3] in the affected epithelial cells.

3. The tissues of the chick embryo appear to be nonsusceptible to this virus.

REFERENCES

1. Kundratitz, K. Experimentelle Übertragungen von Herpes zoster auf Menschen und die Beziehungen von Herpes zoster zu Varicellen. *Ztschr. f. Kinderh.*, 1925, **39**, 379–387.
2. Kling, C. A. Ueber Schutzimpfung gegen Varicellen. *Berl. klin. Wchnschr.*, 1913, **50**, 2083.
3. Lipschütz, B. Untersuchungen über die Ätiologie der Krankheiten der Herpesgruppe (Herpes zoster, Herpes genitalis, Herpes febrilis). *Arch. f. Dermat. u. Syph.*, 1921, **136**, 428–482.
4. Tyzzer, E. E. The histology of the skin lesions in varicella. *Philippine J. Sc.*, 1906, **1**, 349–372.
5. Marinesco, G., and Draganesco, S. Contribution a la pathogénie et a la physiologie pathologique du zona zoster. *Rev. neurol.*, 1923, **1**, 30–45.
6. Cole, R., and Kuttner, A. G. Etiology of herpes zoster. *J. Exper. Med.*, 1925, **42**, 799–820.
7. Goodpasture, E. W., Douglas, B., and Anderson, K. A study of human skin grafted upon the chorioallantois of chick embryos. *J. Exper. Med.*, 1938, **68**, 891–904.
8. Goodpasture, E. W., and Anderson, K. Virus infection of human fetal membranes grafted on the chorioallantois of chick embryos. *Am. J. Path.*, 1942, **18**, 563–575.
9. Goodpasture, E. W., and Anderson, K. Immunity to fowl-pox studied by means of skin grafts on chorioallantois of chick embryos. *Arch. Path.*, 1940, **30**, 212–225.
10. Baird, P. C., Jr. Herpes zoster. *New England J. Med.*, 1943, **228**, 568–577.

[*Illustrations follow*]

DESCRIPTION OF PLATE

PLATE 86

FIG. 1. Pustulating zoster lesion in human skin graft. (8 days.)

FIG. 2. Early (6 days) nonexudative zoster lesion in grafted human skin. Swollen, detached epithelial cells are shown, containing intranuclear inclusions. × 225.

FIG. 3. Intranuclear inclusions from the lesion shown in Figure 1. × 1200.

FIG. 4. Epithelial giant cell with intranuclear inclusions from Figure 1. × 1200.

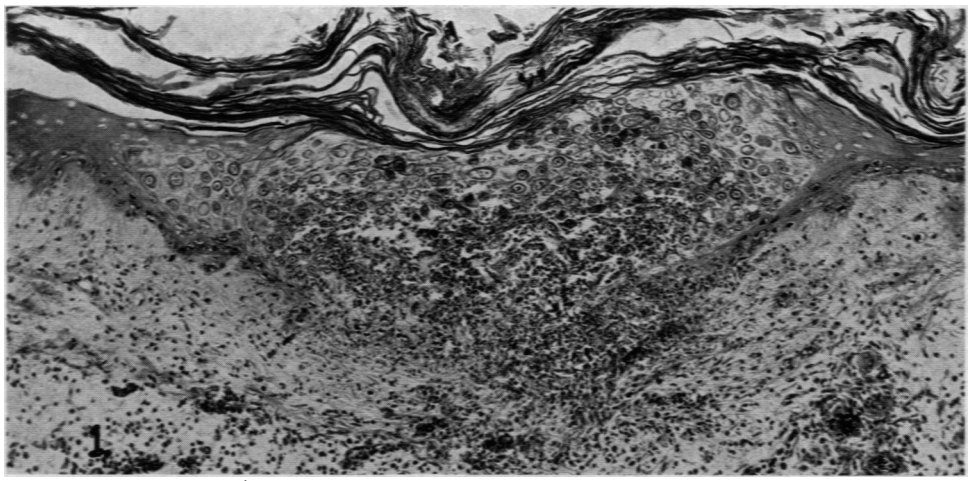

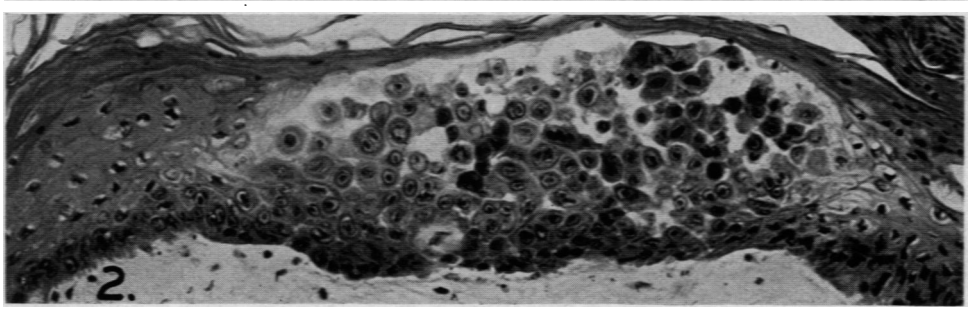

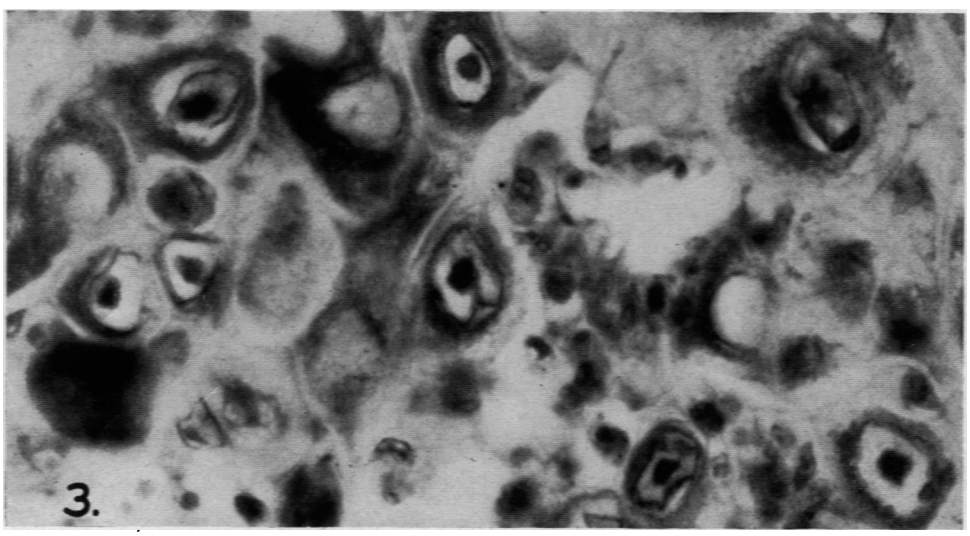

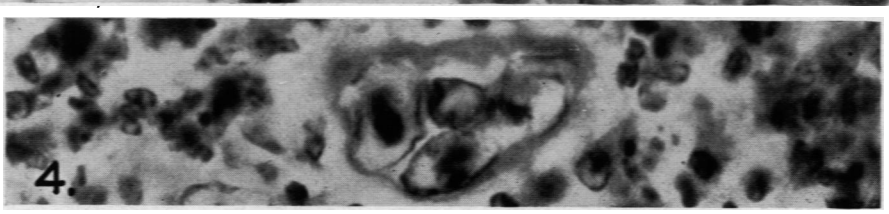

Goodpasture and Anderson Herpes Zoster Virus in Grafted Human Skin