HISTOPATHOLOGY OF KIDNEY DISEASE IN FISH *

E. M. Wood, Ph.D., and W. T. Yasutake, B.A.
From the U.S. Fish and Wildlife Service, Salmon Nutrition Laboratory, Cook, Wash.

Kidney disease is one of the most puzzling fish diseases known to exist in the United States. In less than 10 years it has invaded the Pacific Northwest, exacting a heavy toll of hatchery salmon. Its first appearance apparently was in Massachusetts where Belding and Merrill[1] described a disease similar to that now seen on the Pacific Coast. In 1946 it was diagnosed in Washington[2] and since that time has been observed in an ever increasing number of hatcheries. There are unpublished reports of the same or similar diseases in both California and Washington in the early 1930's.[3] The latest outbreaks occurred in the Federal hatcheries at Berlin, New Hampshire, and Cortland, New York, in brook, brown, and rainbow trout.[4] There is evidence to indicate that the disease may be much more widely spread in New York State.[5]

The disease is especially dangerous since little is known of the origin or source of the causative agent. Indeed, the classification of the diplobacillus associated with kidney disease is still uncertain. Thus, with our present knowledge, it is difficult or impossible to eradicate the malady from an infected hatchery.

Histopathologic studies were undertaken to clarify the pathology of the disease and to compare the eastern form with the western form.

Materials and Methods

Fish exhibiting the typical lesions of kidney disease were selected from two eastern and two western hatcheries which were having active epizootics. Yearling and fingerling brook trout were available from the Fish and Wildlife Service stations at Cortland, New York, and Berlin, New Hampshire. Yearling coho salmon were received from the Oregon Fish Commission station at Sandy, Oregon, and yearling fall chinook salmon from the Fish and Wildlife Service station at Underwood, Washington.

These fish were fixed in Bouin's solution for approximately 24 hours, then stored in 65 per cent alcohol. Paraffin sections were prepared from the tongue, eyes, brain, gill, heart, dorsal and ventral muscles, kidney, liver, gallbladder, air bladder, spleen, and from the digestive tract at seven equally divided regions. The sections were

* Received for publication, July 9, 1955.

stained with hematoxylin and eosin, Mallory's fungus stain, the Gram stain, and Wolbach's Giemsa variant.[6]

Histopathologic Findings

Grossly, the disease has been characterized as a systemic infection with a pronounced affinity for the kidney.[2,4] Belding and Merrill[1] suggested that the complex disease picture was due, in fact, to impaired renal function.

Histologically, the disease was exemplary of the chronic granulomas. Productive fibrotic lesions were observed in every organ of infected fish. The proliferating fibroblasts characteristically formed distinct nodules, but often large masses of tissue occurred without tubercle-like structures. The granulomatous lesions apparently arose in the connective tissue stroma between the parenchymal cells of the various organs. Elements of the reticulo-endothelial system were frequently involved. Giant cells occurred, but only infrequently. As the lesions enlarged, they encroached upon and overwhelmed the parenchymal tissues (Fig. 1). In terminal cases, destruction of essential organs was tremendous. It was, in fact, remarkable that fish survived to the point of such extensive tissue damage.

The first organ to be affected by a natural infection of kidney disease was not determined with certainty, but it was quite likely that the hematopoietic tissue of the kidney was first involved. (In fish, the kidney is the major site of blood production.) In the earliest stage observed in this study, the hematopoietic tissue was always in an advanced stage of destruction. As the disease progressed, the posterior portions of the kidney were obliterated by the massive tissue reaction which apparently outstripped the vascular supply and terminated in necrosis and suppuration. In the anterior parts of the kidney, the granuloma usually progressed in a more orderly fashion, resulting in extensive fibrotic lesions which gradually enveloped the included renal tissue (Fig. 4).

Subsequently, or perhaps simultaneously, certain changes occurred in the digestive tract. From the esophagus through the small intestine, a marked eosinophilic inflammation occurred in the muscular wall. Eosinophils normally are present in the submucosal layers of the intestine. In moribund fish, their numbers were increased (Fig. 2). In the large intestine, the inflammation was granulomatous and involved the subcutaneous tissues in an extensive cellular reaction. The mucosal folds had a solid core of proliferating fibroblastic tissue (Fig. 3). There was also a characteristic cellular proliferation around

the blood vessels of the intestinal tract, which was probably related to their endothelial elements.

The later stages of the intestinal lesions were characterized by an extensive peritonitis in the region of the gastric ceca. At first acute, with many inflammatory cells, both lymphocytic and polymorphonuclear, the lesions spread throughout the visceral fat and pancreatic tissue. The inflammation continued to the chronic granulomatous stage (Fig. 5), although sometimes it was replaced by massive necrosis affecting the entire pancreatic system (Fig. 6).

Cytoplasmic inclusion bodies were seen commonly in the pancreatic acinar cells. These inclusions did not resemble any described in the mammalian literature nor were they similar to those of infectious pancreatic necrosis.[7] They were round or ovoid, were often of tremendous size, forcing the nucleus to one side of the cell, and were strongly eosinophilic (Fig. 7). The larger forms sometimes contained basophilic globules or were uniformly basophilic (Fig. 8). The eosinophilic portions were gram-negative; the basophilic portions, gram-positive.

In the liver, granulomatous nodules formed in the connective tissue stroma between the cords of hepatic cells. These increased in size, forcing the liver tissue aside (Fig. 9). Actual necrosis of the parenchymal cells appeared minor but the hepatic tissue was gradually replaced by the proliferating inflammatory tissue. Cytoplasmic inclusions also were present in the parenchymal cells. These inclusions were most numerous at the periphery of necrotic areas (Figs. 10 and 11). When necrosis was absent, they were found adjacent to the granulomatous lesions in reduced numbers. Such inclusions were usually gram-negative, occasionally contained gram-positive globules, and were observed rarely with a high concentration of gram-positive diplobacilli. The liver inclusions appeared morphologically identical with the inclusions of the pancreatic acinar cells.

The splenic tissue was gradually replaced by the proliferating tissue of the granuloma until its normal structure was altered beyond recognition (Fig. 12).

As the disease entered the terminal stages, no tissue or organ escaped partial destruction. The heart was often the seat of a massive myocarditis with destruction of the major portion of the muscle (Fig. 13). The gills were enveloped in an inflammatory reaction extending from the arches to the tips of the filaments. The cerebral meninges usually contained complete granulomatous nodules (Fig. 14). The brain itself occasionally had necrotic foci or rings of inflammatory cells surround-

ing minor blood vessels (Fig. 15). The gallbladder and air bladder were sites of distinct granulomatous nodules. The subcutaneous tissue behind the eyeball was similarly affected.

The muscle lesions were distinctive. In most cases, they did not penetrate the epithelium of the skin and thus were not visible externally. They consisted of great masses of chronic inflammatory tissue extending far into the underlying muscular tissue (Fig. 16). The muscle lesions were a consistent site for the multinucleate giant cells so characteristic of the granulomas. In muscle sections, necrotic muscle bundles surrounded by normal tissue were frequently observed.

The cellular location of the gram-positive diplobacilli was of considerable interest. Both eastern and western workers have described the organism as being both intracellular and extracellular.[2,4] In tissue sections, the bacilli were rarely found concentrated in the parenchymal cells of any organ. In the liver and pancreas, they were found occasionally in parenchymal cells in close association with cytoplasmic inclusion bodies. In contrast, the organisms usually were found in tremendous numbers, both intracellularly and extracellularly, in the granulomatous lesions. In these areas, it appeared that the intracellular forms might be the result of active phagocytosis by inflammatory cells (Fig. 17). Many cells of the kidney were filled with the organisms. The lymphoid character of this tissue was also suggestive that phagocytosis was responsible for the intracellular position. It is entirely possible, however, that a specific intracellular stage was present in the cells of the granulomatous tissue. The areas of eosinophilic inflammation of the intestine did not contain the organisms although the muscular wall and mucosal folds were frequent sites for extracellular forms.

With Wolbach's Giemsa variant, the diplobacilli were stained reddish purple. Usually, the inclusions in the liver and pancreas were stained uniformly blue by this method. However, when many such inclusions were studied, there appeared to be a range of forms varying from homogeneous blue to packed masses of the violet diplobacilli with all intermediate stages.

Comparison Between the Eastern and Western Types

Histologically, the general character of the disease appeared nearly identical whether it occurred in western salmon or eastern trout. Occasionally, individual specimens were seen in which the acute phases of the disease had swept into massive necrosis with resulting death before the typical chronic stages of the granuloma developed. The disease

in salmon appeared to be somewhat more acute than it was in trout. The diplobacilli appeared morphologically identical regardless of the species of fish infected. In some of the trout examined, the organism stained less intensely with Gram and Giemsa stains and appeared smaller than the western form. Also in some trout, extensive granulomatous lesions were present when diplobacilli were nearly completely absent. These observations tend to confirm the reports of Snieszko and Griffin[4] who observed lesions of kidney disease without the concurrent presence of the diplobacilli.

The primary differences between the eastern and western forms of the disease appeared in connection with a secondary lesion which was rather characteristic. The eastern disease was often associated with a mycosis-like granuloma.[4,8] This, in effect, appeared to result in a second superimposed granuloma of different origin. The mycotic granuloma was sharply differentiated from the primary lesions by the frequent occurrence of foreign body giant cells in association with yeast-like organisms. In the western form of kidney disease, giant cells were limited almost entirely to the muscle lesions and the mycotic organism was not observed.

In the coho salmon from the Sandy, Oregon, hatchery, there was a marked incidence of the salmon poisoning fluke *(Nanophyetus salmincola* Chapin). The metacercariae were encysted in practically all of the fish tissues with heaviest concentrations in the posterior kidney and heart. Histologically, there was no apparent correlation between the encysted organisms and the lesions of kidney disease. In some cases the metacercariae were in the centers of granulomatous lesions. At other times, however, they were observed in tissues which were unaffected by kidney disease. The salmon poisoning fluke was not observed in the fall chinook salmon from Underwood, Washington, and was, of course, absent from the eastern samples.

A round, spherical organism, tentatively identified as *Schizamoeba salmonis,* was present in the anterior digestive tracts of both eastern and western samples. At the Cortland station, fish fed synthetic diets apparently were not infected by this organism but were infected with kidney disease. It would, therefore, appear doubtful that a significant relationship exists.

Discussion

The granulomatous character of the lesions of kidney disease indicates an organism of low virulence or, conversely, indicates a high degree of resistance by infected fish. Eastern workers have experienced difficulty in transmitting the disease systematically except by

injection.[4] This may be due to the apparent balance in pathogenicity of the organism versus the resistance of the host. It appears that salmon may be somewhat less resistant than trout, which may explain why western workers have less trouble in transmitting the disease by feeding infective materials.

The complex and extensive morphologic changes are probably not a direct result of impaired renal function. The renal system is one of the later tissues to be affected by the disease. Instead, each organ is affected directly by the pathogenic organism with the resulting symptoms. The edema frequently seen in the disease is probably the result of a damaged circulatory system, as is especially evident in the mesenteric blood vessels.

At present, the classification of the diplobacillus found in kidney disease is still in doubt. The rickettsia responsible for salmon poisoning in dogs[9] has been suggested as the causative agent of kidney disease.[2,4] The inclusions observed strongly indicate that an intracellular stage is present in the life cycle of the diplobacillus. However, Earp *et al.*[2] maintained at least limited growth of the organism on media containing coagulated chicken eggs, indicating that the organism may be bacterial instead of rickettsial. More recently, on the basis of slides from dogs,* Snieszko[10] believed there is little, if any, likelihood that the salmon poisoning of dogs is related to kidney disease. In mammals, granulomas are rarely attributed to rickettsial agents. Such diseases as typhus, spotted fever, Q fever, and trench fever, all rickettsial in origin, have practically nothing in common histopathologically with the lesions of kidney disease. The Bartonella group, members of the order Rickettsiales, do in some cases produce a granuloma and have, in addition, a marked affinity for the reticuloendothelial system. The diplobacillus is gram-positive, while the Rickettsia are gram-negative. The reactions of the two organisms with Giemsa's stain, however, are very similar. The question is not resolved and awaits further bacteriologic studies. The occurrence of inclusion bodies, their apparent relationship to the diplobacilli, and the presence of granulomatous lesions without diplobacilli also indicate that the disease is more complex than a simple systemic bacterial infection.

The significance of the secondary lesions is obscure. Several workers have suggested the salmon poisoning fluke as a carrier for the causative agent,[2,4] and Snieszko and Griffin[4] have theorized that there may be a correlation between incidence of the disease and concentration of

* Kindly furnished to S. F. Snieszko by W. J. Hadlow, D.V.M., National Institutes of Health, Hamilton, Montana.

carrier-parasites in the hatchery water supply. Since the salmon poisoning fluke has a very limited northwestern distribution, it is apparent that either it is not involved as a carrier or that more than one carrier exists. Aside from the host-parasite relationship, there is an additional likelihood that these supplementary pathogens are directly related to the incidence of kidney disease. Difficulty in transmitting the disease by contact and by feeding of infectious material is indicative of a high degree of resistance. It appears possible that these secondary pathogens may serve the important purpose of breaching the outer defenses of the fish and allowing entry to the disease organism. The possibility of such infection would be increased if the causative organism was present in other aquatic hosts. Brockway[11] has found morphologically similar, gram-positive diplobacilli in many aquatic animals, including the scud, salamander, mayfly, caddis fly, frog, chironimid, blood worm, and dragon fly larva. Even after the organism has gained access to the animal body, it apparently meets a strong resistance which culminates in death only after an extended period. The debilitating effect of the mycotic granuloma and of a massive infestation of the salmon poisoning fluke augments suspicion against these organisms even though they may be proved non-carriers of the kidney disease organism itself.

Summary

Histologically, the eastern and western forms of kidney disease are nearly identical. In both salmon and trout, the disease is characterized as a systemic granuloma.

Cytoplasmic inclusion bodies are present in the liver parenchymal cells and pancreatic acinar cells. These inclusions may be a stage in the life cycle of the causative agent.

The Gram-positive diplobacilli, which stain intensely with Giemsa's stain, are concentrated primarily in the granulomas where they occur both intracellularly and extracellularly. They are rarely seen in parenchymal cells.

The occurrence of secondary parasites in fish infected with kidney disease suggests that these parasites may have a rôle in introducing the causative agent and/or in lowering the resistance of the fish.

REFERENCES

1. Belding, D. L., and Merrill, B. A preliminary report upon a hatchery disease of the Salmonidae. *Tr. Am. Fish. Soc.*, 1935, **65**, 76–84.
2. Earp, B. J.; Ellis, C. H., and Ordal, E. J. Kidney disease in young salmon. Washington State Department of Fisheries, 1953, Special Report Series 1, 74 pp.

3. Rucker, R. R. (Fish and Wildlife Service.) Personal communication, May, 1955.
4. Snieszko, S. F., and Griffin, P. J. Kidney disease in brook trout and its treatment. *Prog. Fish-Cult.*, 1955, **17**, 3–13.
5. Brockway, D. R. (New York State Conservation Department.) Personal communication, March, 1955.
6. Lillie, R. D. Histopathologic Technic. The Blakiston Co., Philadelphia, 1948, 300 pp.
7. Wood, E. M.; Snieszko, S. F., and Yasutake, W. T. Infectious pancreatic necrosis in brook trout. *A. M. A. Arch. Path.*, 1955, **60**, 26–28.
8. Wood, E. M.; Yasutake, W. T., and Lehman, W. L. A mycosis-like granuloma of fish. *J. Infect. Dis.*, 1955, **97**, 262–267.
9. Cordy, D. R., and Gorham, J. R. The pathology and etiology of salmon disease in the dog and the fox. *Am. J. Path.*, 1950, **26**, 617–637.
10. Snieszko, S. F. Personal communication, February, 1955.
11. Brockway, D. R. Unpublished data.

LEGENDS FOR FIGURES

FIG. 1. Normal renal tubules surrounded by granulomatous tissue. Brook trout. Hematoxylin and eosin stain. × 200.

FIG. 2. Eosinophilic inflammation of the intestinal wall. Epithelium at top. Coho salmon. Hematoxylin and eosin stain. × 100.

FIG. 3. Granulomatous inflammation of large intestine. Brook trout. Hematoxylin and eosin stain. × 100.

FIG. 4. Necrosis and granuloma gradually engulfing the renal tubules. Coho salmon. Hematoxylin and eosin stain. × 100.

FIG. 5. Granulomatous tissue infiltrating the pancreas. Intestinal wall at lower left. Brook trout. Hematoxylin and eosin stain. × 100.

FIG. 6. Massive necrosis obliterating the pancreatic tissue. Gastric ceca at upper left. Chinook salmon. Hematoxylin and eosin stain. × 100.

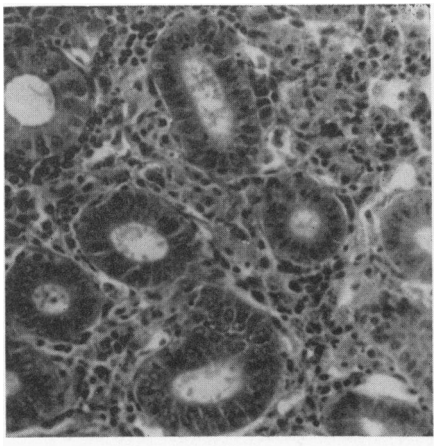

1

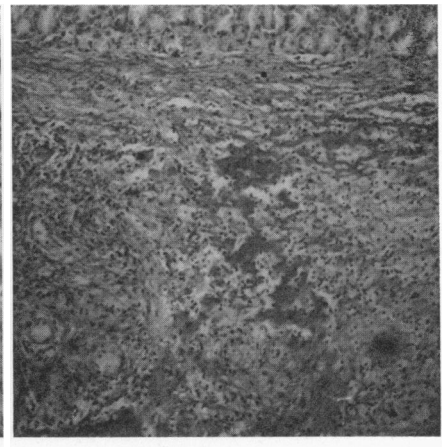

2

3

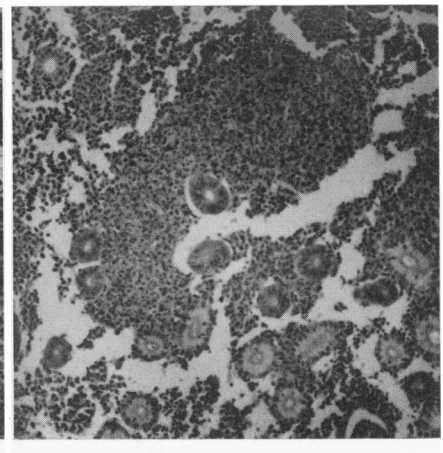

4

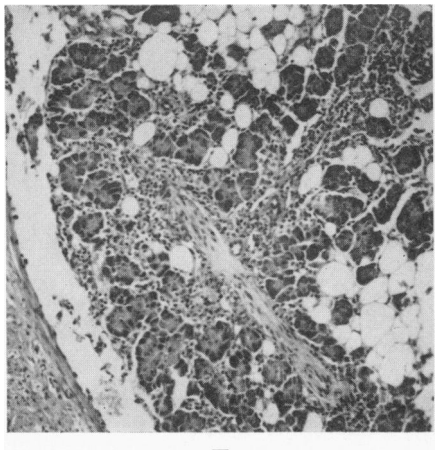

5

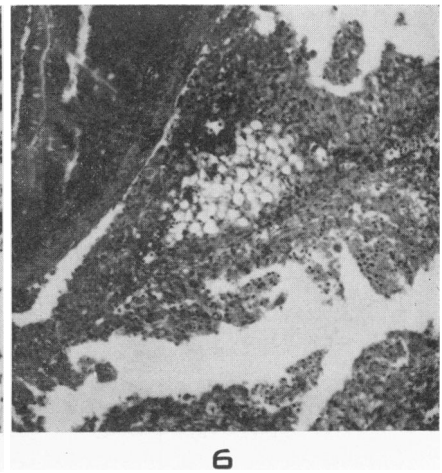

6

FIG. 7. An eosinophilic inclusion is present in the lower part of the pancreatic acinar cell in the center. Coho salmon. Hematoxylin and eosin stain. × 1350.

FIG. 8. From left to right, a lobed basophilic inclusion, an eosinophilic inclusion with basophilic granules, and an eosinophilic inclusion, all in pancreatic acinar cells. Coho salmon. Hematoxylin and eosin stain. × 1350.

FIG. 9. A granulomatous nodule, center, displacing the liver tissue. Brook trout. Hematoxylin and eosin stain. × 200.

FIGS. 10 and 11. Basophilic and eosinophilic inclusions in liver cells. Coho salmon. Hematoxylin and eosin stain. × 1350.

FIG. 12. The granulomatous proliferation has completely replaced the splenic tissue, making it impossible to discern the borderline between spleen and visceral fat. Brook trout. Hematoxylin and eosin stain. × 100.

7

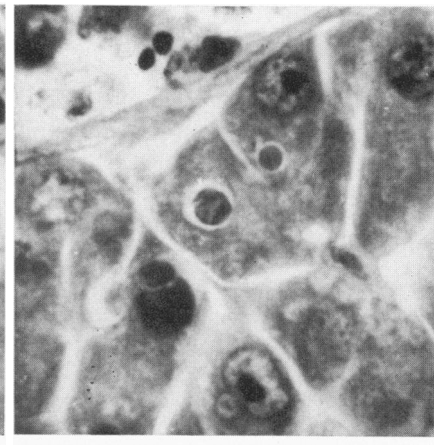

8

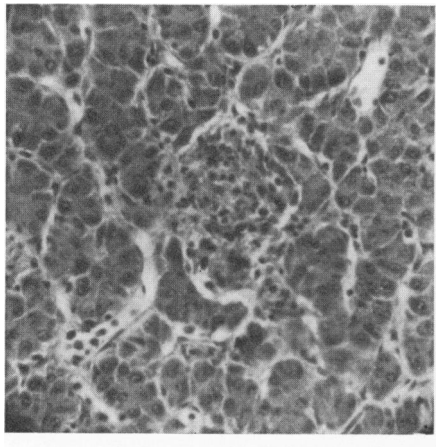

9

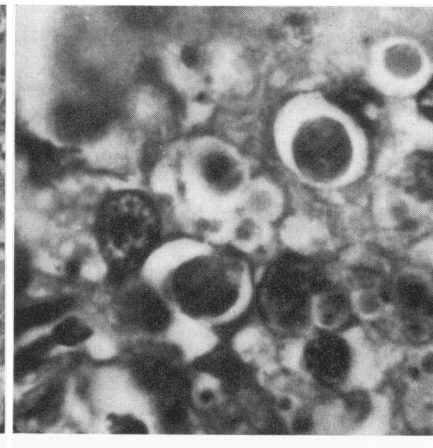

10

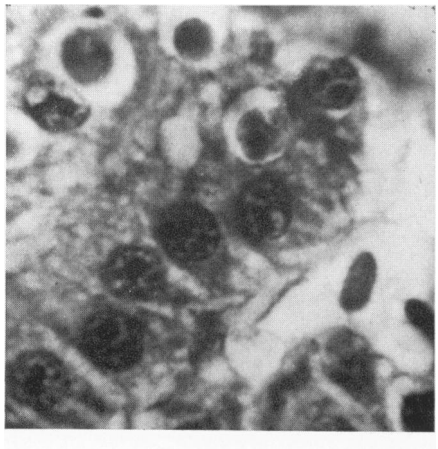

11

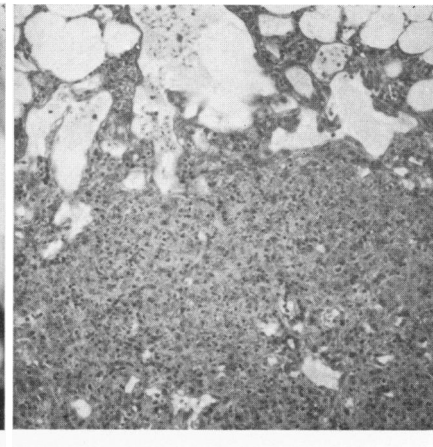

12

FIG. 13. Granulomatous inflammation of the ventricle. Brook trout. Hematoxylin and eosin stain. × 100.

FIG. 14. Nodules of granulomatous tissue between the meninges and the brain proper. Chinook salmon. Hematoxylin and eosin stain. × 100.

FIG. 15. An inflammatory nodule and necrosis within the brain. Brook trout. Hematoxylin and eosin stain. × 100.

FIG. 16. The muscle lesion. Epithelium at top. Muscle myomeres are at right and left with the granulomatous lesion extending between them. Brook trout. Hematoxylin and eosin stain. × 60.

FIG. 17. Inflammatory cells filled with the diplobacilli, top center. Normal pancreatic acinar cells below. Coho salmon. Mallory's fungi stain. × 1350.

FIG. 18. Gram-positive diplobacilli. Brook trout. Gram stain. × 6000.

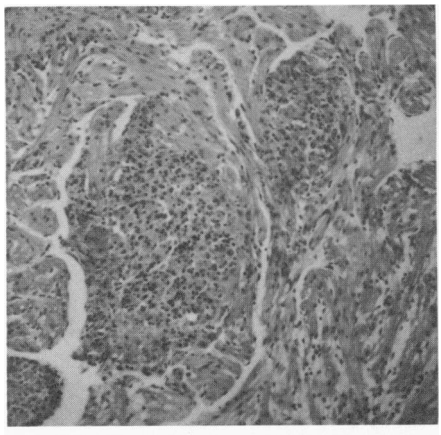

13

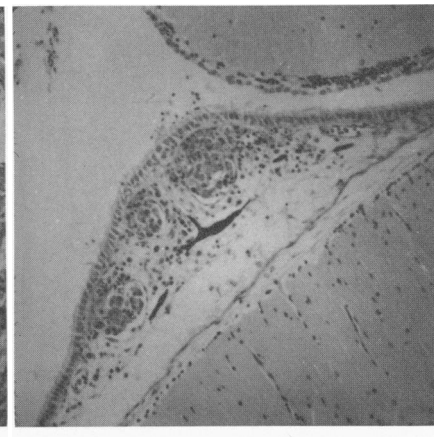

14

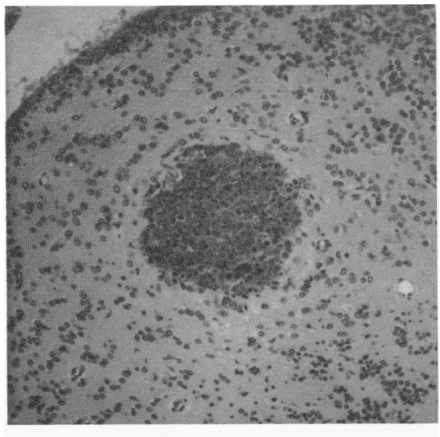

15

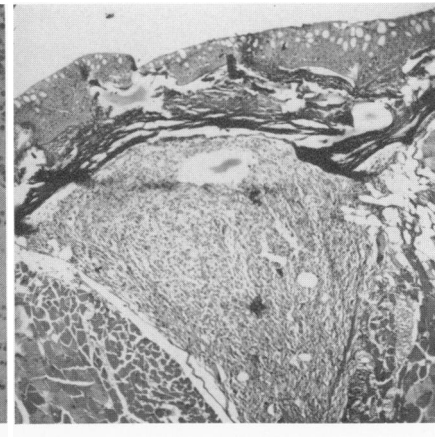

16

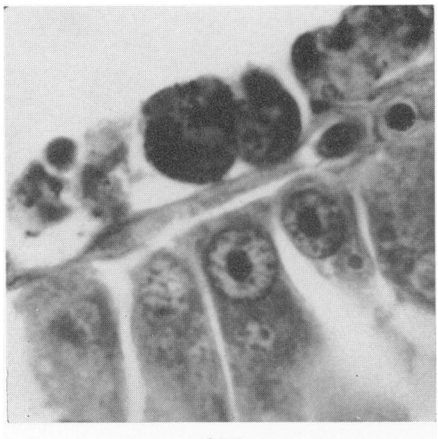

17

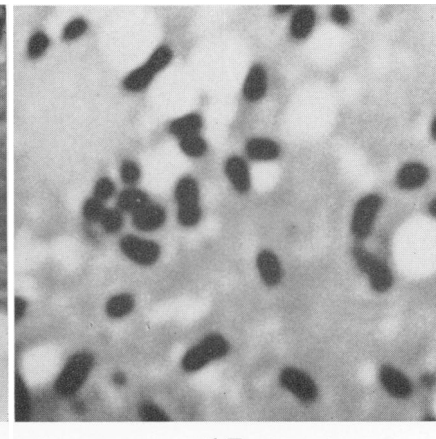

18