STUDIES ON PNEUMONIA FOLLOWING NASO-PHARYNGEAL INJECTIONS OF OIL *

G. F. LAUGHLEN, M.D.

In the routine study of autopsy material at the Toronto, Ontario, Hospital for Sick Children, an unusual microscopic picture was observed in sections of the lung from a pneumonia case. Two days later a similar observation was made in a second case.

Brief abstracts from the histories of these cases are as follows:

Case I. This child, aged 2½ years, had an illness lasting about seven weeks. She first developed diphtheria, from which she recovered after four weeks illness, and about one week or ten days later she developed scarlet fever which was complicated by Vincent's angina. She eventually developed septicaemia and died.

She was only four hours in the Hospital for Sick Children, during which time she received sod-diarsenal intravenously, 15 minims of camphor in oil hypodermically and a transfusion of blood. Menthol in alboline † had been used as treatment of her nose and throat infection previous to her admission to the hospital. Argyrol drops had also been used in the same way but a record of the amount given could not be obtained.

At autopsy grayish red nodules of broncho-pneumonia were found in all lobes of the lung excepting the left upper lobe. There was nothing unusual in the distribution or gross appearance of the broncho-pneumonic process.

In sections of the consolidated portions of the lung, the alveoli were seen to contain three types of exudate: one in which polymorphonuclear leucocytes predominated, another consisting almost exclusively of large vacuolated mononuclear cells, and a third type in which both of these cells were intermixed.

Attention is particularly called to the mononuclear cells which made up this peculiar type of exudate and which contained unstained droplets of various sizes. Some cells contained so many droplets that they were distorted in shape and considerably swollen. A few contained no droplets but the majority contained amounts intermediate between these two extremes.

By the use of Sudan III these globules were demonstrated to be oil. These "oil containing" cells did not appear to be undergoing degeneration but were healthy, as shown by the good nuclear stain-

*Read before the Section of Pathology, Academy of Medicine, Toronto, Ont., Nov. 25, 1924. Received for publication April 3, 1925.

† Menthol — grs. I. — Alboline oz. I.

ing even of those cells which were loaded with droplets. In those which contained much oil the nuclei were often pushed to one side, flattened, or somewhat masked. In others which contained very little the nuclei were round or oval and centrally located.

The appearance and phagocytic nature of these cells characterize them as endothelial leucocytes.

Case II. This infant had an illness lasting seven weeks which commenced with a cough and naso-pharyngitis, and which was followed in one week's time by double suppurative otitis media. In the course of her illness conjunctivitis and convulsions also developed. There was a profuse nasal discharge.

Local treatment consisted of instillations of argyrol drops in the eyes and three drops of menthol and alboline in each nostril every four hours. The menthol and alboline treatment was used for thirty-six days and until three days preceding her death.

On post-mortem examination there was well marked broncho–pneumonia of the right upper lobe and both lower lobes of the lung. As in the preceding case no unusual features were seen on gross examination of the lung, but on microscopic examination, in addition to an exudate of the usual septic type, extensive areas were found in which the pneumonic exudate consisted almost exclusively of large phagocytic endothelial cells (Fig. 1). These were loaded with droplets which were demonstrated to be oil by the use of Scharlach R. stain.

Case III. This child, three years of age, was a diabetic and in the course of her treatment she received two drachms of paraffin oil as a laxative. She was in a somewhat stuporous condition when this was administered and two days later she died in coma.

Post-mortem examination of the lungs showed broncho-pneumonia of both the lower lobes.

In the sections of the lungs oil containing endothelial cells were observed in great numbers in many of the alveoli. An ordinary septic pneumonia was also present.

On reviewing the autopsies of the previous year, about three hundred in all, another case was found in which oil had been administered through the nose and which showed the typical oil phagocytes in the lungs.

A condition similar to that in the four preceding cases was found in an adult at the Toronto General Hospital.

A man aged thirty-seven years had an illness of two years' duration which consisted of multiple paralyses of the face, arms, legs, soft palate, vocal cords and accessory muscles of the larynx. He also had dysphagia, but could swallow if food were placed well back in his mouth.

He received 1.5 oz. of liquid paraffin three times a day over a period of four and one-half months. It was administered by mouth as a laxative.

Twelve days after this treatment was discontinued he had an elevation of temperature and two weeks later showed cyanosis and physical signs of broncho-pneumonia. Eleven days later he died.

At autopsy there were areas of consolidation in all the lobes of both lungs, and the cut surfaces exuded an oily liquid.

Microscopically in addition to a septic pneumonia great numbers of the alveoli were filled with endothelial cells containing oil and in places large droplets of free oil were also observed. This stained fairly well with Scharlach R. stain.

It has been customary in many children's hospitals and among pediatricians in private practice to treat nose and throat infections by the use of drops of menthol and alboline or by the use of argyrol drops. In this paper only the five cases which gave histories of "oil treatment" are referred to in the discussion which follows.

From a study of these cases it was apparent that the endothelial cell reactions in the lungs were due to oil but it still remained to explain the source of the oil and the route by which it reached the lung alveoli and also to prove that oil would produce such reaction in the lungs of animals.

The first experiments with animals were undertaken to prove if possible that the administration of oil led to reactions in the lungs of animals similar to those seen in the clinical cases.

Menthol and alboline was administered in several ways in order to study the route by which it found its way into the lungs.

It was also necessary for comparative purposes to repeat the same experiments using a 15 per cent watery solution of argyrol instead of the menthol and alboline.

For Experiments 1, 2, and 3, three healthy rabbits were selected.

Experiment 1. One-half c.c. of menthol and alboline was injected by means of a syringe and small catheter which was passed into the trachea a distance of about 5 cm. through a tracheotomy wound in the neck. Two days later 0.5 c.c. of menthol and alboline was again injected in the same way and twelve hours after this injection the animal died.

A post-mortem examination showed the cause of death to be broncho-pneumonia. Streptococcus hemolyticus and staphylococcus aureus were recovered from the lungs. The lung alveoli and bronchioles contained an exudate of red blood corpuscles, polymorphonuclear leucocytes and mononuclear cells. In some of the alveoli, vacuolated endothelial leucocytes were present. These were shown to contain oil by the use of Scharlach R. stain. Though few in number they were of the same type as those observed in the clinical cases.

Experiment 2. One-half c.c. of menthol and alboline was administered intratracheally by means of a sterile syringe and needle every second day for one month. Altogether fifteen injections were given. The animal was then killed and examined.

The lower lobes of the lung appeared deeply congested. They were air-containing and crepitant throughout and floated readily in water. On microscopic examination, many of the alveoli, especially throughout the lower lobes, were seen to contain large phagocytic endothelial cells. The droplets within these cells gave the reaction for fat. There were no polymorphonuclear leucocytes present in the exudate. The cells within the alveoli were of the same type and character as those seen in the clinical cases (Fig. 2). The lesion appeared to be produced purely by the presence of oil and was not obscured by reaction to secondary infection.

The rabbit of Experiment 3 received 1 c.c. of menthol and alboline every second day for one month and 1 c.c. daily thereafter until it died. This was injected into the pharynx by the use of a syringe and small catheter. The catheter was inserted into the mouth a distance of about two to three inches to insure the oil being retained. No attempt was made to insert the catheter into the larynx and the opening of the catheter was at the side which rendered it unlikely that any oil would be suddenly thrown into the larynx; moreover the animal was not manipulated in any way and the oil was given with the animal on its back but it was allowed to turn over after each injection.

This rabbit died (on the day I had planned to kill it) two months and six days after the experiment was commenced. The post-mortem examination showed that death was due to broncho-pneumonia. Both lower lobes of the lung were consolidated and mottled in appearance. The greater part of these lobes was dark red in color, but here and there somewhat lighter grayish-red areas were seen. At the margins of the lower lobes and in the upper lobes, bright red areas could be seen which contrasted sharply with the darker red color of other areas. This bright color did not fade on fixing in formalin but became much more distinct, as the color of the surrounding lung tissue faded. This color was due to Scharlach R. which had been added to the last eight or ten doses of the menthol and alboline which were administered to the rabbit. The quantity of Scharlach R. was just sufficient to give a bright red color to

the oil. This served to identify on gross examination the presence of the stained oil, widely distributed throughout the lung.

These features can be made out in the gross specimen. The red color is still bright although the lungs have been kept in formalin since April 21, 1924.

On microscopic examination, a widespread broncho-pneumonia was seen throughout all lobes of the lung. The reaction was of a mixed type but the bulk of the exudate consisted of endothelial cells containing oil droplets (Fig. 3). In many places no other cells were present but areas could be found in which the exudate consisted largely of polymorphonuclear leucocytes.

Two other experiments were carried out before the termination of Experiment 3. It was the purpose in these experiments to set up a throat infection which would reproduce more closely the conditions present in the clinical cases before oil was administered.

Two healthy adult rabbits were selected and their throats swabbed with 50 per cent carbolic acid. The following day both rabbits showed a severe local reaction and were breathing with difficulty.

One rabbit was then given 0.5 c.c. of menthol in alboline dropped into the pharynx and the same amount again on the following day. This rabbit died on the third day and on examination showed a well-marked broncho-pneumonia of the septic type and numbers of oil-containing endothelial cells within some of the alveoli.

The other rabbit was kept as a control and received no treatment. This rabbit recovered.

No definite conclusions have been drawn from these two experiments because the rabbit that died had a slightly more severe reaction from the phenol than had the control rabbit. The experiments are included to show that the oil had found its way into the lung alveoli although only two 0.5 c.c. doses were given.

Experiments were undertaken using argyrol 15 per cent instead of menthol and alboline. This was considered necessary because argyrol as well as menthol and alboline had been administered in one of the clinical cases which has been described, and because argyrol has been extensively used in the treatment of nose and throat infections.

Two healthy adult rabbits were used in these experiments:

One rabbit received daily intratracheal injections of 0.5 c.c. of argyrol which was introduced through a sterile syringe and needle.

This rabbit died from broncho-pneumonia on the third day but no noticeable endothelial cell reaction was found in the lungs.

The other rabbit received 0.5 c.c. of argyrol daily, introduced into the pharynx by a syringe and catheter in the same way as the menthol and alboline of Experiment 3. This rabbit died in two months and twenty-five days. It was much emaciated and the kidneys showed a very advanced nephrosis. There were also degenerative changes in the liver, but no endothelial cells were found within the lung alveoli.

Discussion

The phagocytic cells which have been especially noted in this paper have been referred to as endothelial cells. They are apparently the only ones concerned in the disposal of oil droplets. From a study of the literature it seems clear that they are identical with cells phagocytic for coal dust and other solid particles: the so-called "dust cells." They are also the same as the endothelial cells of pneumonic exudates, the epithelioid cells of tubercles and the heart-failure cells of passive congestion of the lung.

It is also clear that besides possessing marked phagocytic power, they all possess considerable power of ameboid movement. Their origin has long been in dispute. In the present state of our knowledge there is no reason to believe that they arise from the lining cells of the alveolar walls.

Permar [1] has shown that they arise largely from blood vessels of the alveolar walls and perhaps from vessels of more distant parts such as the liver and spleen. He found that under the stimulus of foreign bodies in the alveoli the endothelial cells of vessels proliferated, developed power of ameboid movement, entered the alveoli and became actively phagocytic.

The reaction in the lungs of animals following oil administration has been shown to be identical with that seen in children.

In three of the children the only way the oil had been given was by nasal drops which were allowed to run back into the nasopharynx while the children were in bed and on their backs.

The quantity of oil in two of these cases was considerable: 6 drops every four hours or about 2 c.c. a day for a considerable period of time. In another case only a single dose of 2 drachms was given by mouth.

In the five clinical cases and two of the animal experiments, oil found its way into the terminal air passages though it was only injected into the nose, mouth or pharynx.

In the experiments where oil was administered by mouth as well as in the clinical cases the reactions to oil were complicated by septic pneumonia, but in Experiment 2 in which oil was injected by needle into the trachea a purely endothelial cells reaction with no complicating sepsis was set up.

In one rabbit a granulomatous tumor developed at the side of the mouth where the surface was saturated with oil from the injections.

These observations suggest that oil, by lowering the resistance of the tissue or by carrying infection from the nose and throat, may be a factor in the production of pneumonia.

The oil used for mouth injection and intratracheal injection was the same. It was not sterilized so that accidental infection from outside may have occurred; but in that case the rabbit of Experiment 2, that received oil by intratracheal injection and in which more oil must have entered the lungs, should have developed a septic pneumonia more readily than the others. This points to the infection being autogenous in spite of the contention that the organisms ordinarily present in the throats of man and animals are incapable of producing infection in the host.

In Experiment 3, in which unstained oil was administered for nearly two months and oil stained with Scharlach R. was given throughout the last week or ten days, there was considerable unstained oil within the lungs, showing that oil had been reaching the lungs in the earlier part of the experiment. This oil could have carried infection equally as well as the oil given in the last ten days. Apparently the animal did not develop septic pneumonia until a large number of its lung alveoli were filled with endothelial cells and oil.

The reactions in these cases were produced by mineral oils but similar reactions have been observed in the lungs of animals following intratracheal injections of olive oil.[2,3]

The movements and final disposal of the oil phagocytes are subjects for further study.

This paper has called attention to a type of pneumonia which has not been previously reported as occurring in children.

Conclusions

These observations and experiments have established three facts:

1. That oil finds its way into the alveoli of the lung, not only when directly introduced into the trachea but also at times when administered in sufficient quantity in the nose and throat.

2. Oil when present in the lung is actively phagocyted by endothelial cells which are present in sufficient numbers to dispose of all the oil present and produce consolidation of the lung.

3. Argyrol, when given by mouth or introduced into the trachea, does not lead to any reaction on the part of the endothelial phagocytes in the lung.

The writer desires to express his thanks to Dr. Rittinger who assisted in carrying out the animal experiments; also to Professor Klotz, Dr. Magner and Dr. W. L. Robinson for helpful suggestions.

REFERENCES

1. Permar. Jour. Med. Res., 1920, xlii, 9, 147.
2. Gilbert, A., and Jomier, J. Compt. rend. Soc. Biol., 1905, lix, 87.
3. Gravel, F. Compt. rend. Soc. Biol., 1919, lxxxii, 1329.

DESCRIPTION OF PLATE LXV

Fig. 1. This is a high power photograph showing oil phagocytes filling the alveoli. The outlines of many of the cells are indistinct but one large cell in the center of the field is clearly outlined and shows a rounded nucleus and a single nucleolus. This one contains two large droplets of oil. A few polymorphonuclear leucocytes are recognizable in the alveolar walls.

Fig. 2. Shows a number of oil phagocytes in the alveoli. They are not mixed with other cells and there is very little reaction in the alveolar walls.

Fig. 3. Shows many large typical oil phagocytes intermingled with red blood cells.

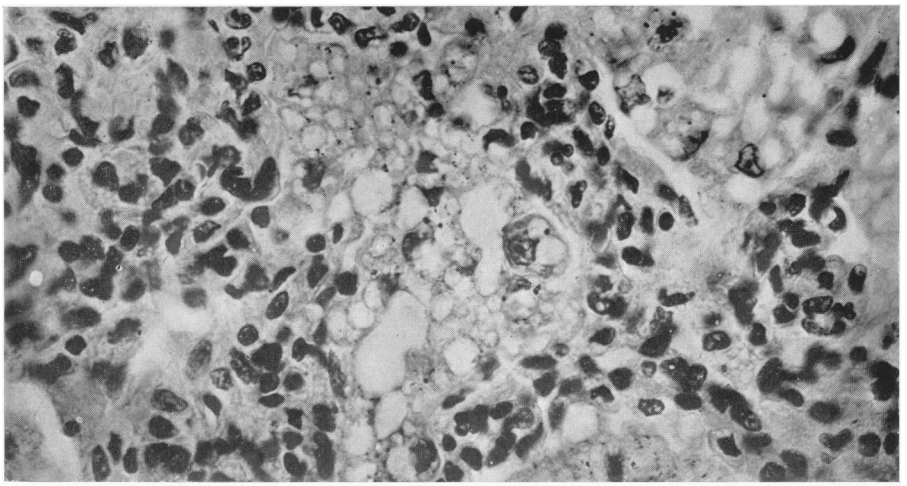

1

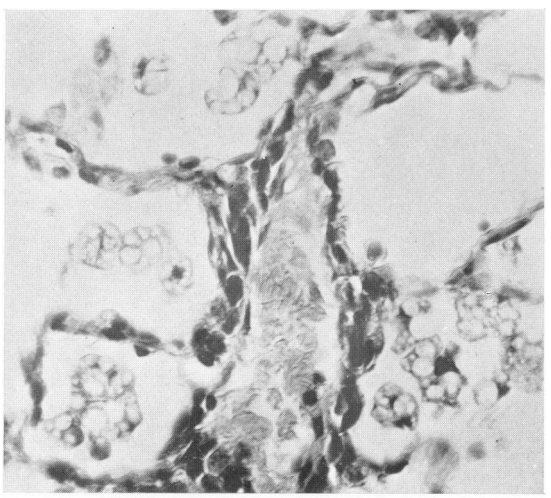

2

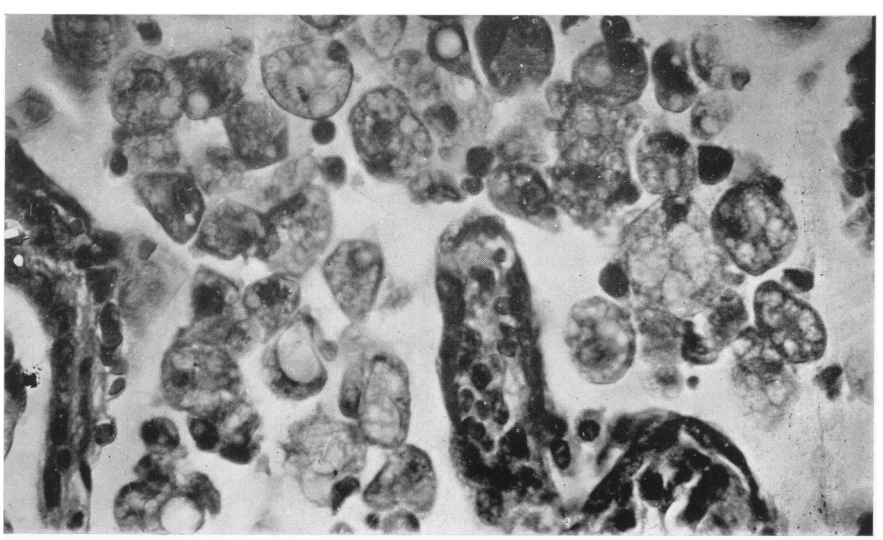

3

Laughlen

Pneumonia following injection of oil