American Journal of Pathology, Vol. 141, No. 5, November 1992
Copyright © American Association of Pathologists

Sequential Changes in Histologic Pattern and Extracellular Matrix Deposition During the Healing of Chronic Venous Ulcers

S. E. Herrick,* P. Sloan,† M. McGurk,† L. Freak,‡ C. N. McCollum,‡ and M. W. J. Ferguson*

From the Departments of Cell and Structural Biology and Oral Medicine and Surgery,† University of Manchester, Manchester, and the Department of Surgery,‡ Withington Hospital, Manchester, United Kingdom*

As part of a major clinical trial, sequential biopsies were taken from the margins of venous leg ulcers during their healing. The changing patterns of tissue architecture and extracellular matrix synthesis during healing were documented histologically and immunocytochemically. Initial biopsies were similar in appearance: prominent fibrin cuffs, variable inflammation, hemosiderin, and red blood cell extravasation. So called "fibrin cuffs" were highly organized structures composed of laminin, fibronectin, tenascin, and collagen as well as trapped leukocytes and fibrin. Fibronectin was absent from the ulcer tissue although collagen was abundant. Major histologic changes were observed after 2 weeks' pressure bandage therapy; hemosiderin, acute inflammation, and granulation tissue with the deposition of fibronectin had all increased and epithelial migration had commenced. Complete epithelialization was frequent by the fourth week of treatment, but the basement membrane was incomplete. At this time, hemosiderin and red blood cell extravasation had decreased and "fibrin cuffs" were virtually absent although chronic inflammation remained. The complex organization of the so-called "fibrin cuffs" may inhibit angiogenesis (but offer protection against increased venous pressure) in addition to their previously ascribed role in causing tissue ischemia. (Am J Pathol 1992, 141: 1085–1095)

Ulceration of the lower leg affects about 1% of the population, causing considerable morbidity.[1] Several authors have investigated aspects of the etiology and pathophysiology of chronic venous ulceration that remain controversial.[2–4] There have been several reports relating to the clinical treatment of venous ulcer patients[5–8]; however, there are few published studies documenting the histopathologic and immunocytochemical features of chronic venous ulcers. This is surprising, because such investigations may reveal new clues concerning the pathogenesis of chronic venous ulcers and suggest novel treatment regimens. The normal progression of healing involving inflammation, granulation tissue formation and remodeling are disrupted in chronic wounds such as venous ulcers and follow a more complex seesaw healing pattern.

As part of a major clinical trial of biosynthetic growth-hormone–assisted wound healing, sequential biopsies were taken from the margins of chronic venous ulcers at the commencement of, and during, treatment. The aim of the current study is to document the initial appearance and subsequent changes in patterns of architecture and extracellular matrix synthesis during healing in the combined placebo- and growth-hormone–treated groups.

Materials and Methods

Biopsies were taken under local anesthesia from the margins of chronic venous ulcers in patients attending the University of Manchester Department of Surgery, University Hospital of South Manchester, Withington, UK, with informed consent, as part of a trial of biosynthetic growth-hormone (B-hGH, Norditropin®) assisted wound healing. Ethical approval for the study was given by the Ethics Committee of the South Manchester Health Authority. Patients ranged in age from 56 to 89 years. A rectangle of tissue approximately 12 mm long and 3 mm wide was excised to include the surrounding intact skin, the ulcer edge, and ulcer base. Biopsies were taken at different

Supported by a grant from Novo Nordisk and Coloplast, Copenhagen, Denmark.

Accepted for publication April 21, 1992.

Address reprint requests to Prof. M. W. J. Ferguson, Department of Cell and Structural Biology, Stopford Building, University of Manchester, Oxford Road, Manchester M139PT, United Kingdom.

sites (position of initial biopsy randomized between patients to exclude anteroposterior and mediolateral gradients) immediately before any treatment, after 2 weeks of standard multilayer compression bandage therapy, after a further 2 weeks with growth hormone (11.2 IU/ml, 1.0 IU/ml, 0.17 IU/ml) or placebo treatment in addition to pressure bandage therapy and at 50% reduction or more in original area. This paper describes key features of 64 biopsy specimens taken from a total of 24 patients. Each biopsy was immediately divided longitudinally and one-half fixed in cold 4% paraformaldehyde in phosphate-buffered saline (PBS) and the other snap-frozen in OCT over liquid nitrogen for immunocytochemistry. After 24 hours, fixed tissues were embedded in paraffin wax and sectioned at 4 μ. Hematoxylin and eosin (H&E), Martius Scarlet Blue (MSB), Elastic van Gieson and Perls Prussian blue methods[9] were used to stain alternate sections. A three-layer immunoperoxidase method[10] was used in conjunction with trypsin pretreatment to demonstrate α_1-smooth muscle actin (primary antibody from Sigma Immunochemicals, Dorset, UK), factor VIII–related antigen and macrophages (primary antibodies from Dako Ltd, High Wycombe, UK). For immunofluorescence, frozen blocks were sectioned at 7 μ on a Leitz cryostat, followed by acetone fixation and storage at −20°C. Cryostat sections were incubated for 1 hour with previously well-characterized primary antisera[11] raised against extracellular matrix molecules (Table 1). After three rinses in PBS, the sections were incubated with fluorescein isothiocyanate-labeled secondary antisera for 1 hour, rinsed three times in PBS, and mounted in a nonfading medium containing DABCO (1,4-diazobicyclo-[2,2,2]-octane) to prevent fading.[12] Control specimens were stained by substituting the primary antibody for either PBS or primary antibody preabsorbed by incubation with the appropriate antigen, followed by the above protocol. Sections were viewed with a Leitz orthoplan microscope equipped with ultraviolet epifluorescence and photographed using Ektachrome 160 ASA film, from which black and white prints and montages were made.

Table 1. *Primary Antibodies*

Primary Ab raised against	Primary Ab raised in	Source	Dilution (PBS)
Laminin	Rabbit	Institut Pasteur de Lyon	1:100
Fibronectin	Rabbit	Institut Pasteur de Lyon	1:100
Type I collagen	Rabbit	Institut Pasteur de Lyon	1:25
Type III collagen	Rabbit	Institut Pasteur de Lyon	1:100
Tenascin	Rabbit	Dr R. Chiquet-Ehrisman, Basel	1:100

Results

Initial Biopsy

All the biopsy sites healed within 1 to 3 weeks. On histological examination, three zones could be identified within each biopsy: the ulcer base, the ulcer margin, and the surrounding skin (Figure 1A). As the ulcer decreased in area, the ulcer margin and the ulcer base at the first time point became the surrounding tissue and ulcer margin, respectively, at the next time point. The surrounding skin appeared normal in most specimens, although there was an increased fibrosis (changes consistent with lipodermatosclerosis). The ulcer margin was covered by epidermis that abutted above, within, or under the fibrinous exudate. The underlying dermis contained numerous small and medium-sized blood vessels surrounded by thick organized fibrin cuffs (Figure 2A). Many of these possessed a concentric layered structure containing collagen as well as fibrin, conspicuous in MSB-stained preparations (Figure 2B). A high proportion of the fibrin cuffs contained migrating polymorphonuclear leukocytes. The remainder of the dermis consisted of fibrous tissue in which inflammatory cells were scattered. The ulcer base was covered with a layer of fibrinous exudate of variable thickness, which always contained numerous polymorphonuclear leukocytes. In a few specimens, bacteria and

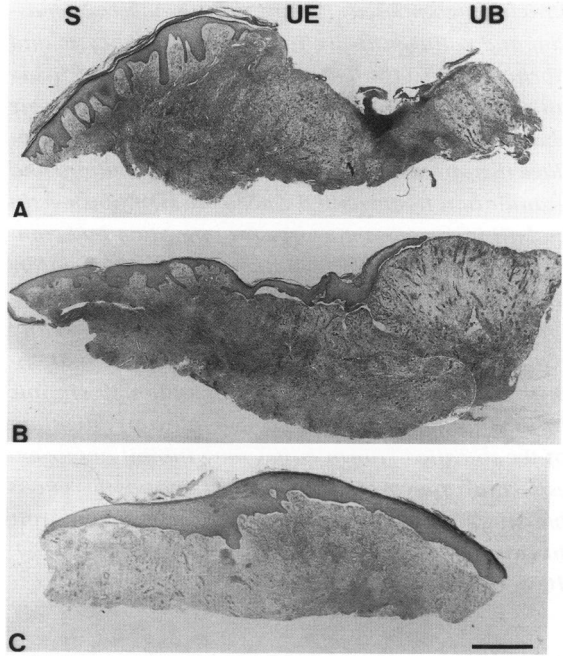

Figure 1. *Sequential histologic sections including surrounding skin (S), ulcer edge (UE), and ulcer base (UB) stained with MSB. Initial biopsy* **(A)**, *after 2 weeks of pressure bandage therapy* **(B)**, *and final biopsy when the ulcer was 50% original area* **(C)**. *Bar: 1mm.*

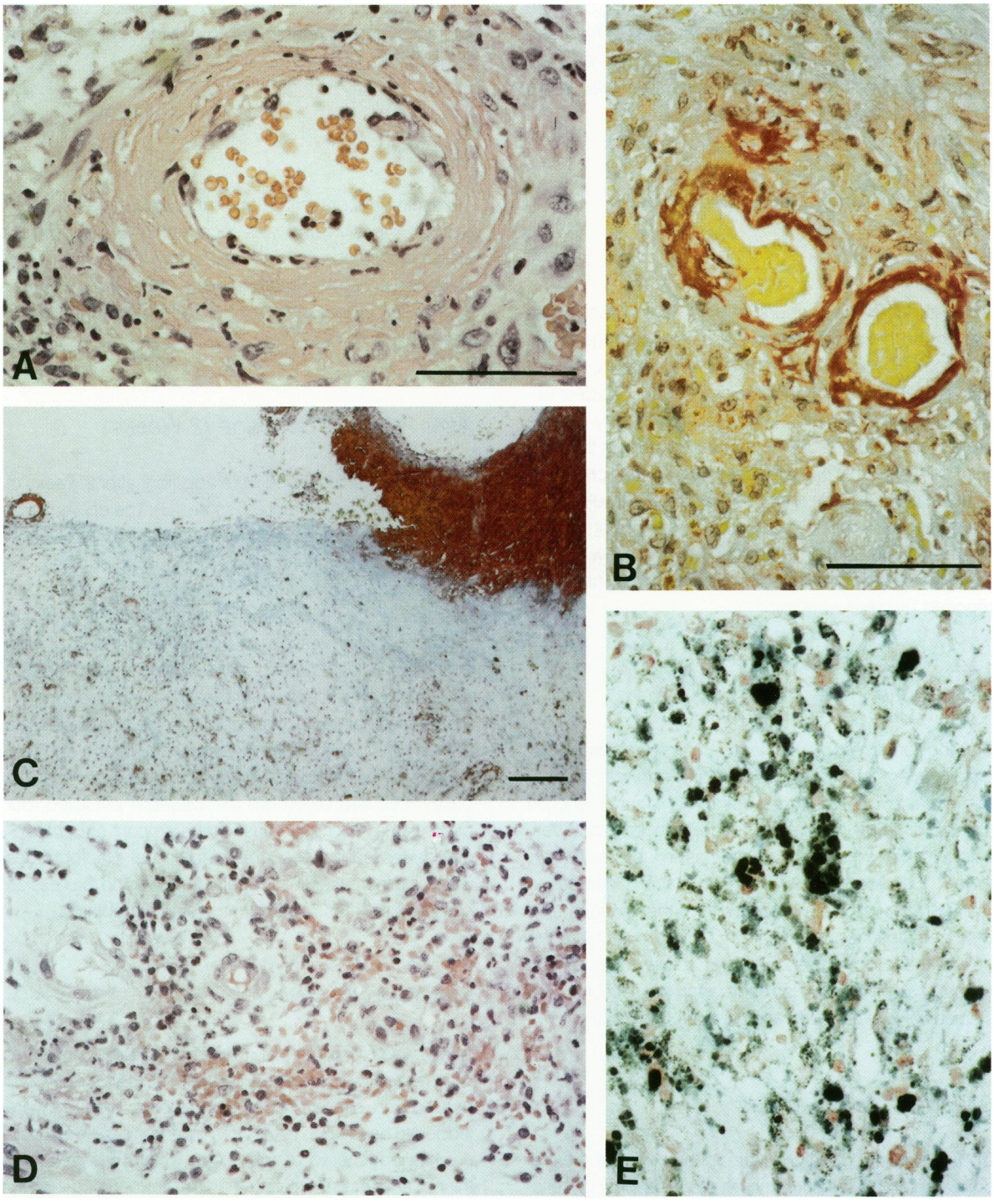

Figure 2. *Histologic features of initial biopsy. Fibrin cuff* (A), *collagen (blue) and fibrin (red) staining of fibrin cuffs* (B), *hyaline collagen (blue) under a fibrinous exudate (red) at the ulcer base* (C), *focally extravasated red blood cells* (D) *and deposits of haemosiderin* (E). (A) *and* (D) *stained with H & E,* (B) *and* (C) *stained with MSB and* (E) *stained with Perls Persian blue. Bar* A: *50 μm and Bar* B–E: *100 μm.*

necrotic debris were present on the surface. A layer of hyaline and apparently acellular collagen approximately 50 μ in thickness was often observed sandwiched between the exudate and ulcer base, together with a mild chronic inflammatory infiltrate (Figure 2C). Sparse granulation tissue or fibrous tissue, containing cuffed vessels, was present deep to the hyaline layer. Focally extravasated red blood cells (Figure 2D), small perivascular deposits of hemosiderin (Figure 2E), and macrophages were present in all zones: ulcer base, edge, and sur-

rounding tissues. Expression of α_1 smooth muscle actin was restricted to vessel coats and was absent from dermal fibroblasts. Factor VIII–related antigen was expressed by endothelial cells and was observed within fibrin cuffs in the ulcer margin and base.

Extracellular Matrix Distribution

Laminin

At all stages in the surrounding skin, laminin was localized in the epidermal basement membrane and in the endothelial basement membranes (Figures 3A, 4A). At the ulcer margin, laminin staining at the epidermal–dermal junction became punctate and expression was enhanced in the adjacent extracellular matrix of the papillary dermis. Within the ulcer base, laminin was present in endothelial basement membranes, some vessels being extensively surrounded by concentric rings of laminin (Figure 5B). This pattern mimicked the one that was seen when the sections were stained for fibrin, which has been reported by other workers.[13–15]

Fibronectin

Staining for fibronectin showed a diffuse pattern in the extracellular matrix of the surrounding skin with a punctate staining pattern at the epidermal–dermal junction (Figure 3B). Staining was enhanced around blood vessels, especially in the papillary dermis. In the ulcer margin toward the ulcer base, fibronectin staining decreased markedly, being virtually absent from the fibrinous exudate and ulcer tissue apart from a broad cuff of staining around the blood vessels (Figure 5C). This cuffed pattern of vessel staining was also seen when the sections were stained with an antibody against fibrin (Figure 5A).

Collagen Types I and III

Collagen staining was widespread throughout the extracellular matrix of the surrounding tissue, appearing reticular in the papillary dermis and fibrillar in the deep dermis (Figure 3C). Within the ulcer base, bundles of collagen III were clearly visible, lying parallel to the surface, producing a striking divide between fibrinous exudate and granulation tissue. Collagen I staining was less evident in the ulcer base, but was punctately expressed in the basement membrane zone of the surrounding tissue and enhanced at the ulcer edge. Collagen I and III were present around some blood vessels in the ulcer base, displaying a cuffed appearance similar to laminin and fibronectin (Figure 5D).

Tenascin

Tenascin was present in the extracellular matrix of the surrounding skin and was localized to the epidermal basement membrane in a linear pattern that stained more intensely at the ulcer margin. In the ulcer base, tenascin was weakly expressed apart from as a cuff around blood vessels (Figure 5E).

After Pressure Bandage (2 Weeks)

Major histologic changes were apparent after 2 weeks of pressure bandage therapy (Figure 1B). The epidermis of the surrounding skin was often much thicker than in normal skin and highly keratinized. In the ulcer base, the fibrinous exudate was thinner, and regenerating epidermis was apparent proliferating either above or within it. Sprouting blood vessels and granulation tissue of variable maturity were present in the ulcer base and margin, and there was a marked increase in the number of polymorphonuclear leukocytes infiltrating the tissue. Vessels cuffed with fibrin, laminin, fibronectin, collagen, and tenascin were less abundant in both the new ulcer edge and base. Focal red blood cell extravasation persisted, but there was a striking increase in the amount of hemosiderin deposited in the surrounding tissue. Macrophages were also increased in number. There was no expression of α_1 smooth muscle actin in the ulcer fibroblasts.

With Further Healing

After 2 weeks of either growth hormone or placebo and at 50% reduction in original area, the histologic patterns of healing were similar (Figure 1C). Although biopsies were judged to have been taken from the margin, all were covered by regenerating epithelium, which was generally thinner and less undulating than the surrounding epidermis. Remnants of fibrinous exudate were sometimes present beneath the epidermis. The epidermis often became detached from the underlying dermis, particularly at sites of re-epithelialization. Cuffed blood vessels were inconspicuous or absent throughout the biopsy, but reduced hemosiderin and focal red blood cell extravasation were observed in the surrounding skin and ulcer margin. The granulation tissue showed signs of organi-

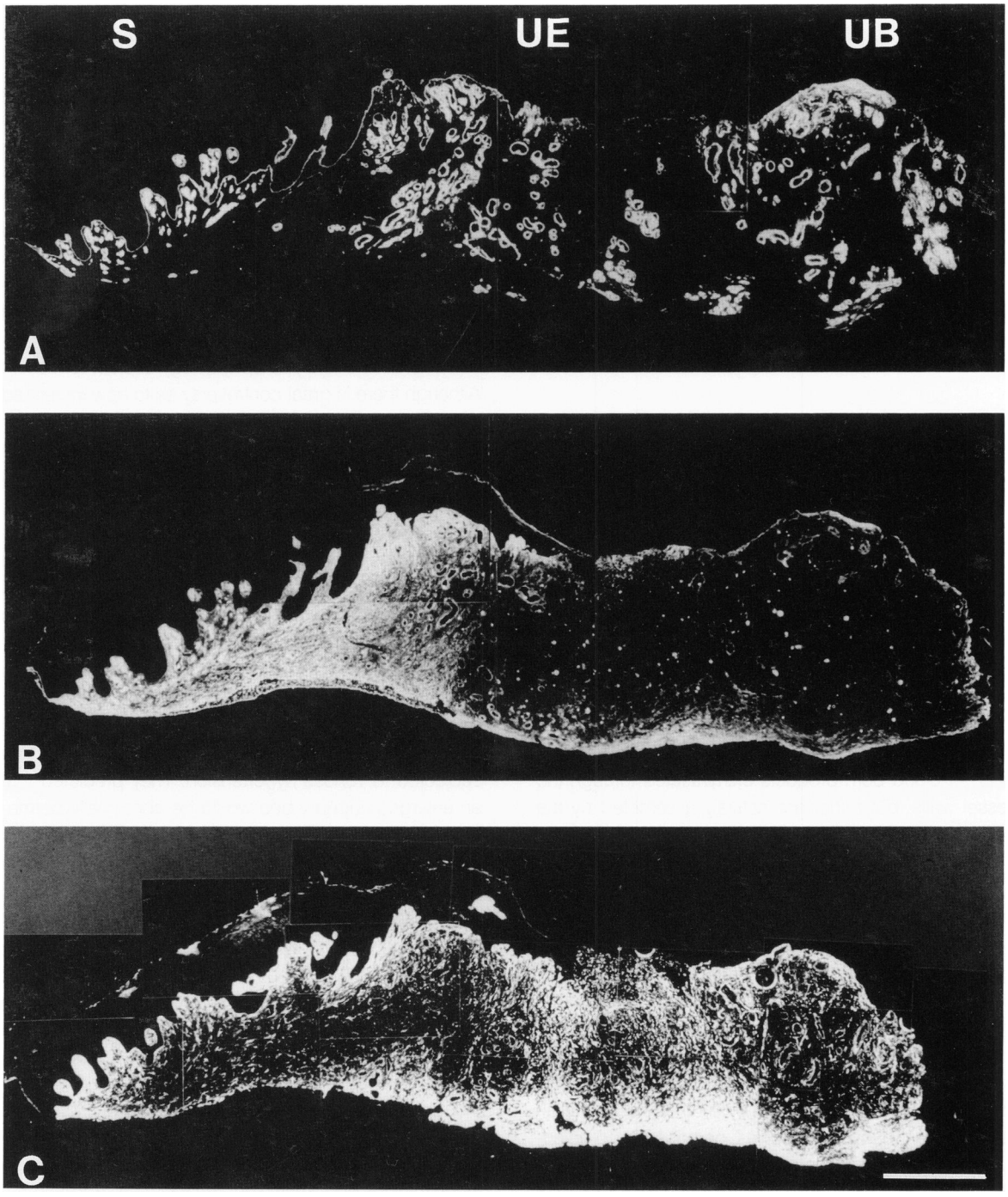

Figure 3. *Initial biopsy including surrounding skin (S), ulcer edge (UE), and ulcer base (UB) stained for laminin* (A), *fibronectin* (B) *and collagen III* (C). *Bar: 1 mm.*

zation, with fibroblasts underlying the ulcer base generally becoming orientated parallel to the surface and often expressing cytoplasmic α_1 smooth muscle actin. A fine fibrillar matrix of fibronectin and collagen was present, and frequently a chronic inflammatory infiltrate was apparent.

Extracellular Matrix Expression During Healing

After re-epithelialization, the pattern of fibronectin and collagen staining of the former ulcer base was indistinguishable from the adjacent surrounding tissue (Figure

4B, C). Staining was decreased in the reticular dermis compared to the papillary and deep layers. Laminin stained punctately in the reformed basement membrane and the regenerated epidermis often became detached during histologic processing (Figure 4A). During healing, neovascularization was pronounced, the sprouting capillaries being surrounded by a thin layer of laminin consistent with the thickness of the basement membrane (but thicker cuffs were absent).

Discussion

During healing of all the ulcer patients, there was a clear sequence of events (Figure 6, Table 2), with no visible differences between biopsies from growth-hormone– and placebo-treated ulcers and no cellular atypia. Biopsies taken at the initial visit were similar in appearance. Prominent fibrin cuffs, focal red blood cell extravasation, and hemosiderin were present and inflammation was variable. So-called fibrin cuffs were found to be highly organized structures and to contain, in addition to fibrin: laminin, fibronectin, tenascin, collagens I and III, and often trapped monocytes, macrophages, and polymorphonuclear leukocytes. These findings suggest that so-called fibrin cuffs are not formed purely by the accumulation of blood born products extravasated through the vessel walls, but rather are actively assembled by the adjacent connective tissue cells.

Major histologic changes were observed after 2 weeks of pressure bandage therapy. Hemosiderin, acute inflammation, and granulation tissue increased with the deposition of fibronectin by migrating fibroblasts, and re-epithelialization commenced. When the ulcer had reduced to 50% or less of its original area, complete epithelialization had often occurred histologically (not evident clinically) along the whole ulcer biopsy: basement membrane formation, however, was not complete. This may be due to a relative lack of biosynthesis of epithelial- and fibroblast-derived molecules, perhaps due to defective interactions between newly migrated fibroblasts and epithelial cells at this junction (or an adverse interaction of the epithelial cells with components of the original ulcer base). Adair[16] showed that epidermal cellular division and migration were not diminished in the skin surrounding venous ulcers and suggested that poor adhesion or increased cellular loss accounted for the delay in healing. "Fibrin cuffs" had completely disappeared by this stage, hemosiderin had decreased, and only a few focal red blood cells were present. Acute inflammation had virtually disappeared, whereas chronic inflammation remained moderate.

Disappearance of blood vessel cuffs seemed to be indicative of ulcer healing. Biopsies that displayed cuffs in the later stages of treatment tended to be from patients with a low or negative rate of ulcer healing. Cuffs decreased in the ulcer margin as well as the ulcer base, suggesting total dissolution of cuffed material during healing.

Blood stasis, capillary damage, edema, and skin hypoxia caused by venous hypertension correlated with calf pump incompetence, is generally agreed to be the underlying factor in the pathophysiology of ulcer formation. Although there is great controversy as to how increased tissue pressure may result in such drastic cellular changes, two main hypotheses have developed[4]: The "fibrin cuff hypothesis" summarized by Browse and Burnand, proposes that as a result of venous hypertension, large molecules such as fibrinogen leak out through enlarged pores of damaged and distended dermal blood vessels. Fibrinogen is quickly polymerized to fibrin and produces cuffs around individual capillaries. These cuffs are thought to impair the exchange of gases, growth factors and nutrients between plasma and dermis, leading to tissue anoxia and ulceration, although this has not been conclusively demonstrated.[17] Burnand et al found an increased number of capillary loops in human skin subjected to venous hypertension. They predicted that an enlarged capillary bed would be abnormally permeable to large molecules such as fibrinogen.[18] Fibrin cuffs were later found surrounding the dermal capillaries in legs of patients suffering from lipodermatosclerosis[13] and also in skin adjacent to venous ulcers.[15] It was also found that the fibrinolytic activity of the blood and tissues is deficient in patients with lipodermatosclerosis and so any conversion of fibrinogen to fibrin and reabsorption was less likely.[19] Studies by Lydon et al[20] apparently show that application of a fibrinolytic hydrocolloid dressing reduced fibrin cuffs and accelerated wound healing, although Layer et al[5] found that Stanozolol (a fibrinolytic anabolic steroid) had little effect on ulcer healing rates.

An alternative theory whereby venous hypertension leads to ulceration, known as "the white cell trapping hypothesis," was proposed by Coleridge Smith et al.[21] They suggest that in response to venous stasis, white blood cells accumulate in capillaries, which in turn leads to increased perivascular resistance. The trapped cells become activated and release toxic metabolites and proteolytic enzymes that result in damage to the capillaries. The capillaries become more permeable to large mole-

Figure 4. *Final biopsy including surrounding skin (S) and ulcer base (UB) stained for laminin* (A), *fibronectin* (B) *and collagen III* (C). *Bar: 1 mm.*

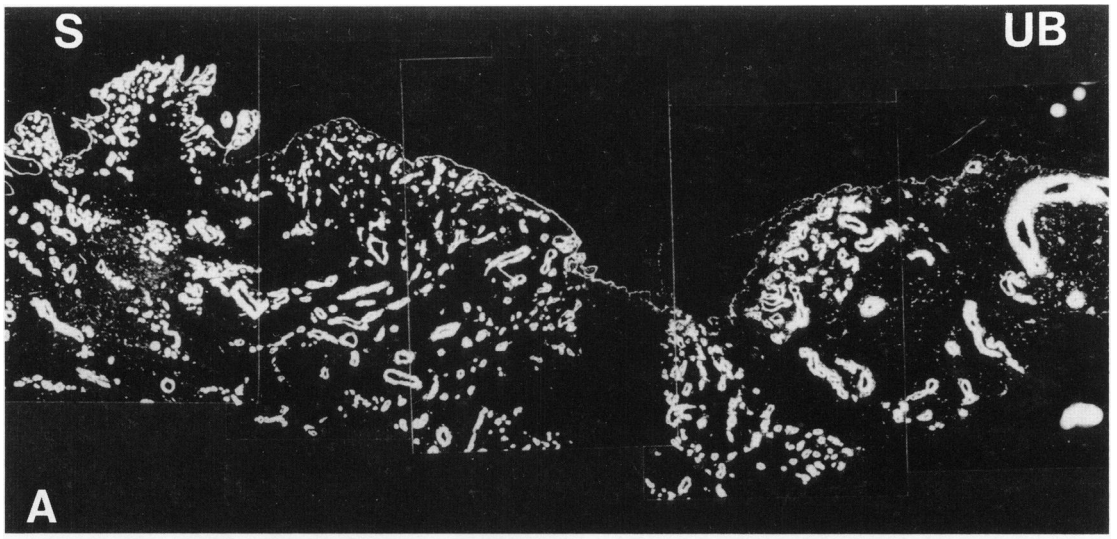
S
UB
A

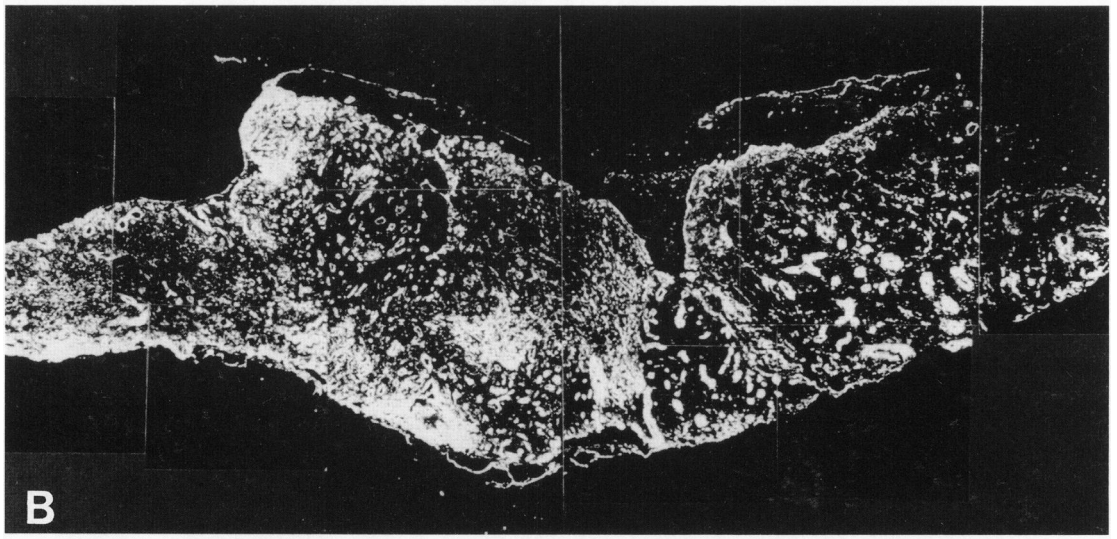
B

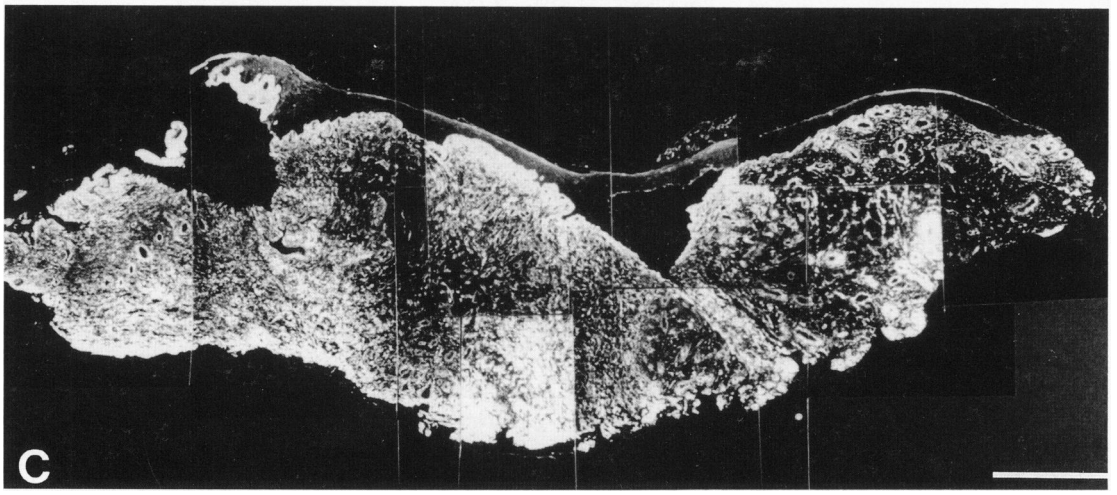
C

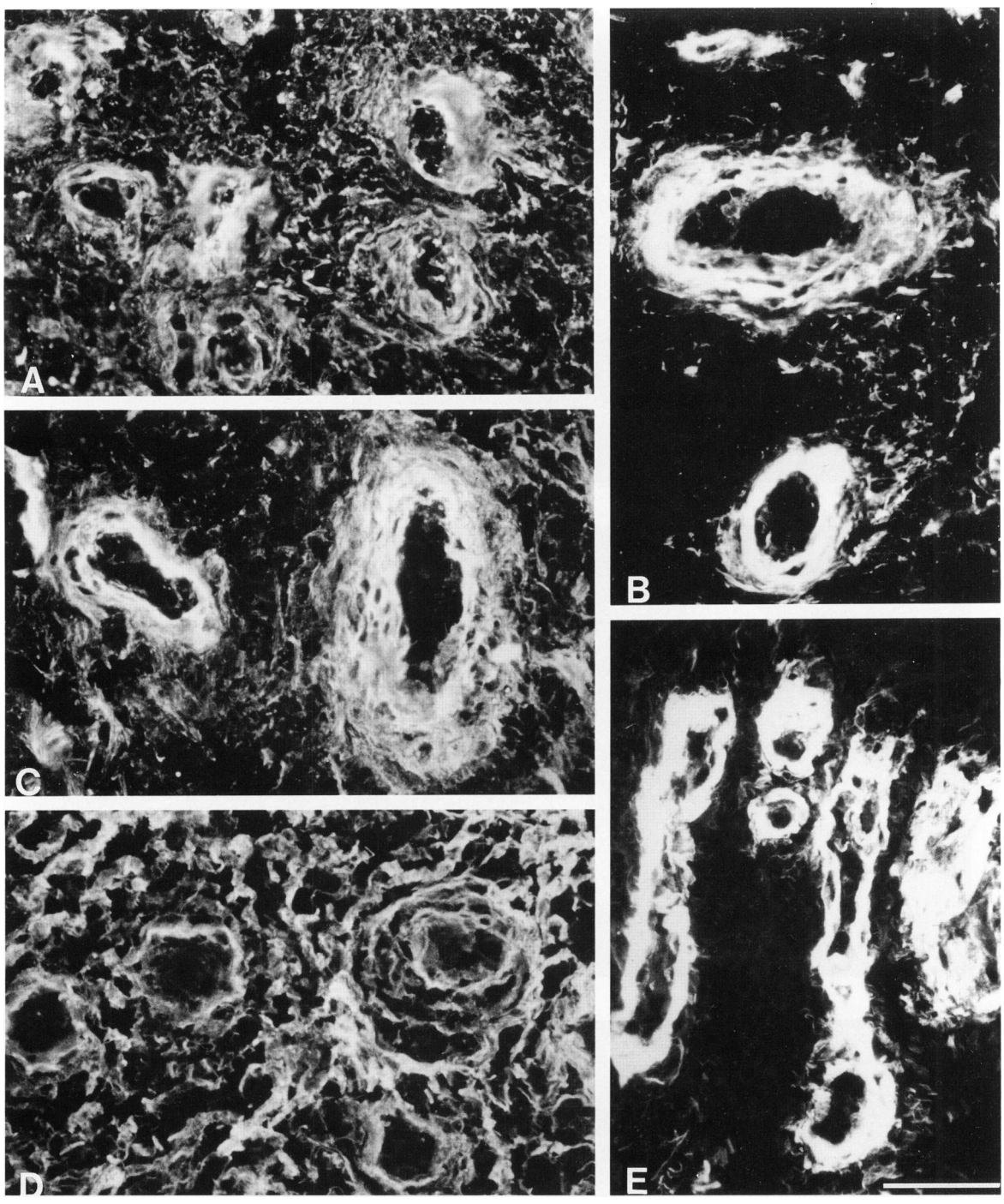

Figure 5. *Blood vessels surrounded by cuffs stained for fibrin* (A), *laminin* (B), *fibronectin* (C), *collagen III* (D), *and tenascin* (E). *Bar: 50 μm.*

cules such as fibrinogen, and fibrin cuffs are formed. Rudofsky's preliminary results[6] using prostaglandin E_1 (an agent that reduces white blood cell activation) to treat venous ulceration were promising. Colgan et al also showed another compound, Oxpentifylline, which affected white cell behavior, had significant effects on ulcer healing rates.[7]

Our results suggest another aspect of venous ulcer pathology. Clearly so-called "fibrin cuffs" around blood vessels contain several molecules other than fibrin (eg, laminin, fibronectin, collagen I and III, and tenascin). This would suggest an active production of extracellular matrix molecules by endothelial, vascular smooth muscle, or fibroblast cells. These cells might be stimulated to syn-

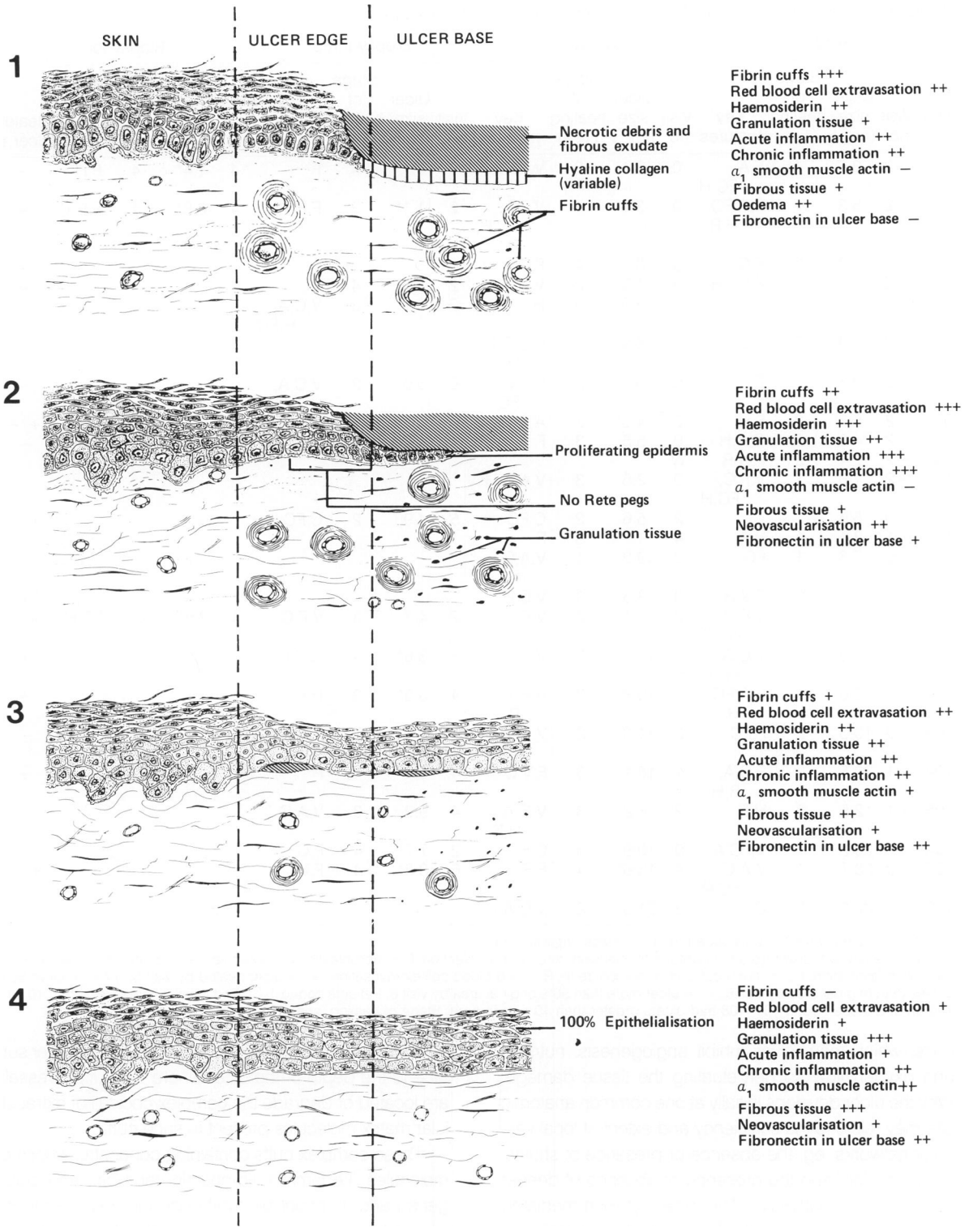

Figure 6. *Schematic representation summarizing histologic and extracellular matrix changes during the healing of venous leg ulcers. Stages 1-4 referred to in Table 2.*

thesize such molecules in response to cytokines released by the accumulated static leukocytes. Thus, the two apparently divergent hypotheses of venous stasis ulcer pathophysiology may be part of the same spectrum of events. Trapped leukocytes (as a result of venous stasis) release a cocktail of cytokines, which elicit chemotactic and biosynthetic responses from the surrounding dermal cells, resulting in the synthesis of complex vessel

Table 2. *Visit Number Compared with Theoretical Stage of Ulcer Healing*

	Biopsy one				Biopsy two				Biopsy three				Biopsy four				
Patient no.	Visit no.	Ulcer size (cm^2)	Stage of healing (1–4)	Key features	Visit no.	Ulcer size (cm^2)	Stage of healing (1–4)	Key features	Visit no.	Ulcer size (cm^2)	Stage of healing (1–4)	Key features	Visit no.	Ulcer size (cm^2)	Stage of healing (1–4)	Key features	Healed ulcer #
1	−2	3.7	1	F,A, FC,H	0	3.1	2	V,F,FC	2	2.1	4	F	4	1.4*	4	F,H	+
2	−2	5.3	1	F,A,FC, H,R	0	3.3	1	V,F,A, FC,H, R	2	1.1*	3	F,H,R	4	0.8*	4	F,H,C	+
3	−2	7.8	3	F,C	0	0.6*	4	F,C									+
4	−2	2.3	1	F,FC,H	0	1.3	2	V,H	2	1.0*	4	V					+
5	−2	5.0	2	I,H	0	3.9	3	H	2	5.1	3	V,C,A, H,FC					+/−
6	−2	7.9	2	V,C	0	8.9	2	F,C,FC, H									+
7	−2	9.3	2	F,C	0	6.9	2	F,A,C, FC	6	6.9	2	V,C,A, H,FC					−
8	−2	8.7	2	F,H	2	4.3*	3	A,C,H									+/−
9	−2	4.9	2	C,A,H	0	5 5	3	F	4	4.7	3	V,C,A					−
10	−2	7.4	2	F,H,R	W												
11	−2	1.8	1	V,F,C, FC,H	0	2.5	3	V,A,C,H									+
12	0	5.9	1	I	2	5.6	2	C,FC	5	4.9	2	C,FC,H					+/−
13	1	8.1	1	V,A	4	1.7*	3	F									+
14	0	7.3	1	FC	2	8.9	1	V,A,C, FC									−
15	−2	2.6	2	F,V,H	0	3.5	3	V,C,H									+
16	−2	5.5	1	V,F,C, A,FC	0	5.1	2	V,F	2	4.7	3	V,F,C	4	2.5*	3	FC,H	+/−
101	−2	11.0	1	V,C,A, FC,H	0	10.1	2	V,A,C, FC	3	3.6*	4	A,C,H					+
102	−2	12.6	1	V,A,FC, H	1	10.8	2	A,H,I, R	4	3.8*	3	H,R					+
103	0	13.3	2	F,FC	2	11.8	2	V,F,A, FC,I									−
104	−1	20.5	2	F,C,A, R,H	1	18.1	3	F,V,C	4	8.4*	4	F					+
105	−1	12.5	2	H,R	2	8.2	3	V,C,A, H,R	4	9.9	3	V,A,C					−
106	−2	20.2	1	V,FC,A	0	10.9	3	C,FC	2	7.7	4	F,C					+
107	0	28.7	1	V,A,C, FC,R	4	13.6*	4	F,R	6	3.8*	4	F,H					+/−
108	0	30.9	2	C	2	31.8	2	V,C,A,I									−

* Biopsy taken when ulcer reduced to 50% or less original area.

W = patient withdrawn (did not conform to inclusion criteria). I = infection; F = fibroblastic; V = vascular; A = acute inflammation; C = chronic inflammation; FC = fibrin cuffs; H = hemosiderin; R = red blood cell extravasation. + = ulcer healed by visit 6; +/− = ulcer 50% or less than original area by visit 6; − = ulcer more than 50% original area by visit 6. Patients coded 1–16 had initial ulcers of less than 10 cm^2 in area and those coded 101–108 had ulcers greater than 10 cm^2 in area. Stage of healing, see Figure 6.

cuffs, which themselves inhibit angiogenesis, nutrient, and oxygen flow so perpetuating the tissue damage. Why the ulcer develops initially at one common anatomic site may relate to the sufficiency and extent of local vascular networks, eg, the absence or presence of shunts, tissue tension, and the presence or absence of deeper venous return pathways. The initial cytokine-mediated damage also may be in the form of a reperfusion injury: leukocytes being slowed, pavemented, and degenerating as the venous pressure rises when the patient is standing, but the noxious effects of these cytokines being manifested when reperfusion occurs, eg, on elevating the leg when lying down.

It is difficult to understand how fibrinolytic agents could either penetrate from the bandage at the ulcer surface to the depth of the ulcer where the cuffed vessels are located or degrade the complex cocktail of extracellular matrix molecules present in such cuffs.

These complex cuffs containing concentric whorls of molecules like laminin, fibronectin, tenascin, and collagens I and III, might be synthesized in response to increased venous pressure to protect the delicate vessels and enable them to withstand the higher pressures. Such cuffs may inhibit capillary sprouting, so limiting angiogenesis and neovascularization as well as acting as a barrier to gasses and nutrients. Although some molecules as well as red blood cells may leak from the vessels initially, once a suitable barrier is produced further leakage may

be reduced. As venous return is improved due to pressure bandaging, and venous hypertension reduced, leukocyte trapping may be reduced, the local levels of cytokines fall, the reperfusion injury cease, and so the vessel cuffs would no longer be synthesized, rather degraded, possibly yielding polypeptide products with angiogenic activity. Lydon et al[20] also suggested that lysis of fibrin cuffs during healing could provide direct or indirect stimuli for generation and directional migration of new blood vessels, leukocyte invasion, fibroblast migration, angiogenesis, and re-epithelialization. Even simple degradation of the cuffs may "release" endothelial cells and pericytes from an adhesive environment and so facilitate sprouting and angiogenesis, as well as improving tissue nutrition and oxygenation.

The observation that disappearing vascular cuffs correlate with the moving ulcer margin and are predictive of the stage of healing, may be used as a prognostic feature in trials to monitor venous ulceration therapies.

Acknowledgments

The authors thank Sue Holland for technical assistance with special histologic stains, and Allen Edwards, Debbie Simon, and staff of the leg ulcer clinic, Department of Surgery, University Hospital of South Manchester for providing the necessary clinical regimens for the patients reported in this article.

References

1. Callam MJ, Ruckley CV, Harper DR, Dale JJ: Chronic ulceration of the leg: extent of the problem and provision of care. Br Med J 1985, 290:1855–1856
2. Burnand KG: Etiology of venous ulceration. Br J Surg 1990, 77:483–484
3. Falanga V, Kruskal J, Franks JJ: Fibrin- and fibrinogen-related antigens in patients with venous disease and venous ulceration. Arch Dermatol 1991, 127:75–78
4. Sarin S, Cheatle TR, Coleridge Smith PD, Scurr JH: Disease mechanisms in venous ulceration. Br J Hosp Med 1991, 45:303–305
5. Layer GT, Stacey MC, Burnand KG: Stanozolol and the treatment of venous ulceration- an interim report. Phlebology 1986, 1:197–203
6. Rudofsky G: Intravenous prostaglandin E1 in the treatment of venous ulcers- a double-blind, placebo-controlled trial. Vasa 1989, 28:39–43
7. Colgan MP, Dormandy JA, Jones PW, Schraibman IG, Shanik DG, Young RAL: Oxpentifylline treatment of venous ulcers of the leg. Br Med J 1990, 300:972–975
8. Knighton DR, Ciresi K, Fiegel VD, Schumerth S, Butler E, Cerra F: Stimulation of repair in chronic, nonhealing, cutaneous ulcers using platelet-derived wound healing formula. Surg Gynaecol Obstet 1990, 170:56–60
9. Bancroft JD, Stevens A: Theory and practice of histological techniques. Edinburgh, Churchill Livingstone, 1977
10. Polak JM, Van Noorden S: Immunocytochemistry, Modern Methods and Applications. Bristol, Wright, 1986
11. Whitby DJ, Ferguson MWJ: The extracellular matrix of lip wounds. Development 1991, 112:651–668
12. Johnson GD, Davidson RS, McNamee KC, Russel G, Goodwin D, Holborow EJ: Fading of immunofluorescence during microscopy: A study of the phenomenon and its remedy. J Immunol Methods 1982, 55:231–242
13. Burnand KG, Whimster I, Naidoo A, Browse NL: Pericapillary fibrin in the ulcer-bearing skin of the leg: The cause of lipodermatosclerosis and venous ulceration. Br Med J 1982, 72:1072–1072
14. Leach RD: Venous ulceration, fibrinogen and fibrinolysis. Ann R Coll Surg Eng 1984, 66:258–263
15. Falanga V, Moosa HH, Nemeth AJ, Alstadt SP, Eaglstein WH: Dermal pericapillary fibrin in venous disease and venous ulceration. Arch Dermatol 1987, 123:620–623
16. Adair HM: Epidermal repair in chronic venous ulcers. Br J Surg 1977, 64:800–804
17. Browse NL, Burnand KG: The cause of venous ulceration. Lancet 1982, ii:243–245
18. Burnand KG, Whimster I, Clemenson G, Lea Thomas M, Browse NL: The relationship between the number of capillaries in the skin of the venous ulcer-bearing area of the lower leg and the fall in foot vein pressure during exercise. Br J Surg 1981, 68:297–300
19. Browse NL, Gray L, Jarrett PEM, Morland M: Blood and vein-wall fibrinolytic activity in health and vascular disease. Br Med J 1977, i:478–481
20. Lydon MJ, Cherry GW, Cederholm-Williams SA, Pickworth JJ, Cherry C, Scudder C, Johnson ER, Ryan TJ, Fairbrother JE: Fibrinolytic activity of hydrocolloid dressings, Beyond Occlusion: Wound Care Proceedings. Edited by TJ Ryan. Royal Society of Medicine International Congress and Symposium Series No 136, Royal Society of Medicine Services Limited, 1988, pp 9–17
21. Coleridge Smith PD, Thomas P, Scurr JH, Dormandy JA: Causes of venous ulceration: A new hypothesis. Br Med J 1988, 296:1726–1727