INFECTION AND IMMUNITY, Apr. 1994, p. 1262–1267
0019-9567/94/$04.00+0
Copyright © 1994, American Society for Microbiology
Vol. 62, No. 4

In Vivo Association of *Actinobacillus pleuropneumoniae* Serotype 2 with the Respiratory Epithelium of Pigs

PETER DOM,[1]* FREDDY HAESEBROUCK,[1] RICHARD DUCATELLE,[2] AND GERARD CHARLIER[3]

Laboratory of Veterinary Bacteriology and Mycology,[1] and Department of Veterinary Pathology,[2] Faculty of Veterinary Medicine, University of Ghent, Ghent, and National Institute for Veterinary Research (NIDO), Brussels,[3] Belgium

Received 16 November 1993/Returned for modification 22 December 1993/Accepted 21 January 1994

The ability of an *Actinobacillus pleuropneumoniae* serotype 2 strain to associate in vivo with the epithelium of the porcine respiratory tract was investigated in a sequential study after intranasal inoculation of hysterectomy-derived and colostrum-deprived pigs. At 30 min postinoculation more than 95% of the bacteria present in the lungs were intimately associated with the epithelium of the alveoli or the cilia of the terminal bronchioli, as observed by light and electron microscopy. At 90 and 180 min postinoculation multiple focal early inflammatory lesions in which histologically different, more or less concentric zones could be distinguished were observed. In the center of these pneumonic areas bacteria were associated with infiltrated cells and exudate. In the zone surrounding the center, approximately 95% of the bacteria were lying with their longest side in close apposition to the epithelial cells of alveoli and the cilia of the terminal bronchioli. Bacteria were only sporadically associated with the cilia or the epithelium of the bronchi and trachea. Bacteria were not observed in tonsils or conchae. In view of the findings presented here, we propose the hypothesis that adherence of the *A. pleuropneumoniae* serotype 2 strain to epithelial cells of the lower respiratory tract constitutes an important initial step in pathogenesis.

Contagious pleuropneumonia, caused by *Actinobacillus pleuropneumoniae*, has important economic implications for the pig industry worldwide (19). The protection of swine against *A. pleuropneumoniae* infection has been an aim of veterinary scientific research for several years. Successful control of the infection, however, requires knowledge of the virulence factors of the bacteria and the pathogenesis of the disease. *A. pleuropneumoniae* displays several virulence factors, including RTX toxins. These proteins, which are secreted by the bacteria, are toxic for porcine erythrocytes, endothelial cells, macrophages, and neutrophils (8, 15, 20). The importance and the exact meaning of other potential virulence factors in the pathogenesis of pleuropneumonia, however, remain unclear.

During the course of many infectious diseases, including pulmonary infections, bacteria colonize body sites by engaging their surface-bound adhesins with cognate receptors available on host cells. The recognition and attachment processes are therefore considered to be the first steps in establishing bacteria at a given site (9, 10). Additionally, the ability of bacteria to interact with cells may mediate delivery of high concentrations of toxic products (for example, exotoxins) to the surface of the eukaryotic cells, resulting in destruction of the target cell (17). Almost no information is available on the significance of adherence in the pathogenesis of pleuropneumonia. *A. pleuropneumoniae* has been isolated from nasal cavities and tonsils, suggesting the colonization of the epithelium of the nasopharynx by the bacterium (16, 21, 23). Adherence of *A. pleuropneumoniae* to the epithelium of the upper respiratory tract has, however, not been demonstrated. Recently, hemagglutination (12) as well as in vitro adherence of *A. pleuropneumoniae* to porcine tracheal epithelial cells, frozen lung sections, and mucus of the respiratory tract (1, 11) has been described. However, evidence for in vivo adherence of *A. pleuropneumoniae* to respiratory epithelium has not been provided so far.

The objective of this work was to investigate the in vivo association of an *A. pleuropneumoniae* serotype 2 strain with the epithelium of the porcine respiratory tract. This phenomenon was examined in a sequential study using light, scanning, and transmission electron microscopy (SEM and TEM, respectively).

MATERIALS AND METHODS

Bacterial strain. A NAD-dependent *A. pleuropneumoniae* serotype 2 strain (266/7656), isolated from a pig with pleuropneumonia in Belgium, was used in these studies. Characteristics of this strain, such as production of RTX toxins, interaction with phagocytes, and the ability to reproduce pleuropneumonia in pigs, have been described previously (3–6). Stock suspensions were stored at −70°C in leukocyte medium (RPMI 1640 [GIBCO Europe, Ghent, Belgium] supplemented with 10% nonessential amino acids, 10% glutamine, 10% fetal calf serum, and 1% sodium pyruvate). After thawing, the bacteria were grown overnight at 37°C in an atmosphere of 5% CO_2 on Columbia agar (Columbia agar base; Lab m, Bury, Great Britain) supplemented with 5% bovine blood, 0.03% NAD (Sigma Chemical Co., St. Louis, Mo.), and 5% yeast extract. Subsequently, colonies were transferred to Columbia agar supplemented with 3% equine serum, 0.03% NAD, and 5% yeast extract. These plates were incubated for 6 h at 37°C in a 5% CO_2 atmosphere. Bacteria were harvested in phosphate-buffered saline solution (PBSS, pH 7.3), centrifuged at 400 × *g* for 20 min, and suspended in leukocyte medium. The suspension was checked for purity, and the number of CFU was determined by

* Corresponding author. Mailing address: Laboratory of Veterinary Bacteriology and Mycology, Faculty of Veterinary Medicine, University of Ghent, Casinoplein 24, B-9000 Ghent, Belgium. Phone: 32 92 23 37 65. Fax: 32 92 33 22 34.

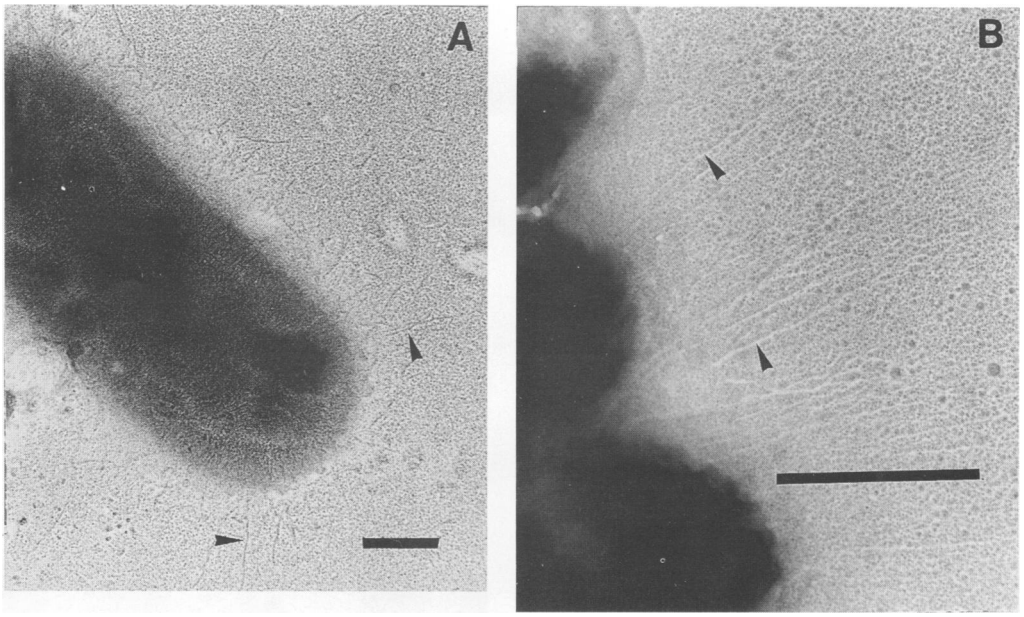

FIG. 1. (A and B) Electron micrographs of a 6-h culture of the *A. pleuropneumoniae* serotype 2 strain stained by rotary shadowing. Long and thin filamentous appendages are indicated with arrowheads. Bars, 200 nm.

plating 10-fold dilutions on Columbia agar supplemented with 5% blood, 0.03% NAD, and 5% yeast extract. Bacterial suspensions were stored overnight at 4°C. The next day, the bacteria were washed once in PBSS before being used in the experiments.

Examination for fimbriae. Bacteria from a 6-h culture were examined for the presence of fimbriae by negative staining and shadowing after they were suspended in a minimal amount of distilled water. For negative staining, a Formvar-coated copper grid was floated on the surface of the bacterial suspension for 10 min. Then the grid was floated for 10 s on a solution of 2% (wt/vol) uranyl acetate in distilled water. After staining, the grid was washed two times and observed with a Philips 201 TEM. For shadowing, the bacterial suspension was absorbed on carbon-coated grids and rotary shadowed with platinum-carbon at a small angle (5 to 6°) with the Balgers shadowing apparatus. The grid was examined with a Philips 201 TEM.

Infection of pigs. Eight hysterectomy-derived and colostrum-deprived pigs were used in this study. The pigs were kept in isolators to prevent cross infections with different strains of bacteria or viruses. At the age of 30 to 34 days, six pigs were inoculated intranasally with 5 ml of inoculum containing 10^9 CFU of the *A. pleuropneumoniae* strain per ml. At 30, 90, and 180 min postinoculation (p.i.), two pigs (at each time) were euthanized, bled, and necropsied. Two additional pigs were inoculated with 5 ml of PBSS and served as controls. Specimens were collected for bacteriological and light and electron microscopical examination.

Bacteriology. Samples from the conchae, tonsils, tracheae, bronchi, and lungs were cultured on Columbia agar supplemented with 5% bovine blood with a *Staphylococcus intermedius* inoculation streak. Identification of the colonies as *A. pleuropneumoniae* was based on the satellitism phenomenon, the positive hemolysis and the positive CAMP reaction. Serotyping was performed as described previously (7).

Microscopy. Samples from conchae, tonsils, tracheae, bronchi, and lungs collected for light microscopy were immediately immersed in buffered formalin (10%) and processed for paraffin sectioning according to standard techniques. Sections were stained with hematoxylin and eosin, Giemsa, and periodic acid-Schiff stain. The percentage of bacterial adherence after 30, 90, and 180 min p.i. was determined in Giemsa-stained sections. At least 1,000 bacteria were counted in samples from each infected pig. In order to identify bacteria as *A. pleuropneumoniae* serotype 2, sections were also stained by an indirect immunoperoxidase technique. For this purpose, hyperimmune rabbit antiserum against the *A. pleuropneumoniae* serotype 2 strain was prepared as described previously (7). Sections were incubated for 1 h with rabbit anti-*A. pleuropneumoniae* serum in PBSS (diluted 1:2,000) followed by 1 h of incubation with peroxidase goat anti-rabbit serum (Nordic Immunological Laboratories B. V., Tilburg, The Netherlands) in a dilution of 1:100. Slides were washed and incubated with diaminobenzidine tetrahydrochloride and hydrogen peroxide in PBSS for 3 min. Finally, the sections were counterstained with hematoxylin for 2 min. The specificity of the test had previously been determined by examining lung tissue of pigs infected with *A. pleuropneumoniae* serotypes 2, 3, and 9. No cross-reactions were observed with serotypes 3 and 9.

Samples from conchae, tonsils, tracheae, bronchi, and lungs for electron microscopy were immediately fixed in cacodylate buffer (0.1 M, pH 7.3) containing 2.5% gluteraldehyde and 2% paraformaldehyde. The samples were postfixed in 1% (wt/vol) osmium tetroxide in distilled water. Samples for SEM were dehydrated in alcohol and acetone for subsequent critical point drying in liquid carbon dioxide, glued with carbon cement on aluminum stubs, sputtered with a gold layer, and examined with a Philips 501 SEM. Samples for TEM were block stained with 2% (wt/vol) uranyl acetate in distilled water and dehydrated in ethanol. They were embedded in Epon-Spurr's (1:1) medium. Semithin sections were cut, stained with toluidine blue, and examined for the presence of bacteria and lesions. Ultrathin sections were cut from samples in which bacteria were demonstrated, stained with lead citrate, and examined with a Philips 201 TEM.

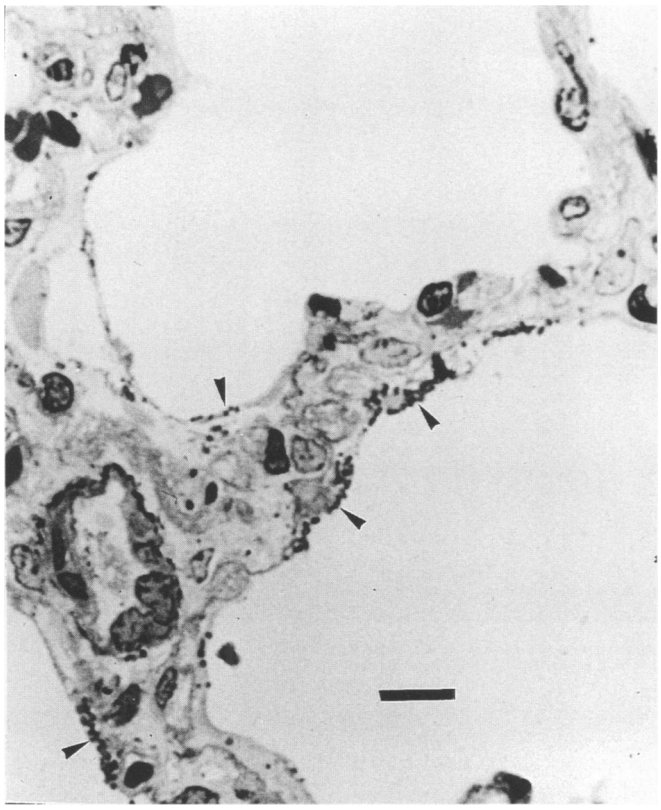

FIG. 2. Toluidine blue-stained semithin section of the lung from a pig at 30 min p.i. with *A. pleuropneumoniae* serotype 2. Note the bacterial colonization of the lung epithelium (arrowheads). Bar, 10 μm.

RESULTS

Presence of fimbriae. In the present study, fimbriae were not demonstrated by negative staining. Rotary shadowing, on the other hand, revealed the presence of numerous, filamentous, 100- to 300-nm-long and approximately 1-nm-wide appendages that were peritrichous in distribution (Fig. 1). We refer to these structures as fimbriae.

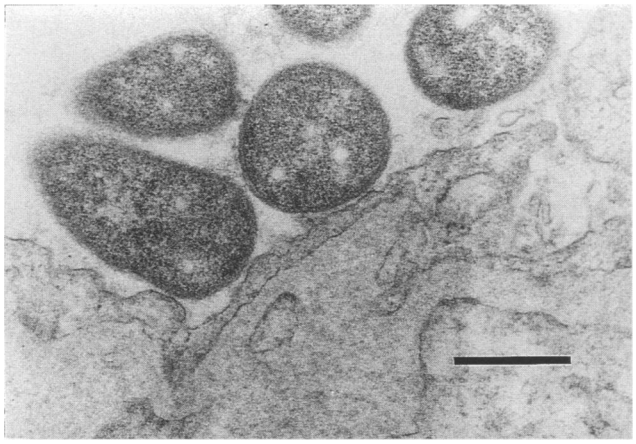

FIG. 3. Transmission electron micrograph of the sample shown in Fig. 2. Bacteria are closely associated with the alveolar epithelial cell membrane. Bar, 500 nm.

FIG. 4. Scanning electron micrograph of the lung from a pig at 30 min p.i. with *A. pleuropneumoniae* serotype 2. Bacteria are closely associated with the cilia of terminal bronchioli. Note the presence of dividing bacteria (arrowhead). Bar, 1 μm.

Clinical signs. One of the infected pigs developed respiratory distress 150 min p.i. The other pigs, including the controls, remained clinically normal.

Macroscopic lesions. In one of the two pigs necropsied 30 min p.i., small areas with thickened interlobular septa were observed. The other pig necropsied 30 min p.i. had no gross lesions at necropsy. At 90 min p.i., the two pigs had multiple sublobular or lobular foci of consolidation of 1 to 2 mm in diameter scattered throughout the caudal lobes. In a zone with a diameter of approximately 5 mm around these foci, the interlobular septa were thickened. Lobular and sublobular foci of consolidation of 1 to 5 mm in diameter were distributed throughout the caudal and cranial lobes in the two pigs at 180 min p.i. Edema and thickening of the interlobular septa in and around these areas were observed. At necropsy, no macroscopic lesions were observed in the control pigs.

Bacteriology. *A. pleuropneumoniae* serotype 2 was isolated in profuse and pure cultures from lungs and bronchi of all infected pigs. Only few *A. pleuropneumoniae* serotype 2 organisms were isolated from the trachea of one pig at 30 min p.i. Abundant, pure cultures of *A. pleuropneumoniae* serotype 2 were isolated from the tracheae of the other five infected pigs. Fewer than 10 colonies of *A. pleuropneumoniae* serotype 2 were detected on culture plates inoculated with samples from the conchae or the tonsils of three pigs. *A. pleuropneumoniae* was not isolated from the conchae or the tonsils of the other pigs. Samples collected from the control pigs were free of bacteria.

Association of *A. pleuropneumoniae* with epithelium in the lungs. At 30 min p.i. localized areas with thickening of interlobular septa by edema and dilated lymphatics were observed in histological sections of the lungs. Alveoli occasion-

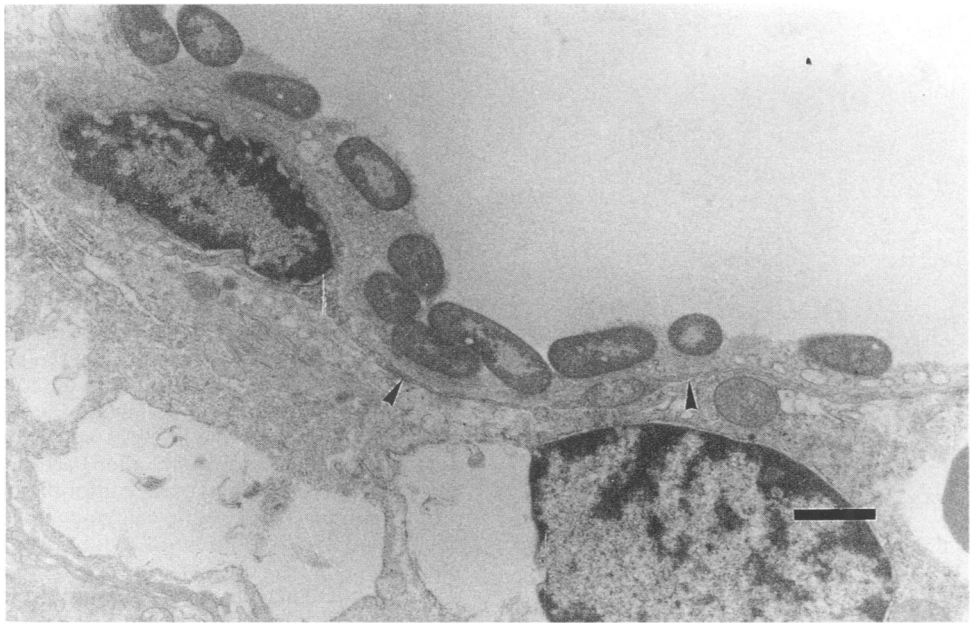

FIG. 5. Transmission electron micrograph of the sample shown in Fig. 4. The alveolar epithelium (arrowheads) is coated with a 0.2- to 0.6-μm-thick layer of exudate. Bacteria are associated with the luminal exudate surface and are lying with their longest side parallel to the cell membrane of the alveolar cells. Bar, 1 μm.

ally contained exudate and erythrocytes. No other pathological lesions were observed. Giemsa and toluidine blue staining revealed that more than 95% of the bacteria present in the lungs were associated with the epithelium of the alveoli (Fig. 2) or the cilia of the terminal bronchioli. Adherence to alveolar type I as well as type II cells was observed. Bacteria were present singly, in small groups, or as aggregates of 20 to more than 100 bacteria. The immunoperoxidase technique revealed numerous dark brown bacteria associated with the epithelium, indicating the presence of *A. pleuropneumoniae* serotype 2. TEM revealed numerous rod-shaped bacteria intimately attached to the alveolar epithelial cell membrane, with a more or less regular gap of 10 to 15 nm (Fig. 3). The association of rod-shaped bacteria with the alveolar epithelium and cilia in the bronchioli (Fig. 4) was also demonstrated by SEM. In some localized zones the alveolar epithelium was coated with a 0.2- to 0.6-μm-thick layer of exudate. Bacteria in these areas were associated with the luminal surface of the exudate and were lying with their longest side parallel to the cell membrane of the alveolar cells (Fig. 5). Approximately 5% of the bacteria were lying in the alveolar or bronchiolar lumen. More than 50% of these bacteria were associated with debris or exudate; the remaining bacteria were lying free in the lumen.

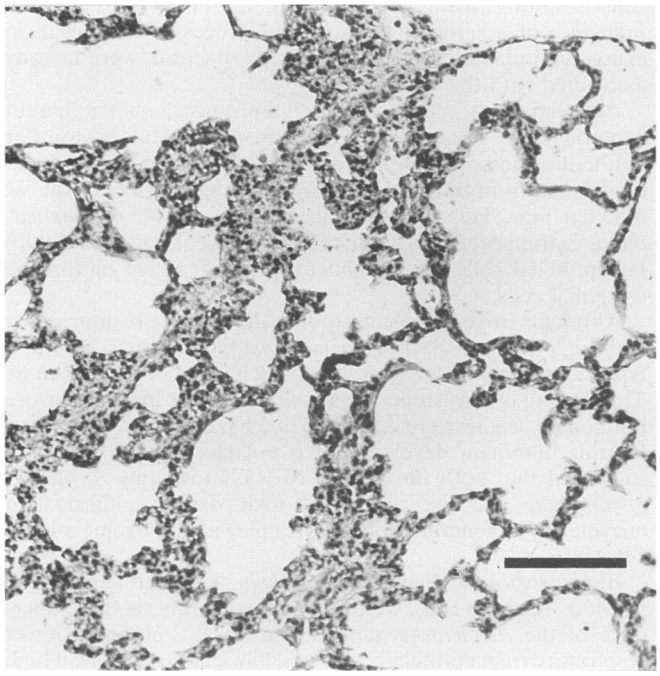

FIG. 6. Hematoxylin- and eosin-stained histologic section through a focal lesion in the lung from a pig at 90 min p.i. with *A. pleuropneumoniae* serotype 2. This zone is characterized by interalveolar septal thickening. Bar, 100 μm.

At 90 and 180 min p.i., multiple focal lesions were observed in histological sections of the lungs. At 90 min p.i. the lesions had a diameter of 1 to 2 mm; at 180 min p.i. the lesions had a diameter of 1 to 5 mm. Three histologically different, more or less concentric zones could be distinguished in these lesions (Fig. 6 and 7). In the center of these pneumonic areas the primary structure of the lungs was lost. The interalveolar septa were thickened as the result of capillary congestion, hemorrhages, and cellular infiltration. Alveoli were filled with exudate, numerous erythrocytes and macrophages, fibrin, and some neutrophils. Periodic acid-Schiff staining was negative. This is an indication that the exudate contained no mucin. Since the exudate was eosinophilic, it was probably proteinous in nature. Aggregates of rod-shaped bacteria were associated with the cells and the exudate. Single bacteria were observed sporadically. In the zone which was situated more or less concentrically around the center, the primary structure of the lungs was recognizable. This zone was characterized by inter-

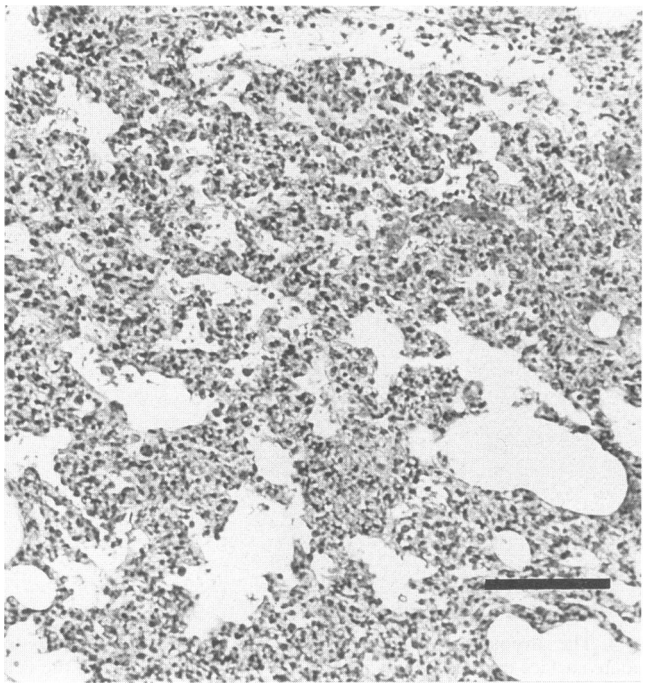

FIG. 7. Hematoxylin- and eosin-stained histologic section through a lesion in the lung from a pig at 180 min p.i. with *A. pleuropneumoniae* serotype 2. The primary structure of the lung is lost in this area. The interalveolar septa are thickened severely, and alveoli are filled with cells and exudate. Bar, 100 μm.

alveolar septal thickening and some small hemorrhages. The alveoli and terminal bronchioli in this zone contained exudate. High numbers of bacteria, singly or in small groups, were lying associated with this exudate in the alveolar and bronchiolar lumen. A third zone surrounding these areas showed no histological lesions. In this zone rod-shaped bacteria were visible. The number of bacteria decreased as the distance from the center of the lesions increased. Approximately 95% of the bacteria in the periphery of the lesions were lying with their longest side close and parallel to the epithelial cells of alveoli and the cilia of the terminal bronchioli. The immunoperoxidase technique revealed the presence of *A. pleuropneumoniae* serotype 2 in sections of all samples in which bacteria were demonstrated. The adherence of rod-shaped bacteria to alveolar epithelium and bronchiolar ciliae was also demonstrated by TEM and SEM.

Bacteria and microscopic lesions were not observed in the control pigs.

Association of *A. pleuropneumoniae* with epithelium of the upper respiratory tract. In all infected pigs, low numbers of rod-shaped bacteria were lying free or associated with some cellular debris in the lumen of the bronchi and trachea. Sporadically, bacteria were associated with the cilia or the epithelium of the bronchi and trachea. The immunoperoxidase technique revealed the presence of *A. pleuropneumoniae* serotype 2 in sections of all samples in which bacteria were demonstrated. Bacteria were not observed in the bronchi or trachea by TEM or SEM. Bacteria were not observed in histological sections of tonsils or conchae.

DISCUSSION

In the present report, the hitherto poorly understood early stages of the pathogenesis of *A. pleuropneumoniae* infections were studied. We demonstrated in vivo association of an *A. pleuropneumoniae* serotype 2 strain with porcine alveolar and bronchiolar epithelium. Although in vitro adherence of *A. pleuropneumoniae* to porcine tracheal epithelial cells and frozen lung sections and hemagglutination has already been described (1, 11, 12), to our knowledge this is the first study showing in vivo adherence.

The present study does not emphasize the question of the nature of the mechanisms involved in the interaction between the *A. pleuropneumoniae* strain and the respiratory surface. It is not clear whether the interaction is either a more or less weak, reversible association or a stable attachment mediated by bacterial adhesins and specific receptors on eukaryotic cell membranes. Recently, the presence of fimbrial structures on *A. pleuropneumoniae* isolates has been described (21). In many bacterial species, fimbriae are involved in adherence to mucosal surfaces (13). In the present study, fimbriae also were demonstrated. However, any other bacterial surface antigens which have a stereochemical conformation, hydrophobicity profile, and net electrostatic charge complementary with certain membrane structures on a target cell could evolve as potential adhesins (13). Further in vitro studies are required to determine whether bacterial adhesins are involved in attachment and, if so, to identify them.

At 30 min p.i. most bacteria were closely associated with the alveolar and bronchiolar epithelium. At 90 and 180 min p.i. three histologically different, more or less concentric zones could be distinguished, probably reflecting three different stages of progress in the early pathogenesis of contagious pleuropneumonia. In the zones in which histological lesions were not observed, 95% of the bacteria were lying with their longest side close and parallel to the epithelial cells of alveoli. These findings suggest that the bacterial association with the alveolar and bronchiolar epithelium is one of the first steps in pathogenesis. This association may mediate delivery of high concentrations of RTX toxins to the surface of the eukaryotic cells, resulting in the destruction of the target cells and the induction of a series of pathological processes that result in exudative inflammation. At 90 min p.i. bacteria were already associated with the exudate.

Although pigs were inoculated intranasally, no adherent bacteria were observed on the nasopharyngeal or tonsilar epithelium, and only few *A. pleuropneumoniae* organisms could be isolated from the tonsils or nasal cavities of three of the six infected pigs. This finding indicates that the *A. pleuropneumoniae* strain preferably adheres to the alveolar and bronchiolar epithelial cells rather than to nasopharyngeal or tonsilar epithelial cells.

Although in the present studies the pigs were inoculated with high doses of *A. pleuropneumoniae*, it is remarkable that typical lesions were present within such short periods of time. This finding is consistent with previous reports in which severe pulmonary lesions were described at 3 h p.i. (2, 18). The reason for this fulminant development is not clear, but it has been suggested that both the release of RTX toxins by *A. pleuropneumoniae* and the release of toxic oxygen radicals and enzymes by degenerated phagocytes play an important role (4, 14, 22).

In conclusion, in view of the findings presented here and in previous reports (5, 6), we propose the hypothesis that adherence of the *A. pleuropneumoniae* serotype 2 strain to lower respiratory tract epithelial cells, possibly leading to a local high concentration of RTX toxins, constitutes an important initial step in pathogenesis. Further studies are required to determine whether adherence occurs with other strains belonging to different serotypes.

ACKNOWLEDGMENTS

The technical assistance of N. Van Loocke, M. Martens, M. Gheyle, and C. Puttevils is gratefully appreciated.

This study was supported by the Institute for the Encouragement of Research in Industry and Agriculture (IWONL), Brussels, Belgium.

REFERENCES

1. **Bélanger, M., D. Dubreuil, J. Harel, C. Girard, and M. Jacques.** 1990. Role of lipopolysaccharides in adherence of *Actinobacillus pleuropneumoniae* to porcine tracheal cells. Infect. Immun. **58:** 3523–3530.
2. **Bertram, T. A.** 1985. Quantitative morphology of peracute pulmonary lesions in swine induced by *Haemophilus pleuropneumoniae*. Vet. Pathol. **22:**598–609.
3. **Dom, P., and F. Haesebrouck.** 1992. Comparative virulence of NAD-dependent and NAD-independent *Actinobacillus pleuropneumoniae* strains. J. Vet. Med. B. **39:**303–306.
4. **Dom, P., F. Haesebrouck, and P. De Baetselier.** 1992. Stimulation and suppression of the oxygenation activity of porcine pulmonary alveolar macrophages by *Actinobacillus pleuropneumoniae* and its metabolites. Am. J. Vet. Res. **53:**1113–1118.
5. **Dom, P., F. Haesebrouck, E. M. Kamp, and M. A. Smits.** 1992. Influence of *Actinobacillus pleuropneumoniae* serotype 2 and its cytolysins on porcine neutrophil chemiluminescence. Infect. Immun. **60:**4328–4334.
6. **Dom, P., F. Haesebrouck, E. M. Kamp, and M. A. Smits.** NAD-independent *Actinobacillus pleuropneumoniae* strains: production of RTX toxins and interactions with porcine phagocytes. Vet. Microbiol., in press.
7. **Dom, P., J. Hommez, F. Castryck, L. A. Devriese, and F. Haesebrouck.** 1994. Serotyping and quantitative determination of *in vitro* antibiotic susceptibility of *Actinobacillus pleuropneumoniae* strains isolated in Belgium (July 1991–August 1992). Vet. Q. **16:**10–13.
8. **Frey, J., J. T. Bosse, Y.-F. Chang, J. M. Cullen, B. Fenwick, G. F. Gerlach, D. Gygi, F. Haesebrouck, T. J. Inzana, R. Jansen, E. M. Kamp, J. Macdonald, J. I. MacInnes, K. R. Mittal, J. Nicolet, A. Rycroft, R. P. A. M. Segers, M. A. Smits, E. Stenbaek, D. K. Struck, J. F. van den Bosch, P. J. Willson, and R. Young.** 1993. *Actinobacillus pleuropneumoniae*-RTX-toxins: uniform designation of haemolysins, cytolysins, pleurotoxin and their genes. J. Gen. Microbiol. **139:**1723–1728.
9. **Hoepelman, A. I. M., and E. I. Tuomanen.** 1992. Consequences of microbial attachment: directing host cell functions with adhesins. Infect. Immun. **60:**1729–1733.
10. **Hultgren, S. J., S. Abraham, M. Caparon, P. Falk, J. W. St. Geme III, and S. Normark.** 1993. Pilus and non-pilus bacterial adhesins: assembly and function in cell recognition. Cell **73:**887–901.
11. **Jacques, M., M. Bélanger, G. Goy, and B. Foiry.** 1990. Adherence of *Actinobacillus pleuropneumoniae* to porcine tracheal epithelial cells and frozen lung sections. Vet. Microbiol. **27:**133–143.
12. **Jacques, M., G. Goy, and K. R. Mittal.** 1988. Hemagglutinating properties of *Actinobacillus pleuropneumoniae*. Can. J. Microbiol. **34:**1046–1049.
13. **Jann, K., and H. Hoschützky.** 1990. Nature and organization of adhesins. Curr. Top. Microbiol. Immunol. **151:**55–68.
14. **Jansen, R., J. Briaire, E. M. Kamp, and M. A. Smits.** 1992. Comparison of the cytolysin II genetic determinants of *Actinobacillus pleuropneumoniae* serotypes. Infect. Immun. **60:**630–636.
15. **Kamp, E. M., J. K. Popma, J. Anakotta, and M. A. Smits.** 1991. Identification of hemolytic and cytotoxic proteins of *Actinobacillus pleuropneumoniae* by use of monoclonal antibodies. Infect. Immun. **59:**3079–3085.
16. **Kume, K., T. Nakai, and A. Sawata.** 1984. Isolation of *Haemophilus pleuropneumoniae* from the nasal cavities of healthy pigs. Jpn. J. Vet. Sci. **46:**641–647.
17. **Lagergard, T., M. Purvén, and A. Frisk.** 1993. Evidence of *Haemophilus ducreyi* adherence to and cytotoxin destruction of human epithelial cells. Microb. Pathog. **14:**417–431.
18. **Liggett, A. D., L. R. Harrison, and R. L. Farrell.** 1987. Sequential study of lesion development in experimental haemophilus pleuropneumonia. Res. Vet. Sci. **42:**204–212.
19. **Nicolet, J.** 1992. *Actinobacillus pleuropneumoniae*, p. 401–408. *In* A. D. Leman, B. Straw, W. L. Mengeling, S. D'Allaire, and D. J. Taylor (ed.), Diseases of swine. Iowa State University Press, Ames.
20. **Serebrin, S., S. Rosendal, A. Valdivieso-Garcia, and P. B. Little.** 1991. Endothelial cytotoxicity of *Actinobacillus pleuropneumoniae*. Res. Vet. Sci. **50:**18–22.
21. **Utrera, V., and C. Pijoan.** 1991. Fimbriae in *Actinobacillus pleuropneumoniae* strains isolated from pig respiratory tracts. Vet. Rec. **128:**357–358.
22. **van Leengoed, L. A., E. M. Kamp, and J. M. A. Pol.** 1989. Toxicity of *Haemophilus pleuropneumoniae* to porcine lung macrophages. Vet. Microbiol. **19:**337–349.
23. **Wilson, P. J., G. Falk, and S. Klashinsky.** 1987. Detection of *Actinobacillus pleuropneumoniae* infection in pigs. Can. Vet. J. **28:**111–116.