American Journal of Pathology, Vol. 148, No. 5, May 1996
Copyright © American Society for Investigative Pathology

Clinical and Pathological Significance of Microsatellite Instability in Sporadic Endometrial Carcinoma

Rosmarie F. Caduff,* Carolyn M. Johnston,† Suzette M. Svoboda-Newman,* Ellen L. Poy,* Sofia D. Merajver,‡ and Thomas S. Frank*

From the Departments of Pathology, Obstetrics and Gynecology,† and Internal Medicine,‡ University of Michigan Hospitals, Ann Arbor, Michigan*

Defective DNA mismatch repair in neoplasia is manifested by extra, aberrant bands within multiple microsatellite markers. The replication error (RER) phenotype is present in most colorectal and endometrial carcinomas in patients with the hereditary nonpolyposis colorectal carcinoma syndrome. In addition, a minority of sporadic colorectal and endometrial carcinomas are RER positive. RER in sporadic colorectal carcinomas has been associated with improved prognosis, but its clinical significance in sporadic endometrial cancer has not been characterized. We analyzed DNA extracted from 109 formalin-fixed sporadic endometrial carcinomas for microsatellite instability. The RER-positive phenotype was demonstrated by microsatellite instability in more than one of the eight dinucleotide markers tested. RER was correlated with pathological and clinical parameters as well as with immunohistochemical staining for the p53 gene product and alterations in codon 12 of Ki-*ras*. Nine percent of the endometrial carcinomas were RER positive, and RER was significantly associated with high grade and adverse outcome. We found no significant correlation of RER with histological subtype, stage, depth of invasion, mutations in the 12th codon of Ki-*ras*, or p53 immunoreactivity. We conclude that the RER phenotype is present in a minority of sporadic endometrial carcinomas and is associated with high grade and poor prognosis. (Am J Pathol 1996, 148:1671–1678)

The observation in neoplasia of somatic alterations located in simple tandem repeated sequences led to the postulation of a mutator mutation in genes coding for replication or repair factors.[1] Subsequent studies have identified these mismatch repair genes as homologues of the bacterial *mutHLS* complex.[2–6] The decrease in replication fidelity resulting from such mutations leads to accumulation of replication errors (RERs), which can be observed as electrophoretic mobility shifts in microsatellite markers. This phenomenon, termed microsatellite instability, was first described in colorectal carcinoma,[1,7,8] and germline mutations of mismatch repair genes have been implicated in the pathogenesis of hereditary nonpolyposis colorectal cancer (HNPCC).[5,6,9–12] RER has been identified in other carcinomas arising in patients with HNPCC, including endometrial carcinoma,[13] which is the most common extracolonic malignancy in these patients.[14]

Microsatellite instability has also been identified in 13 to 17% of sporadic colorectal carcinomas.[8,15] These tumors appear to represent a clinical and pathological subset of sporadic colorectal cancers that are characterized by high tumor grade,[1,7,15] improved prognosis,[7,8] and low incidence of alterations of Ki-*ras*[1] and p53.[15] RER has recently been reported in other sporadic neoplasms of the types associated with HNPCC,[16] including carcinoma of the stomach[16,17] and endometrium.[13,16,18,19] Endometrial carcinomas generally exhibit many of the same genotypic characteristics as RER-positive colorectal carcinomas such as a low incidence of p53 and Ki-*ras* gene mutations.[20–22] The clinical and biological significance of RER in endometrial carcinoma has not yet been characterized. It is of partic-

Supported in part by grants to T. S. Frank from the Harris Foundation and to R. F. Caduff from the Union Bank of Switzerland made possible by an anonymous donor.

Accepted for publication January 15, 1996.

Address reprint requests to Dr. Thomas S. Frank, Department of Pathology, 2G332–0054 University Hospital, 1500 East Medical Center Drive, Ann Arbor, MI 48109-0054.

ular interest whether the relationship between RER and both high tumor grade and improved prognosis observed for colorectal carcinomas might also exist for carcinomas of the endometrium, as tumor grade is of more ominous prognostic significance for carcinomas of the endometrium than those of the colon. The purpose of this study therefore was to analyze the prevalence of RER in sporadic endometrial carcinoma and its relationship to genotypic (Ki-*ras* mutations and p53 gene product overexpression), phenotypic (tumor grade and stage), and clinical (age of onset and prognosis) characteristics.

Materials and Methods

Patient Selection

We analyzed 109 endometrial carcinomas from patients with no known history of HNPCC. (Two additional cases were analyzed for several markers but subsequently excluded when insufficient paraffin-embedded material was available for completion of the analysis.) Hematoxylin and eosin (H&E)-stained slides from each case had been reviewed previously for determination of depth of invasion, grade, and tumor cell type in conjunction with an earlier study.[21] Using the criteria of the International Society of Gynecological Pathologists, the tumors were categorized by cell type into 86 typical glandular endometrioid adenocarcinomas and 23 non-endometrioid carcinomas, termed type I and type II, respectively.[23] The type I tumors included 52 grade 1, 17 grade 2, and 17 grade 3 endometrioid carcinomas using the grading criteria of the International Federation of Obstetrics and Gynecology (FIGO),[24] in which low grade denotes a predominance of gland formation and high grade its relative absence. The type II malignancies included 16 papillary serous-clear cell carcinomas (8 pure papillary serous carcinomas, 6 pure clear cell carcinomas, and 2 with mixed features of both), 4 undifferentiated carcinomas, and 3 carcinosarcomas, which were were not separated by grade as tumors of this type are all considered to be high grade. Stage was assigned by surgical and pathological findings according to FIGO criteria[24] in which the presence of metastases at diagnosis would render a neoplasm at least stage 3, and clinical outcome was evaluated for each patient from whom it was available at least 12 months after surgery.

DNA Extraction

Based on review of H&E-stained slides, two paraffin tissue blocks were selected from each case, one each of neoplastic endometrial and non-neoplastic non-endometrial tissue (usually uninvolved lymph nodes and occasionally uninvolved ovarian or cervical tissue). Tissue sections of 4 μm thickness were cut from each block and placed on plain glass slides. As described previously,[25,26] non-neoplastic tissue was selectively removed from unstained sections of carcinoma under a dissecting microscope using a serial H&E-stained section as a template guide. One tissue section from each case was transferred with a disposable razor blade to 100 μl of xylene in a 1.7-ml nonsiliconized microcentrifuge tube. An equal volume of 100% ethanol was added and the samples were pelleted (10 minutes in a countertop microcentrifuge), dried under vacuum, and digested overnight in 100 μl of 50 mmol/L Tris, pH 8.3, with 200 ng/μl proteinase K at 37°C. Samples were then boiled for 8 minutes, cooled on ice, and spun 5 minutes to pellet out debris. DNA extraction was performed in batches of 10 to 14 samples in which each batch included a reagent-only negative control.

Polymerase Chain Reaction (PCR) Analysis

Primers were designed to analyze eight highly informative dinucleotide microsatellite repeat sequences on chromosomes 2p, 3p, 5q, 10p, 11p, 13, 17q, and 18q. PCR was performed with an initial denaturation step of 4 minutes at 94°C coupled to 35 cycles of 1 minute at 94°C, 2 minutes at a primer-specific annealing temperature (Table 1), and 2 minutes at 72°C, followed by a 7-minute completion step at 72°C. A 10-μl volume of PCR product was loaded with 10 μl of 1X Tris-borate/EDTA buffer and 3 μl of loading dye onto 8% neutral polyacrylamide gels and electrophoresed from 2.5 to 5 hours (depending on the expected size of the product). The gels were stained for 15 minutes in 0.5 μg/ml ethidium bromide and photographed with a Polaroid camera using an ultraviolet light source. For verification of the RER-positive phenotype, analyses were repeated using newly extracted DNA for at least two of the markers demonstrating instability.

Immunohistochemical Detection of p53 Gene Product

Most mutations in p53 are missense mutations that prolong the half-life of the gene product. Therefore,

Table 1. *Microsatellite Loci Used for Identification of RER in Endometrial Carcinomas*

Locus	Location	Primer sequence	T_A (°C)	Size (approximate) in bp
D2S123	2p	5′-GATGCCTGCCTTTAACAGTG-3′ 5′-GAATTGGAGGGGACTTTCCA-3′	54	230
HUMCA1126	3p	5′-ATTCCCTGCATATGATCCCA-3′ 5′-ACCTAAGAGCAATCACTTAAC-3′	52	125
D5S107	5q	5′-GATCCACTTTAACCCAAATAC-3′ 5′-GGCATCAACTTGAACAGCAT-3′	52	145
D10S197	10p	5′-CGCACCACTGCACTTCAG-3′ 5′-TGGCATGTGAGGTGCCTTA-3′	52	260
D11S904	11p	5′-GCAGGGCTCACACTATGAC-3′ 5′-TGTGTTATATCCCTAAAGGGT-3′	53	210
D13S175	13	5′-CCTAATGTACAGTATGGTGG-3′ 5′-CTATGCATCACCTCACATAG-3′	52	145
D17S1323	17q	5′-TAGGAGATGGATTATTGGTG-3′ 5′-AAGCAACTTTGCAATGAGTG-3′	55	155
D18S34	18q	5′-CAGAAAATTCTCTCTGGCTA-3′ 5′-CTCATGTTCCTGGCAAGAAAT-3′	51	115

immunoreactivity for the p53 gene product serves as a marker for the majority of p53 gene mutations.[27,28] Antibody PAb1801 (Oncogene Science, Uniondale, NY) is a murine monoclonal antibody specific for a denaturation-resistant epitope between amino acids 32 and 79 of the human p53 protein[29] and has been demonstrated to correlate well with p53 mutation and gene product accumulation in paraffin-embedded tissues.[28,30] Using the same block of neoplasm selected for PCR analysis, tissue sections of 4 μm thickness were pretreated with microwaving in 10 mmol/L citrate buffer and incubated overnight at room temperature with the primary antibody at a 1:1000 dilution as previously described.[25] After 1 hour of incubation with a 1:200 dilution of biotinylated anti-mouse IgG (Vector mouse ABC kit, Burlingame, CA), the tissues were incubated for 30 minutes at room temperature with 1 μg/ml streptavidin-alkaline phosphatase (BRL Life Technologies, Bethesda, MD). The samples were then incubated in the dark for 1 hour with nitroblue tetrazolium and 5-bromo-4-chloro-3-indolyl phosphate substrate (BRL) for chromogen development.

*Analysis of Ki-*ras *Codon 12 Mutations*

RER was correlated with mutations of codon 12 of Ki-*ras* that have been previously reported in this group of neoplasms.[21] Mutations were initially identified using PCR primers that generated a *BstNI* recognition site with the wild-type codon 12 and subsequently confirmed by DNA sequence determination.

Statistical Analysis

RER in sporadic endometrial carcinomas was analyzed for significant association with histological subtype, grade, stage, age at diagnosis, and patient outcome with Fisher's exact test, using Statview version 4.01 (Abacus Concepts, Berkeley, CA). In addition, the presence of RER was correlated with previously characterized alterations in codon 12 of Ki-*ras*[21] as well as with immunoreactivity for p53.

Results

Microsatellite Instability and RER in Endometrial Carcinoma

Successful PCR amplification of eight microsatellite markers was obtained for 109 tumor and normal samples. Microsatellite instability generally consisted of additions and deletions of greater than 2 bp. Instability was present in at least one of the eight tested loci in 27 of 109 (25%) endometrial carcinomas, and 10 tumors (9%) demonstrating microsatellite instability in two or more loci (repeated for confirmation as described above) were considered to be RER positive. Examples of RER-positive and RER-negative tumors are illustrated in Figure 1.

Histological Features of RER-Positive Endometrial Carcinomas

Of the 10 RER-positive carcinomas, 9 were of the typical endometrioid subtype (type I). The 10th RER-positive tumor had mixed papillary serous and clear cell components and was therefore considered an example of a type II endometrial carcinoma, which are generally not associated with unopposed estrogen and are typified clinically by aggressive behavior. Overall, 9 of 86 (10%) endometrioid carcinomas analyzed were RER positive compared with 1 of 23

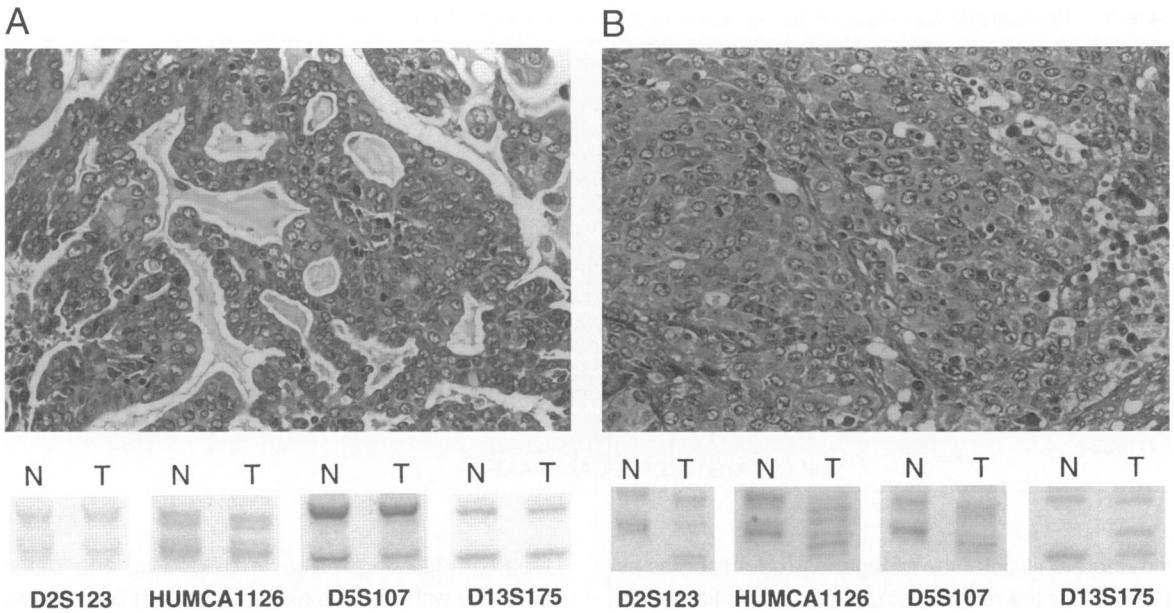

Figure 1. *Correlation of RER with endometrial tumor grade.* A: *A grade 1 tumor is characterized by a predominance of gland formation* (top). *There is no difference in the electrophoretic mobility of microsatellite markers amplified from DNA extracted from normal (N) compared with tumor (T) tissues from the same patient* (bottom). B: *A grade 3 tumor (sample 6) is characterized by solid growth* (top) *and is RER positive as demonstrated by microsatellite instability in multiple markers* (bottom). *All tumor/normal pairs were electrophoresed together and photographed simultaneously (photographs inverted black-to-white for illustration).*

(4%) non-endometrioid (type II) carcinomas, but this difference was not statistically significant.

Among the endometrioid carcinomas, RER positivity correlated with histological grade. Using the grading criteria of FIGO, 6 of 17 (35%) grade 3 tumors were RER positive in contrast to 3 of 69 (4%) tumors of grade 1 or 2 ($P = 0.0015$). Of the 10 RER-positive patients, 4 presented as stage 1, 3 as stage 2, 2 as stage 3, and 1 as stage 4. There was no significant difference in presenting stage between RER-positive and RER-negative patients, nor was there a difference found correlating with depth of myometrial invasion.

Clinical Aspects of Patients with RER-Positive Endometrial Carcinomas

Patient ages ranged from 31 to 87 years and 47 to 83 years for patients with RER-negative and RER-positive tumors, respectively. The mean age of both groups was 63 years. None of the patients with RER-positive tumors had a history of colorectal carcinoma.

The clinical outcome of 98 patients was known, including that of all of the patients with RER-positive tumors. Overall, 28 patients (28.5%) died of disease from 1 to 66 months after diagnosis, and 6 of 10 (60%) patients with RER-positive tumors and 22 of 88 (25%) patients with RER-negative tumors died of disease. When patients with the type I carcinomas were analyzed separately, 6 of 9 patients (67%) with RER-positive endometrioid tumors died of disease compared with 7 of 68 patients (10%) whose endometrioid tumors were RER negative ($P = 0.0005$). All of the lethal RER-positive type I tumors were FIGO grade 2 or 3. The prognostic significance of RER could not be separated from that of grade, an established adverse indicator in endometrial carcinoma. The clinical and histological characteristics of the RER-positive endometrial carcinomas are summarized in Table 2.

Comparison of RER-Positive and RER-Negative Endometrial Carcinomas

Because RER is inversely correlated with Ki-*ras* mutations and p53 gene product immunoreactivity in sporadic colorectal carcinomas, we evaluated the relationship between these variables in our group of endometrial carcinomas. Mutations in Ki-*ras* codon 12 were present in 2 of 10 (20%) RER-positive tumors compared with 11 of 99 (11%) RER-negative tumors, a difference that was not statistically significant (Fisher's exact test). Similarly, the proportion of nuclear immunoreactivity for the p53 gene product was the same in both groups: 2 of 10 (20%) RER-positive and 18 of 96 (22%) RER-negative tumors demonstrated diffuse nuclear staining.

Table 2. *Summary of RER-Positive Endometrial Carcinomas*

Sample	Histological subtype	Grade*	Depth of myometrial invasion	Stage†	Ki-*ras* codon 12	p53 immunoreactivity	Status‡
6	Endometrioid	3	Outer third	3	Wild-type	–	DOD
15	Endometrioid	3	Outer third	1	Mutated (GAT)	–	NED
17	Endometrioid	1	Inner third	1	Wild-type	–	NED
31	Endometrioid	3	Middle third	1	Wild-type	+	NED
35	Endometrioid	3	Outer third	3	Wild-type	–	DOD
73	Endometrioid	2	Inner third	1	Mutated (TGT)	–	DOD
90	Endometrioid	3	Outer third	2	Wild-type	–	DOD
98	Endometrioid	2	Inner third	2	Wild-type	–	DOD
103	Endometrioid	3	Outer third	4	Wild-type	–	DOD
112	Mixed clear cell-papillary serous	NA	Inner third	2	Wild-type	+	NED

*Using FIGO criteria. NA, not applicable for these histological subtypes.
†Surgical stage (FIGO criteria).
‡Patient outcome: AWD, alive with disease; NED, no evidence of disease; DOD, dead of disease.

Discussion

The molecular events that occur during the development of endometrial carcinoma are largely uncharacterized but appear to be different than those responsible for most sporadic colorectal carcinomas. For example, mutations in codon 12 of Ki-*ras* are present in only 12% of endometrial carcinomas[21] in contrast to approximately 40% of carcinomas of the colon.[31] Similarly, whereas overexpression of the p53 gene product is reported in 50% of carcinomas of the colon,[30,32] we observed this in only 18% of endometrial carcinomas. The pattern of alterations present in sporadic endometrial carcinoma does, however, resemble that of a distinctive subset of colorectal cancers that are RER positive and have a low incidence of Ki-*ras* and p53 gene mutations.[1,15] In addition, RER-positive endometrial carcinoma is common in patients with HNPCC,[13] implying that defects in mismatch repair might be important in the development of sporadic endometrial cancers as well. We identified the RER phenotype in only 9% of sporadic endometrial carcinomas, however, which is a somewhat lower prevalence of RER in these tumors than the 11 to 23% reported in smaller series.[13,16,18,19]

Differences between reports of RER in endometrial carcinoma may result in part from the diversity of methods used to identify microsatellite instability. Among studies there is little uniformity in the number of microsatellites analyzed or in the specific loci chosen, and as the frequency and degree of instability vary from one microsatellite marker to another,[33] such differences may affect results. In addition, it is difficult to consistently interpret minor alterations as single 2-bp type II[34] allelic shifts. Our use of nonisotopic methods in particular had the potential to make such minor shifts difficult to discern. To assess this possibility, we analyzed the sensitivity of nonisotopic methods to detect instability in a small number of breast cancers that had been previously characterized with radiolabeled primers for D13S221, D13S123, and D13S289. We found complete concordance except for a single example of microsatellite instability in the largest microsatellite marker (260 bp) that was not evident without isotopic labeling. This likely reflects the limited ability of nonisotopic PCR to analyze products of increasing length,[35] but as all but one of the markers used for this study were smaller than 250 bp, we do not believe that our use of nonradiolabeled primers in this study led to a significant underestimate of instability. Other authors have also demonstrated that nonisotopic techniques are suitable to identify minor electrophoretic alterations in dinucleotide repeat markers.[36]

An association of the RER phenotype with high grade has been previously reported in carcinoma of the colon[1,15] but not endometrium. Burks et al[19] identified RER in 2 of 5 (40%) grade 3 endometrioid carcinomas and 5 of 16 (31%) grade 1 and 2 tumors, and Duggan et al[18] identified the RER phenotype in 2 of 10 (20%) grade 3 tumors and 6 of 26 (23%) grade 1 and 2 tumors. In a third study, 3 of 6 RER-positive sporadic endometrial carcinomas were grade 3, but the grade of the 30 RER-negative cases in that study was not stated.[13] In contrast, we did identify an association of RER with grade, as 35% of the grade 3 tumors we studied were RER positive in contrast to only 4% of grade 1 or 2 tumors.

In addition to its association with high grade, RER also strongly correlated with poor clinical outcome, reflecting the importance of grade as a negative prognostic indicator in endometrial carcinoma. In colorectal carcinoma, however, the RER phenotype

has been associated with both high tumor grade and favorable prognosis,[7,8] as well as the absence of metastases at diagnosis.[1] This discrepancy between aggressive histology and improved prognosis in the colon has been postulated to result from peritumoral inflammatory infiltrates representing the host response in RER-positive colorectal carcinomas.[15] Alternatively, it has been speculated that the accumulation of mutations in the RER-positive tumor cells may be detrimental to the neoplastic clone.[37] Our results suggest that, in endometrial carcinomas at least, this is not the case. We also found that RER in endometrial carcinoma is not associated with an early age of onset, in contrast to sporadic colorectal carcinoma. The distinctive clinical characteristics of RER-positive colorectal carcinomas are thus absent from their endometrial counterparts.

Although Shibata et al[18] reported that mutant Ki-*ras* alleles were more frequent in RER-positive than RER-negative endometrial carcinomas, we did not confirm this association. We analyzed p53 gene product overexpression by immunohistochemistry, which serves as a marker of p53 gene mutation in paraffin-embedded tissue.[27,28] We did not find a trend toward less frequent staining in RER-positive tumors that has been reported among colorectal carcinomas. We did, however, identify a strong association of p53 gene product immunoreactivity with histological type, as diffuse nuclear staining was present in 6 of 8 papillary serous (75%) carcinomas compared with 4 of 86 endometrioid (4%) carcinomas ($P < 0.0001$). Interestingly, we did not observe the RER phenotype in any of 8 pure papillary serous carcinomas (although 1 neoplasm with mixed papillary serous and clear cell features was RER positive). Two previous studies of endometrial carcinomas also failed to identify RER positivity in any of 11 papillary serous carcinomas of the endometrium.[18,19] These findings suggest that this histological subtype, which has distinctive clinical features (advanced age and aggressive course), is genotypically distinctive as well.

Numerous lines of evidence suggest that defective DNA mismatch repair is a fundamental cause (rather than consequence) of malignant transformation.[38,39] Models in which the background mutation rate of normal cells is known can account for only two or three mutations in each tumor and not the much larger number of mutations that are generally present in transformed cells. For multiple mutations to occur in a malignant clone at a background mutation rate of 1.4×10^{-10} mutations/base pair/cell generation, virtually every mutation would have to result in a profound growth advantage.[39] In addition, the mutation rate of cell lines derived from RER-positive tumors is at least 100-fold that of RER-negative tumor cells.[38] The observation that microsatellite instability is homogeneously distributed throughout some carcinomas indicates that defective mismatch repair is an early event that occurs before tumor expansion,[18,37] a hypothesis that is further supported by reports of microsatellite instability in dysplastic tissue adjacent to gastric and colonic cancer.[40,41] In only one of our cases were we able to identify a residual area of atypical endometrial hyperplasia, which is a preneoplastic marker of endometrial epithelium. DNA was isolated and analyzed from this area and did not demonstrate microsatellite instability in any of the eight microsatellite markers. Analysis of additional examples of endometrial hyperplasia will hopefully provide more insight into the role of defective DNA mismatch repair in the development of endometrial carcinoma.

References

1. Ionov Y, Peinado MA, Malkhosyan S, Shibata D, Perucho M: Ubiquitous somatic mutations in simple repeated sequences reveal a new mechanism of colonic carcinogenesis. Nature 1993, 363:558–561
2. Fishel R, Lescoe MK, Rao MRS, Copeland NG, Jenkins NA, Garber J, Kane M, Kolodner R: The human mutator gene homolog MSH2 and its association with hereditary nonpolyposis colon cancer. Cell 1993, 75:1027–1038
3. Papadopoulos N, Nicolaides NC, Wei YF, Ruben SM, Carter KC, Rosen CA, Fleischmann RD, Fraser CM, Adams MD, Venter JC, Hamilton SR, Petersen GM, Watson P, Lynch HT, Peltomäki P, Mecklin JP, de la Chapelle A, Kinzler KW, Vogelstein B: Mutation of a mutL homolog in hereditary colon cancer. Science 1994, 263:1625–1629
4. Bronner CE, Baker SM, Morrison PT, Warren G, Smith LG, Lescoe MK, Earabino C, Lipford J, Lindblom A, Tannergard P, Bollag RJ, Godwin AR, Ward DC, Nordenskjöld M, Fishel R, Kolodner R, Liskay RM: Mutation in the DNA mismatch repair gene homologue hMLH1 is associated with hereditary non-polyposis colon cancer. Nature 1994, 368:258–261
5. Leach FS, Nicolaides NC, Papadopoulos N, Liu B, Jen J, Parsons R, Peltomäki P, Sistonen P, Aaltonen LA, Nyström-Lahti M, Guan X-Y, Zhang J, Meltzer PS, Yu J-W, Kao F-T, Chen DJ, Cerosaletti KM, Fournier REK, Todd S, Lewis T, Leach RJ, Naylor SL, Weissenbach J, Mecklin J-P, Järvinen H, Petersen GM, Hamilton SR, Green J, Jass J, Watson P, Lynch HT, Trent JM, de la Chapelle A, Kinzler KW, Vogelstein B: Mutations of a mutS homolog in hereditary nonpolyposis colorectal cancer. Cell 1993, 75:1215–1225
6. Nicolaides NC, Papadopoulos N, Liu B, Wei YF, Carter

KC, Ruben SM, Haseltine WA, Fleischmann RD, Fraser CM, Adams MD, Venter JC, Dunlop MG, Hamilton SR, Petersen GM, de la Chapelle A, Vogelstein B, Kinzler KW: Mutations of two PMS homologues in hereditary nonpolyposis colon cancer. Nature 1994, 371:75–80

7. Lothe RA, Peltomäki P, Meling GI, Aaltonen LA, Nyström-Lahti M, Heimdal K, Andersen TI, Moller P, Rognum TO, Fossa SD, Haldorsen T, Langmark F, Brögger A, de la Chapelle A, Börresen A: Genomic instability in colorectal cancer: relationship to clinicopathological variables and family history. Cancer Res 1993, 53:5849–5852
8. Thibodeau SN, Bren G, Schaid G: Microsatellite instability in cancer of the proximal colon. Science 1993, 260:816–819
9. Aaltonen LA, Peltomäki P, Leach FS, Sistonen P, Pylkkänen L, Mecklin J-P, Järvinen H, Powell SM, Jen J, Hamilton SR, Petersen GM, Kinzler KW, Vogelstein B, de la Chapelle A: Clues to the pathogenesis of familial colorectal cancer. Science 1993, 260:812–816
10. Peltomäki P, Aaltonen LA, Sistonen P, Pylkkänen L, Mecklin J-P, Järvinen H, Green JS, Jass JR, Weber JL, Leach FS, Petersen GM, Hamilton SR, de la Chapelle A, Vogelstein B: Genetic mapping of a locus predisposing to human colorectal cancer. Science 1993, 260: 810–812
11. Lindblom A, Tannergård P, Werelius B, Nordenskjöld M: Genetic mapping of a second locus predisposing to hereditary non-polyposis colon cancer. Nat Genet 1993, 5:279–282
12. Liu B, Parsons RE, Hamilton SR, Petersen GM, Lynch HT, Watson P, Markowitz S, Willson JKV, Green J, de la Chapelle A, Kinzler KW, Vogelstein B: hMSH2 mutations in hereditary nonpolyposis colorectal cancer kindreds. Cancer Res 1994, 54:4590–4594
13. Risinger JI, Berchuck A, Kohler MF, Watson P, Lynch HT, Boyd J: Genetic instability of microsatellites in endometrial carcinoma. Cancer Res 1993, 53:5100–5103
14. Lynch HT, Kimberling W, Albano WA, Lynch JF, Biscone K, Schuelke GS, Sandberg AA, Lipkin M, Deschner EE, Mikol YB, Elston RC, Bailey-Wilson JE, Danes BS: Hereditary nonpolyposis colorectal cancer (Lynch syndromes I and II). I. Clinical description of resource. Cancer 1985, 56:934–938
15. Kim H, Jen J, Vogelstein B, Hamilton SR: Clinical and pathological characteristics of sporadic colorectal carcinomas with DNA replication errors in microsatellite sequences. Am J Pathol 1994, 145:148–156
16. Peltomäki P, Lothe RA, Aaltonen LA, Pylkkänen L, Nyström-Lahti M, Seruca R, David L, Holm R, Ryberg D, Haugen A, Brögger A, Börresen A, de la Chapelle A: Microsatellite instability is associated with tumors that characterize the hereditary non-polyposis colorectal carcinoma syndrome. Cancer Res 1994, 53:5853–5855
17. Han HJ, Yanagisawa A, Kato Y, Park JG, Nakamura Y: Genetic instability in pancreatic cancer and poorly differentiated type of gastric cancer. Cancer Res 1993, 53:5087–5089
18. Duggan BD, Felix JC, Muderspach LI, Tourgeman D, Zheng J, Shibata D: Microsatellite instability in sporadic endometrial carcinoma. J Natl Cancer Inst 1994, 86:1216–1221
19. Burks RT, Kessis TD, Cho KR, Hedrick L: Microsatellite instability in endometrial carcinoma. Oncogene 1994, 9:1163–1166
20. Risinger JI, Dent GA, Ignar Trowbridge D, McLachlan JA, Tsao MS, Senterman M, Boyd J: p53 gene mutations in human endometrial carcinoma. Mol Carcinogen 1992, 5:250–253
21. Caduff RF, Johnston CM, Frank TS: Mutations of the Ki-*ras* oncogene in carcinoma of the endometrium. Am J Pathol 1995, 146:182–188
22. Massenkeil G, Caduff R, Oberhuber H, Schwarte-Waldhoff I, Diener PA, Bannwart F, Walt H, Schäfer R: Loss of heterozygosity on chromosome 16q, expression of HER2/neu and p53 mutations in endometrial cancer. Int J Oncol 1995, 6:157–162
23. Kurman RJ, Zaino RJ, Norris HJ: Endometrial carcinoma. Blaustein's Pathology of the Female Genital Tract. Edited by RJ Kurman. New York, Springer-Verlag, 1994:441
24. FIGO stages: 1988 revision. Gynecol Oncol 1989, 35: 125–127
25. Frank TS, Bartos RE, Haefner HK, Roberts JK, Wilson MD, Hubbell GP: Loss of heterozygosity and overexpression of the p53 gene in ovarian carcinoma. Mod Pathol 1994, 7:3–8
26. Goldblum JR, Bartos RE, Carr KA, Frank TS: Hepatitis B and alterations of the p53 tumor suppressor gene in hepatocellular carcinoma. Am J Surg Pathol 1993, 17: 1244–1251
27. Finlay CA, Hinds PW, Tan T-H, Eliyahu D, Oren M, Levine AJ: Activating mutations for transformation by p53 produce a gene product that forms an hsc70-p53 complex with an altered half-life. Mol Cell Biol 1988, 8:531–539
28. Kerns BJ, Jordan PA, Moore MH, Humphrey PA, Berchuck A, Kohler MF, Bast RC, Iglehart JD, Marks JR: p53 overexpression in formalin-fixed, paraffin-embedded tissue detected by immunohistochemistry. J Histochem Cytochem 1992, 40:1047–1051
29. Banks L, Matlashewski G, Crawford L: Isolation of human p53-specific monoclonal antibodies and their use in the studies of human p53 expression. Eur J Biochem 1986, 159:529–534
30. Cunningham J, Lust JA, Schaid DJ, Bren GD, Carpenter HA, Rizza E, Kovach JS, Thibodeau SN: Expression of p53 and 17p allelic loss in colorectal carcinoma. Cancer Res 1992, 1980, 52:1974
31. Forrester K, Almoguera C, Han K, Grizzle W, Perucho M: Detection of high incidence of K-*ras* oncogenes during human colorectal tumorigenesis. Nature 1987, 327:298–303
32. Rodrigues NR, Rowan A, Smith MEF, Kerr IB, Bodmer

WF, Gannon JV, Lane DP: p53 mutations in colorectal cancer. Proc Natl Acad Sci USA 1990, 87:7555–7559
33. Honchel R, Halling KC, Thibodeau SN: Genomic instability in neoplasia. Semin Cell Biol 1995, 6:45–52
34. Harlow SP, Stewart CC: Quantitation of c-*myc* gene amplification by a competitive PCR assay system. PCR Methods Appl 1993, 3:163–168
35. Frank TS, Svoboda-Newman SM, Hsi ED: Comparison of methods for extracting DNA from formalin fixed paraffin sections for non-isotopic PCR. Diagn Mol Pathol 1996, 5 (in press)
36. Wu C, Akiyama Y, Imai K, Miyake S, Nagasaki H, Oto M, Okabe S, Iwama T, Mitamura K, Masumitsu H, Nomizu T, Baba S, Maruyama K, Yuasa Y: DNA alterations in cells from hereditary non-polyposis colorectal cancer patients. Oncogene 1994, 9:991–994
37. Shibata D, Peinado MA, Ionov Y, Malkhosyan S, Perucho M: Genomic instability in repeated sequences is an early somatic event in colorectal tumorigenesis that persists after transformation. Nat Genet 1994, 6:273–281
38. Parsons R, Li GM, Longley MJ, Fang WH, Papadopoulos N, Jen J, de la Chapelle A, Kinzler KW, Vogelstein B, Modrich P: Hypermutability and mismatch repair deficiency in RER^+ tumor cells. Cell 1993, 75:1227–1236
39. Loeb LA: Microsatellite instability: marker of a mutator phenotype in cancer. Cancer Res 1994, 54:5059–5063
40. Rhyu M-G, Park W-S, Meltzer SJ: Microsatellite instability occurs frequently in human gastric carcinoma. Oncogene 1994, 9:29–32
41. Suzuki H, Harpaz N, Tarmin L, Yin J, Jiang HY, Bell JD, Hontanosas M, Abraham JM, Meltzer SJ: Microsatellite instability in ulcerative colitis-associated colorectal dysplasias and cancers. Cancer Res 1994, 54:4841–4844