likely to be institutionalised and are often admitted to hospital, factors contributing to a lower likelihood of being identified in our study.

In the absence of previous specific reports on these stages the high prevalence of asymptomatic cardiac abnormalities and of patients at high risk for HF was surprising.

There are therapeutic options with documented benefit in delaying or even preventing progression to symptomatic HF. Yusuf and Pitt[5] called attention to the relatively modest research aimed at preventing HF in high risk patients in comparison with the extensive efforts aimed at discovering new treatments for patients after HF develops. The results of our study are useful in this regard. They may be helpful in quantifying the magnitude of the HF problem in the population by dissecting stages and their progression by age.

ACKNOWLEDGEMENTS

This study was supported by a grant from Fundação para a Ciência e a Tecnologia of the Portuguese Ministério da Ciência e Tecnologia (POCTI 35769/99).

Authors' affiliations

A Azevedo*, H Barros, Department of Hygiene and Epidemiology, University of Porto Medical School, Porto, Portugal
P Bettencourt, Heart Failure Clinic, Department of Medicine B, Hospital S João, Porto, Portugal
P Dias, C Abreu-Lima, Department of Cardiology, Hospital S João and University of Porto Medical School, Porto, Portugal
H-W Hense, Institute of Epidemiology and Social Medicine, University of Muenster, Muenster, Germany

Competing interests: none declared

*Also the Heart Failure Clinic, Department of Medicine B, Hospital S João, Porto, Portugal

Institution where work was performed: University of Porto Medical School, Porto, Portugal

Correspondence to: Dr Ana Azevedo, Department of Hygiene and Epidemiology, University of Porto Medical School, Alameda Prof Hernani Monteiro, 4200–319 Porto, Portugal; anazev@med.up.pt

Accepted 7 November 2005

REFERENCES

1 **Hunt SA**, Baker DW, Chin MH, *et al*. ACC/AHA guidelines for the evaluation and management of chronic heart failure in the adult: executive summary: a report of the American College of Cardiology/American Heart Association task force on practice guidelines (committee to revise the 1995 guidelines for the evaluation and management of heart failure) developed in collaboration with the International Society for Heart and Lung Transplantation endorsed by the Heart Failure Society of America. *J Am Coll Cardiol* 2001;**38**:2101–13.
2 **Ramos E**, Lopes C, Barros H. Investigating the effect of nonparticipation using a population-based case-control study on myocardial infarction. *Ann Epidemiol* 2004;**14**:437–41.
3 **Kuch B**, Schunkert H, Muscholl M, *et al*. [Distribution, determinants and reference values of left ventricular parameters in the general population: results of the MONICA/KORA echocardiography studies]. *Gesundheitswesen*. 2005;67: S68–73, (In German.), (suppl 1).
4 **Mosterd A**, Hoes AW, de Bruyne MC, *et al*. Prevalence of heart failure and left ventricular dysfunction in the general population: the Rotterdam study. *Eur Heart J* 1999;**20**:447–55.
5 **Yusuf S**, Pitt B. A lifetime of prevention: the case of heart failure. *Circulation* 2002;**106**:2997–8.

IMAGES IN CARDIOLOGY

doi: 10.1136/hrt.2005.080424

A rare and potentially lethal coronary artery anomaly

A 42-year-old man was admitted with central chest pain which he described as "someone sitting on his chest". He had a strong family history of premature coronary artery disease and raised cholesterol. He completed over nine minutes of a treadmill stress test, complaining of chest tightness and breathlessness after seven minutes but with no ECG changes.

Coronary angiography demonstrated an anomalous origin of the left main coronary artery (LMCA) arising from the right sinus of Valsalva (panels A and B, arrow) and only mild coronary atheroma. Congenital coronary artery anomalies of this type are relatively rare. However, they can be associated with episodic ischaemia, myocardial infarction and more importantly, with sudden cardiac death particularly among young athletes, depending on the anatomical relationship with the great vessels. The potentially lethal type of this anomaly occurs when the LMCA runs an interarterial course between the aorta and pulmonary trunk and requires prompt correction. This man has a more benign variant where the LMCA runs an intramuscular course before branching into the left anterior descending artery (LAD) and circumflex artery (Cx) in the mid portion of the interventricular septum (panel C).

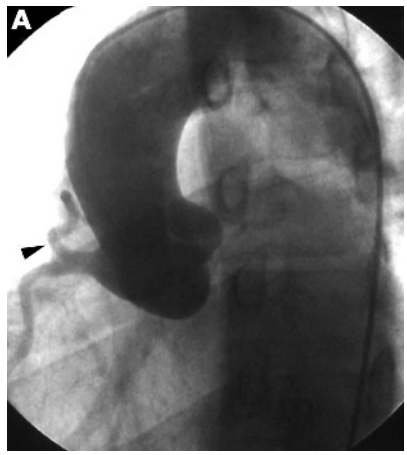

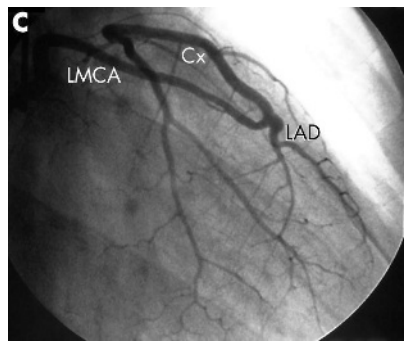

J P Winter, C J P Welsh
jpwinter@doctors.org.uk