INTERVENTIONAL CARDIOLOGY AND SURGERY

Evaluation of restenosis and extent of coronary artery disease in patients with previous percutaneous coronary interventions by dobutamine stress real-time myocardial contrast perfusion imaging

A Elhendy, J M Tsutsui, E L O'Leary, F Xie, F Majeed, T R Porter

Heart 2006;**92**:1480–1483. doi: 10.1136/hrt.2005.086140

See end of article for authors' affiliations

Correspondence to: Dr Abdou Elhendy, 982265 Nebraska Medical Center, Omaha, NE 68198–2265, USA; Aelhendy@unmc.edu

Accepted 15 March 2006
Published Online First 10 April 2006

Objectives: To assess the accuracy of real-time myocardial contrast perfusion imaging (MCPI) for the diagnosis of restenosis and extent of coronary artery disease (CAD) in patients with previous percutaneous coronary intervention (PCI).

Methods: 56 patients were studied 1.9 (SD 1.4) years after PCI. They underwent MCPI with commercially available ultrasound contrast agents (Optison or Definity) at rest and at peak dobutamine–atropine stress. Coronary angiography was performed within one month. Significant CAD was defined as ⩾ 50% stenosis in ⩾ 1 major epicardial coronary artery. Significant restenosis was defined as ⩾ 50% stenosis in a coronary segment with previous intervention.

Results: Reversible perfusion abnormalities were detected in 40 of 43 patients with significant CAD and in 4 of 13 patients without (overall sensitivity 93%, 95% CI 85% to 99%; specificity 69%, 95% CI 44% to 94%; and accuracy 88%, 95% CI 79% to 96%). Significant restenosis in ⩾ 1 coronary artery with previous PCI was detected in 38 (68%) patients. Reversible perfusion abnormalities were present in 35 of them (sensitivity 92%, 95% CI 84% to 99%). Reversible perfusion abnormalities were detected in ⩾ 2 vascular distributions in 20 of 28 patients with multivessel CAD and in 3 of 28 patients without (sensitivity 71%, 95% CI 55% to 88%; specificity 89%, 95% CI 78% to 99%; and accuracy 80%, 95% CI 70% to 91%). Restenosis was detected in 41 coronary arteries. Sensitivity of MCPI for regional diagnosis of restenosis was 73% (95% CI 60% to 87%), specificity was 75% (95% CI 60% to 90%), and accuracy was 74% (95% CI 64% to 84%).

Conclusion: Dobutamine stress MCPI is a useful technique for the evaluation of restenosis and extent of CAD after PCI.

Myocardial contrast echocardiography is a newly introduced technique for the evaluation of myocardial perfusion in patients with known or suspected coronary artery disease (CAD).[1–3] Real-time imaging with low mechanical index pulse sequence schemes enhances the detection of microbubbles and reduces microbubble destruction. This permits the real-time identification of perfusion abnormalities during stress echocardiography.[1–5] Studies of myocardial perfusion after percutaneous coronary intervention (PCI) have used radionuclide imaging to detect restenosis.[6–15] There are no data on the utility of myocardial contrast perfusion imaging (MCPI) in the evaluation of patients with previous PCI. The objective of this study was to assess the accuracy of dobutamine stress real-time MCPI for the diagnosis of restenosis and evaluation of extent of CAD in patients with previous PCI.

METHODS

We studied 56 patients with previous PCI referred for evaluation of myocardial ischaemia by dobutamine stress MCPI in our laboratory between January 2002 and January 2005. All patients underwent quantitative coronary angiography within one month of the dobutamine stress test. Patients were not included if they had previous coronary artery bypass graft surgery. Table 1 presents clinical data and reasons for stress testing.

The stress test was performed four months to six years (mean 1.9 (SD 1.4) years) after PCI. Patients gave their informed consent to undergo the stress test. The protocol of this study was approved by the Institutional Review Board of the University of Nebraska Medical Center. Diabetes mellitus was defined as a fasting glucose concentration ⩾ 7.8 mmol/l or the need for insulin or oral hypoglycaemia agents. Hypercholesterolaemia was defined as total cholesterol ⩾ 5.2 mmol/l or treatment with lipid-lowering drugs. Hypertension was defined as repeated blood pressure measurements > 140/90 mm Hg or intake of hypertension drugs. Contraindications for the test were severe heart

Table 1 Clinical data of the study patients

Age (years)	63 (12)
Women	22 (39%)
Reason for referral	
Angina	20 (36%)
Atypical chest pain	9 (16%)
Dyspnoea	8 (14%)
Perioperative risk assessment	9 (16%)
Risk stratification/assessment of adequacy of revascularisation	10 (18%)
Previous myocardial infarction	19 (34%)
Diabetes mellitus	22 (39%)
Hypertension	43 (77%)
Hypercholesterolaemia	45 (80%)
Cigarette smoking	23 (41%)
β blockers	40 (71%)
Calcium channel blockers	15 (27%)

Data are mean (SD) or number (%) of patients.

failure, severe valvular heart disease, severe hypertension (blood pressure ⩾ 180/110 mm Hg), hypotension (blood pressure < 90/60 mm Hg) and unstable chest pain.

Dobutamine stress test

Patients were instructed to discontinue β blockers 24 h before the stress test. Dobutamine was infused at a starting dose of 5 μg/kg/min for 3 min, followed by 10 μg/kg/min for 3 min. The dobutamine dose was increased by 10 μg/kg/min every 3 min up to a maximum dose of 50 μg/kg/min. Atropine (up to 2 mg) was administered intravenously to achieve 85% of maximum predicted heart rate (220 − age). End points were reaching the target heart rate and the maximum dose of dobutamine and atropine, hypertension (blood pressure > 240/120 mm Hg), a symptomatic decrease in systolic blood pressure, symptomatic or sustained tachycardia, ST segment depression > 2 mm in ECG leads without resting ST depression, severe angina and any intolerable adverse effect considered to be the result of dobutamine. Metoprolol (1–5 mg) was used intravenously to reverse the side effects of dobutamine if these did not revert quickly after the stress test was stopped.

Echocardiographic imaging

The contrast agents used for the study were perfluorocarbon-containing albumin-coated microbubbles (Optison; GE-Amersham, Princeton, New Jersey, USA) in 46 patients and lipid-encapsulated perfluoropropane-filled microbubbles (Definity; Bristol Myers Squibb Medical Imaging, Inc, North Billerica, Massachusetts, USA) in 10 patients. Images were recorded with commercially available ultrasound scanners (SONOS 5500 and HDI 5000; Philips Medical Systems, Bothell, Washington; or Sequoia 6.0; Siemens Acuson, Mountain View, California, USA), equipped with low mechanical index real-time pulse sequence schemes. Images were obtained by the use of pulse inversion Doppler (HDI 5000), contrast pulse sequencing (Sequoia 6.0) or power modulation (SONOS 5500). The equipment was adjusted to achieve a maximal non-linear signal from contrast. Mechanical indexes were set to ⩽ 0.3 and frame rate to ⩾ 25 Hz.

Time gain compensation and two-dimensional gain settings were adjusted to suppress signals from the myocardium before contrast injection. Images from apical views (four, two and three chamber) were obtained and digitised at rest and at maximal stress after the patients achieved ⩾ 85% of the predicted maximum heart rate or a test end point.

After the settings were optimised, a 0.2–0.3 ml calibration dose of Optison or a 0.1–0.15 ml dose of Definity followed by saline flush was given. The bolus of contrast with saline flush was given over a 5 s period. As we were examining myocardial blood volume only and not using a continuous infusion, we did not use high mechanical index impulses (for example, flash impulses). Settings were corrected to optimise gain and minimise any tissue non-linear signals. Imaging began with a similar contrast dose in the apical four-chamber view. Images were acquired for a minimum of 15 s after peak myocardial opacification until contrast disappeared from the myocardium.

Images were acquired from the apical two-chamber and apical long-axis views by the same method. Myocardial perfusion was interpreted in the 16-segment model by an independent investigator, who was blinded to clinical and angiographic data. Studies were interpreted as either normal or abnormal in each of the three coronary arterial territories. A stress-induced (reversible) contrast defect was considered present when two contiguous segments showed no contrast enhancement during the washout of contrast after the bolus injection as compared with other segments at the same depth in the same view, and as compared with contrast enhancement in the same segment at rest in a side by side image analysis.[3] This was considered diagnostic for significant CAD. Attenuation from contrast or lung interference was considered present if any segment could not be visualised and was not distinguishable from surrounding tissue. The interobserver agreement on the presence of reversible perfusion defects on MCPI in our laboratory is 92%. The intraobserver agreement is 92%.[3]

Quantitative angiography

Coronary angiography was performed within one month from the dobutamine stress test. Coronary artery stenosis was measured quantitatively by an experienced interventional cardiologist with a hand-held electronic calliper. Measurements were expressed as the percentage diameter narrowing relative to the diameter of the nearest normal-appearing region. Significant CAD was defined as a diameter stenosis ⩾ 50% in a major epicardial coronary artery. Significant restenosis was defined as ⩾ 50% stenosis in stent or at a segment with previous angioplasty. The anterior, apical, septal and anteroseptal walls were assigned to the left anterior descending coronary artery. The posterolateral wall was assigned to the left circumflex coronary artery and its marginal branches. The inferior wall and basal septal segments were assigned to the right coronary artery. Because of the frequent vascular overlap between the right coronary artery and the left circumflex coronary artery, the posterior wall was regarded as overlap regions for these two coronary arteries.[1 3]

Statistical analysis

Continuous variables were presented as mean (SD) and were compared by Student's t test. Sensitivity, specificity and accuracy of MCPI were calculated according to standard definitions and were presented with 95% confidence intervals (CIs). Proportions were compared by χ^2 test. A value of $p < 0.05$ was considered significant.

RESULTS

Coronary angiography

Significant CAD was detected in 43 patients. Among them, 15 had single-vessel, 17 had two-vessel and 11 had three-vessel CAD. Previous PCI was performed in one coronary artery in 43 patients, two coronary arteries in nine patients and three coronary arteries in four patients (a total of 73 arteries with PCI; stents were deployed in 50 of these). Significant restenosis was detected in 41 (56%) coronary arteries with previous PCI.

Dobutamine stress test

Dobutamine–atropine induced changes of heart rate (70 (19) *v* 145 (13) beats/min) and systolic blood pressure (139 (34) *v* 147 (35) mm Hg) from rest to peak stress, respectively. Atropine was given to 38 (68%) patients. The mean dobutamine dose was 31 (12) μg/kg/min. The target heart rate was achieved by 52 (93%) patients. Chest pain occurred in 27 (48%) patients and ST segment depression (> 0.1 mV horizontal or downsloping) occurred in 10 (18%) patients. Two patients had non-sustained ventricular tachycardia and one patient had transient supraventricular tachycardia.

Diagnostic accuracy of MCPI

Myocardial perfusion abnormalities were detected at baseline echocardiogram in 17 (30%) patients. Reversible perfusion abnormalities occurred in 44 (79%) patients. Reversible perfusion abnormalities were detected in 40 of 43 patients with significant CAD and in four patients without (overall sensitivity 93%, 95% CI 85% to 99%; specificity 69%, 95% CI

Table 2 Regional accuracy of dobutamine stress myocardial contrast perfusion imaging for the diagnosis of coronary artery disease and restenosis after PCI

Arterial region	Sensitivity	Specificity	Accuracy
LAD	24/31 (77%, 63 to 92)	20/25 (80%, 64 to 96)	44/56 (79%, 68 to 89)
RCA	20/32, (63%, 46 to 79)	17/24 (71%, 53 to 89)	37/56 (66%, 54 to 79)
LCX	13/19 (68%, 48 to 89)	27/37 (73%, 59 to 87)	40/56 (71%, 60 to 83)
All arteries	57/82 (70%, 60 to 80)	64/86, (74%, 65 to 84)	121/168 (72%, 65 to 79)
Arteries with previous PCI	30/41 (73%, 60 to 87)	24/32 (75%, 60 to 90)	54/73 (74%, 64 to 84)

Diagnostic parameters are presented as percentages with corresponding 95% CI.
LAD, left anterior descending coronary artery; LCX, left circumflex artery; PCI, percutaneous coronary intervention; RCA, right coronary artery.

44% to 94%; and accuracy 88%, 95% CI 79% to 96%). One of the three patients with false negative myocardial contrast echocardiography did not achieve the target heart rate. Two of these patients had single-vessel and one had multivessel CAD. Among the 12 patients without reversible perfusion abnormalities, five had ST segment depression, four had exertional angina and three had dobutamine-induced angina. Among the four patients with false positive results, two had coronary stenosis $< 50\%$. Significant restenosis in $\geqslant 1$ coronary artery with previous PCI was detected in 38 (68%) patients. Reversible perfusion abnormalities were present in 35 of them (sensitivity 92%, 95% CI 84% to 99%). Reversible perfusion abnormalities were detected in $\geqslant 2$ vascular distributions in 20 of 28 patients with multivessel CAD and in three of 28 patients without (sensitivity to identify multivessel CAD based on abnormalities on two vascular distribution was 71%, 95% CI 55% to 88%; specificity 89%, 95% CI 78% to 99%; and accuracy 80%, 95% CI 70% to 91%). Table 2 presents the regional accuracy of MCPI for the diagnosis of CAD in all arteries and in coronary arteries with previous PCI.

Figure 1 presents echocardiographic and angiographic images of a patient who developed perfusion defects in multivessel distributions during dobutamine stress. In this example, MCPI detected a significant restenosis of the left anterior descending coronary artery and correctly identified the patient as having multivessel CAD on the basis of detection of reversible perfusion abnormalities in multivessel distribution.

DISCUSSION

PCI is an increasingly used technique for restoration of myocardial perfusion in patients with obstructive CAD. The improved outcome with the use of stents with PCI and the use of new antiplatelet agents have resulted in a significant increase in the number of PCI procedures over the past decade. As a result, the use of and indications for PCI have greatly expanded.[16] Nevertheless, restenosis remains a major clinical problem.[17] Patients may remain asymptomatic or have atypical symptoms despite restenosis or progression of CAD in other coronary arterial segments. Coronary angiography is not recommended as a routine follow-up tool due to the associated risk and the high cost. The non-invasive evaluation of CAD after PCI is a clinical challenge. Stress radionuclide imaging can detect compromised myocardial perfusion after PCI with a reportedly fair to good accuracy.[6–15]

In this study we showed that dobutamine stress MCPI was a useful method for detection of compromised perfusion due to restenosis and CAD involving arteries without previous interventions in 56 patients who were evaluated at a mean of

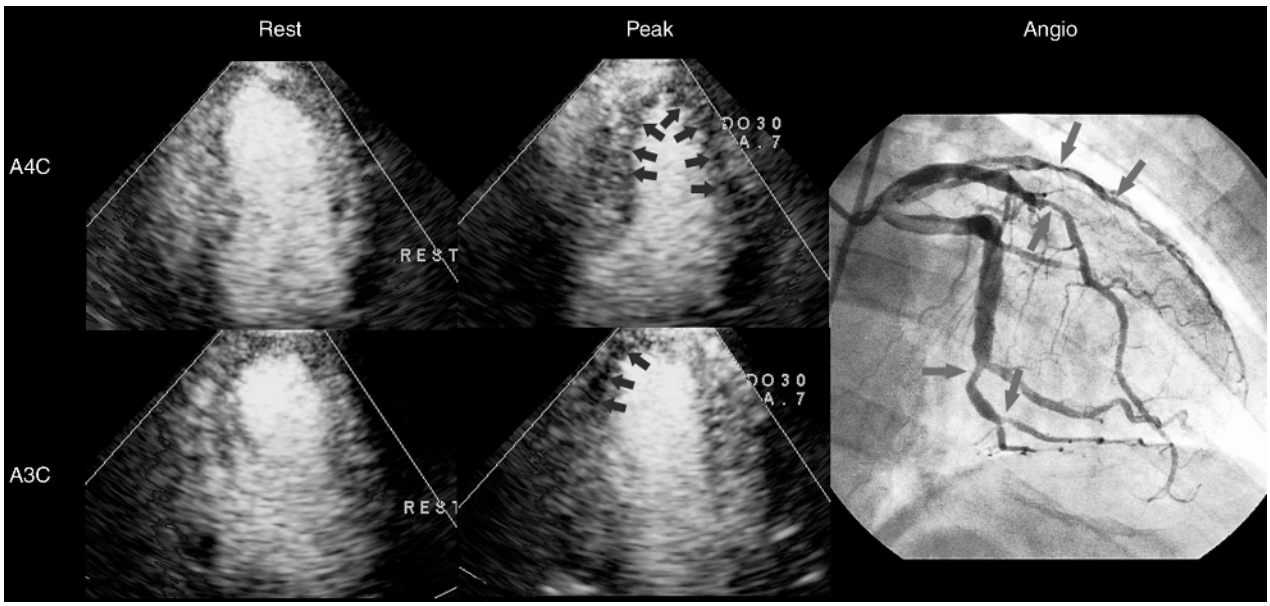

Figure 1 Echocardiographic images from the apical four-chamber (A4C) and three-chamber (A3C) views at rest (left) and at peak dobutamine stress (middle) of a 63-year-old man with previous intervention of a mid-left anterior descending coronary artery (LAD) lesion. Reversible subendocardial perfusion abnormalities in the distal septum, apex, lateral wall and apical posterior wall are indicated by arrows on the stress images. Coronary angiography (right) shows restenosis of the LAD lesion as well as high-grade stenosis of both the left circumflex and a large diagonal coronary artery (arrows).

1.9 years after PCI. The test was tolerated without serious complications. Reversible perfusion abnormalities were detected in 93% of patients with restenosis. We identified most patients with multivessel disease by observing perfusion abnormalities in multivessel distribution with a sensitivity of 71% and a specificity of 89%. MCPI is therefore potentially useful in determining patients with large myocardial regions at risk after PCI and selecting patients for further invasive procedure.

To date, clinical studies of myocardial perfusion after PCI have been mainly performed with nuclear techniques. The current study suggests that MCPI potentially is an alternative echocardiographic method for evaluation of myocardial perfusion after PCI, without the need for irradiation or a nuclear scanner. Other advantages of the technique include the acquisition of rest and stress images in one setting and the immediate availability of the results.

Stress radionuclide imaging

Giedd *et al*[6] pooled data from eight studies with 640 patients, in which stress radionuclide tomography and coronary angiography were performed within 2–48 months of PCI. The overall sensitivity and specificity of radionuclide imaging for detecting myocardial ischaemia were both 79% and were roughly equivalent in all three vascular territories. Caner *et al*[13] evaluated 34 consecutive patients with dobutamine thallium-201 SPECT eight weeks to two years after percutaneous coronary angioplasty. Sensitivity, specificity and accuracy for predicting restenosis were 76%, 79% and 77%, respectively. Takeuchi *et al*[1] compared dobutamine thallium with echocardiography in 53 patients after PCI. The sensitivities of echocardiography and SPECT for detecting restenosis were 78% and 74%; specificities were 93% and 93%; and accuracies were 87% and 85%, respectively. Elhendy *et al*[15] studied 40 patients at a mean of 185 days after successful PCI with dobutamine stress test, in conjunction with technetium-99m sestamibi tomography. The sensitivity for the detection of restenosis in arteries with previous PCI was 69%, the specificity was 76% and accuracy was 72%.

Limitations of the study

Coronary angiography was performed according to the discretion of the treating physician. Therefore, verification bias related to performing coronary angiography in patients with an abnormal test may have influenced the results. The population was heterogeneous with a wide time range after PCI and included patients with and without symptoms. The study therefore did not determine whether stress testing should be routinely used in these patients at a certain time interval.

This study used intravenous bolus injections of microbubbles and therefore analysed myocardial blood volume only. As with any contrast imaging method, the system threshold and dynamic range affect the detection of signal intensity and the ability to discriminate regional differences in myocardial blood volume. This is why we chose to analyse heterogeneity in myocardial contrast enhancement while contrast was washing out of the myocardium after a bolus injection. During this time microbubble concentration and signal intensity are linearly related. Unlike with continuous infusions of microbubbles, there are no methods for detecting flow velocity or myocardial blood flow changes with bolus injections of microbubbles.

Authors' affiliations

A Elhendy, J M Tsutsui, E L O'Leary, F Xie, F Majeed, T R Porter, Department of Internal Medicine, Section of Cardiology, University of Nebraska Medical Center, Omaha, Nebraska, USA

AE is in the speakers bureau of Bristol Myers Squibb Medical Imaging. TP has received research grants from Bristol Myers Squibb Medical Imaging.

REFERENCES

1 **Tsutsui JM**, Elhendy A, Xie F, *et al*. Safety of dobutamine stress real-time myocardial contrast echocardiography. *J Am Coll Cardiol* 2005;**45**:1235–42.
2 **Lepper W**, Belcik T, Wei K, *et al*. Myocardial contrast echocardiography. *Circulation* 2004;**109**:3132–5.
3 **Elhendy A**, O'Leary EL, Xie F, *et al*. Comparative accuracy of real-time myocardial contrast perfusion imaging and wall motion analysis during dobutamine stress echocardiography for the diagnosis of coronary artery disease. *J Am Coll Cardiol* 2004;**44**:2185–91.
4 **Mulvagh SL**, DeMaria AN, Feinstein SB, *et al*. Contrast echocardiography: current and future applications. *J Am Soc Echocardiogr* 2000;**13**:331–42.
5 **Leistad E**, Ohmori K, Peterson TA, *et al*. Quantitative assessment of myocardial perfusion during graded coronary artery stenoses by intravenous myocardial contrast echocardiography. *J Am Coll Cardiol* 2001;**37**:624–31.
6 **Giedd KN**, Bergmann SR. Myocardial perfusion imaging following percutaneous coronary intervention: the importance of restenosis, disease progression, and directed reintervention [review]. *J Am Coll Cardiol* 2004;**43**:328–36.
7 **Bachmann R**, Sechtem U, Voth E, *et al*. Dipyridamole scintigraphy and intravascular ultrasound after successful coronary intervention. *J Nucl Med* 1997;**38**:553–8.
8 **Milan E**, Zoccarato O, Terzi A, *et al*. Technetium-99m-sestamibi SPECT to detect restenosis after successful percutaneous coronary angioplasty. *J Nucl Med* 1996;**37**:1300–5.
9 **Kósa I**, Blasini R, Schneider-Eicke J, *et al*. Myocardial perfusion scintigraphy to evaluate patients after coronary stent implantation. *J Nucl Med* 1998;**39**:1307–11.
10 **Milavetz JJ**, Miller JD, Hodge DO, *et al*. Accuracy of single-photon emission computed tomography myocardial perfusion imaging in patients with stents in native coronary arteries. *Am J Cardiol* 1998;**82**:857–61.
11 **Beygui F**, Le Feuvre C, Maunoury C, *et al*. Detection of coronary restenosis by exercise electrocardiography thallium-201 perfusion imaging and coronary angiography in asymptomatic patients after percutaneous transluminal coronary angioplasty. *Am J Cardiol* 2000;**86**:35–40.
12 **Galassi AR**, Foti R, Azzarelli S, *et al*. Usefulness of exercise tomographic perfusion imaging for detection of restenosis after coronary stent implantation. *Am J Cardiol* 2000;**85**:1362–4.
13 **Caner B**, Oto A, Ovunc K, *et al*. Prediction of restenosis after successful percutaneous coronary angioplasty by dobutamine thallium-201 scintigraphy. *Int J Cardiol* 1998;**66**:175–81.
14 **Takeuchi M**, Miura Y, Toyokawa T, *et al*. The comparative diagnostic value of dobutamine stress echocardiography and thallium stress tomography for detecting restenosis after coronary angioplasty. *J Am Soc Echocardiogr* 1995;**8**:696–702.
15 **Elhendy A**, Geleijnse ML, Roelandt JR, *et al*. Dobutamine ^{99m}Tc-MIBI SPET myocardial perfusion scintigraphy in the prediction of restenosis after percutaneous transluminal coronary angioplasty in patients unable to perform an exercise stress test. *Nucl Med Commun* 1997;**18**:122–8.
16 **Anderson HV**, Shaw RE, Brindis RG, *et al*. A contemporary overview of percutaneous coronary interventions: the American College of Cardiology-National Cardiovascular Data Registry (ACC-NCDR). *J Am Coll Cardiol*, 2000;**39**;1096–103..
17 **Lowe HC**, Oesterle SN, Khachigian LM. Coronary in-stent restenosis: current status and future strategies. *J Am Coll Cardiol* 2002;**39**:83–193.