light microscopy and by immunohistochemical staining.

The majority of granular cell tumours are benign. Atypical histological features noted in malignant granular cell tumours include necrosis, increased mitotic activity (Ki-67 proliferative index), high nuclear/cytoplasmic ratio, and nuclear pleomorphism. Our case did not show these atypical features.

Granular cell tumour should be included in the differential diagnosis of an asymptomatic caruncle mass that may cause secondary mechanical ectropion, as in our case. In the majority of cases, these lesions represent a benign isolated tumour. Surgical excision is the treatment of choice with minimal or no potential of recurrence.

M Evans, E Chang, D L Yu, N A Rao
Doheny Eye Institute, Department of Ophthalmology and Pathology, The Keck School of Medicine, University of Southern California, Los Angeles, CA, USA

Correspondence to: Narsing A Rao, MD, Doheny Eye Institute, 1450 San Pablo Street, DVRC 211, Los Angeles, CA 90033, USA; nrao@usc.edu

doi: 10.1136/bjo.2005.083790

Accepted for publication 3 October 2005

References

1 **Mazur MT**, Shultz JJ, Myers JL. Granular cell tumor. Immunohistochemical analysis of 21 benign and one malignant tumor. *Arch Pathol Lab Med* 1990;**114**:692–6.
2 **Luthra CL**, Doxanas MT, Green WR. Lesions of the caruncle: a clinicohistopathologic study. *Surv Ophthalmol* 1978;**23**:183–95.
3 **Le BH**, Boyer PJ, Lewis JE, Kapadia SB. Granular cell tumor: immunohistochemical assessment of inhibin-alpha, protein gene product 9.5, S100 protein, CD68, and Ki-67 proliferative index with clinical correlation. *Arch Pathol Lab Med* 2004;**128**:771–5.
4 **Kurtin PJ**, Bonin DM. Immunohistochemical demonstration of the lysosome-associated glycoprotein CD-68 (KP-1) in granular cell tumor and schwannomas. *Hum Pathol* 1994;**25**:1172–8.

Solar retinopathy in a patient with bipolar affective disorder

The commonest cause of solar retinopathy is direct viewing of a solar eclipse.[1] Other associations include sun gazing during religious rituals, drug or alcohol intoxication, and mental illness.[2 3] However, it may not be considered in the absence of a history of sun gazing. We report an unusual case of solar retinopathy in a patient with bipolar affective disorder and demonstrate the value of optical coherence tomography in aiding the diagnosis in cases of unexplained visual loss in patients with mental illness.

Case report

A 45 year old woman presented complaining of a gradual deterioration in vision over 3 years. Past medical history included hypothyroidism and bipolar affective disorder treated with antidepressant and antipsychotic medication.

Presenting visual acuities were 6/12 in the right eye and 6/9 in the left. In the centre of the fovea in both eyes there was a small, irregular 100 μm size red spot without oedema (fig 1). Fluorescein angiogram was normal. Optical coherence tomography (OCT) was performed bilaterally using a Zeiss Stratus model 3000, with the scanning line centred manually on the area of foveal disturbance. Both eyes showed similar findings with multiple slices at different angles revealing a single spot of hyporeflectivity in the outer retina, suggesting discontinuity in the photoreceptor outer segment layer (fig 2).

The OCT appearance suggested a diagnosis of solar retinopathy and on direct questioning the patient admitted to staring at the sun for prolonged periods of time during depressive phases of her illness and during solar eclipses.

Comment

Classically, solar retinopathy presents soon after the initial insult with symptoms including reduced visual acuity, central scotoma, chromatopsia, photophobia, and metamorphopsia. Acutely, there may be loss of the foveal reflex together with a small yellow-white spot near the foveola which gradually fades. A longstanding lesion may only show an irregularly pigmented macula with foveal hypopigmentation.[3]

Differential diagnoses include early macular hole, lamellar hole, macula dystrophy, or cystoid macular oedema.[3] Fluorescein angiography may help to differentiate these. However there is often little or no abnormality in solar retinopathy, although in severe cases there may be a window defect caused by retinal pigment epithelium (RPE) atrophy.[2]

OCT findings in acute solar retinopathy were first described by Codenotti *et al*.[4] OCT studies in chronic solar retinopathy describe hyporeflective spaces at the level of the outer photoreceptor segments and RPE. These may involve the entire photoreceptor layer in more severe cases, together with overlying neurosensory thinning.[5 6]

Our patient would not initially volunteer a history of sun gazing but admitted to this when told the OCT findings. Similar OCT findings can be seen in stage 1 macular hole, but these findings in combination with a history of sun gazing are strongly suggestive of a diagnosis of solar retinopathy. Sun gazing has been described in a patient with bipolar disease during a manic episode with psychotic symptoms, although there was no evidence of alteration of visual function or macular damage.[7] Previous reports have mainly been associated with schizophrenia.[8 9] Patients presented acutely, as acute or chronic episodes with repeated sun gazing, or were found to have a typical macular lesion incidentally. In chronic cases they gave a history of sun gazing during acute episodes of illness.

To our knowledge this is the first documented case of solar retinopathy in a patient with bipolar affective disorder. This case demonstrates the benefits of OCT in the diagnosis of macular diseases where the history may be unreliable. It also highlights the need to consider the diagnosis of solar retinopathy in a range of psychiatric conditions where there is functional visual loss.

Figure 1 Colour photograph depicting stage 1 macular hole-like appearance.

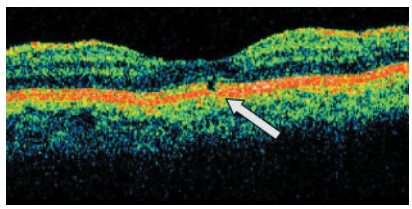

Figure 2 A 3 mm Stratus OCT single line scan through fixation. Arrow indicating hyporeflectivity in photoreceptor outer segment layer suggesting discontinuity.

D S Devadason, S Mahmood, P E Stanga
Manchester Royal Eye Hospital, Manchester, UK

P N Bishop
Academic Unit of Eye and Vision Science, The Medical School, University of Manchester, UK

Correspondence to: P N Bishop, Academic Department of Ophthalmology, Manchester Royal Eye Hospital, Oxford Road, Manchester M13 9WH, UK; paul.bishop@manchester.ac.uk

doi: 10.1136/bjo.2005.078550

Accepted for publication 17 October 2005

Competing interests: none declared

References

1 **Rai N**, Thuladar L, Brandt F, *et al*. Solar retinopathy. A study from Nepal and Germany. *Doc Ophthalmol* 1998;**95**:99–108.
2 **Michaelides M**, Rajendram R, Marshall J, *et al*. Eclipse retinopathy. *Eye* 2001;**15**:148–51.
3 **Thomas JW**, Stokkermans OD, Dunbar TM. Solar retinopathy in a hospital based primary care clinic. *J Am Optom Assoc* 1998;**69**:625–36.
4 **Codenotti M**, Patelli F, Brancato R. OCT findings in patients with retinopathy after watching a solar eclipse. *Ophthalmologica* 2002;**216**:463–6.
5 **Jorge R**, Costa RA, Quirino LS. Optical coherence tomography findings in patients with late solar retinopathy. *Am J Ophthalmol* 2004;**37**:1139–43.
6 **Garg SJ**, Martidis A, Nelson ML, *et al*. Optical coherence tomography of chronic solar retinopathy. *Am J Ophthalmol* 2004;**137**:351–4.
7 **Kamp PS**, Dietrich AM, Rosse RB. Sungazing by psychiatric patients. *Am J Psychiatry* 1990;**147**:810–11.
8 **Galainena ML**. Solar retinopathy. *Ann Ophthalmol* 1976;**8**:304–6.
9 **Anaclerio AM**, Wicker SH. Self induced solar retinopathy by patients in a psychiatric hospital. *Am J Ophthalmol* 1970;**69**:731–6.

Topical brinzolamide and metabolic acidosis

Treatment of ophthalmic disease largely involves the administration of topical medication in doses that would appear small relative to those used systemically. With a few exceptions (such as β receptor antagonists) the systemic side effects of topical ocular medication, though recognised, are

often ignored in clinical practice. We report a case that highlights the need for constant vigilance in the context of such ophthalmic therapy.

Case report

A 66 year old white man, on treatment with topical latanoprost for primary open angle glaucoma, required further reduction of intraocular pressure, in the pursuit of which topical brinzolamide was added to one eye only.

At review 3 months later, the patient reported having stopped brinzolamide on his own initiative because of lethargy and a bad taste in the mouth. The subject had worn a silver chain around his neck for many years; interestingly, this chain had turned black within 2 days of starting topical brinzolamide. The chain was professionally cleaned and then re-worn, immediately upon which it turned black once again (fig 1).

Adequate control of intraocular pressure was subsequently established with a combination of topical travoprost, timolol, and pilocarpine.

Comment

The clinical history strongly indicates the development of metabolic acidosis in response to topical brinzolamide, a recognised consequence of therapy with carbonic anhydrase inhibitors. The blackening of the silver chain was caused by oxidation of the silver, most likely as a result of exposure to acidic sweat, a homeostatic mechanism to normalise the pH of the extracellular fluid. Incontrovertible objective verification of such disturbance of the acid-base balance would necessitate re-challenging the patient with the drug along with arterial blood gas analysis, a measure that was deemed excessive and inappropriate on the grounds of patient safety.

It would appear remarkable that such acidosis developed in response to an apparently small dose of medication, the drug having been instilled twice daily in only one eye—until the pharmacodynamics of topical ocular medications are studied. It is well recognised that topically administered drugs are rapidly absorbed into the systemic circulation.[1] Manual lacrimal sac compression has been advocated as a means of reducing systemic absorption, on the basis that drugs are absorbed more effectively from the ciliated columnar (respiratory) epithelium of the nasal passages—the effects of such lacrimal compression are, however, variable.[2 3] Lacrimal compression also does not affect drug absorption across the vascular conjunctiva, which has been estimated at being 10 times faster than the transcorneal route. Transconjunctival absorption also competitively reduces absorption across the cornea, thus depotentiating any ocular therapeutic effect.

It has been estimated that less than 5% of an instilled dose of a topical drug is absorbed intraocularly.[4] The achievement of a desired ocular therapeutic effect therefore often necessitates higher concentrations and frequent instillations of a drug, with the attendant increased risk of systemic effects. In this context it is also clinically significant that topical eye drops, when absorbed, do not undergo first pass metabolism, bypassing as they do the liver and gaining direct entry into the systemic circulation.

We submit that the common tendency to consider eye drops as representing miniscule and systemically insignificant doses of therapeutic agents is therefore ill founded—the prescription of eye drops merits comparable weight and consideration as that of systemic medication.

G J Menon, S A Vernon
Department of Ophthalmology, Eye and ENT Centre, University Hospital Nottingham, UK

Correspondence to: Mr S A Vernon, Department of Ophthalmology, Eye and ENT Centre, University Hospital Nottingham, Nottingham NG7 2UH, UK; stephen.vernon@qmc.nhs.uk

doi: 10.1136/bjo.2005.075622

Accepted for publication 21 August 2005

References

1 **Salminen L**. Review: systemic absorption of topically applied ocular drugs in humans. *J Ocul Pharmacol* 1990;**6**:243–9.
2 **Kaila T**, Huupponen R, Salminen L. Effects of eyelid closure and nasolacrimal duct occlusion on the systemic absorption of ocular timolol in human subjects. *J Ocul Pharmacol* 1986;**2**:365–9.
3 **Zimmerman TJ**, Kooner KS, Kandarakis AS, *et al*. Improving the therapeutic index of topically applied ocular drugs. *Arch Ophthalmol* 1984;**102**:551–3.
4 **Urtti A**, Salminen L. Minimizing systemic absorption of topically administered ophthalmic drugs. *Surv Ophthalmol* 1993;**37**:435–56.

Figure 1 The blackened silver medallion.

Anterior ischaemic optic neuropathy after rotator cuff surgery

Perioperative visual loss has been associated with many types of non-ocular surgery.[1] Risk factors include combinations of prolonged surgical times, hypotension, anaemia due to blood loss, or prone positioning.[2] We are not aware of another report of perioperative visual loss in which the only risk factor was hypotension.

Case report

A 55 year old man had left rotator cuff surgery. He was supine, surgical time was 3 hours, and blood loss was minimal. Postoperatively he experienced ''kaleidoscopic'' vision in the inferior visual field of his left eye which cleared. Four weeks later he had right rotator cuff surgery. Again he was supine, surgery lasted 2–3 hours, and blood loss was 100 ml. After recovery he had ''kaleidoscopic'' vision in the same eye. It did not resolve and his vision continued to deteriorate prompting him to seek ophthalmological care.

His medical history was significant for treated hyperlipidaemia. He quit smoking 35 years earlier. Visual acuity was 20/20 in the right eye and counting fingers in the left. He identified 9/12 colour plates in the right eye and 0/12 in the left. He had a left afferent papillary defect. The right optic disc was

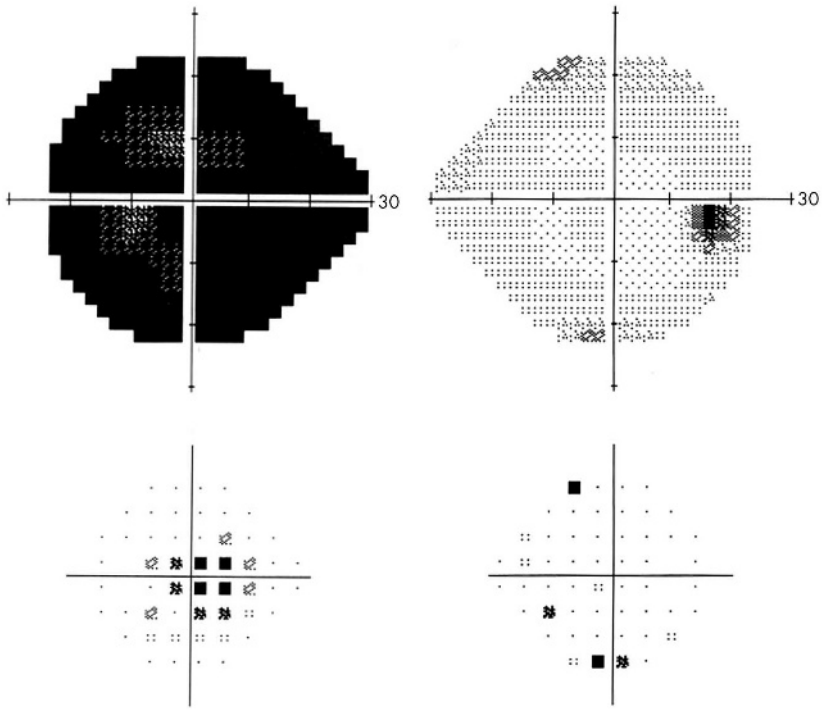

Figure 1 Humphrey automated perimetry after the second surgery and loss of vision in the left eye.