Table 1 *BclI*, ER22/23EK, and N363S genotype in patients with Crohn's disease (CD), ulcerative colitis (UC), and controls

	Genotype (n (%))			OR (95% CI)	
	Wild-type	Heterozygous	Mutated	Mutated *v* not mutated	p Value
BclI					
Controls (n = 70)	30 (42.9%)	34 (48.5%)	6 (8.6%)	–	–
CD (n = 34)	9 (26.5%)	16 (47%)	9 (26.5%)	3.84 (1.23–11.91)	0.03
UC (n = 23)	10 (43.5%)	12 (52.2%)	1 (4.3%)	1.03 (0.39–2.65)	1
ER22/23EK	Wild-type	Heterozygous	Mutated	Heterozygous *v* wild-type	
Controls (n = 70)	67 (95.7%)	3 (4.3%)	0 (0%)	–	–
CD (n = 34)	32 (94.1%)	2 (5.9%)	0 (0%)	1.39 (0.22–8.78)	0.6
UC (n = 23)	22 (95.7%)	1 (4.3%)	0 (0%)	1.01 (0.10–10.27)	1
N363S	Wild-type	Heterozygous	Mutated	Heterozygous *v* wild-type	
Controls (n = 70)	67 (95.7%)	3 (4.3%)	0 (0%)	–	–
CD (n = 34)	33 (97.1%)	1 (2.9%)	0 (0%)	0.68 (0.07–6.76)	1
UC (n = 23)	21 (91.3%)	2 (8.7%)	0 (0%)	2.13(0.33–13.60)	0.6

OR (95% CI), odds ratio (95% confidence interval).

length polymorphism of the glucocorticoid receptor locus and hyperinsulinaemia in obese women. *J Mol Endocrinol* 1992;**9**:295–300.
8 **van Rossum EF**, Koper JW, van den Beld AW, *et al*. Identification of the BclI polymorphism in the glucocorticoid receptor gene: association with sensitivity to glucocorticoids in vivo and body mass index. *Clin Endocrinol* 2003;**59**:585–92.
9 **Reinshagen M**, Haefele T, Holicki S, *et al*. The ultra low dose ACTH-test identifies a subgroup of patients with Crohn's disease and an impaired hypothalamo-pituitary-adrenal (HPA) axis. *Gastroenterology* 2002;**122**:S1384.
10 **Huizenga NA**, Koper JW, De Lange P, *et al*. A polymorphism in the glucocorticoid receptor gene may be associated with increased sensitivity to glucocorticoids in vivo. *J Clin Endocrinol Metab* 1998;**83**:144–51.

Effect of *Helicobacter pylori* eradication on precancerous lesions

We read with interest the paper by Mera and colleagues (*Gut* 2005;**54**:1536–40) on the effect of eradicating *Helicobacter pylori* infection on precancerous gastric lesions. However, we have concern regarding the extent to which the limited data provided in the paper support the authors' conclusions of regression of atrophy and intestinal metaplasia following *H pylori* eradication.

The main outcome reported was the average histological score. This is an arbitrary ordinal scale which is based on the presence of superficial gastritis, atrophic gastritis, intestinal metaplasia, dysplasia, or cancer as the most advanced lesion found in the four gastric biopsies performed at each time point. The average score was 3.77 at baseline, and following eradication of the infection decrease to 3.18 after 12 years. The extent to which resolution of the different components of the average histological score contributed to the fall in the score is not made clear in the paper. However, the authors do present data showing that the acute polymorphonuclear cell infiltration fully resolved and the chronic mononuclear cell infiltration partially resolved. The magnitude of the resolution of the inflammatory infiltrate would appear to be adequate to explain the fall in the average histological score without any associated resolution of the intestinal metaplasia or atrophy. The results section does not give information on the score for atrophy or intestinal metaplasia at baseline versus 12 years.

In the discussion section, comment is made to changes in atrophy and intestinal metaplasia. However, there are insufficient data to draw any meaningful conclusions or perform statistical analysis. In addition, there is clearly an error in the data provided is the discussion section as 70/182 is called 20%.

We would be grateful if the authors would provide individual metaplasia and atrophy scores at baseline and at 12 years in the two groups in order to allow independent analysis and interpretation of this important study. This is important as these are the lesions most strongly associated with cancer risk.

Our interpretation of the limited data made available in the current version of the paper is that there is evidence of early complete resolution of acute polymorphonuclear infiltration and partial resolution of chronic mononuclear cell infiltration but no convincing evidence presented of resolution of intestinal metaplasia or atrophy. The findings are therefore consistent with a number of previous studies showing no evidence of reversal of the important precancerous lesions. We also note that during the 12 years of follow up, five cancers occurred in the *H pylori* treatment group and four in the non-treatment group. Contrary to the conclusions of the authors, the benefit of eradicating *H pylori* infection in patients with advanced gastritis as a means of preventing cancer remains far from clear.

D Gillen, K E L McColl
Department of Gastroenterology, Western Infirmary, Glasgow, UK

Correspondence to: Professor K E L McColl, Department of Gastroenterology, Western Infirmary, 44 Church St, Glasgow G11 6NT, UK; k.e.l.mccoll@clinmed.gla.ac.uk

Conflict of interest: None declared.

Symptomatic gastro-oesophageal reflux in a patient with achlorhydria

Intraluminal impedance monitoring makes it possible to detect gastro-oesophageal reflux, independent of its pH.[1] This is useful because other factors apart from acidity are important in symptom generation.[2] Here, we describe a patient with achlorhydria in which impedance monitoring was used to identify gastro-oesophageal reflux as the cause of her symptoms.

A 72 year old female presented at our department. She complained of a retrosternal burning sensation which occurred at least five times a day. Eighteen months previously, her general practitioner prescribed monthly vitamin B12 injections after a routine blood test had revealed a megaloblastic macrocytic anaemia. She had underwent laparoscopic cholecystectomy for symptomatic gall stones four years previously.

Oesophageal manometry and 24 hour pH monitoring were performed. Results of oesophageal manometry were unremarkable. Ambulatory 24 hour pH monitoring showed an oesophageal acid exposure time of 0%; the lowest pH value that was reached was 5.5 (fig 1). Nine episodes of heartburn were reported by the patient but none was acid reflux related, resulting in a negative symptom index (SI) and symptom association probability (SAP) (both 0%).

After the results of pH monitoring had shown total absence of acid reflux, achlorhydria was suspected and further investigations were felt to be warranted. A blood test revealed normal values for blood cell counts and volumes and a slightly elevated serum vitamin B12 level (1080 pmol/l; normal 148–625). Serum gastrin was slightly high (135 ng/l; normal <75 for females). Tests for antibodies against parietal cells and intrinsic factor were positive. Upper endoscopy revealed an atrophic reddish mucosa of the gastric corpus and fundus. No oesophageal abnormalities were observed. Rapid urease tests were negative, indicating the absence of *Helicobacter pylori*. Microscopy revealed inflammation and intestinal metaplasia but no *H pylori*. A diagnosis of autoimmune atrophic gastritis was thus made. However, it was still unclear whether the patient's symptoms were the result of reflux of gastric contents.

Therefore, we decided to perform a 24 hour combined pH-impedance measurement. Again, pH data showed an acid exposure time of 0%, and no acid reflux episodes were measured. Analysis of the impedance signals showed 22 weakly acidic and five weakly alkaline reflux episodes. The patient experienced 11 episodes of heartburn, eight of which were preceded by a weakly acidic reflux episode, resulting in a positive SI and SAP for weakly acidic reflux (72.7% and 100.0%, respectively). The options of endoscopic or surgical antireflux treatments were considered but the patient responded well to intermittent sucralfate.

There is little information in the literature on reflux symptoms in patients with achlorhydria. Palmer described 22 cases of oesophagitis in patients with achlorhydria, also suggesting that non-acid reflux can induce oesophageal inflammation.[3] However, in Palmer's report, no mention was made of the symptoms experienced by his patients. Orlando and Bozymski described heartburn in

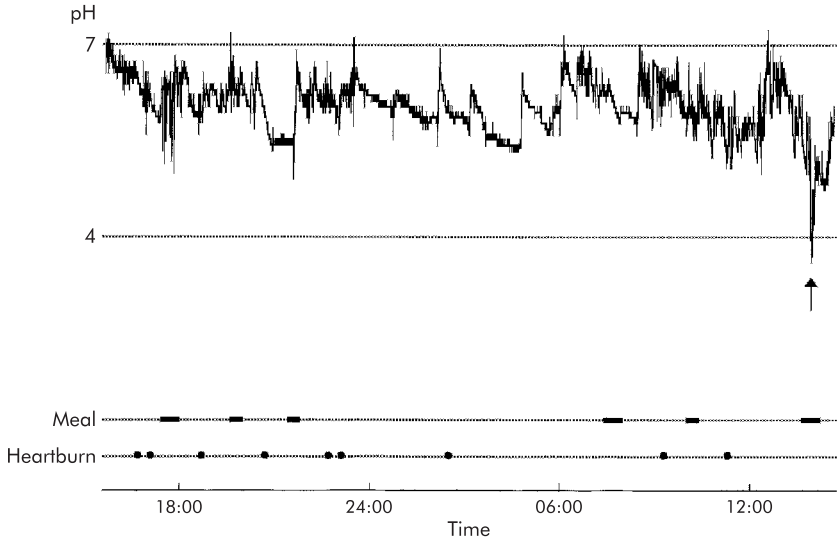

Figure 1 Tracing of 24 hour pH monitoring. No acid reflux episodes occurred. The drop in pH indicated by the arrow was caused by ingestion of (acidic) food.

a patient with pernicious anaemia which they felt was most likely induced by bile reflux.[4] Their patient's heartburn resolved on treatment with cholestyramine, a resin that binds bile salts. Our patient underwent a cholecystectomy a few years previously, a condition which may facilitate entry of bile into the stomach.[5] Bile may have been responsible for symptom generation in our patient. Although the study of Orlando and Bozymski suggests a relationship between reflux and symptoms, it does not prove such a relationship as confidently as can be done using symptom association analysis.

In conclusion, combined impedance-pH monitoring can be used to evaluate symptoms in patients with achlorhydria. The relationship between symptoms and weakly acidic and weakly alkaline reflux episodes can be investigated with this technique, which may have consequences for patient management.

Acknowledgements

AJ Bredenoord is supported by a grant from Janssen-Cilag, Tilburg, the Netherlands.

A J Bredenoord
Department of Gastroenterology, Sint Antonius Hospital, Nieuwegein, the Netherlands

A Baron, A J P M Smout
Gastrointestinal Research Unit, Department of Gastroenterology, University Medical Centre, Utrecht, the Netherlands

Correspondence to: Dr A J Bredenoord, Department of Gastroenterology, St Antonius Hospital, PO Box 2500, 3430 EM Nieuwegein, the Netherlands; a.bredenoord@antonius.net

doi: 10.1136/gut.2006.092650

Conflict of interest: None declared.

References

1 **Silny J**. Intraluminal multiple electric impedance procedure for measurement of gastrointestinal motility. *J Gastrointest Motil* 1991;**3**:151–62.
2 **Bredenoord AJ**, Weusten BL, Curvers WL, *et al*. Determinants of perception of heartburn and regurgitation. *Gut* 2005;**55**:313–18.
3 **Palmer ED**. Subacute erosive ("peptic") esophagitis associated with achlorhydria. *N Engl J Med* 1960;**262**:927–9.
4 **Orlando RC**, Bozymski EM. Heartburn in pernicious anemia—a consequence of bile reflux. *N Engl J Med* 1973;**289**:522–3.
5 **Mearin F**, De RX, Balboa A, *et al*. Duodenogastric bile reflux and gastrointestinal motility in pathogenesis of functional dyspepsia. Role of cholecystectomy. *Dig Dis Sci* 1995;**40**:1703–9.

Liver fibrosis assessment by transient elastography in hepatitis C patients with normal alanine aminotransferase

We read with interest the paper by Foucher *et al* (*Gut* 2006;**55**: 403–8) where the authors assessed the accuracy of transient elastography for the detection of cirrhosis. Its use in assessing the severity of chronic liver disease in other clinical scenarios warrants further evaluation. According to large population studies, the prevalence of chronic hepatitis C virus (HCV) infected patients who have persistently normal serum alanine aminotransferase (PN-ALT) levels is most likely 30–50%.[1] A major problem is defining whether or not these patients will suffer a progressive disease; additionally, although no consensus exists regarding who must be treated and when antiviral therapy should be initiated, positive decisions have been reinforced by recent results of a large clinical trial indicating that pegylated interferon plus ribavirin combination therapy is effective and safe in these patients with PN-ALT.[2]

In a recent review, the schedule of antiviral combination treatment of patients with chronic hepatitis C and normal aminotransferases was described, and indications for antiviral therapy in some cases was decided on the basis of histological findings[1]; hence liver biopsy seems to be key in this decision and a patient must be treated if there is significant fibrosis (≥OR = F2). However, although liver biopsy remains the "gold standard" for assessment of hepatic fibrosis, it represents an invasive procedure with some risks and limitations, as noted by Foucher *et al*, and is not well accepted by all patients. Non-invasive methods such as Fibrotest, Forns' index (FI), and APRI have been designed to assess liver fibrosis.[3]

Fibroscan (FS), a new transient elastography technique to measure liver stiffness or elasticity,[4 5] has provided some optimism as an alternative method for staging liver disease. Stiffness non-significantly correlates with fibrosis stage and is a promising and reproducible method for the detection of cirrhosis, independent of the operator.[5] Our aim was to use FS to assess hepatic fibrosis in patients infected by HCV with PN-ALT, comparing the accuracy of FS to that previously described for biomarkers.

We analysed prospectively 28 chronically infected HCV patients (18 females) with PN-ALT (at least three determinations yearly), assessing hepatic fibrosis by FS. Concordance and correlation between FS, FI, and APRI were also evaluated. Almost all consecutive patients were asymptomatic and none had the well known complications of advanced liver disease or cirrhosis.[6] Patient characteristics (mean (SD)) were as follow: age 44.3 (10) years, body mass index 24.1 (2.8) kg/m^2, platelets count 249.6 (58)/mm^3, serum cholesterol 190.5 (26) mg/dl, serum aspartate aminotransferase 25 (5) IU/l, serum ALT 27.7 (6.7) IU/l, and serum gamma glutamyl transferase 23.2 (21) IU/l. Results of the study were as follow: 26 (92.8%) patients had HCV genotype 1. Mean value for FS was 6.35 (3.3) kPa, indicating absence or mild stage fibrosis (<8.5 kPa); as expected, mean values for FI (3.35 (1.4)) and APRI (0.27 (0.09)) also reflected minimal or no fibrosis (<4.5 and <0.5, respectively). These provocative findings show that this cohort of PN-ALT chronically infected HCV patients had a low stage of fibrosis, based on three non-invasive methods. A previous study has compared and validated these methods in chronic hepatitis C patients with elevated ALT.[7]

Liver biopsy has been used as the "gold standard" for assessment of hepatic fibrosis. It has been used for staging liver damage in chronic viral hepatitis and for decision analysis as to the need for treatment in patients with chronic hepatitis C. The limitations of biopsy, such as patient acceptability, sampling error, or diagnostic inaccuracy, and the remote risk of complications, have led clinical investigators to study alternative methods of staging chronic viral hepatitis.[4 8] Measurement of serum biological markers is the most widely used procedure for estimation of liver fibrosis[8]; combining serum biomarkers with FS may increase the accuracy of these non-invasive methods, suggesting that it may be valid to circumvent the limitations of hepatic histology.[7 8] FS is an objective and safe technique, enthusiastically accepted by patients. Hence periodic examinations can be performed as a follow up protocol for assessment of hepatic fibrosis progression or improvement. Moreover, it is a precise method for detection of cirrhosis and is a promising method of predicting complications of cirrhosis.

Accordingly, our data suggest that therapeutic management of PN-ALT patients could be established according to fibrosis stage detected by successive FS examinations. Those PN-ALT patients with evidence of fibrosis by FS would need to start early antiviral treatment. Although less effective in obese subjects, transient elastography may be very useful for the diagnosis and therapeutic management of PN-ALT chronically HCV infected patients, questioning the need for biopsy.[7 8] Further studies are warranted to evaluate the diagnostic accuracy for staging hepatic fibrosis, the natural history of disease, and the optimum response to combination antiviral therapy. Additionally, it has been demonstrated that combining FS