a foetal tissue response. The organism may also be capable of infecting a living foetus, and there is evidence of this in Case 2.

Infection with *M. hominis* probably more commonly extends only as far as the maternal genital tract, contributing to pyrexia associated with delivery. Of seven patients who aborted and who had *M. hominis* in the vagina, three developed a rise in antibody titre (Table II). These patients had a pyrexial illness, and presumably an infection of the genital tract due at least in part to *M. hominis*. The appearance of growth-inhibiting antibody, which does not persist for long in the circulation, is consistent with recent infection (Jones and Sequeira, 1966). It is of interest to note that when mycoplasmas are introduced into the bovine uterus, endometritis and endosalpingitis are produced (Hartman *et al.*, 1964). Mycoplasmas, as opportunists, may be able to produce similar infections in humans when conditions in the genital tract are favourable.

Summary

The isolation of *Mycoplasma hominis* from aborted foetuses, accompanied by significant levels of maternal antibody, is described. Rises in antibody titre to *M. hominis* were also detected in some patients who had this organism in the vagina at the time of abortion. These findings suggest that infection of the genital tract occurs in association with abortion, and sometimes this infection may involve the foetus. The possibility that such infection may sometimes cause abortion is discussed.

I am indebted to Dr. James Davson for the histological reports, and to Dr. R. W. Burslem and Mr. J. B. Jones, under whose care these patients were admitted.

REFERENCES

Card, D. H. (1959). *Brit. J. vener. Dis.*, **35**, 27.
Clyde, W. A. (1964). *J. Immunol.*, **92**, 958.
Gotthardson, A., and Melén, B. (1953). *Acta path. Microbiol. scand.*, **33**, 291.
Hartman, H. A., Tourtellotte, M. E., Neilsen, S. W., and Plastridge, W. N. (1964). *Res. Vet. Sci.*, **5**, 303.
Jones, D. M., and Davson, J. (1967). *Nature (Lond.)*. In press.
—— and Sequeira, P. J. L. (1966). *J. Hyg. (Lond.)*, **64**, 441.
Lemcke, R., and Csonka, G. W. (1962). *Brit. J. vener. Dis.*, **38**, 212.
O'Berry, P. A., Bryner, J. H., and Frank, A. H. (1966). *Amer. J. vet. Res.*, **27**, 677.
Shepard, M. C. (1954). *Amer. J. Syph.*, **38**, 113.
Stokes, E. J. (1955). *Lancet*, **1**, 276.
Taylor-Robinson, D., Purcell, R. H., Wong, D. C., and Chanock, R. M. (1966). *J. Hyg. (Lond.)*, **64**, 91.

Unusual Case of Mercury Poisoning

H. R. M. JOHNSON,* M.A., M.B., B.CHIR., M.C.PATH., D.M.J.
O. KOUMIDES,* B.SC., PH.D., F.R.I.C.

Brit. med. J., 1967, **1**, 340–341

Poisoning by metallic mercury is extremely rare. A review of the literature of the past 70 years has brought to light only 27 cases. Most of these were accidental, and many of the more recent ones had followed gas-analysis procedures, where mercury was used as a seal in syringes (Lathem *et al.*, 1954; Schulz and Beskind, 1960; Buxton *et al.*, 1965). Others occurred after injury from broken thermometers (Haubrich and Schuler, 1949), or in those working with mercury (Ekert, 1949), or after the rupture of the mercury-filled bag of an indwelling intestinal tube (Lindenmuth, 1949; Crikelair and Hiratzka, 1953), or as a result of inunction of the skin with preparations containing mercury (Rixford, 1895; Stammel, 1929), or in tattoos (Lane *et al.*, 1954). Suicidal attempts by means of metallic mercury are quoted by Umber (1923), Conrad *et al.* (1957), and Schulze (1958). In all these cases the presence of metallic mercury in the tissues was demonstrated by radiography, the mercury being present either at the site of introduction or in the form of emboli. Out of the 27 cases reported, there were only three deaths.

In view of the rarity of the condition, a case of deliberate self-injection of metallic mercury with subsequent death from mercurial poisoning is presented in detail.

Case Report

An intelligent, healthy female laboratory technician aged 23 deliberately injected her own left forearm with between 1 and 2 ml. of unsterilized mercury. Three weeks later her forearm had become tender, red, and swollen, and symptoms of median nerve damage had developed. *X*-ray examination confirmed the presence of mercury in the arm. The left forearm was explored, and between 0.5 and 0.75 ml. of mercury was removed. There was obvious damage to the median nerve. After the exploration increasing fever and pulse rate with muscular spasms and rigidity developed. Four days later her temperature had reached 107.2° F. (41.8° C.), and she was unrousable. A lumbar puncture showed no abnormality. She was intubated and put on a respirator. The next day her arm was re-explored, but no more mercury was found. Necrotic tissue was cultured for *Clostridium tetani*, with negative results. *X*-ray examination of her chest the same day showed mercury emboli throughout both lungs. Her blood urea rose steadily, and she died 31 days after the original mercury injection.

* Department of Forensic Medicine, the London Hospital Medical College, London E.1.

Post-mortem Findings

The whole body was *x*-rayed before dissection. Residual mercury was seen in the left forearm and hand, and multiple fine globules were present throughout both lungs (see Figs. 1 and 2). A few scattered solitary globules were present elsewhere in the body, but none were seen in the brain.

The body was pale and oedematous. There was necrosis of the median nerve in the left forearm. Dissection under low-power magnification showed multiple fine globules of mercury in and around the median nerve sheath and between muscles. The lungs were oedematous, but there were no other naked-eye abnormalities, and no more mercury was seen.

Histologically extensive epithelial necrosis was found in the renal proximal convoluted tubules, which contained eosinophilic debris. There was exudate around many glomeruli beneath Bowman's capsule, and many distal tubules contained altered red cells. In the heart were multiple foci of inflammatory cells with necrosis of myocardial fibres. The blood vessels in all parts of the brain contained rounded bodies staining purple with haematoxylin and eosin, and giving a positive reaction with the periodic-acid–Schiff stain. There was no obvious damage to the nervous tissue of the brain itself, but many anterior horn cells in the spinal cord showed degenerative changes.

Toxicological Analysis.—This was made on necropsy material and on an antemortem sample of urine. The determination of mercury was carried out by means of a micromethod involving the destruction of organic matter by a wet oxidation system followed by subsequent extraction, and colorimetric determination of mercury with dithizone in chloroform, which produces coloured metal chelates (Nielsen Kudsk, 1964). The extinction value of the resulting "mixed colour" was read on a spectrophotometer. The digestate was prepared with mixed sulphuric and nitric acids and completed with potassium permanganate, except in the case of the urine sample, where the digestion was performed exclusively with potassium permanganate and sulphuric acid (Barrett, 1956). The mercury values after extraction were read off from a calibration curve showing extinction values plotted against known control amounts of mercury (Sandell, 1959; Stewart and Stolman, 1961).

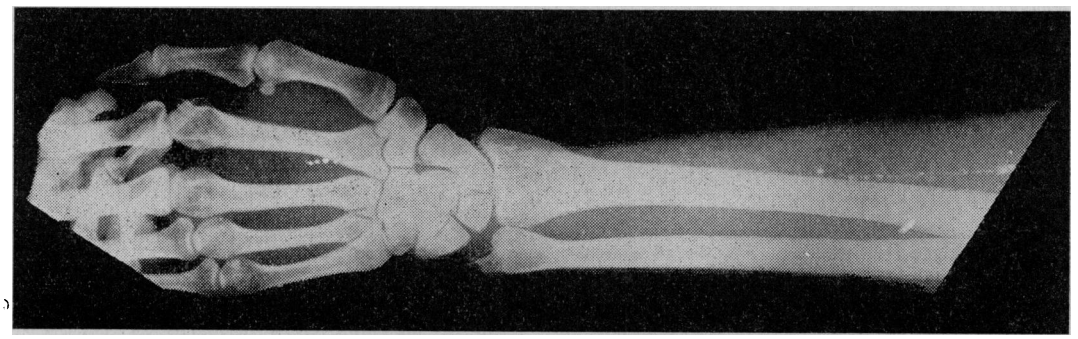

FIG. 1.—Residual mercury in left forearm and hand.

Analysis Results

Blood	1·22 mg./100 ml.	Spleen	0·43 mg./100 g.
Urine	2·51 mg./l.	Heart	0·79 mg./100 g.
Kidneys	6·07 mg./100 g.	Bile	0·21 mg./100 ml.
Liver	1·66 mg./100 g.	Colon	1·80 mg./100 g.
Lungs	11·75 mg./100 g.	Spinal cord	0·04 mg./100 g.

Various Parts of Brain

Occipital lobe	0·34 mg./100 g.	Cerebellum	0·08 mg./100 g.
Thalamus	0·29 mg./100 g.		

Discussion

In many of the cases described in the literature the mercury remained in the body for long periods, even years in some instances. In several cases serial *x*-ray films showed the gradual disappearance of the mercury, but toxicological assessment of its excretion was seldom performed. Where subcutaneous deposits were present they excited an inflammatory response, with abscess formation and the extrusion of globules of mercury. When embolization occurred it was in most cases to the lungs, but in some cases, including our own, the mercury passed through the pulmonary bed into the systemic circulation. It is thought to pass from the right to the left side of the heart via the lungs through shunts or pulmonary capillaries (Ekert, 1950; Conrad *et al.*, 1957; Buxton *et al.*, 1965). The disappearance of the metallic mercury as judged by serial radiography and its excretion in the urine and elsewhere argues its solution in the tissue fluids. Buxton *et al.* suggested that there is a slow ionization of metallic mercury through biological oxidation forming mercuric salts that interfere with the sulphydryl radical in many enzyme systems, and that the salts are excreted largely via the colon, kidneys, and salivary glands.

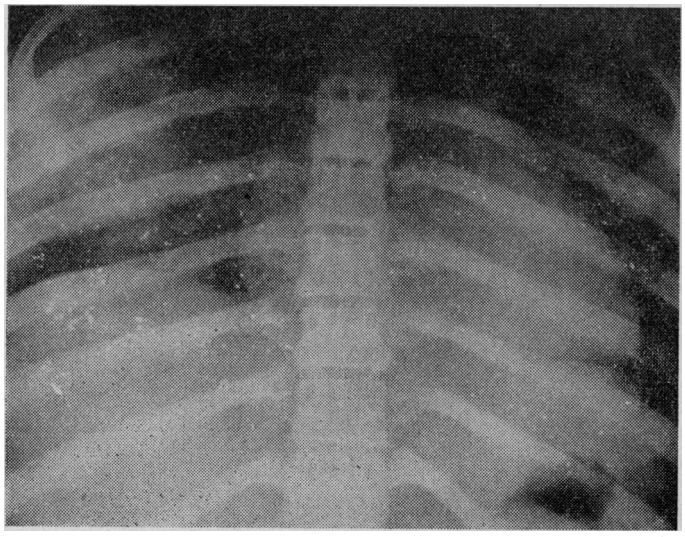

FIG. 2.—Mercury globules throughout both lungs.

It may well be that with the increasing use of gas-analysis procedures more cases of metallic mercury entering the body will occur despite the criticism of the use of mercury as a seal (Buxton *et al.*, 1965).

Summary

The literature on the effects of metallic mercury introduced either deliberately or accidentally into the human body is reviewed, and a case of suicide by the self-injection of metallic mercury is described in detail.

It is suggested that the long-held belief that metallic mercury is non-toxic when introduced into the human body is untrue.

We would like to thank the many colleagues who assisted us and provided information, especially Professor W. I. Cranston, Dr. M. Lea Thomas, Dr. S. J. G. Semple, Mr. W. A. B. Smellie, and Dr. R. D. Peachey, of St. Thomas's Hospital, and Dr. H. Urich, of the London Hospital Medical College. We are grateful to Dr. A. G. Davies, H.M. Coroner for Inner London (South), for permission to publish. Mr. A. J. Hardy, of this department, took the photographs.

BIBLIOGRAPHY

Barrett, F. R. (1956). *Analyst*, **81**, 294.
Buxton, J. T., Hewitt, J. C., Gadsen, R. H., and Bradham, G. B. (1965). *J. Amer. med. Ass.*, **193**, 573.
Conrad, M. E., Sanford, J. P., and Preston, J. A. (1957). *Arch. intern. Med.*, **100**, 59.
Crikelair, G. F., and Hiratzka, T. (1953). *Ann. Surg.*, **137**, 272.
Ekert, F. (1950). *Fortschr. Röntgenstr.*, **72**, 470.
Esau, P. (1924). *Dtsch. Z. Chir.*, **188**, 221.
Haubrich, R., and Schuler, B. (1949). *Fortschr. Röntgenstr.*, **72**, 68.
Hey, R. (1933). *Dtsch. Z. ges. gerichtl. Med.*, **21**, 257.
Holzbach, E. (1947). *Arch. path. Anat.*, **314**, 287.
Konig, E. (1939). *Chirurg*, **11**, 57.
Kudsk, F. N. (1964). *Scand. J. clin. Lab. Invest.*, **16**, 575.
Lancet, 1965, **2**, 1174.
Lane, R. A. G., Berman, H., and Mescon, H. (1954). *Canad. med. Ass. J.*, **70**, 546.
Lathem, W., Lesser, G. T., Messinger, W. J., and Galdston, M. (1954). *Arch. intern. Med.*, **93**, 550.
Leschke, E. (1934). *Clinical Toxicology*, translated by C. P. Stewart and O. Dorrer, p. 33. London.
Lindenmuth, W. W. (1949). *J. Amer. med. Ass.*, **141**, 986.
Richter, E. (1910). *Berl. klin. Wschr.*, **47**, 1588.
Rixford, E. (1895). *Occid. med. Tms*, **9**, 415.
Sandell, E. B. (1959). *Colorimetric Determination of Traces of Metals*, 3rd ed., p. 635. London.
Schulz, E., and Beskind, H. (1960). *J. Pediat.*, **57**, 733.
Schulze, W. (1958). *Fortschr. Röntgenstr.*, **89**, 24.
Sitson. Quoted by Umber (1923).
Stammel, C. A. (1929). *Milit. Surg.*, **65**, 529.
Stewart, C. P., and Stolman, A. (1961). *Toxicology*, **2**, p. 676. London.
Umber, F. (1923). *Med. Klin.*, **19**, 35.