REFERENCES

1. MALLORY, G. K., WHITE, P. D. AND SALCEDO-SALGAR, J.: *Am. Heart J.*, 18: 647, 1939.
2. MARIE, R.: L'infarctus du myocarde et ses conséquences. Thèse pour Doctorat en Médecine, Faculté de Médecine de Paris, Georges Carré et cie, 1896.
3. SCHLESINGER, M. J. AND REINER, L.: *Am. J. Path.*, 31: 443, 1955.

RÉSUMÉ

On ne peut prétendre que l'infarctus dans le myocarde soit remplacé par du tissu de granulation sans donner une fausse impression de la réalité. A la région périphérique d'un infarctus se trouve une lisière de tissu dans laquelle le stroma survit. Dans cette lisière le muscle mort est rapidement absorbé, l'absorption étant complétée vers le dixième jour. L'endomysium qui reste se condense graduellement en perdant son liquide d'œdème, mais il n'y a aucune croissance de tissu conjonctif ou vasculaire qui pourrait former une cicatrice. La partie centrale de l'infarctus est absorbée plus lentement par les macrophages et sa trame d'endomysium est envahie par les fibroblastes et les cellules endothéliales. Les fibres réticulaires s'épaississent et deviennent hyalines avec le temps mais conservent leur orientation et peuvent être retracées dans les coupes transversales. Le tout illustre la remarquable capacité d'un organe à s'adapter à une infirmité avec relativement peu de perturbation dans sa structure et aucune interruption dans sa fonction. La période de repos devrait être déterminée beaucoup plus d'après l'évaluation clinique de la fonction cardiaque que d'après les altérations histologiques.

THE REVERSIBILITY OF ATHEROSCLEROSIS*

G. C. WILLIS, D.T.M.&H., M.R.C.P.(Edin.), F.R.C.P.[C.], *Montreal*

THE QUESTION whether or not it is possible for experimentally induced atherosclerotic plaques to be resorbed has been investigated several times. An early study by Anitschkow[1] indicated that withdrawal of cholesterol from cholesterol-fed rabbits was followed by a gradual disappearance of lipid from the plaques. In large plaques it took two to three years for this to occur. In a recent study by McMillan and his colleagues[2] along the same lines, histological reorganization of plaques was noted but no decrease in arterial lipid content was detected chemically in animals killed at intervals up to six months. Indeed, their work demonstrated that atherogenesis in the cholesterol-fed rabbit proceeds for some time after withdrawal of cholesterol from the diet. They attribute this to the persistence of hyperlipæmia, the etiological mechanism in this experimental procedure. This explanation would appear to be valid, as it is well recognized that atherosclerosis of cholesterol feeding is accompanied by extensive lipid deposits throughout the body, particularly in the reticulo-endothelial system. Except in such conditions as xanthomatosis, this state of cholesterol saturation has no counterpart in atherosclerosis in man.[3] It is not etiological in human atherosclerosis and does not offer a barrier to resorption of plaques in the way that it does in the cholesterol-fed rabbit.

Any approach to the study of resorption of atherosclerosis in experimental animals should thus have as its basis a method of inducing atherosclerosis without cholesterol feeding. As this has now become possible through the medium of scurvy in the guinea-pig,[4] ascorbic acid treatment of such animals forms an ideal means of studying the reversibility of atherosclerosis.

MATERIALS AND METHODS

A total of 77 male and female adult guinea-pigs was rendered scorbutic in the manner described in a previous communication.[4] After intervals of from 21 to 30 days, 50 of these animals were given ascorbic acid therapy and the remaining 27 were sacrificed. Ascorbic acid therapy consisted of a single intraperitoneal injection of 75 mg. of sodium ascorbate followed by the liberal addition of ascorbic acid powder to the basic scorbutogenic diet. The animals in this treated group were then sacrificed at intervals of time varying from 1 to 27 days.

Twelve additional animals employed as controls were placed on the scorbutogenic diet for 42 days, with powdered ascorbic acid liberally added from the beginning.

All animals were sacrificed by stunning and the thoracic aorta was dissected out and fixed in 10% formalin. Frozen sections were then made through the aortic arch and ascending and descending portions. As many sections as possible were obtained from each aorta and stained with Scharlach R for lipid.

The extent of deposition of stainable lipid in the aortic intima was graded as in the previous communication (i.e., + represented the earliest deposit of lipid, ++++ was solid filling of the intima with lipid, and ++ and +++ were intermediate). Careful note was made as to the morphology of the plaques under the different experimental circumstances.

RESULTS

No atherosclerosis was found in the control group of animals. The number of animals with

*From the Department of Medicine and the University Clinic of the Montreal General Hospital.

TABLE I.—INDICATING THE NUMBER OF ANIMALS IN THE VARIOUS EXPERIMENTAL GROUPS WITH AND WITHOUT ATHEROSCLEROSIS AND THE DEGREE OF THE LESIONS IN THOSE SHOWING THEM

Experiment	*Total animals*	*With atherosclerosis*	*Without atherosclerosis*	*Average degree of atherosclerosis*
Scorbutogenic diet 42 days with ascorbic acid added from the beginning	12	0	12	0
Scorbutogenic diet for periods of from 21 to 30 days	27	11	16	2.5+
Scorbutogenic diet for 21 to 30 days, then ascorbic acid for 1 to 5 days	25	9	16	2.5+
Scorbutogenic diet for 21 to 30 days, then ascorbic acid for 7 to 27 days	25	7	18	2.5+

atherosclerosis in the various groups and the average degree of their lesions is set forth in Table I. Variations in the morphology of the lesions were as follows:

Atherosclerotic Lesions of Scurvy

The earliest lesions were characterized by a diffuse deposit of stainable lipid along the internal elastic membrane and in the immediately adjacent intima. This staining faded out gradually at the extremities of the plaques, blending into apparently intact internal elastic membrane. A heaping up of lipid in the middle portion of such early lesions eventually extending to involve the whole thickness of the intima was seen in the intermediate and advanced plaques (Fig. 1). Macrophages were noted in small numbers only. Each individual plaque appeared as a confluent mass of stainable lipid with no fat-free areas associated.

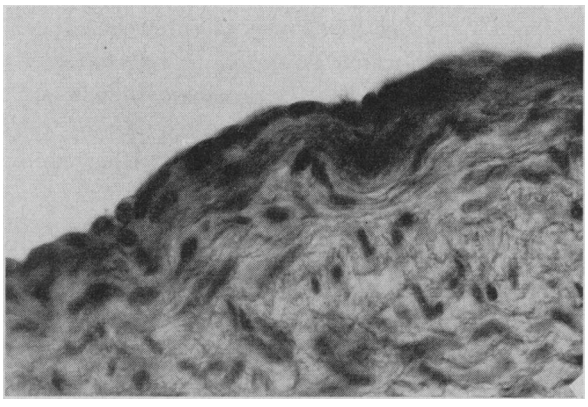

Fig. 1.—High power view of an early atherosclerotic lesion in a scorbutic guinea-pig. The dark internal elastic membrane and adjacent intima represents stained lipid (Scharlach R).

Atherosclerotic Lesions of Treated Scurvy

After as little as two days of ascorbic acid therapy, the early atherosclerotic plaques stained less intensely with Scharlach R and soon lost their diffuse lipid deposit completely. Numerous macrophages meanwhile became apparent, some on the intimal side of the internal elastic membrane and some on the medial side (Fig. 2). All these macrophages stained intensely for fat. Later stages of the process were characterized by a decrease in the bulk of lipid within macrophages. The end stages of lipid resorption were not detected, as this degree of atherosclerosis appeared to heal rapidly without permanent sequelæ.

Advanced lesions of atherosclerosis presented quite a different pattern, being considerably more resistant to resorption. After a period of about seven days, large plaques were found to be no longer a confluent mass of lipid filling the intima. Instead, the lipid was aggregated into separate islands with lipid-free areas intervening (Fig. 3). Sometimes such islands had a few macrophages around them but often none were noted. Sometimes there appeared to be diffusion of lipid into the inner layer of the arterial media. Even after a further period of nine days, very little further change could be noted in such plaques. Although animals killed as long as 27 days after the initiation of ascorbic acid therapy

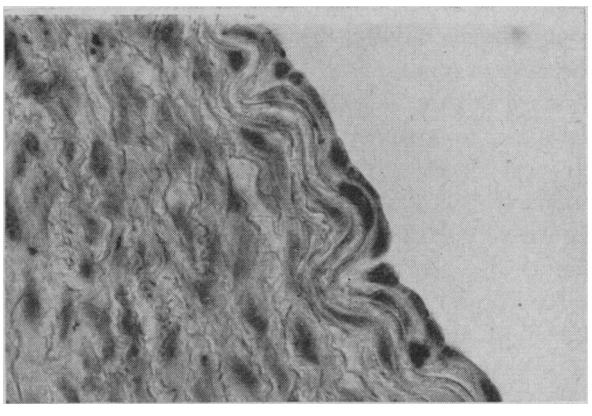

Fig. 2.—High power view of a plaque similar to that shown in Fig. 1. This plaque is undergoing resolution under the influence of two days of ascorbic acid therapy. Note that the extracellular stainable lipid is almost all gone while several lipid-laden macrophages are seen in apposition to the internal elastic membrane both on its intimal and medial surfaces (Scharlach R).

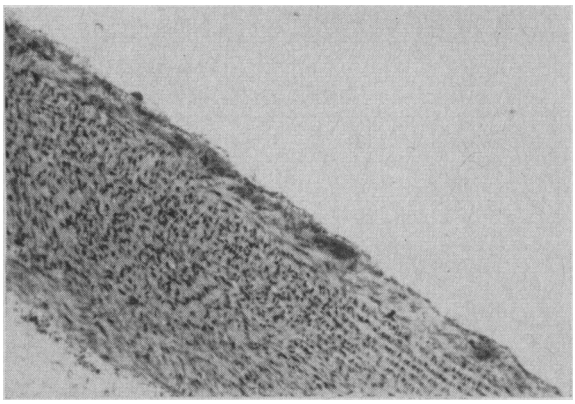

Fig. 3.—A low power photomicrograph of an advanced lesion of atherosclerosis in a formely scorbutic guinea-pig. This animal received ascorbic acid therapy for 16 days. The lipid is now collected in pools with areas of lipid-free intima intervening.

showed no lesions, the number of such animals was too small to warrant the conclusion that all lesions are reversed in this time. It was true, however, that there was a steady decline in the incidence of lesions in direct proportion to the duration of therapy.

DISCUSSION

The obstacle of hyperlipæmia, which has thwarted the studies of resorption of lipid from atherosclerotic plaques of the cholesterol-fed rabbit, was avoided in this study and some insight was gained into the reversibility of atherosclerosis comparable to the human type.

The results of this investigation indicate that early lesions of atherosclerosis are quickly resorbed. The stages in this process are first a fading of lipid staining in the region of the internal elastic membrane with later a disappearance of all extracellular fat. Active phagocytosis of lipid by macrophages occurs, and when these macrophages finally disappear no evidence of the lesion remains.

More advanced lesions are considerably more resistant to reversal. Extensive lipid deposits clear in some parts of a plaque but islands of intensely staining lipid persist in other parts. The macrophage response to such areas is only slight.

Assembling all these various phases of reversal of the atherosclerotic plaque, a certain impression is gained as to the mechanism involved. It would appear that lipid diffusely deposited in the intimal ground substance is easily resorbed. Such resorption is rapid, and as it is associated with a macrophage response of only moderate degree, it may well be that a portion of the lipid is dealt with in some other way. The independent islands of lipid observed in the healing of advanced plaques appear to be no longer in a stratum of ground substance nor are they intracellular. Rather they seem to be inert pools of fat similar to the "cholesterol abscesses" described in human atherosclerosis. Only the surface area of such pools is in contact with resorptive processes and this may account for their resistance to healing.

The reversibility of human atherosclerosis is, of course, a vital question. Following the observation that total ascorbic acid depletion is common in human arteries[5] and that ascorbic acid therapy is able to replace this deficit,[5] it was possible to make some correlation of human atherosclerosis with that observed in the scorbutic guinea-pig. On this basis, human atherosclerosis was studied by serial arteriography in 16 cases.[6] Ten of these cases received ascorbic acid therapy and six were untreated. Of the 10 treated cases, the plaques visualized radiologically became larger in three, remained unchanged in one and became smaller in six. There was no diminution in the size of the plaques in any of the six untreated cases while in three of them they became bigger.

It seems likely that the histological changes associated with resorption of atherosclerosis in the human would be along the lines observed in this present study with guinea-pigs.

SUMMARY

Former studies into the reversibility of experimentally induced atherosclerosis had been seriously hampered by the persistence of the hypercholesterolæmia essential for the production of the lesions. This hypercholesterolæmia actually causes atherogenesis to proceed even when cholesterol feeding is stopped.

In the present study this difficulty is avoided by employing scorbutic guinea-pigs in which it had previously been shown that atherosclerosis develops rapidly without cholesterol feeding. When ascorbic acid is given to scorbutic guinea-pigs, the early atherosclerotic lesions resorb quickly. The advanced lesions are considerably more resistant to reversal, apparently because of the islands of lipid whose only contact with the resorbing process is at the surface.

A correlation is made between the atherosclerosis of the scorbutic guinea-pig and that

observed in man, and the results of a previous study of ascorbic acid therapy in human atherosclerosis are quoted.

The author would like to thank Dr. J. E. Pritchard and Dr. W. H. Mathews of the Department of Pathology, The Montreal General Hospital, for their kind advice and frequent help and the unstinted use of the facilities of their department.

He would also like to express his appreciation to Miss Dorean Slessor of the Department of Pathology, who kindly made the histological preparations.

This study was supported by the Cooper Research Fund of McGill University.

References

1. Anitschkow, N.: *In*: Arteriosclerosis, edited by E. V. Cowdry, The Macmillan Company, New York, 1933, p. 291.
2. McMillan, G. C., Horlick, L. and Duff, G. L.: *A.M.A. Arch. Path.*, **59**: 285, 1955.
3. Duff, G. L.: *Arch. Path.*, **20**: 81, 257, 1935.
4. Willis, G. C.: *Canad. M. A. J.*, **69**: 17, 1953.
5. Willis, G. C. and Fishman, S.: *Ibid.*, **72**: 500, 1955.
6. Willis, G. C., Light, A. W. and Gow, W. S.: *Ibid.*, **71**: 562, 1954.

Résumé

Les résultats des travaux faits jusqu'à présent sur la réversibilité de l'athérome expérimental peuvent être mis en doute à cause de la persistance de l'hypercholestérolémie nécessaire à la production de ces lésions. Cette hypercholestérolémie stimule l'athérogénèse même une fois que l'apport de cholestérol dans le diète est supprimé. Cette difficulté a été contournée dans le présent travail par l'emploi de cobayes scorbutiques chez qui il a déjà été démontré que l'athérome apparait rapidement même sans apport particulier de cholestérol dans la diète. Lorsque l'on administre de l'acide ascorbique à ces animaux les lésions athéromateuses d'origine récente se résorbent rapidement. Les lésions avancées sont beaucoup plus tenaces apparemment à cause des îlots de lipide dont le seul contact avec le processus de réabsorption est par la surface. L'auteur compare les lésions d'artériosclérose chez le cobaye et chez l'home; il se réfère à des données obtenues précédemment dans le traitement de l'artériosclérose humaine par l'acide ascorbique.

1000 CASES OF TONSILLECTOMY IN A PREPAYMENT PLAN: PREOPERATIVE AND POSTOPERATIVE HISTORY*

HARDING leRICHE, B.Sc., M.D., Ch.B., M.P.H., F.S.S.† and
W. B. STIVER, M.D., D.P.H.,‡ *Toronto*

Present Study

The material of the present study was extracted from the records of Physicians' Services Incorporated, Ontario. The assumption was made that physicians would list all tonsillectomies and that they would note all claims made for diseases connected with tonsillectomy. Since physicians are paid on a fee-for-service basis, it is improbable that they would omit to send details of the work they have done.

In order to obtain a picture of the prevalence of tonsillectomies in the various counties and districts of Ontario, a record was made of all tonsillectomies carried out under the comprehensive P.S.I. Plan—that is, the Medical, Surgical and Obstetrical Plan—during the period February to July 1955.

The number of tonsillectomies during the six months was 4281, giving an annual rate in 1955 of 19.8 per thousand. As on May 1, 1955, the P.S.I. comprehensive plan covered 449,131 participants in Ontario and 21,980 outside the province. Table I gives the annual tonsillectomy rate per thousand participants in those 12 counties and districts in Ontario which had more than 10,000 participants.

TABLE I.—Annual Tonsillectomy Rates Based on a Six-Months' Study (February to July 1955) of the P.S.I. Comprehensive Plan. Twelve Counties of Ontario Each Having More Than 10,000 Participants

Rank order	*County or district*	*Annual tonsillectomy rate per 1000 participants*
1	Thunder Bay	29.0
2	Lambton	24.2
3	Lincoln	24.0
4	Sudbury	23.6
5	Ontario	20.7
6	Wentworth	18.6
7	Welland	17.4
8	Cochrane	13.8
9	York	13.6
10	Carleton	6.1
11	Halton	5.0
12	Kenora	3.5
	All Counties in Ontario	19.8

Because of the large numbers involved, these rates are stable and reliable. This table indicates the wide variation in the tonsillectomy rate in Ontario. Thunder Bay leads with a rate of 29 per thousand, and Kenora is the lowest with a

*Read at the Annual Meeting of the Ontario Medical Association, Toronto, May 7-11, 1956.

†Research Medical Officer, Physicians' Services Inc., Toronto.

‡Medical Director, Physicians' Services Inc., Toronto.