until a representative section is obtained. (The blade is moistened with soap solution or water.) With some care a very thin section can be cut. It can then be removed with the finger-tip into a shallow vessel containing one per cent sodium chlorid solution. From this it is quickly removed to another shallow vessel containing Unna's polychrome methylene blue solution or some modified stain. Here it remains ten to thirty seconds; from there it is removed with a small glass rod to another vessel containing one per cent sodium chlorid solution, where it is quickly washed, rolled out on a glass slide and covered with a cover slip. The tissue can then be examined under the low- and high-power magnifications of an ordinary microscope.

With practice, considerable dexterity will be gained, and reasonably satisfactory microscopic sections made. No originality is claimed for this method. It offers an easy scheme of examination, and should be of some advantage to the isolated surgeon. Most of us have spent weary hours in pathology and histology courses, familiarizing ourselves with the microscopic appearance of normal and diseased tissues. After graduation, very little of this training can be of use, because only for a few are the services of a large laboratory readily available.

Johnston Clinic.

MESENTERICO—PARIETAL HERNIA

REPORT OF CASE

By Frederick S. Foote, M.D.
San Francisco

CONGENITAL defects of the intestinal tract, which result in obstruction, involve mainly the midgut. This embryologic division corresponds, in the fully developed bowel, to the portion between the duodenojejunal junction and the middle of the transverse colon. It is the portion of the bowel which is involved in rotation in the embryonic period to reach its final position in the fully developed abdominal cavity.

Obstructions result from three primary abnormalities of this process in the embryo. The first, and most common, is incomplete rotation, in which the cecum and appendix fail to descend to the right lower quadrant; may remain, in fact, in the upper abdomen or even in the left abdomen.

The second abnormality is reverse rotation, which results in the duodenum being placed anterior to the transverse colon, with obstruction of the colon. Volvulus of varying amounts of small bowel, as well as cecum and ascending colon, also occurs as a complication of reverse rotation.

The third anomaly is failure of the rotated bowel and its primitive mesentery to fuse to the posterior abdominal wall. This third condition predisposes to intussusception, volvulus and internal or mesenterico-parietal hernia.

These anomalies were pictured and described in detail by Dott [1] in 1923.

Mesenterico-parietal hernia, also known as duodenal hernia of Treitz,[2] is formed when a portion of small bowel becomes confined between this unfused primitive mesentery and the posterior abdominal wall. It is most likely to occur when rotation has been completed and when the large bowel has fused in the proper place, but when the primitive mesentery of the large and small bowel has failed to fuse. This condition leaves an opening through the mesentery of the small bowel either to right or left into a closed space, bounded posteriorly by the posterior abdominal wall; anteriorly by the primitive mesentery (two layers of peritoneum); laterally by large bowel and medially by the defective mesentery of the small bowel containing the superior mesenteric artery. The opening through the mesentery passes between the superior mesenteric artery above and the fixed point at which the terminal ileum and cecum are fused below.

Usually most of the small bowel is contained in the sac and is very often adherent within. Whether the small bowel is caught in this space during embryonic life or gains access to it after development is complete, is not clear. The fact that a number of them have manifested themselves by intestinal obstruction in new-born infants suggests that the former is true in at least some of the cases.

The clinical picture of those patients found to have such herniae during active life is essentially that of intestinal obstruction. In some instances a soft mass has been noted over the region of the sac. This mass, when noticed, has usually been mistaken for an enlarged spleen, for liver or for a true tumor.

A third group of mesenterico-parietal herniae are found at autopsy in patients dying of other causes. Most of these patients are not suspected of having herniae; nor have they symptoms of intestinal stasis. Such were the two cases recently reported by Longacre.[3] One of these patients, suffering from pulmonary tuberculosis, exhibited a mass in the left abdomen thought to be enlarged spleen. This mass was later shown at autopsy to be the hernial sac containing most of the small bowel. Longacre reviewed the literature, finding 140 cases reported to date. In 105 of these the hernia was on the left side, and in thirty-five on the right. Of the cases treated surgically, only five were diagnosed as internal hernia before operation.

REPORT OF CASE

The case which I wish to report is one of right-sided, mesenterico-parietal hernia. The patient, a male laundry foreman, forty-six years of age, was suffering from cramp-like abdominal pain, nausea and vomiting, and was referred by his physician with a diagnosis of intestinal obstruction. The onset, approximately sixty hours before being seen, was characterized by nausea and mild, cramp-like pain in the left upper abdomen. This was relieved at first by rest and abstinence from food. However, during the last twenty-four hours of the sixty he had abdominal distention, vomiting and severe left upper quadrant pain, radiating to the region of the umbilicus. Saline cathartics were vomited, and enemata resulted in expulsion of gas and a small amount of fecal material. A dose of castor oil accentuated the pain. These measures were taken of his own accord. In the past he had never had serious trouble. He remembered that once or

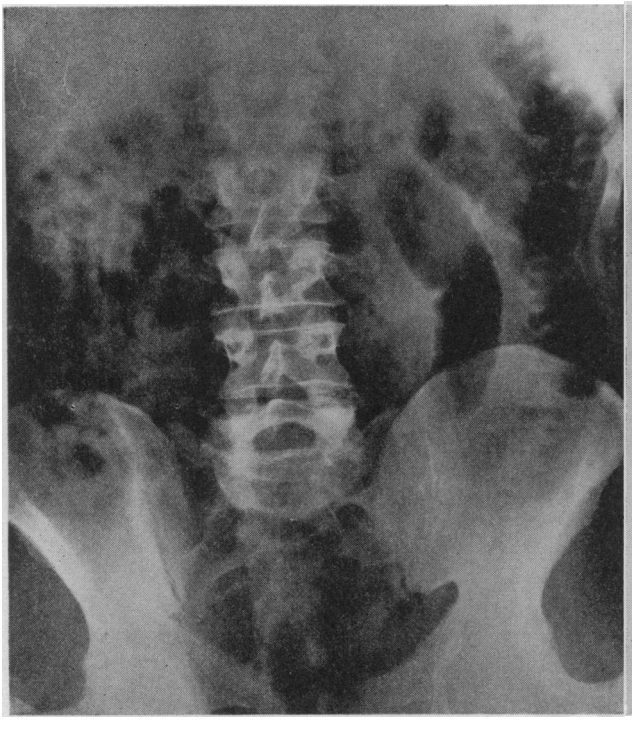

Fig. 1

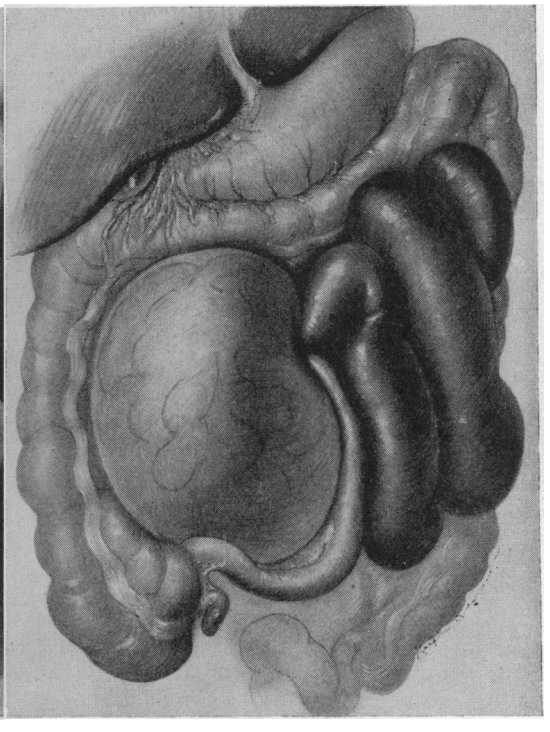

Fig. 2

Fig. 1.—Plain plate of the abdomen, taken with the patient in the upright position. The dilated loops of small bowel are shown in the left upper quadrant.

Fig. 2.—Right sided mesenterico-parietal hernia with obstruction. The obstructed bowel is shown in the left abdomen, while the collapsed loops of small bowel may be seen through the transparent wall of sac in the right abdomen.

twice a year, following extra hard work or a heavy meal, he had had abdominal cramps, which were relieved by rest, abstinence from food, and a cathartic.

Physical examination revealed no abnormalities other than those of the abdomen. Here was a definite, localized distention confined to the left upper quadrant. This area was tympanitic, with no localized dullness, no succussion splash. Peristalsis was audible, but not excessive. Pressure over the area caused pain in the region of the umbilicus.

Rectal examination revealed no masses and no blood. There was no blood in the vomitus. The leukocyte count was slightly elevated. The urine was normal except for increased concentration. His temperature was normal.

A plain x-ray picture of the abdomen, showing dilated loops of small bowel in the left upper quadrant is reproduced here (Fig. 1). There were no fluid levels in these loops. The diaphragm appeared intact throughout.

The abdomen was explored, under ether anesthesia, through a left upper rectus incision. There was a small amount of free, slightly turbid fluid. Three dilated bluish loops of proximal jejunum were exposed immediately beneath the incision. In the right abdomen many collapsed loops of small bowel could be seen confined beneath a transparent membrane. The normal omentum and transverse colon overlay these. The dividing line between the dilated bowel on the left and collapsed bowel on the right was the mesentery of the small bowel. The most dilated loop was followed with the finger to the root of the mesentery, where gentle traction suddenly released it. The collapsed bowel then followed this loop out through an opening in the mesentery. Content of obstructed loop readily flowed past the point of obstruction into collapsed loops. The point of constriction was due to outside pressure by the neck of the sac. It was approximately one meter from Treitz's ligament. The rest of the small bowel, with the exception of about 20 centimeters of the terminal ileum, was within the sac. The ileum was adherent to the neck of the sac at the point of emergence. Otherwise it was quite free and easily delivered from the sac. After the sac was emptied, the neck was found to be six centimeters in diameter, and placed four centimeters below the upper extent of the mesentery. The part of the mesentery above the neck was very thick and contained the superior mesenteric artery. The cecum and colon were fixed in normal position. The sigmoid was not especially redundant. The appendix was in normal position. There was no Meckel's diverticulum. The course of the blood supply to the terminal ileum and cecum was not determined, but the vessels did not course over the surface of the sac. The position and fixity of the spleen was not noted.

The drawing on Plate 2 shows the condition. It was drawn by the artist, from my description and from the x-rays (Fig. 2).

After the bowel was freed, the opening into the sac was closed with interrupted sutures of silk. The wound was closed with catgut.

No cultures were taken of the peritoneal fluid, but a colon bacillus infection of the subcutaneous fat of the wound probably had its origin from this fluid or from the surfaces of the badly distended bowel.

Postoperatively, for three days the patient suffered from generalized abdominal distention, which then subsided. The infected wound was healed at the end of three weeks, with the exception of a small area of superficial granulation tissue, and the patient was able to go home.

It is now six months since operation, and during this time the patient has resumed his occupation and has had no further difficulty.

490 Post Street.

REFERENCES

1. Dott: Brit. J. Surg., 11:251, 1923.
2. Treitz, W.: Hernia Retroperitonalis, Prague, 1857.
3. Longacre, J. J.: Surg. Gynec. and Obst., 59:165, 1934.