CALIFORNIA AND WESTERN MEDICINE

Owned and Published Monthly by the California Medical Association
FOUR FIFTY SUTTER, ROOM 2004, SAN FRANCISCO
ACCREDITED REPRESENTATIVE OF THE CALIFORNIA AND NEVADA MEDICAL ASSOCIATIONS

VOL. 41 NOVEMBER, 1934 No. 5

CARCINOMA OF THE LARYNX*

OBSERVATIONS ON CASES TREATED BY PROTRACTED (COUTARD) ROENTGEN THERAPY

By L. H. GARLAND, M. D.
San Francisco

DISCUSSION *by William E. Costolow, M.D., Los Angeles; Harold A. Fletcher, M.D., San Francisco; Robert S. Stone, M.D., San Francisco.*

IN dealing with malignant tumors of the larynx, as in dealing with malignant tumors anywhere in the body, it is generally agreed that there is no surer method of cure than complete and total excision. It is also generally agreed that complete and total excision of some tumors is impossible, for the simple and obvious reason that the tumor, by the very nature of its malignancy, is no longer confined to a small area, but has spread into neighboring and perhaps vital tissues. There is a second factor which renders the total and adequate excision of a tumor undesirable, and that is the amount of disability produced by the operation. There are few more disabling operations than total laryngectomy; there are few greater disappointments than the development of recurrence after the performance of so severe an operation, and recurrence is sufficiently common for us to question the efficacy of operation except in strictly localized epitheliomas of the vocal cord.

COUTARD'S STUDIES

Since 1931, when Coutard[3] published the results obtainable in the treatment of various malignancies of the pharynx and larynx, there has been widespread interest in the application of prolonged, carefully measured roentgen radiation to such lesions. So thorough was his work, and so carefully controlled his results, that, to give radiation therapy adequate trial, some clinics, notably one of the largest surgical clinics in Vienna, have ceased entirely from operating for carcinoma of the larynx. Coutard's method is based on the well known fact that cells in a state of active mitosis are much more radiosensitive than cells in a resting stage. In general, therefore, tumor cells are more sensitive to radiation than normal cells. By prolonging the time during which a given dose of radiation is applied, more tumor cells will be damaged in a dividing phase than if the dose is given over a short period. Also, the fact, that normal cells recover from the effects of radiation more quickly and more thoroughly than tumor cells, is made use of in protracted radiation, the tissues tolerating a much larger dose than they would were it given in a short time. We do not know the exact period of time during which all of the cells of a given tumor will be in a stage of division, but clinical results suggest that it is about two weeks. However, since doses large enough to destroy all of the tumor cells cannot be safely given to adequately large, nonsuperficial areas in a two-week period, it is common to have to extend the course of radiation to a four- or even six-week period. During that time, small or moderately-sized doses of x-rays are given daily to a variable number of fields about the neck, depending upon the size and location of the tumor. It is believed by some clinicians, including Coutard, that thick filters are of value in eliminating the softer components of the beam of rays; but results in other clinics, notably the Memorial Hospital clinic,[6] suggest that it is the long time and large total dose, rather than the thickness of the filter, which is effective.

Since the radiosensitivity of epithelial tumors diminishes with increasing differentiation and keratinization of the cells, tumors arising from different areas of the pharynx and larynx react differently to radiation therapy. Transitional epithelium is the most sensitive, and highly keratinized epithelium is the least sensitive. The order of radiosensitivity of tumors of this area is said[5] to be as follows: small cell lymphosarcomas, reticulum cell sarcomas, lympho-epitheliomas, transitional cell carcinomas, undifferentiated squamous epitheliomas, and pearl-forming differentiated epidermoid epitheliomas (see Table 1). The failure or success of roentgen therapy also depends on the extent of the tumor, the presence or absence of infection, the existence of invasion of bone or cartilage, and the general condition of the patient.

---

* From the Stanford University Service at the San Francisco Hospital, Department of Public Health and Stanford University Medical School, San Francisco.

Read before the San Francisco County Medical Society, April 10, 1934.

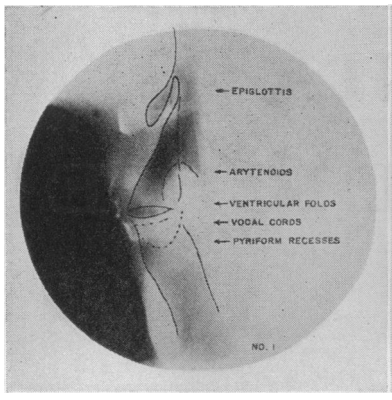

Fig. 1

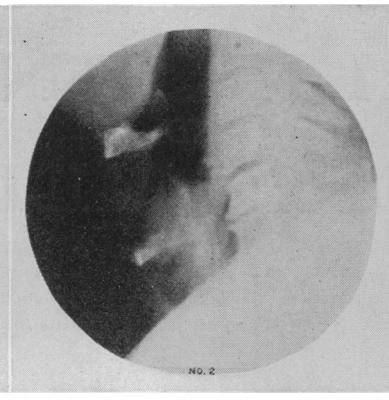

Fig. 2

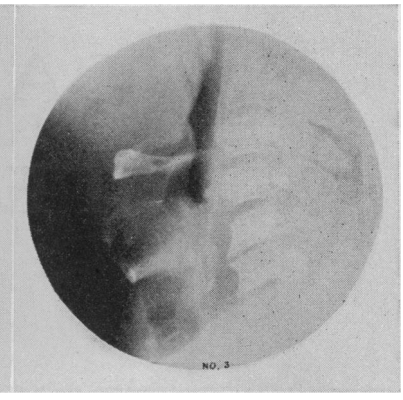

Fig. 3

Fig. 1.—Normal larynx, adult male. Note the ample dark air shadow between the middle of the epiglottis and the arytenoid eminences. Note the ample air shadow of the laryngeal ventricles (actually only the spaces between the false and true cords are normally thus air-filled, the upper recesses of the ventricles being collapsed).

Fig. 2.—Case 2. Well differentiated epithelioma of the left vocal cord involving both arytenoids. Hoarse for two years. Note that the tumor is an intrinsic lesion, and that the upper air shadow (in the region of the vestibule or aryepiglottic folds) is not encroached upon. This patient had a tracheotomy one week before making this film, the tube being removed just before exposure.

Fig. 3.—Case 2. After treatment. Voice satisfactory. Tracheotomy wound healed.

Infection and poor general health are liable to result in failure.

TISSUE REACTION TO PROTRACTED ROENTGEN THERAPY

In the average case of carcinoma of the larynx receiving a protracted course of roentgen therapy, the skin over the area being treated becomes very reddened and inflamed during the third or fourth week of therapy; in properly administered courses, the skin then develops a weeping exfoliation and the entire thickness of the epidermis over the area treated peels off. The corium and subcutaneous tissues are not destroyed, however, and within another two weeks complete regeneration of the epidermis, from the outside of the irradiated area inwards, develops. The fact that no other tissues are dissolved or necrosed differentiates this benign "epidermitis" from the undesirable and sometimes disastrous roentgen necrosis.

Shortly before, or coincident with the development of this epidermitis or epidermiolysis, the mucosa of the underlying larynx develops a membranous inflammatory reaction known as an "epithelitis" or "mucositis." This mucosal reaction is similar to that occurring in the skin and is followed by equally rapid resolution. At the same time, it is common for the patient to lose some weight and to develop moderate dysphagia. The weight normally returns rapidly following cessation of treatment.

LENGTH OF TREATMENT IN COUTARD PROCEDURE

Coutard believes it is always necessary to treat patients until a marked radio-epithelitis has developed. If the tumor has entirely disappeared by that time, and if its histological appearance suggests that it is of a very anaplastic type, treatment is discontinued. If, on the other hand, it is of a highly differentiated type, treatment may be continued; the duration of further treatment and the extent of further dosage depends upon personal judgment and experience. The main danger is apparently that of giving an overdose to the con-

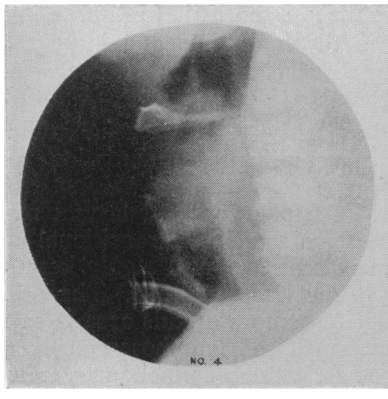

Fig. 4

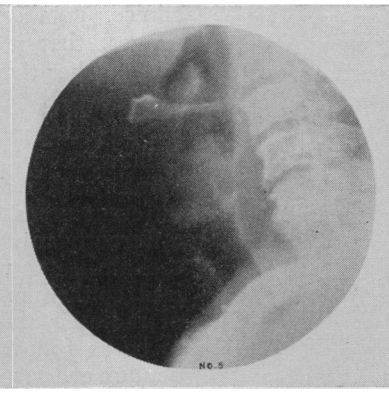

Fig. 5

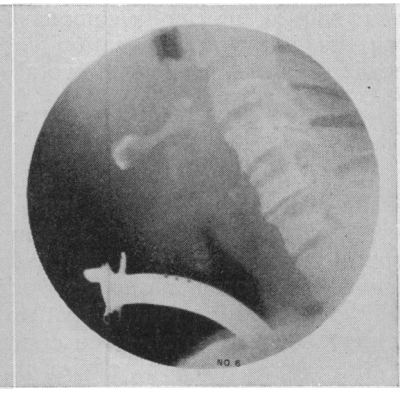

Fig. 6

Fig. 4.—Case 3. Epithelioma right vocal cord involving base of epiglottis and both arytenoids. Extensive encroachment of upper laryngeal air passage. Emergency tracheotomy.

Fig. 5.—Case 3. After treatment. Air shadow of vestibule practically normal. Slight residual edema of arytenoid areas. Voice normal.

Fig. 6.—Case 8. Massive epithelioma of larynx, recurrent postoperative. Tumor extending from apex of epiglottis and base of tongue down to 2 centimeters below the vocal cords. Note that the vertical extent of the tumor can best be shown by roentgen examination. This tumor shrank over 50 per cent following the course of roentgen therapy, and the patient was able to "speak" for some months. He later developed bronchopneumonia and died.

TABLE 1.—*Classification of Carcinomas of the Larynx According to Extent and Type*

Stage I	Small localized tumor (not over 1 centimeter in extent), usually intrinsic and often confined to one vocal cord.
Stage II	Medium sized, clinically localized tumor (not over 4 centimeters in extent), usually largely, if not entirely, intrinsic.
Stage III	Large tumor (over 4 centimeters in extent), often both intrinsic and extrinsic and associated with probable, if not definite, cervical adenopathy.
	(Note: For purposes of summarizing results in subsequent tables the suffix A equals non-operated case and suffix B equals recurrent postoperative case.)
Well differentiated carcinoma	A squamous cell epithelioma (epidermoid carcinoma) composed chiefly of differentiated cells, showing much keratinization and pearl formation. Often arises from the true vocal cords, the glosso-epiglottic recess and lateral pharyngeal wall. Usually "radioresistant," i. e., requiring very large doses to cure; usually metastasizes to glands late. Commonly graded 1 and 2.
Poorly differentiated carcinoma	A squamous cell epithelioma (epidermoid carcinoma) composed chiefly of transitional epithelium, or poorly differentiated squamous cells, showing no keratinization. Often arises from the superior or false vocal cords, the aryepiglottic area, the pyriform sinus or the posterior pharyngeal wall. Usually not "radioresistant"; sometimes metastasizes to glands early. Commonly graded 3 and 4.
	(Note: Lymphoepitheliomas or squamous cell tumors arising in contact with lymphoid tissue may be occasionally confused with large extrinsic laryngeal tumors. They are usually radiosensitive and on shrinkage will reveal their true point of origin (such as the base of the tongue).

nective tissue, and thereby delaying or preventing complete healing. Extreme overdosage is, of course, followed by necrosis, even of bone and cartilage. Coutard believes that the mucous membrane must receive approximately 2,500 roentgens (including scatter) to produce an epithelitis. It is usually best to produce this mucosal dose by using two lateral fields, their size depending on the size and extent of the tumor. In Coutard's twenty-two cured cases of carcinoma of the larynx (28 per cent of seventy-seven cases treated), the total dosage varied from 4,900 roentgens to 7,500 roentgens, and was delivered in a period of nine to thirty-nine days, using as a rule two fields of entry. This dosage is the total dosage given to all fields and represents roentgens measured on the skin with back scatter. His cured laryngeal cases received on average, 5,000 roentgens (air), one side receiving 3,000 roentgens, and the other, 2,000 roentgens. His maximum total dose in this cured series was 7,500 roentgens (skin) or 6,200 roentgents (air). Giving doses much larger than these failed to produce any cures. In passing, one may note that the above percentage of cures refers to cases treated between 1920 and 1926; since that time he believes that his percentage of cures has increased considerably.

CARCINOMAS WHICH RESPOND

Epitheliomas of the cords, glottis or subglottis, without much infiltration of the laryngeal muscles, can be cured in a good percentage of cases by adequate roentgen therapy or adequate surgery; conservation of the voice is, of course, better with radiation. Epitheliomas of the cords and glottis, with considerable infiltration of the laryngeal muscles or with chondritis, or of a highly differentiated type, are often radioresistant. Coutard believes that in some of these cases resection of the infiltrated cartilage or the infected areas, followed by roentgen therapy, is more apt to produce cure than roentgen therapy alone. Judgment is, of course, extremely difficult, and in the average moderate lesion of the hypopharynx and larynx with a little infection, it is often difficult to decide whether to advise surgery or irradiation. Curiously enough, Coutard believes that unilateral adenopathy is easy to cure by adequate roentgen therapy, provided secondary infection is not present.

Most of the cases in Coutard's series that were cured, were cured by a single course. Only 4 per cent of the cured cases received a second course, this being given about six months after the first one.

COMPLICATIONS OF RADIATION THERAPY OF CARCINOMA

The complications of radiation therapy of carcinoma of the larynx include local edema (sometimes necessitating tracheotomy), dysphagia and pain. In our small series of cases we had none in which the edema was sufficient to need tracheotomy, though it must be noted that most of our patients had had a preliminary tracheotomy on account of the large size of the tumor. Indeed, three of them came in on account of severe obstruction to respiration. Dysphagia was present in about half of the cases, and pain in only one-quarter. Direct digestive and cardiovascular disturbances, with the small fields needed in radiation therapy of carcinoma of the larynx, do not occur. However, dehydration with its debilitating effects, must be constantly guarded against. No significant changes in the blood picture were noted.

TECHNIQUE AFTER COUTARD

The actual technique used in the average case is as follows:

The patient is examined with the laryngologist, and the position and estimated extent of the lesion is marked with gentian violet or silver nitrate on the surface of the neck on each side of the larynx. A field at least 3 cm. wider on each margin than the estimated maximum size or extent of the tumor is used. The initial dose is usually 200 roentgens, although in some cases we have started

TABLE 2.—*Summary of Carcinomas of the Larynx Treated by X-Rays (Modified Coutard Technique)*

Case No.	Sex Age	Site of Tumor, Duration of Symptoms, Date of Biopsy, etc.	Histology and Stage	Treatment Begun	Length of Treatment in Days	Dosage (r Measured in Air)	Total Dosage Including Backscatter (±25%)	Course and Result
1	M 56 T. H.	Tumor arising from right pyriform sinus. Hoarse several months. Wa. R. (+++) Biopsy 9-30-33.	Probable epidermoid carcinoma Stage II A	10-4-33	40	2,400 r to left 2,600 r to right lat. fields av. 7.5 cm. in diam.	8,000 r	Radioepithelitis 10-30-33. Lesion shrunken to one-third its former size 11-10-33. Tiny pedunculated nodule removed 11-15-33. (Biopsy: fibrosis, marked "roentgen changes," no ca. cells visible). Clinically well 4-4-34 (5 months).
2	M 56 R. N.	Tumor left vocal cord extending to both arytenoids. Hoarse 2 years. Lesion grew under antiluetic treatment. Wa. R. (–) Developed obstruction. Tracheotomy 8-4-33. Biopsy 2-9-34.	Epidermoid carcinoma Stage II A	8-10-33	50	4,400 r to antr., 1,000 r to left 800 r to right lat. fields; antr. 7 x 6 cm. lat. 9 cm. diam.	7,750 r	Radioepithelitis 9-8-33. Bronchopneumonia and lung abscess 9-24-33. Tracheotomy healed and voice returned 10-12-33. Larynx showed small scar left vocal cord 4-4-34. Gained 16 pounds. Clinically well 4-4-34 (7 months).
3	M 60 J. S.	Tumor right vocal cord involving epiglottis and arytenoids. Hoarse and dysphagic 3 months. Emergency tracheotomy 8-17-33. Biopsy 8-23-33.	Carcinoma Type unclassified Stage II A	8-24-33	35	3,600 r to right 2,200 r to left lat. fields, av. 5 x 9 cm. rectangle	7,250 r	Radioepithelitis 10-5-33. Tracheotomy healed and voice normal 11-2-33. Clinically well 3-30-34 (7 months).
4	M 65 B. K.	Tumor arising from left pyriform sinus, extensive. Hoarse 3 months. Wa. R. (–) Biopsy 9-30-33.	Epidermoid carcinoma Stage II A	10-4-33	40	2,400 r to both right and left lat. fields, each 10 x 8 cm. rectangular	6,000 r	Tracheotomy 10-13-33. Radioepithelitis 11-4-33. Bronchopneumonia 11-20-33. Died 11-29-33. P.M. microscopic examination: marked roentgen changes in the residual tumor tissue (necrosis; nuclear pyknosis, etc.). Cause of death: Multiple pulmonary abscesses, mediastinitis.
5	M 57 W. S.	Tumor involving both cords, extensive infiltration. Hoarse several years with some dyspnea. Biopsy 9-30-33. Wa. R. (–) Laryngofissure and excision 10-15-33. Recurrence 12-15-33. Tracheotomy required 3-7-34.	Epidermoid carcinoma Stage II B	3-2-34	43	3,300 r to left 2,600 r to right lat. fields, 6 x 8 cm. areas	8,500 r	Radioepithelitis 4-12-34. Dyspnea and stridor improved.
6	F 60 W. W.	Tumor right side of larynx, extensive, advanced with adenopathy. Hoarse one year. Right otalgia. Patient feeble and senile. Wa. R. (–).	Biopsy not permitted. Stage III A	3-22-33	31	1,200 r to left 1,300 r to right lat. fields, 10 x 14 cm. areas (patient would not finish course)	(3,125 r)	Radioepithelitis did not develop. Patient's stridor and dyspnea improved so much that she decided not to continue treatments. Present condition is unknown.
7	M 71 H. W.	Tumor left retrolaryngeal area, large with cervical adenopathy. Dysphagia and hoarseness 2 months. Wa. R. (–) Biopsy 11-10-33.	Carcinoma, probably squamous. Stage III A	11-15-33	26	3,100 r to both left and right lat. fields, each 9 cm. diameter	7,750 r	Radioepithelitis 12-4-33. Bronchopneumonia 12-21-33. Left hemiparesis 12-29-33. Skin over neck normal; voice much improved. However, films showed metastatic lesions in spine and ribs. Died 1-14-34. (Septicemia and cachexia?) No P.M. allowed.
8	M 59 C. B.	Tumor extending from base of tongue to 2 centimeters below vocal cords, advanced, hopeless. Palliation requested. Hoarse 3 years. Laryngectomy 2 years ago followed by moderate course of radiation therapy. Tracheotomy 2 years ago. Biopsy 1931, Wa. R. (–).	Carcinoma Type unclassified Stage III B	9-26-33	32	2,400 r to both left and right lat. fields, each 8 x 10 cm. in area	6,000 r	Radioepithelitis 10-26-33. "Voice" returned (patient could actually speak) 10-16-33, and films showed 50% recession of tumor. Tracheotomy tube removed 1-15-34. Bronchopneumonia developed and patient died 1-21-34. No P.M. allowed.
9	M 74 M. M.	Tumor left side of larynx, recurrent, postoperative, with left cervical adenopathy. Hoarse 2 years. Wa. R. (–). Treated for "luetic" laryngeal ulcer in 1931. Laryngectomy 5-28-32 preceded by short preoperative roentgen course (600 r anteriorly to 10 x 10 centimeters field in 3 days). Recurrence 9-28-32. Biopsy 5-28-32.	Epidermoid carcinoma Stage III B	9-29-32	19	1,800 r to left 1,600 r to right lat. fields, each 18 cm. in diameter (patient too weak to finish course)	4,200 r	Radioepithelitis did not develop. Patient did not improve and died 11-28-32. (?Bronchopneumonia and cachexia). No P.M. allowed.

TABLE 3.—*Summary of Roentgen Therapy Results*

Total number of cases treated		9
Clinically well (arrested?)	4	
Improved (but died of subsequent bronchopneumonia)	3	
Unchanged (no extension) of lesion for some months	1	
No improvement (died)	1	
Total number living		5
Total number dead		4

with only 100 roentgens. Such a dose is given daily to alternate sides of the neck for a period of about four weeks. The factors used are 200 KVP., 30 Ma., Thoraeus filter (0.4 mm. Sn, 0.25 mm. Cu, 1.0 Al) H. V. L. 1.5 cm. Cu, 50 to 60 cm. target skin distance, fields varying from 7 to 10 cm. in diameter. The exact size and shape of the field varies in every case, and also varies in the same cases from time to time. A long, cylindrical lead cone, 9 cm. in diameter, is used to accurately center the beam over each field; pieces of "radiopaque" lead rubber (2 mm. thick, absorbing 95 per cent of the primary beam) are used to outline exactly the area to be treated; and a piece is laid against the ventral edge of the neck to prevent marginal overlapping of the two beams. The patient lies on his back with one shoulder moderately elevated, and the projection of the beam is an oblique, rather than a true lateral one. A daily dose of from 100 to 300 roentgens is kept up, excluding Sundays, until the neck has received approximately 3,600 roentgens to the more diseased side, and 2,400 roentgens to the less involved side. The total air dosage by that time is therefore 3,600 plus 2,400, or 6,000 roentgens. If one adds 25 per cent to this air figure to allow

TABLE 4.—*Summary of Results According to Extent of Lesion*

	I A	I B	II A	II B	III A	III B
Total number in each group	0	0	4	1	2	2
Clinically well	0	0	3	1	0	0
Improved but later died	0	0	1	0	1	1
Unchanged but later untraced	0	0	0	0	1	0
No improvement and died	0	0	0	0	0	1

TABLE 5.—*Summary of Carcinomas of the Larynx Treated Surgically (During the Same Period and in the Same Hospital as the Nine Roentgen Treated Cases Listed in Table 2)*

Case No.	Sex Age	Site of Tumor, Histology and Stage	Operation and Date	Course and Result
1	M 71 T. M.	"Infiltration beneath both cords." Biopsy 4-26-33. Squamous cell epithelioma. Stage I A.	Laryngofissure and fulguration 6-28-33.	Returned to work. Now untraced.
2	M 65 N. T.	Tumor mass both laryngeal ventricles with fixation right arytenoid. Cervical adenopathy. Biopsy 7-12-33. Epithelioma, type unclassified. Stage III A.	Total laryngectomy with resection neck glands 7-12-33.	Steadily downhill. *Died* 7-30-33. (Eighteen days postoperative.)
3	M 49 J. S.	Tumor of right vocal cord. Biopsy 10-22-32. Epithelioma, type unclassified, Stage I A.	1. "Hemilaryngectomy with removal of right vocal cord" 10-22-32. 2. Total laryngectomy 4-22-33.	*Recurrence* again developed. Present status unknown.
4	M 45 J. M.	Nodular tumor of right vocal cord, size of a pea. Biopsy 12-29-31. Epithelial hyperplasia, ? precancerous. Stage I A.	Laryngofissure 12-29-31.	Recovered, present status unknown. (? benign lesion.)
5	M 61 N. S.	Extensive tumor of right cord and ventricle, left ventricle, etc. Biopsy 12-14-31. Squamous cell epithelioma. Stage III A.	Laryngectomy 12-22-31.	*Died* 12-26-31. "Suffocation due to obstruction of tracheotomy opening."
6	M 74 M. M.	Tumor size unrecorded. Biopsy 5-28-32. Epidermoid epithelioma. ? Stage II A.	Laryngectomy 5-28-32.	Recurrence 8-28-32. Roentgen therapy. *Died* 11-28-32. (Cachexia, bronchopneumonia, cancer larynx.)
7	M 57 C. B.	Moderate sized tumor of larynx. Biopsy 1931. Epithelioma, type unclassified. ? Stage II A.	Laryngectomy 1931.	Recurrence July, 1932. Roentgen therapy 1932. Recurrence. Roentgen therapy 1933. *Died* 1-21-34. (Cachexia, cancer larynx.)
8	M 40 C. C.	Moderate sized tumor of larynx. Biopsy 2-23-34. Epithelioma, type unclassified. Stage II A.	Laryngectomy 3-5-34.	Steadily downhill. *Died* 3-14-34. (Nine days postoperative. No P. M. allowed. (Clinical diagnosis: Pulmonary hemorrhage.)

TABLE 6.—*Summary of Surgical Results*

Total number of cases operated		8
Clinically well (untraced but ? arrested)	2	
Improved but developed recurrence	3	
No improvement (died postoperative)	3	
Total number living unknown, but possibly		3
Total number dead		5

for back scatter, the total skin dose is approximately 7,500 roentgens. As may be seen from Table 2, this is the average dose received by our cases. (It is quite misleading to add up the roentgens given to each field to express the total dose; when so added up in this paper, it is done only to permit ready comparison with existing literature.)

During the end of the third or middle of the fourth week a marked cutaneous reaction develops which necessitates oily, soothing skin dressings (pieces of gauze soaked in mineral oil or smeared with boric acid ointment). A high caloric liquid diet is given, and every effort is made to see that the patient takes plenty of fluids, sleeps well and does not catch cold. Since many of them are breathing through a relatively new tracheotomy opening, they are apt to develop a mild tracheobronchitis with catarrhal discharge.

Whether the treatment should be pushed beyond the above stage depends on the individual case. In one case the patient received a total dose of 6,400 roentgens (air) or 8,000 roentgens (skin). Judging by subsequent developments, we now think that some of our patients should have received more radiation, or radiation more rapidly delivered, while some might have been cured with less. Time and experience will be the only answers to these two problems.

RESULTS OBTAINED IN AUTHOR'S SERIES

The actual results in our short series of cases are tabulated in Tables 3 and 4. There were no small or early lesions in the series. Of four cases classified as moderate lesions, nonoperated, three patients are living and clinically arrested, one is dead (bronchopneumonia with multiple pulmonary abscesses). One case, classified as moderate, recurrent postoperative, is clinically well. Of three patients, classified as advanced recurrent postoperative, all are dead, one showing no improvement after therapy, two showing definite and, in the words of the attending surgeons, remarkable improvement. One case, classified as advanced, nonoperated, is clinically unchanged following radiation, the growth having neither receded nor extended during the period under observation.

TABLE 7.—*Comparison of Recent Surgical and Radiological Results in the Treatment of Carcinoma of the Larynx (Literature)*

Treatment	Authority	Publication	Total Number of Cases	Results
Roentgen	Coutard, H.	Amer. Jour. Roent. and Ra. Ther. 1932. 28, 313.	77	22 cases or 28 per cent cured 4 years and over.
Roentgen	Lenz, M.	Jour. Amer. Med. Assoc. 1932. 99, 1840.	33	7 cases or 21 per cent clinically well 6 months to 2½ years.
Roentgen	Schinz, H. R.	Strahlentherapie 1933. 1-7-33.	116	40 cases or 34 per cent clinically well 9 months to 3 years.
Surgical	Colledge, L. and Peacock, R.	Jour. Laryngol. and Otol. 1932, 47, 161.	79*	11 cases or 13.9 per cent cured 4 years and over. 33 cases or 41 per cent clinically well 9 months to 10 years.

* See Table 8.

COMPARISON WITH OTHER RESULTS REPORTED

It will be of interest to compare the results obtained by roentgen therapy with those obtained by surgery, working under similar conditions, in the same institution and with the same general type of patient. These surgical cases were handled by skilled, experienced surgeons, and received the same type of nursing care as the roentgen treated cases. They are tabulated in Table 5 and summarized in Table 6.

Lastly, the results of treatment in 334 cases recently reported by well known radiologists are

TABLE 8.—*Analysis of Colledge and Peacock's Surgical Results in the Treatment of Carcinoma of the Larynx*

Total Number of Cases	Total Number Classified as "Operated"	Mortality 26.5 per cent	Recurrence 25 per cent	Result
108	79	(21 cases)	(20 cases)	8 cases (10 per cent) cured 5 years or more. 11 cases (13.9 per cent) cured 4 years or more. 33 cases clinically well 9 months to 10 years.

Note (1)—Judging by the description of the lesions and using a I-III Stage classification, the "arrested" cases show 18 in Stage I, 8 in Stage II, 7 in Stage I or II, and 0 in Stage III.

Note (2)—Of the total 108 cases, 29 are described as refusing or being unsuited for operative treatment. If the cured or arrested percentages were based on *all cases* "treated" the 4-year cures would be 10 per cent and the 5-year cures 7.4 per cent respectively.

tabulated (Table 7), and a carefully documented series of surgically-treated cases are analyzed (Table 8). It will be seen that the best radiological results are exactly twice as good as the best surgical results (28 per cent of four-year cures as compared with 13.9 per cent), while the mortality of the latter is considerably greater than that of the former. On the other hand, it must be emphasized that no one realizes better than the radiologist that cases of malignant disease thought cured do, in fact, sometimes recur at a later date, and no one will pretend that these four-year results are to be regarded by any means as final, or even as satisfactory at the present time.

IN CONCLUSION

In concluding, I would like to present the following impressions:

1. Many cases of carcinoma of the larynx can apparently be cured by adequate, carefully administered roentgen therapy.

2. None of the present series of nine patients has been observed for a period of five years or more, and therefore the number of clinical cures cannot be stated. However, it may be pointed out that four out of the nine patients treated are clinically well at the time of making this report.

3. There was no mortality directly attributable to the roentgen therapy in this series of patients. No late necrosis of cartilage or bone, and no emergency tracheotomies nor pharyngeal obstructions developed following radiation; nevertheless, such complications may be expected to arise occasionally in a sufficiently large series of patients.

4. Roentgen therapy avoids destruction of the voice and, in our series of patients, has resulted in no disfigurement of the neck.

5. The choice of therapeutic attack in cancer of the larynx would appear to be a joint problem for the radiologist and the surgeon, the indications for one or the other (or both) procedures varying in each individual case.*

450 Sutter Street.

REFERENCES

1. Bailey, Wilbur: Protracted Fractional Radiation Therapy as Introduced by Coutard (unpublished), 1933.

2. Colledge, L. and Peacock, R.: An Analysis of 126 Cases of Malignant Disease of the Upper Air Passages Treated During a Period of Ten Years (1921 to 1930), J. Laryng. and Otol., 47:161, 1932.

3. Coutard, H.: Roentgen Therapy of Epitheliomas of the Larynx, etc., Am. J. Roentgenol., 28:313, 1932.

4. Ewing, J.: Neoplastic Diseases, W. B. Saunders Co., N. Y., 1928.

5. Lenz, M.: Roentgenotherapy of Malignant Neoplasm of the Pharynx and Larynx, J. A. M. A., 99: 1840, 1932.

6. Martin, H. E. and McNattin, R. F.: The Treatment of Carcinomas of the Pharynx, Tonsil and Extrinsic Larynx by Divided Doses of Radiation Therapy (unpublished), read at First Am. Cong. Radiology, 1933.

7. Schinz, H. R.: Operative u. Radiotherapeutische Behandlung der Krebse, Strahlentherapie, 46:7, 1933.

* The writer wishes to acknowledge with gratitude the painstaking work of Drs. W. L. Allred and M. J. Thorpe, without whose capable assistance the actual details of treating the patients mentioned in this paper would not have been accomplished. He is also indebted to the officers and staff of the Ear, Nose and Throat Department for their consideration and unfailing coöperation.

DISCUSSION

WILLIAM E. COSTOLOW, M. D. (1407 South Hope Street, Los Angeles).—Doctor Garland has very completely described the present-day conception of the irradiation treatment of carcinoma of the larynx. The published work of Coutard in 1931, which he mentioned, has caused all radiologists to adopt this technique or some modification of it. Previous to this, usually a combination of internal radium application and external x-ray irradiation was used. The results were erratic, although in some cases of not too extensive involvement with radiosensitive growths, arrests were obtained. In our clinic during the past two years we have used a technique similar to the one which Doctor Garland has described. Five patients have been given a complete treatment according to this technique: two are deceased; one is alive and improved, but only recently treated; one has been well and free from symptoms for one year, and one has been well and free from symptoms for one year and four months. Other cases have been treated, but did not receive a complete treatment according to the Coutard technique.

One of our patients, who is apparently well, shows a case in which the growth was early and localized to one vocal cord. Another case is one in which the growth had become extrinsic and quite extensive. Patients having a growth which has involved the cartilage probably will not be permanently cured by this method, but worthwhile palliation may be obtained. Attempts should not be made to excessively irradiate these cases, however, if the malignancy is low grade, because, as Coutard has pointed out, the vasculoconnective tissue will be damaged, and the aid which this tissue affords in destroying the malignancy will be lost. Coutard believes that the radiosensitivity of cancer cells depends not only upon the youthfulness of the cells, but also upon the reactionary changes produced in the surrounding vasculoconnective tissue. In high-grade, or anaplastic malignancy, the direct action of the rays on the youthful cells may be sufficient to destroy these cells; but in a low-grade or differentiated malignancy the reaction from the vasculoconnective tissue is the most important factor. Hence, these cases must be carefully examined daily, the laryngeal growth and irradiation reaction carefully studied. It is important, especially in the reactionary period, to avoid excessive reaction. This may be accomplished by using weaker daily dosage intensity and increased duration of treatment time.

Coutard lately, in the more radioresistant growths, has increased the duration of treatment from thirty to 90 days, with a daily dosage of 175 r to 250 r, given in two seances, and has been able to produce disappearance of tumors which had been considered radioresistant.

The irradiation treatment of cancer of the larynx, as of cancer in other parts of the body, should be individualized, the type and degree of malignancy of the tumor accurately determined and appreciated, the extent of the disease defined, and the general condition of the patient evaluated before the treatment is planned and carried out. As has been pointed out by Coutard, a small margin exists sometimes between the dose which will determine a cure and the dose which will provoke an injury.

Doctor Garland's cases, together with the ones reported in the literature, and the increasing experience with this type of irradiation by many therapists, show that definite arrests may be obtained in carcinoma of the larynx; and equally important that a great amount of palliation may be obtained by proper irradiation. The results will be proportionate to the accuracy with which the patients and their growths are studied, to the accuracy with which the irradiation dosage is measured and applied, and to the clinical judgment and experience of the physician in charge.

HAROLD A. FLETCHER, M. D. (490 Post Street, San Francisco).—In general it is my opinion that the operator in the surgical treatment of cancer of the

larynx tends to err on the side of conservatism, particularly in the early stages of the malignancy. The reason for this is, of course, the desire to preserve function of the voice. Another mistake often made is in attempting to attack a malignancy of a vocal cord intralaryngeally rather than through a laryngeal fissure, which I believe should be the method of approach in all but very exceptional cases.

Hemilaryngectomies or total laryngectomies can sometimes be made with the confidence that a cure will be brought about, provided the proper diagnostic study of the condition has been made previously. Both of these operations have saved many lives and resulted in permanent cures, but the percentage of recurrences is high, and the complications due to a permanent tracheotomy opening are frequent, and often disastrous and disabling. The difficulty of knowing whether the operation has been wide of the pathology is well known.

It is my belief that in most cases where any wide involvement is found, roentgen therapy should be used both before and after operation, or at least afterward.

The recent advances in the treatment of these conditions, with both x-ray and radium, are surely pointing to an increase in the percentage of cures. Radiologists deserve a great deal of credit for the promotion of this work. The laryngologists and the general surgeon will be only too thankful if the radiologist can take the carcinoma of the larynx case out of his hands and cure it with roentgen therapy. I do not believe that this day has yet arrived, but it may come in the near future. At present, I feel that we must stay with the careful study of the individual case, early diagnosis and the combined intelligent use of both surgery and roentgenology.

❋

ROBERT S. STONE, M. D. (University of California Hospital, San Francisco).—Malignant tumors of the larynx have been cured so infrequently by the methods of treatment formerly employed that Doctor Garland is to be thanked for calling our attention to a method which, in competent hands, has given about double the percentage of cured cases. He has covered the subject very thoroughly in his paper, but there are two points which I would like to emphasize.

The method of treatment with protracted roentgen therapy depends for its efficacy on treating until the extreme limit of tolerance of normal tissue is reached. The cancer cells are killed by a dose of x-ray which is just slightly less than that required to kill normal tissue cells. The normal cells recover from a dose slightly more rapidly than the malignant cells. The repeated small doses hit cancer cells not quite so well recovered from previous doses as the normal cells. This means that a slight overdose could easily kill the normal cells and result in serious permanent damage. Therefore, this method of treatment must be tried only by those who have their roentgen apparatus thoroughly calibrated, and who understand the methods of procedure quite as well as the best surgeons understand theirs.

In the second place, I wish to emphasize the fact that the reactions are very severe. Most practitioners have never seen x-ray reactions such as these, and their first inclination is to exclaim, in the patient's presence, that he has received a severe "burn." The skin does appear much like that in the so-called x-ray burn, but it recovers very rapidly and has few or none of the late sequelae. If a patient of yours has to be treated in this way, please be guarded in the remarks you make in his presence about the reaction.

In closing, I wish to say that while the reactions are severe and the danger of complications is real, they are not comparable with the mortality rate in the best surgeons' hands or the handicap of being without a larynx. In the proper cases it is certainly the method of choice.

BACILLARY DYSENTERY*

By W. H. KELLOGG, M. D.
Berkeley

THE diagnosis of dysentery depends on finding the etiologic factor. Some cases are clinically a simple diarrhea; but if their cause is one of the specific microbial agents, they are dysentery. Others present the complete syndrome of frequent loose or watery discharges with blood and mucus, tenesmus, fever, and prostration. The frequent occurrence of the mild type, with a low case fatality rate, renders its recognition and control difficult. The essential thing in establishing the diagnosis is the identification of the infectious agent which may be either bacterial or protozoan. Doubtless there are living agents as yet unknown; most certainly in the bacillary group, less certainly among the protozoan, and, it might be suggested, among the filterable viruses. True cases of proved specific infections may have symptoms so mild and transitory as to be indistinguishable from intestinal disturbance of apparently simple irritative origin. Even the supposedly classical phenomena of blood and mucus in the stools are not pathognomonic, and their absence does not rule out dysentery.

Dysentery is one of the annoying problems of the epidemiologist, who frequently must conclude his report with the statement that the source of the outbreak remains undetermined. In large part the sterile results are due to the evanescent nature of the illness, the trail being cold when attention is directed to the occurrence of an epidemic.

CLASSIFICATION OF ACUTE DYSENTERY

Leaving out of consideration amebic dysentery, which is not included in the scope of the present discussion, acute dysentery may be roughly classified as to cause into known bacillary types under which we can group, on one side, those caused by the Shiga bacillus, and on the other, those caused by members of the group of mannite fermenters, probably best spoken of as the Flexner group. Members of this group have been isolated and named from time to time, familiar names for individual strains being Flexner, Hiss-Russell, Strong, and the alphabetical group, V, W, X, Y, and Z, of the English authors, Andrews and Inman. To these must be added the Sonne bacillus, the Schmitz bacillus, possibly Alkalescens and Morgan's bacillus, and a new strain of the Flexner group recently isolated and studied by ourselves. Besides these bacteriologically identifiable cases, there are others occurring in outbreaks having the appearance of epidemics, the etiology of which is obscure and their inclusion as dysenteries of doubtful propriety. These acute diarrheas of unknown origin occur sometimes in quite extensive outbreaks, the individual cases being of short duration, but the outbreak extending over a period of days, even weeks, for a given locality.

San Francisco Bay Region Experience.—In the San Francisco Bay region last summer, hundreds of such cases occurred, the only thing in common

*From the Bureau of Laboratories of the California State Board of Health.