THE ROYAL SOCIETY

Filamentous nerve cell inclusions in neurodegenerative diseases: tauopathies and α-synucleinopathies

Michel Goedert

Medical Research Council Laboratory of Molecular Biology, Hills Road, Cambridge CB2 2QH, UK (mg@mrc-lmb.cam.ac.uk)

Alzheimer's disease and Parkinson's disease are the most common neurodegenerative diseases. They are characterized by the degeneration of selected populations of nerve cells that develop filamentous inclusions before degeneration. The neuronal inclusions of Alzheimer's disease are made of the microtubule-associated protein tau, in a hyperphosphorylated state. Recent work has shown that the filamentous inclusions of Parkinson's disease are made of the protein α-synuclein and that rare, familial forms of Parkinson's disease are caused by missense mutations in the α-synuclein gene. Besides Parkinson's disease, the filamentous inclusions of two additional neurodegenerative diseases, namely dementia with Lewy bodies and multiple system atrophy, have also been found to be made of α-synuclein. Abundant filamentous tau inclusions are not limited to Alzheimer's disease. They are the defining neuropathological characteristic of frontotemporal dementias such as Pick's disease, and of progressive supranuclear palsy and corticobasal degeneration. The recent discovery of mutations in the tau gene in familial forms of frontotemporal dementia has provided a direct link between tau dysfunction and dementing disease. The new work has established that tauopathies and α-synucleinopathies account for most late-onset neurodegenerative diseases in man. The formation of intracellular filamentous inclusions might be the gain of toxic function that leads to the demise of affected brain cells.

Keywords: tau protein; α-synuclein; Alzheimer's disease; frontotemporal dementia; Lewy body diseases; multiple system atrophy

1. INTRODUCTION

Neurodegenerative diseases of the human brain are characterized by the degeneration of specific populations of nerve cells. Alzheimer's disease, a dementing condition, is the most common of these diseases. It affects 20–25 million people worldwide and is the fourth leading cause of death in the industrialized world. Alzheimer's disease is defined by the presence of two neuropathological abnormalities made of filamentous deposits: neuritic plaques in the extracellular space and neurofibrillary lesions inside nerve cells. Frontotemporal dementias such as Pick's disease account for 5–10% of dementias. They frequently show neuropathological features similar to the neurofibrillary lesions of Alzheimer's disease. Parkinson's disease, a movement disorder, is the second most common neurodegenerative disease. It affects six to seven million individuals worldwide. Neuropathologically, Parkinson's disease is defined by the presence of intracytoplasmic filamentous inclusions in the form of Lewy bodies and Lewy neurites. Dementia with Lewy bodies is a common late-life dementia that shares pathological features with Parkinson's disease and is clinically similar to Alzheimer's disease. Finally, multiple system atrophy, a less common neurodegenerative disease that is often clinically mistaken for Parkinson's disease, is characterized by filamentous inclusions in glial cells. All these diseases exist as rare genetic forms and as much more common sporadic forms. Taken together, they account for the majority of late-onset neurodegenerative diseases in man (Goedert *et al.* 1998*a*).

At the beginning of this century, Alzheimer and Lewy described the characteristic light-microscopic neuropathological features of Alzheimer's disease, Pick's disease and Parkinson's disease (Alzheimer 1907, 1911; Lewy 1912). In the 1960s these lesions were shown to be made of abnormal filamentous material (Kidd 1963; Duffy & Tennyson 1965; Rewcastle & Ball 1968). Over the past 15 years, the molecular components of the filamentous lesions of Alzheimer's disease and Pick's disease have been identified and much continues to be learnt about their formation. The intracellular deposits are made of the microtubule-associated protein tau (Brion *et al.* 1985; Pollock *et al.* 1986; Goedert *et al.* 1988; Wischik *et al.* 1988; Kondo *et al.* 1988; Lee *et al.* 1991), whereas the extracellular deposits of Alzheimer's disease are made of the β-amyloid protein Aβ (Glenner & Wong 1984; Masters *et al.* 1985). Over the past two years, the biochemical nature of the filamentous material of Lewy bodies and Lewy neurites of Parkinson's disease and dementia with Lewy bodies has been discovered (Spillantini *et al.* 1997*a*, 1998*a*). Last year, the biochemical nature of the filaments of multiple system atrophy was revealed (Spillantini *et al.* 1998*b*; Tu *et al.* 1998; Wakabayashi *et al.* 1998*a*,*b*; Arima *et al.* 1998*a*). In all three diseases, the intracellular filaments are made of the protein α-synuclein.

 © 1999 The Royal Society

Table 1. *Intraneuronal filamentous inclusions in neurodegenerative diseases*

(Abbreviations: FTDP-17, frontotemporal dementia and Parkinsonism linked to chromosome 17; PSP, progressive supranuclear palsy; CBD, corticobasal degeneration; SCA, spinocerebellar ataxia; DRPLA, dentatorubral–pallidoluysian atrophy; SBMA, spinal and bulbar muscular atrophy.)

disease	filamentous inclusion	main component
Alzheimer's disease	neurofibrillary lesions	tau protein
Pick's disease	Pick bodies	tau protein
FTDP-17	neurofibrillary lesions, glialfibrillary lesions	tau protein
PSP	neurofibrillary lesions, glialfibrillary lesions	tau protein
CBD	neurofibrillary lesions, glialfibrillary lesions	tau protein
Parkinson's disease	Lewy bodies and neurites	α-synuclein
dementia with Lewy bodies	Lewy bodies and neurites	α-synuclein
multiple system atrophy	glial and neuronal inclusions	α-synuclein
Huntington's disease	intranuclear inclusions, dystrophic neurites	expanded glutamine repeats in huntingtin
SCA-1	intranuclear inclusions	expanded glutamine repeats in ataxin-1
SCA-3	intranuclear inclusions	expanded glutamine repeats in ataxin-3
SCA-7	intranuclear inclusions	expanded glutamine repeats in ataxin-7
DRPLA	intranuclear inclusions	expanded glutamine repeats in atrophin-1
SBMA	intranuclear inclusions	expanded glutamine repeats in androgen receptor

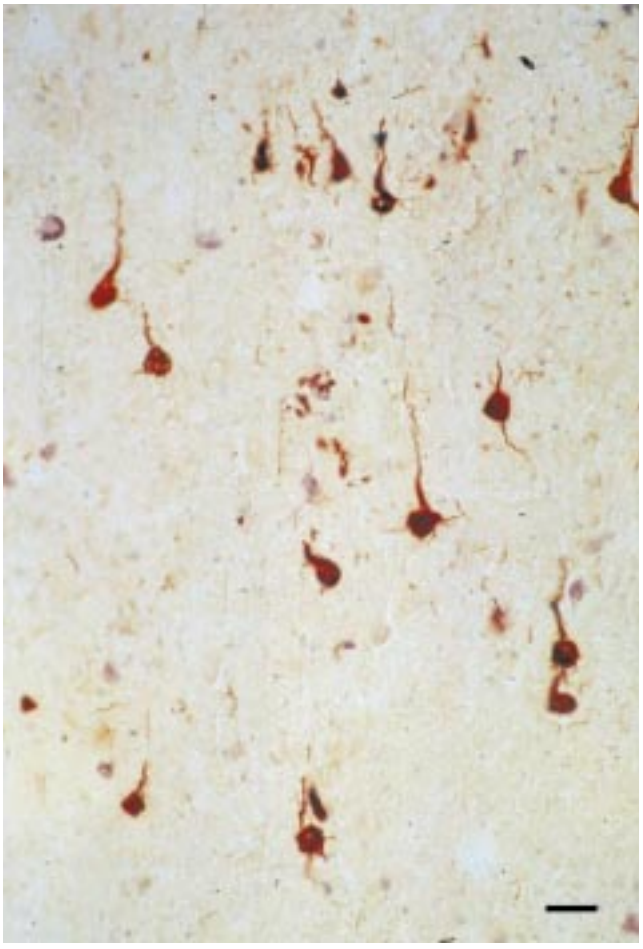

Figure 1. Neurofibrillary lesions in cerebral cortex from an Alzheimer's disease patient revealed with a phosphorylation-dependent anti-tau antibody.

Recent progress has led to the classification of late-onset neurodegenerative diseases according to the biochemical composition of their intracellular filamentous deposits (Goedert *et al*. 1998*a*; Hardy & Gwinn Hardy 1998). The three major classes of disease are the tauopathies, the α-synucleinopathies and the glutamine repeat diseases (table 1). This paper deals exclusively with tauopathies and α-synucleinopathies.

2. ALZHEIMER'S DISEASE

A diagnosis of Alzheimer's disease is made when a patient exhibits clinical evidence of progressive dementia and when a post-mortem examination of the brain reveals the characteristic neuropathology consisting of extracellular neuritic plaques and intracellular neurofibrillary lesions. Aβ, the 40–42-residue plaque component, is derived by proteolytic cleavage from the much larger amyloid precursor protein (APP) (Glenner & Wong 1984; Masters *et al*. 1985; Kang *et al*. 1987). Genetic evidence has shown that APP pathology has an important role in the aetiology and pathogenesis of at least a proportion of cases of Alzheimer's disease (Goate *et al*. 1991). The relationship between amyloid deposition and neurofibrillary lesions remains an important unresolved issue in our understanding of the pathogenesis of Alzheimer's disease.

Abundant amyloid deposits can be present in cognitively normal individuals and it is the presence of neurofibrillary lesions that correlates better with the presence of dementia (Arriagada *et al*. 1992). Until recently, a major question was whether this correlation implied a causal relation. It had repeatedly been suggested that neurofibrillary lesions might be nothing more than an epiphenomenon (Duff & Hardy 1995; Masters & Beyreuther 1998). The discovery of mutations in the tau gene in familial frontotemporal

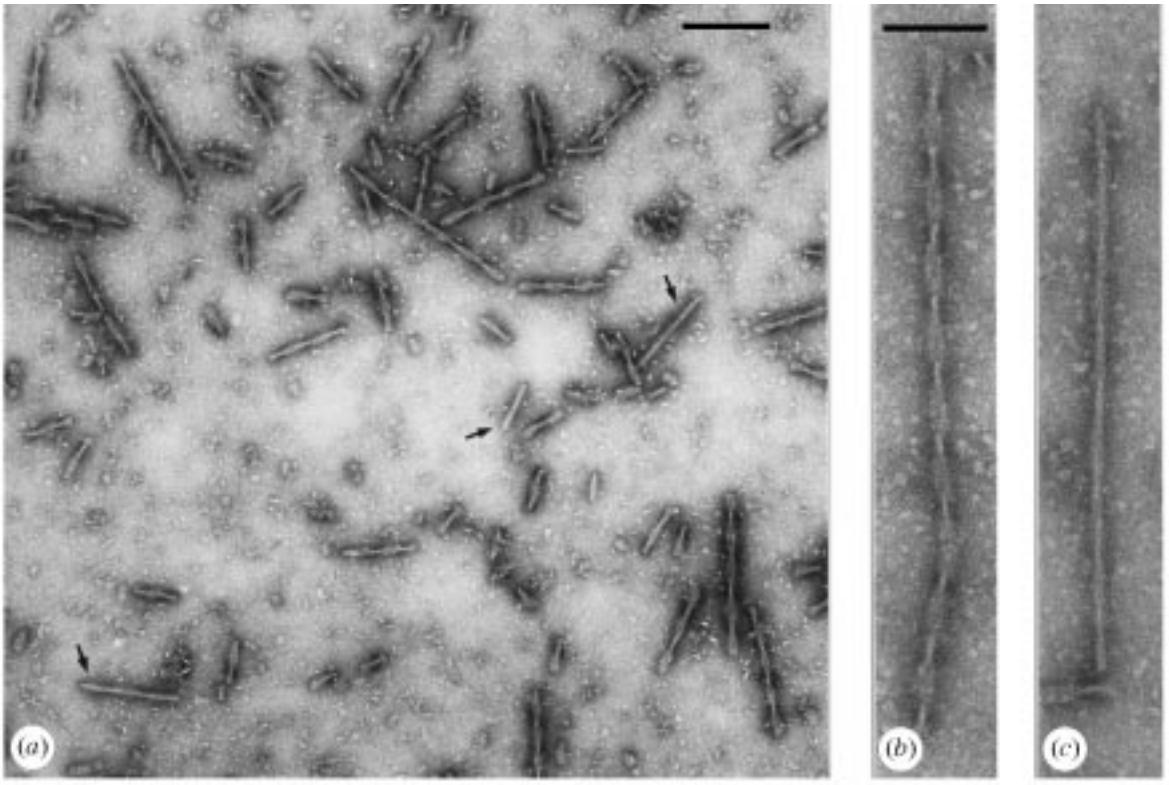

Figure 2. Electron micrographs of negatively stained abnormal filaments from the brain of a patient with Alzheimer's disease. (*a*) Low-power view showing predominantly paired helical filaments but with a few straight filaments (arrows); (*b*,*c*) high-power view of a paired helical filament (*b*) and a straight filament (*c*). Scale bars: (*a*) 200 nm; (*b*,*c*) 100 nm.



Figure 3. Isoforms of human tau. (*a*) Schematic representation of the six human brain tau isoforms (ranging from 352 to 441 residues). The region common to all isoforms is shown in blue, with the N-terminal inserts shown in red and green. The alternatively spliced repeat is in yellow. The three or four tandem repeats are indicated by black bars. Isoform 1 is expressed in foetal human brain, whereas all six isoforms (1–6) are expressed in adult human brain. (*b*) PHF-tau from Alzheimer's disease brain and recombinant human tau isoforms. Lane 1, mixture of recombinant human brain tau isoforms, with each isoform identified by a number; lane 2, the four PHF-tau bands of 60, 64, 68 and 72 kDa, with the tau isoform composition of each band identified by a number. After SDS–PAGE, the tau isoforms were revealed by immunoblotting with a phosphorylation-independent anti-tau antibody.

dementias, in conjunction with the presence of a filamentous tau pathology, has settled this question (see § 3) (Spillantini *et al*. 1998*c*,*d*; Poorkaj *et al*. 1998; Hutton *et al*. 1998). It now seems clear that the formation of a filamentous tau pathology leads to nerve cell degeneration.

(a) *Natural history of neurofibrillary lesions*

The neurofibrillary pathology forms within nerve cells of the cerebral cortex, the hippocampal formation and some subcortical nuclei. The nerve cells eventually degenerate and the insoluble neurofibrillary lesions are found in

the extracellular space as ghost tangles (Alzheimer 1907, 1911). In the hippocampus, there exists an inverse correlation between the number of extracellular tangles and the number of surviving nerve cells (Bondareff *et al.* 1989; Cras *et al.* 1995; Fukutani *et al.* 1995), demonstrating that the nerve cells that degenerate developed neurofibrillary lesions. These lesions are found in nerve cell bodies and apical dendrites as neurofibrillary tangles, in distal dendrites as neuropil threads and in abnormal neurites that are often, but not always, associated with amyloid plaques (figure 1). Ultrastructurally, the neurofibrillary pathology consists of paired helical filaments (PHFs) and the related straight filaments (SFs) (figure 2) (Kidd 1963; Crowther 1991). These filaments are made of the microtubule-associated protein tau, in a hyperphosphorylated state (Brion *et al.* 1985; Goedert *et al.* 1988; Wischik *et al.* 1988; Kondo *et al.* 1988; Lee *et al.* 1991).

A filamentous tau pathology indistinguishable from that of Alzheimer's disease is a frequent accompaniment of ageing. The difference with Alzheimer's disease lies in the much smaller number of affected nerve cells. The development of neurofibrillary lesions in ageing and Alzheimer's disease follows a stereotyped pattern with regard to affected cell types, cellular layers and brain regions, with little variation between individuals. This pattern has been used to define six neuropathological stages of Alzheimer's disease (Braak & Braak 1991, 1997). The very first nerve cells in the brain to develop neurofibrillary lesions are located in the pre-alpha layer of the transentorhinal region, thus defining stage I. Stage II shows a more severe involvement of this region, as well as a mild involvement of the pre-alpha layer of the entorhinal cortex. Patients with this pathology are unimpaired cognitively, indicating that stages I and II might represent clinically silent stages of Alzheimer's disease. Mild impairments of cognitive function become apparent in stages III and IV. Stage III is characterized by severe neurofibrillary lesions in the pre-alpha layers of both the entorhinal and transentorhinal regions. Stage III is also characterized by the appearance of the first extracellular tangles. In stage IV, the deep pre-alpha layer develops extensive neurofibrillary lesions. During stages III and IV, changes are also seen in layer I of Ammon's horn of the hippocampus and in a number of subcortical nuclei. The major feature of stages V and VI is the massive development of neurofibrillary lesions in isocortical association areas. They meet the criteria for the neuropathological diagnosis of Alzheimer's disease and are found in patients who were severely demented at the time of death.

As a function of age, most individuals develop stages I and II of neurofibrillary degeneration. Extensive studies by Braak & Braak (1997) have suggested a continuum between these initial changes and full-blown Alzheimer's disease. They have indicated that even small numbers of neurofibrillary lesions are pathological and might represent the early stages of Alzheimer's disease. Extracellular tangles were never observed in the absence of intracellular lesions, indicating that once initiated the neurodegenerative process follows its relentless course. These studies have also provided the important information that neurofibrillary lesions can develop in layer pre-alpha in the absence of extracellular Aβ deposits. They are inconsistent with the widely held view that the neurofibrillary pathology develops as the mere consequence of the neurotoxic action of Aβ deposits and suggest instead that nerve cells die from within.

(b) *Tau protein in normal brain*

Tau is a microtubule-associated protein whose physiological functions are to promote microtubule assembly and to stabilize microtubules (Hirokawa 1994). In adult human brain, six isoforms of tau are expressed, which are produced by alternative mRNA splicing from a single gene located on the long arm of chromosome 17 (figure 3) (Goedert *et al.* 1989*a*,*b*; Goedert & Jakes 1990; Andreadis *et al.* 1992). They differ by the presence of three or four tandem repeats of 31 or 32 residues each, located in the C-terminal region, in conjunction with inserts of 0, 29 or 58 residues located in the N-terminal region. There is also a larger tau isoform, with an additional 254-residue insert in the N-terminal region, which is mainly expressed in the peripheral nervous system (Goedert *et al.* 1992*a*; Couchie *et al.* 1992).

The repeat regions of tau and sequences flanking the repeats constitute microtubule-binding domains, with the functions of the N-terminal regions remaining uncertain (Gustke *et al.* 1994; Trinczek *et al.* 1995). Tau protein mRNA is expressed predominantly in nerve cells, with lower levels in some glial cells. Within nerve cells, tau protein is present mainly in axons (Binder *et al.* 1985). Tau does not seem to be an essential protein, because inactivation of its gene by homologous recombination leads to no overt phenotype, except a decrease in the number of microtubules in some small-calibre axons (Harada *et al.* 1994). Tau expression is developmentally regulated in that only the tau isoform with three repeats and no N-terminal inserts is present in foetal human brain (Goedert *et al.* 1989*a*,*b*). There exist true species differences in the expression of tau isoforms in adult brain. Thus, only three tau isoforms are expressed in rodent brain, each with four repeats and N-terminal inserts of 0, 29 or 58 residues (Götz *et al.* 1995). In contrast, all six tau isoforms are expressed in adult human brain, where tau isoforms with three repeats are slightly more abundant than isoforms with four repeats (Goedert & Jakes 1990). Tau is a phosphoprotein, and phosphorylation is also developmentally regulated. Thus, the shortest isoform is phosphorylated more during development than any of the six tau isoforms in adult brain (Kanemura *et al.* 1992; Goedert *et al.* 1993).

(c) *Tau protein in Alzheimer's disease brain*

In Alzheimer's disease brain, a proportion of tau protein is filamentous and of decreased solubility. Dispersed PHFs and SFs consist of three major tau bands of 60, 64 and 68 kDa and a minor band of 72 kDa (figure 3) (Greenberg & Davies 1990; Lee *et al.* 1991). On dephosphorylation, six tau bands are seen that align with the six recombinant human brain tau isoforms (Goedert *et al.* 1992*b*). Thus, all the brain tau isoforms are present, each in a full-length form. Several approaches have helped to delineate which tau isoforms make up each PHF-tau band (figure 3) (Goedert *et al.* 1992*b*; Mulot *et al.* 1994; Sergeant *et al.* 1997*b*). The shortest and the longest tau isoforms constitute the 60 and 72 kDa bands, respectively. Each of the 64 and 68 kDa bands consists of two tau isoforms, one with three repeats and one with

four repeats. PHF-tau from Alzheimer's disease brain therefore consists of all six tau isoforms, each in a hyperphosphorylated state.

Hyperphosphorylation and abnormal phosphorylation are major biochemical abnormalities of PHF-tau. They are early events in the development of the neurofibrillary lesions (Braak *et al*. 1994) and as a result tau is unable to bind to microtubules (Bramblett *et al*. 1993; Yoshida & Ihara 1993). Most phosphorylated sites are known (Morishima-Kawashima *et al*. 1995; Hanger *et al*. 1998). They consist of serine or threonine residues, many of which are followed by a proline in the tau sequence. A number of protein kinases have been implicated in the abnormal phosphorylation of tau, largely based on studies of tau phosphorylation *in vitro*. The latest additions to this growing list are stress-activated protein (SAP) kinases, especially SAP kinase 3 and SAP kinase 4 (Goedert *et al*. 1997). Protein phosphatase 2A is the major protein phosphatase activity in brain able to dephosphorylate tau phosphorylated by a number of protein kinases (Goedert *et al*. 1992*c*; Sontag *et al*. 1996).

Relatively little is known about which protein kinases phosphorylate tau in brain. This requires specific protein kinase inhibitors or the inactivation of individual protein kinase genes. The use of lithium chloride as a specific inhibitor of glycogen synthase kinase 3 has provided strong evidence that this protein kinase is involved in the phosphorylation of tau in normal brain (Munoz-Montado *et al*. 1997; Hong *et al*. 1997). However, the identity of the protein kinases and/or protein phosphatases that lead to the hyperphosphorylation of tau in the Alzheimer's disease brain remains to be established.

PHFs and SFs form from hyperphosphorylated full-length tau protein. After assembly, tau is proteolysed, mainly from the N-terminus, with extensively proteolysed PHFs and SFs only consisting of the microtubule-binding repeats (Wischik *et al*. 1988; Goedert *et al*. 1992*b*). Ubiquitination is a biochemical modification of PHF-tau that occurs after partial proteolysis from the N-terminus (Mori *et al*. 1987; Morishima-Kawashima *et al*. 1993). Four lysine residues in the microtubule-binding repeats of tau have been identified as the ubiquitin-conjugating sites (Morishima-Kawashima *et al*. 1993). Ubiquitination is an event that follows assembly into filaments and probably forms part of a largely unsuccessful attempt by the cellular machinery to degrade PHFs and SFs.

(d) *Synthetic tau filaments*

Whether hyperphosphorylation and abnormal phosphorylation of tau are sufficient for PHF formation is unclear. Phosphorylated recombinant tau has consistently failed to assemble into PHF-like filaments in experiments *in vitro*. In contrast, incubation of recombinant tau with sulphated glycosaminoglycans such as heparin and heparan sulphate results in the bulk assembly of tau into Alzheimer-like filaments (figure 4) (Goedert *et al*. 1996; Pérez *et al*. 1996; Arrasate *et al*. 1997; Hasegawa *et al*. 1997; Friedhoff *et al*. 1998). Tau isoforms with three repeats assemble into twisted paired helical-like filaments, whereas tau isoforms with four repeats assemble into straight filaments. By immunoelectron microscopy, the paired helical-like filaments are decorated by antibodies directed against the N- and C-termini of tau, but not by an antibody directed against the microtubule-binding repeat region. These results, which indicate that in the filaments the repeat region of tau is inaccessible to the antibody, are identical to those previously obtained with PHFs from the brains of Alzheimer's disease patients (Goedert *et al*. 1992*b*, 1996). They establish that the microtubule-binding repeat region of tau is essential for sulphated glycosaminoglycan-induced filament formation. The dimensions of tau filaments formed in the presence of sulphated glycosaminoglycans are similar to those of filaments extracted from Alzheimer's disease brain, with

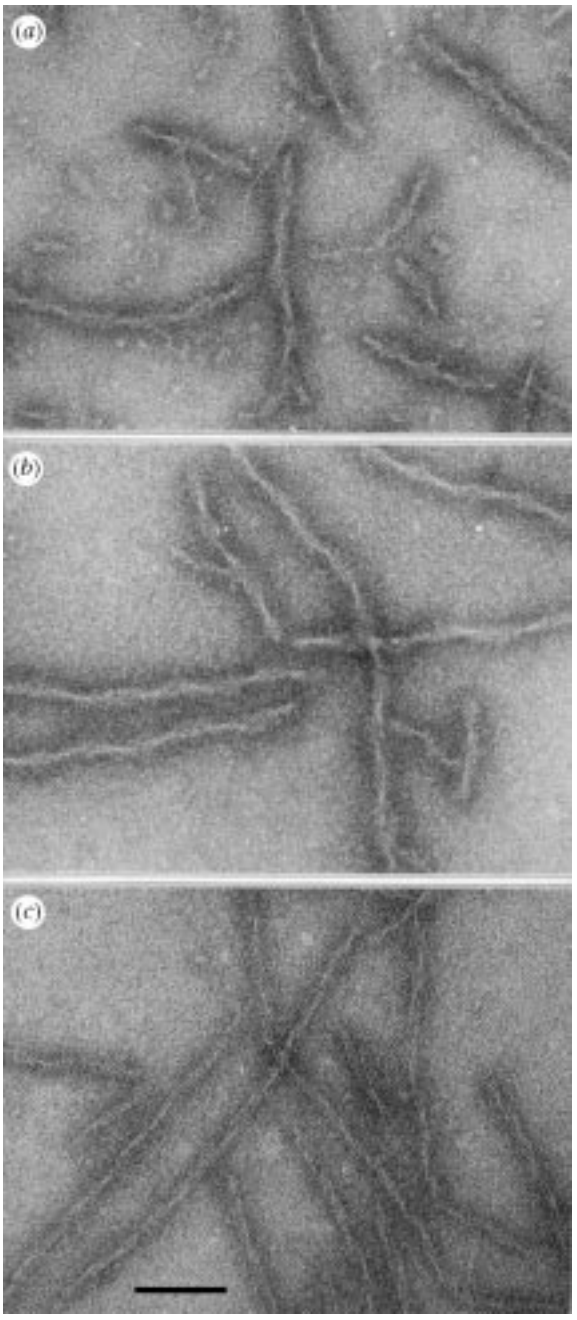

Figure 4. Sulphated glycosaminoglycan-induced filament assembly. (*a*) Recombinant three-repeat htau37 (381-residue isoform of human tau) was incubated with heparin. (*b*) htau37 was incubated with heparan sulphate. (*c*) Recombinant four-repeat htau40 (441-residue isoform of human tau) was incubated with heparin. Note the presence of paired helical-like filaments in (*a*) and (*b*) and straight filaments in (*c*). Scale bar, 100 nm.



Figure 5. Schematic representation of tau bands from filamentous assemblies of different tauopathies. Type I includes Alzheimer's disease and a number of other dementing disorders and is characterized by tau bands of 60, 64, 68 and 72 kDa. It includes Seattle family A, an FTDP-17 with a V337M mutation in exon 12 of the tau gene. Type II consists of Pick's disease and is characterized by two major tau bands of 60 and 64 kDa. Type III comprises progressive supranuclear palsy, corticobasal degeneration, familial multiple system tauopathy with presenile dementia (MSTD), pallido-ponto-nigral degeneration (PPND), Dutch family 1 and familial progressive subcortical gliosis (PSG). Familial MSTD is an FTDP-17 with a mutation in the intron following exon 10 of the tau gene (at position + 3), PPND is an FTDP-17 with a N279K mutation in exon 10, Dutch family 1 is an FTDP-17 with a P301L mutation in exon 10 of the tau gene and familial PSG is an FTDP-17 with a mutation in the intron following exon 10 of the tau gene (at position + 16). Type III is characterized by two major tau bands of 64 and 68 kDa and a minor band of 72 kDa. Abbreviation: GSS, Gerstmann–Sträussler–Scheinker disease.

Table 2. *Tau mutations, isoforms and filaments in FTDP-17*

tau mutation	soluble tau	filamentous tau	tau filaments
P301L (exon 10)	normal ratio of 3- to 4-repeat isoforms (4-repeat isoforms mutated)	4-repeat isoforms; small amount of 3-repeat isoform	narrow twisted ribbons in neurons and glia
intron following exon 10, N279K (exon 10)	abnormal preponderance of 4- over 3-repeat isoforms	4-repeat isoforms	wide twisted ribbons in neurons and glia
V337M (exon 12), R406W (exon 13)	normal ratio of 3- to 4-repeat isoforms (all isoforms mutated)	all 6 isoforms	paired helical filaments and straight filaments in neurons

a diameter of *ca.* 20 nm for twisted filaments and 15 nm for straight filaments, with a crossing-over spacing of *ca.* 80 nm for paired helical-like filaments, although their twist is in general less regular than in Alzheimer's disease filaments.

Sulphated glycosaminoglycans also stimulate the phosphorylation of tau by a number of protein kinases, prevent the binding of tau to taxol-stabilized microtubules and disassemble microtubules assembled from tau and tubulin (Hasegawa *et al.* 1997; Qi *et al.* 1998). Moreover, heparan sulphate has been detected in nerve cells in the early stages of neurofibrillary degeneration (Snow *et al.* 1989; Goedert *et al.* 1996). Sulphated glycosaminoglycans stimulate tau phosphorylation at lower concentrations than those required for filament formation. The pathological presence of heparan sulphate within the cytoplasm of some nerve cells, perhaps as a result of leakage from membrane-bound compartments, would lead first to the hyperphosphorylation of tau, resulting in its inability to bind to microtubules. At higher concentrations of heparan sulphate, tau would then assemble into PHFs and SFs. The formation of tau filaments is also observed after the incubation of recombinant tau with RNA, which has been shown to be sequestered in the neurofibrillary lesions of Alzheimer's disease (Kampers *et al.* 1996; Ginsberg *et al.* 1997, 1998; Hasegawa *et al.* 1997). Whether the presence of RNA is an early event remains to be determined.

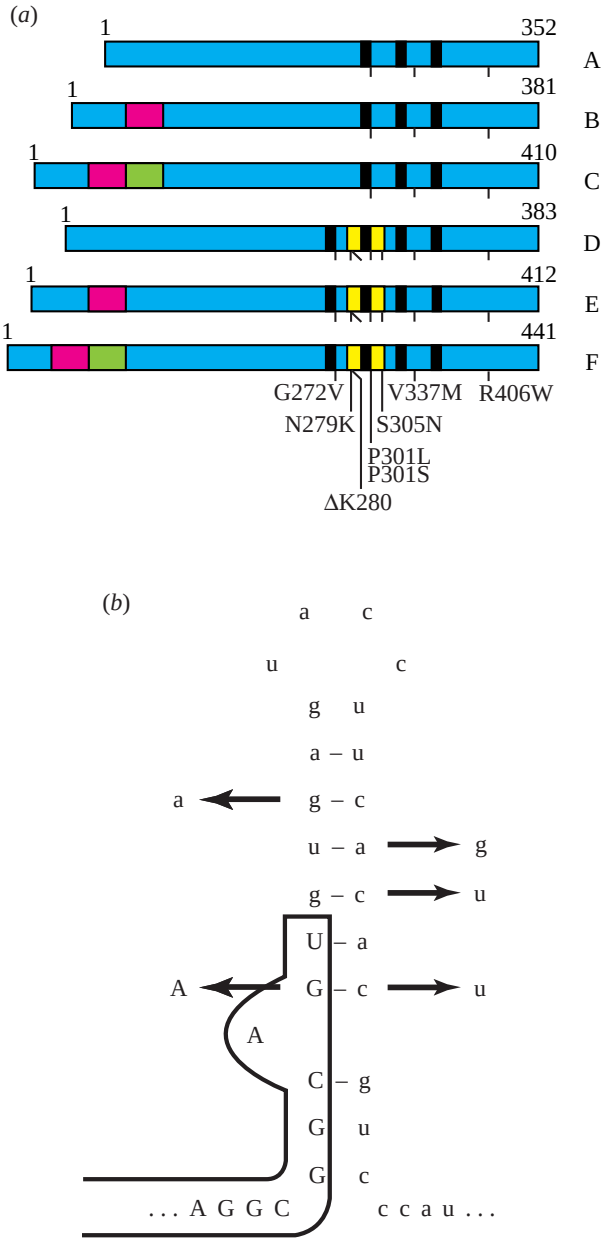

Figure 6. Mutations in the tau gene in frontotemporal dementia and Parkinsonism linked to chromosome 17 (FTDP-17). (*a*) Schematic diagram of the six tau isoforms (A–F) that are expressed in adult human brain. Alternatively spliced exons are shown in red (exon 2), green (exon 3) and yellow (exon 10); black bars indicate the microtubule-binding repeats. Seven mis-sense mutations and one deletion mutation in the coding region are shown. They affect all six tau isoforms, with the exception of N279K, ΔK280, P301L, P301S and S305N, which affect only tau isoforms with four microtubule-binding repeats. Amino acid numbering corresponds to the 441-residue isoform of human brain tau. (*b*) Predicted stem–loop in the pre-mRNA at the exon 10–5′ intron boundary. The probable destabilizing effects of the S305N mutation and the four intronic mutations are indicated. Exon sequences are shown in capital and intron sequences in lower-case letters.

Sulphated glycosaminoglycans and RNA share a repeat sugar backbone and negative charges in the form of sulphates or phosphates. Tau protein is thought to be an extended molecule with little secondary structure that becomes partly structured on binding to microtubules. Binding of sulphated glycosaminoglycans or RNA to tau might induce or stabilize a conformation of tau that brings the microtubule-binding repeats of individual tau molecules into close proximity, creating sites that favour polymerization into filaments.

(e) *Experimental animal models*

The work on synthetic tau filaments has provided the first robust methods by which to produce Alzheimer-like filaments from full-length tau. The same cannot yet be said of tau filaments in nerve cells. So far, there has been no demonstration of Alzheimer-like filaments in transgenic mice. Two studies have directly addressed this issue by expressing wild-type human tau in mouse brain (Götz *et al.* 1995; Brion *et al.* 1999; Goedert & Hasegawa 1999). It has been addressed indirectly in transgenic mouse models of Aβ deposition, which are based on the expression of mutated APP (Games *et al.* 1995; Hsiao *et al.* 1996; Sturchler-Pierrat *et al.* 1997). Although some staining for hyperphosphorylated tau has been described in nerve cell processes around Aβ deposits in transgenic mice expressing mutated APP, no somatodendritic staining of hyperphosphorylated tau was observed in these mice. Two of these mouse lines did not exhibit nerve cell loss, whereas a third showed a 17% decrease in the number of nerve cells in layer CA1 of the hippocampus (Irizarry *et al.* 1997*a*,*b*; Calhoun *et al.* 1998). However, it remains to be seen whether this cell loss is mechanistically related to the nerve cell loss observed in Alzheimer's disease hippocampus. Mutated APP is expressed at high levels in these mice and this could in itself result in the degeneration of some nerve cells.

Expression of human tau in transgenic mouse has used either the longest or the shortest brain isoforms (Götz *et al.* 1995; Brion *et al.* 1999). Both studies described broadly similar results, in that they showed strong somatodendritic and axonal staining for hyperphosphorylated tau in subpopulations of nerve cells. By electron microscopy, transgenic human tau was associated with microtubules in axons and dendrites but not in nerve cell bodies, where it was associated with ribosomes or distributed more diffusely (Brion *et al.* 1999). Overexpression of human tau in lamprey neurons has also been shown to lead to the presence of hyperphosphorylated human tau in the somatodendritic compartment (Hall *et al.* 1997). It therefore seems that an excess of tau over available binding sites on microtubules results in the accumulation of tau in nerve cell bodies.

Somatodendritic staining for hyperphosphorylated tau has been described as an early pathological change in human brain, where it is characteristic of the so-called 'pre-tangle' stage of Alzheimer's disease (Braak *et al.* 1994). In human brain, the pre-tangle pathology progresses to the filamentous tangle stage, which is followed by nerve cell degeneration and death. So far, tau filaments have not been observed in brains of mice transgenic for tau protein. There is no evidence to suggest the presence of nerve cell loss in these mice, indicating that the prolonged presence of hyperphosphorylated tau in the somatodendritic compartment of nerve cells is not sufficient to lead to nerve cell degeneration. The current transgenic mouse models therefore go only part of the way towards a filamentous tau pathology.

3. OTHER TAUOPATHIES

Filamentous tau protein deposits are the defining pathological characteristics of neurodegenerative diseases other than Alzheimer's disease (Spillantini & Goedert 1998). In these diseases, tau pathology is found in the absence of Aβ amyloid deposits. Pick's disease is the prototypical frontotemporal dementia, with Pick bodies as its central pathological characteristic (Alzheimer 1911). The latter consist of abnormal filaments that comprise hyperphosphorylated tau protein (table 1) (Rewcastle & Ball 1968; Pollock *et al.* 1986). Unlike PHFs and SFs from Alzheimer's disease brain, Pick body filaments contain only three tau isoforms, each with three microtubule-binding repeats (figure 5) (Sergeant *et al.* 1997*a*; Delacourte *et al.* 1998). Over the past few years, familial frontotemporal dementias, some with Parkinsonism, have been recognized as a previously unknown group of dementing disorders (Foster *et al.* 1997). Their unifying pathological characteristic is the presence of abundant filamentous tau deposits (Spillantini *et al.* 1998*c*). In some of these families, tau deposits are found in both nerve cells and glial cells, whereas in others, only nerve cells are affected. Ultrastructurally, depending on the families, tau filaments are either identical to those from Alzheimer's disease brain or show twisted ribbon-like morphologies (table 2) (Spillantini *et al.* 1996, 1997*b*, 1998*e*; Reed *et al.* 1997, 1998). Biochemically, these filaments fall into at least three separate groups: they consist either of all six brain tau isoforms (as in Seattle family A), or they consist predominantly (as in Dutch family 1) or exclusively (as in familial multiple system tauopathy with presenile dementia (MSTD) in pallido-ponto-nigral degeneration and in familial progressive subcortical gliosis (PSG)) of only three tau isoforms, each with four microtubule-binding repeats (table 2, figure 5) (Spillantini *et al.* 1996, 1997*b*, 1998*e*; Reed *et al.* 1998; Goedert *et al.* 1999). A biochemical tau pattern similar to that of familial MSTD and familial PSG is present in progressive supranuclear palsy and corticobasal degeneration, two largely sporadic tauopathies (table 1, figure 5) (Flament *et al.* 1991; Ksiezak-Reding *et al.* 1994). Intriguingly, an intronic polymorphism in the tau gene has been reported to be a risk factor for progressive supranuclear palsy (Conrad *et al.* 1997).

(a) *Tau mutations in FTDP-17*

Aside from having a filamentous tau pathology in common, the familial frontotemporal dementias also share genetic linkage to chromosome 17q21–22, the same region as that containing the tau gene (Wilhelmsen *et al.* 1994). They have therefore been grouped together under the heading of 'frontotemporal dementia and Parkinsonism linked to chromosome 17' (FTDP-17) (Foster *et al.* 1997; Spillantini *et al.* 1998*c*).

Over the past year, the first mutations in the tau gene have been discovered in a number of these families (figure 6) (Poorkaj *et al.* 1998; Hutton *et al.* 1998; Spillantini *et al.* 1998*d*). The speed with which mutations are being discovered suggests that a defective tau gene is a major cause of inherited dementing disease. The mutations are either missense or deletion mutations in the microtubule-binding repeat region and the C-terminal region, or intronic mutations located close to the splice-donor site of the intron following exon 10 (figure 6) (Hardy *et al.* 1998; Goedert *et al.* 1998*b*). Missense mutations have been found in exons 9, 10, 12 and 13 of the tau gene. They change glycine-272 to valine (G272V), asparagine-279 to lysine (N279K), proline-301 to either leucine (P301L) or serine (P301S), serine-305 to asparagine (S305N), valine-337 to methionine (V337M) and arginine-406 to tryptophan (R406W) (figure 6) (Poorkaj *et al.* 1998; Hutton *et al.* 1998; Spillantini *et al.* 1998*d*; Dumanchin *et al.* 1998; Clark *et al.* 1998; Mirra *et al.* 1999; Bugiani *et al.* 1999; Iijima *et al.* 1999). A mutation that deletes lysine-280 (ΔK280) has been found in exon 10 (figure 6) (Rizzu *et al.* 1999). So far, five different mutations have been described in the 31-residue alternatively spliced exon 10. They affect only four-repeat tau isoforms. In contrast, the other four missense mutations are present in all six brain tau isoforms. Four different intronic mutations have been found close to the splice-donor site of the intron following exon 10 (at positions +3, +13, +14 and +16, with the first nucleotide of the invariant splice-donor site sequence taken as +1) (figure 6) (Hutton *et al.* 1998; Spillantini *et al.* 1998*d*; Goedert *et al.* 1999). These mutations disrupt a predicted stem–loop structure located at the exon 10–5′ intron boundary. The S305N missense mutation, which is located in the last residue of exon 10, also disrupts the predicted stem–loop (Iijima *et al.* 1999).

The presence of a stem–loop at the exon 10–5′ intron boundary of the tau gene has been inferred from predictions of secondary structure (Hutton *et al.* 1998; Spillantini *et al.* 1998*d*). Its existence has been put on a firm footing with the determination of the three-dimensional structure by nuclear magnetic resonance spectroscopy of a 25-mer oligonucleotide extending from positions −5 to +19 (Varani *et al.* 1999), showing that the stem–loop forms a stable, folded structure. The stem consists of a lower and an upper part, separated by a bulged adenine at position −2, with the loop consisting of six nucleotides. The structure of the tau exon 10 regulatory element (Varani *et al.* 1999) differs in several respects from the predicted structures (Hutton *et al.* 1998; Spillantini *et al.* 1998*d*). The known intronic mutations are located in the upper part of the stem, which is destabilized as a result, as judged by a marked decrease in melting temperatures.

Recombinant tau proteins carrying missense mutations or the deletion mutation have a decreased ability to promote microtubule assembly, which is more marked for three-repeat than for four-repeat isoforms (Hasegawa *et al.* 1998; Rizzu *et al.* 1999; Bugiani *et al.* 1999). Of the mutations tested, the P301L and ΔK280 mutations in exon 10 had the largest effects (Hasegawa *et al.* 1998; Rizzu *et al.* 1999). The likely primary effect of these mutations is thus a decreased ability of mutated tau to interact with microtubules, which amounts to a partial loss of function.

The net effect of the intronic mutations is increased splicing in of exon 10, leading to a change in the ratio of three-repeat to four-repeat tau isoforms and resulting in an overproduction of four-repeat isoforms (Hutton *et al.* 1998; Spillantini *et al.* 1998*d*; Goedert *et al.* 1999). Earlier work had suggested that three-repeat and four-repeat tau isoforms might bind to different sites on microtubules (Goode & Feinstein 1994). The overproduction of tau

isoforms with four repeats might result in an excess of tau over available binding sites on microtubules, equivalent to a partial loss of function of the unbound excess tau. Increased splicing in of exon 10 also seems to be the primary mechanism by which the missense mutations N279K and S305N lead to dementia (Hasegawa *et al.* 1999). Recombinant tau proteins with these mutations do not show a decreased ability to promote microtubule assembly, unlike tau proteins with other missense mutations. However, by exon trapping, both mutations lead to increased splicing in of exon 10, exactly as in the intronic mutations (Hasegawa *et al.* 1999). This is explained by the fact that the N279K mutation creates an exon-splice enhancer sequence, whereas the S305N mutation destabilizes the predicted stem–loop at the exon 10–5′ intron boundary (Clark *et al.* 1998; Hong *et al.* 1998; Iijima *et al.* 1999). Thus, the known mutations in the tau gene either produce a decreased ability to promote microtubule assembly or lead to increased splicing in of exon 10, resulting in the overproduction of four-repeat isoforms (Goedert *et al.* 1998*b*).

(b) *Pathogenesis of FTDP-17*

The pathway leading from a mutation in the tau gene to neurodegeneration is unknown. A partial loss of function of tau resulting from the mutations could lead to the destabilization of microtubules, with deleterious consequences for cellular processes, such as rapid axonal transport. However, in the intronic mutations, where four-repeat tau is overproduced, this seems unlikely. Moreover, mutations in exon 10 will affect only 20–25% of tau molecules, with 75–80% of tau being normal (Goedert *et al.* 1998*b*).

It is possible, however, that a correct ratio of wild-type three-repeat to four-repeat tau is essential for the normal function of tau in human brain. An alternative hypothesis is that a partial loss of function of tau is necessary for setting in motion the mechanisms that ultimately lead to filament assembly. Besides leading to a partial loss of function phenotype, tau mutations might have additional effects on phosphorylation and filament assembly.

Where studied, pathological tau from FTDP-17 brain is hyperphosphorylated. As the known mutations in tau do not create additional phosphorylation sites (with the possible exception of the P301S mutation), hyperphosphorylation of tau must be an event downstream of the primary effects of the mutations and might be a consequence of the partial loss of function. It probably reinforces the effects of the mutations, because it is well established that hyperphosphorylated tau is unable to bind to microtubules (Bramblett *et al.* 1993; Yoshida & Ihara 1993). The steps lying between hyperphosphorylation of tau and assembly into filaments are at present unknown.

The emerging picture is that of a remarkably direct correspondence between the locations of tau mutations, the cellular pathology, and the isoform compositions and morphologies of tau filaments (table 2, figure 7). Mutations in exon 10 lead to a neuronal and glial tau pathology, with the narrow twisted ribbon-like filaments being made predominantly of four-repeat tau isoforms. Mutations in the intron following exon 10 lead to a neuronal and glial tau pathology, with the wide twisted ribbon-like filaments being made of only four-repeat tau isoforms. This contrasts with missense mutations located outside exon 10 that lead to a mostly neuronal pathology, with the Alzheimer-type PHFs and SFs being made of all six tau isoforms (Goedert *et al.* 1998*b*).

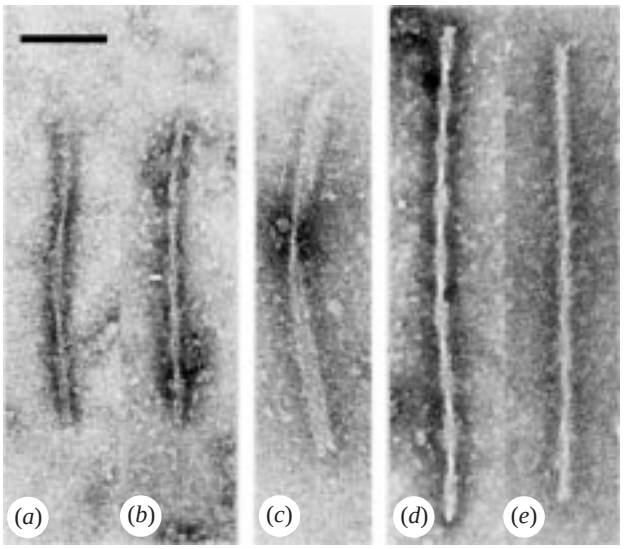

Figure 7. Tau filaments in FTDP-17. Dutch family 1 (with the P301L mutation in exon 10) is characterized by the presence of narrow twisted ribbons (*a*), and occasional rope-like filaments (*b*). The tau pathology is both neuronal and glial. Familial multiple system tauopathy with presenile dementia (with the +3 intronic mutation) is characterized by wide twisted ribbons (*c*), which might be formed by two copies of the narrow twisted ribbons joined across the central axis. The tau pathology is both neuronal and glial. Seattle family A (with the V337M mutation in exon 12) is characterized by the presence of paired helical (*d*), and straight (*e*), filaments. The tau pathology is largely neuronal. Scale bar, 100 nm. (Reproduced from Goedert *et al.* (1998*b*).)

It is unclear why some mutations lead to a neuronal and glial tau pathology, whereas others result in a largely neuronal pathology. In normal human brain, tau protein is confined mostly to nerve cells, where it is concentrated in axons (Binder *et al.* 1985). Although it is not known which isoforms account for the low levels of tau in glial cells, the cellular pathology of FTDP-17 is compatible with nerve cells expressing all six tau isoforms and glial cells expressing predominantly four-repeat isoforms. For mutations located outside exon 10, the ordered assembly of tau into filaments might be driven by three-repeat isoforms, leading to the formation of PHFs and SFs in nerve cells. Four-repeat tau isoforms drive filament assembly when tau mutations are located in exon 10 or in the intron following exon 10, resulting in the formation of twisted ribbon-like filaments in both nerve cells and glial cells.

It is perhaps not suprising that mutations that affect predominantly four-repeat isoforms give rise to filaments with different morphologies from those resulting from mutations that affect all six tau isoforms. It is well established that the repeat region of tau forms the densely packed core of PHFs and SFs, with the N- and C-terminal parts of the molecule forming a proteolytically sensitive coat (Wischik *et al.* 1988; Goedert *et al.* 1992*b*). Moreover, the morphology of filaments assembled *in vitro*

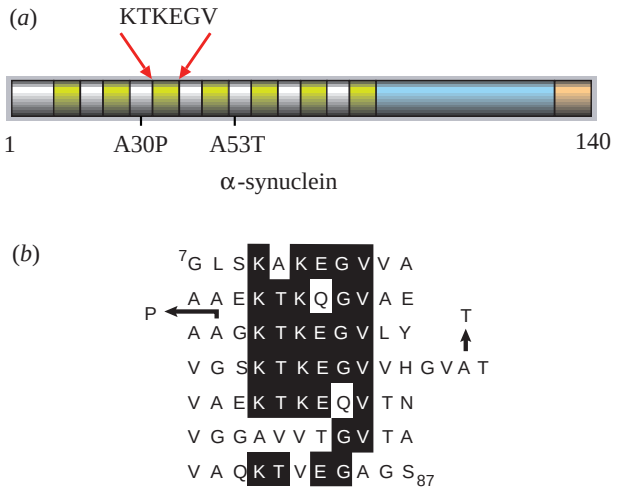

Figure 8. Mutations in the α-synuclein gene in familial Parkinson's disease. (*a*) Schematic diagram of human α-synuclein. The seven repeats with the consensus sequence KTKEGV are shown as green bars. The hydrophobic region is shown in blue and the negatively charged C-terminus in yellow. The two known missense mutations are indicated. (*b*) Repeats in human α-synuclein. Residues 7–87 of the 140-residue protein are shown. Amino-acid identities between at least five of the seven repeats are indicated by black bars. The Ala→Pro mutation at residue 30 between repeats two and three and the Ala→Thr mutation at residue 53 between repeats four and five are shown. (Reproduced from Goedert & Spillantini (1998).)

in the presence of sulphated glycosaminoglycans depends on the number of repeats in the tau isoform used (Goedert *et al.* 1996). Thus, mutations in the repeat region or a change in the relative amounts of three- and four-repeat isoforms could well influence filament morphology.

The most important feature of the tau assemblies might be their extended filamentous nature and the deleterious effects that this has on intracellular processes, rather than the detailed morphology of the different filaments. The new work has firmly established that the events leading to a filamentous tau pathology or the mere presence of tau filaments are sufficient for the degeneration of affected nerve cells and glial cells and the onset of dementia.

4. LEWY BODY DISEASES

(a) *Parkinson's disease*

Parkinson's disease is a movement disorder characterized by tremor, rigidity and bradykinesia. Neuropathologically, it is defined by nerve cell loss in the substantia nigra and several other regions of the nervous system and by the presence of Lewy bodies and Lewy neurites. Under the light microscope, brainstem Lewy bodies appear as round, intracytoplasmic inclusions, 5–25 μm in diameter, with a dense eosinophilic core and a clearer surrounding corona (Lewy 1912). Ultrastructurally, they are composed of a core of filamentous and granular material that is surrounded by radially orientated filaments 10–20 nm in diameter (Duffy & Tennyson 1965; Forno 1996). Lewy neurites constitute an important component of the pathology of Parkinson's disease. They correspond

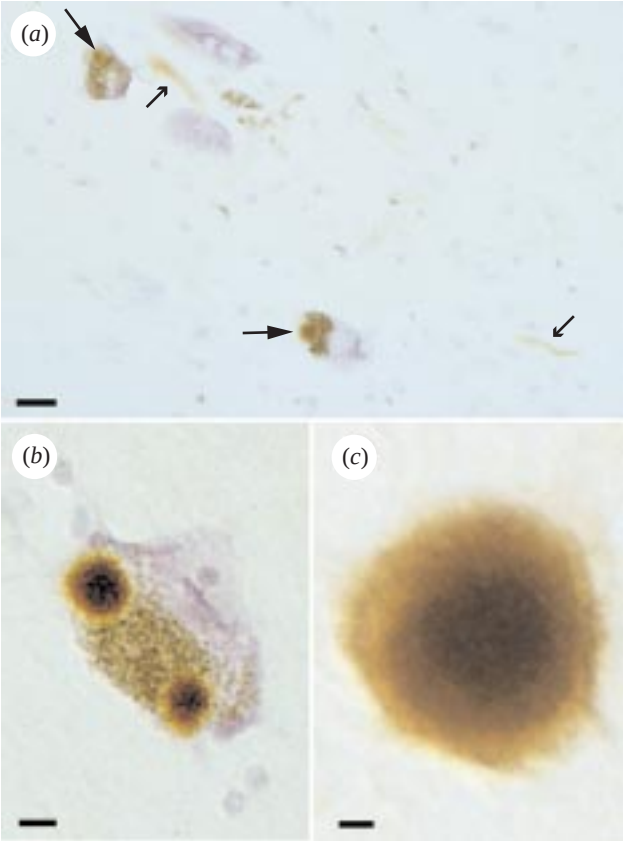

Figure 9. Substantia nigra from patients with Parkinson's disease immunostained for α-synuclein. (*a*) Two pigmented nerve cells, each containing an α-synuclein-positive Lewy body (thin arrows). Lewy neurites (thick arrows) are also immunopositive. Scale bar, 20 μm. (*b*) Pigmented nerve cell with two α-synuclein-positive Lewy bodies. Scale bar, 8 μm. (*c*) α-Synuclein-positive extracellular Lewy body. Scale bar, 4 μm. (Reproduced from Spillantini *et al.* (1997*a*).)

to abnormal neurites that have the same immunohistochemical staining profile as Lewy bodies and consist ultrastructurally of abnormal filaments similar to those found in Lewy bodies.

Despite much work, the biochemical nature of the Lewy body filament remained unknown until recently. On the basis of immunohistochemical findings, some had reached the conclusion that neurofilaments constitute the major filament component (Anderton 1997). However, this type of work does not distinguish between intrinsic Lewy body components and normal cellular constituents that merely become trapped in the filaments that make up the Lewy body. A similar problem plagued the field of Alzheimer's disease over part of the 1980s. It was solved with the purification and analysis of PHFs and SFs (Goedert *et al.* 1988; Wischik *et al.* 1988; Kondo *et al.* 1988). A similar approach with Lewy bodies has met with only partial success, mainly because Lewy bodies and Lewy neurites are less abundant than neurofibrillary lesions (Iwatsubo *et al.* 1996). This was the situation until the middle of 1997, when genetics came to the rescue, taking us straight to the very core of the Lewy body filament.

Most cases of Parkinson's disease are sporadic, without an obvious family history. However, a small percentage is

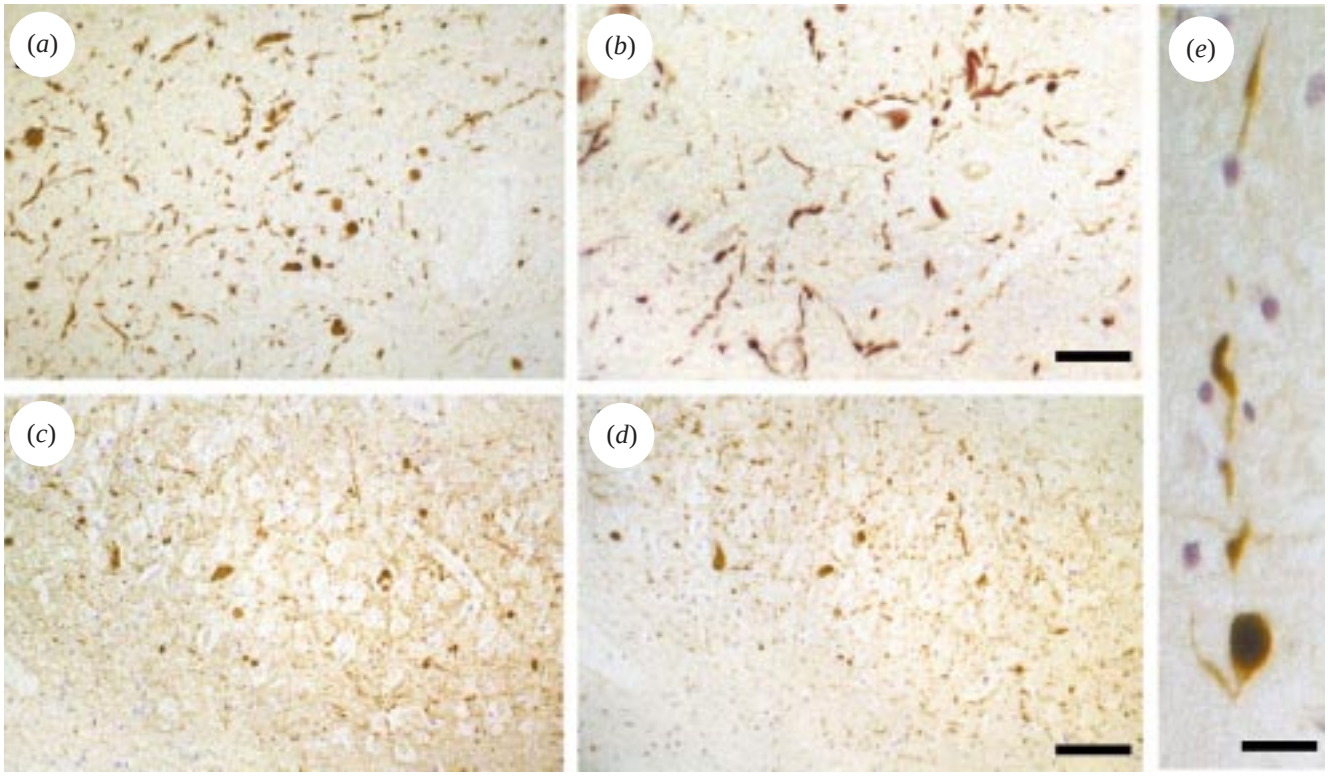

Figure 10. Brain tissue from patients with dementia with Lewy bodies immunostained for α-synuclein. (*a*,*b*) α-Synuclein-positive Lewy bodies and Lewy neurites in substantia nigra stained with antibodies recognizing the N-terminal (*a*) or the C-terminal (*b*) region of α-synuclein. Scale bar in (*b*), 100 μm (for (*a*) and (*b*)). (*c*,*d*) α-Synuclein-positive Lewy neurites in serial sections of hippocampus stained with antibodies recognizing the N-terminal (*c*) or the C-terminal (*d*) region of α-synuclein. Scale bar in (*d*), 80 μm (for (*c*) and (*d*)).(*e*) α-Synuclein-positive intraneuritic Lewy body in a Lewy neurite in substantia nigra stained with an antibody recognizing the C-terminal region of α-synuclein. Scale bar, 40 μm. (Reproduced from Spillantini *et al*. (1998*a*).)

familial and inherited in an autosomal-dominant manner. Two separate missense mutations have been discovered in the α-synuclein gene in kindreds with early-onset familial Parkinson's disease (figure 8) (Polymeropoulos *et al*. 1997; Krüger *et al*. 1998). The first mutation, which changes residue 53 in α-synuclein from alanine to threonine (A53T), was identified in a large Italian–American kindred and three smaller Greek pedigrees. The second mutation, which changes alanine-30 to proline (A30P), was found in a German pedigree with early-onset Parkinson's disease.

α-Synuclein is a 140-residue protein of unknown function that is abundantly expressed in brain, where it is located in presynaptic nerve terminals, with little staining of nerve cell bodies and dendrites (Uéda *et al*. 1993; Jakes *et al*. 1994). Two related proteins, called β-synuclein and γ-synuclein (or BCSG1), have also been described in brain (Nakajo *et al*. 1993; Jakes *et al*. 1994; Ji *et al*. 1997). The N-terminal half of each synuclein is taken up by imperfect repeats, with the consensus sequence KTKEGV (single-letter codes). These repeats are followed by a hydrophobic middle region and a negatively charged C-terminal region (figure 8). Both the A30P and A53T mutations lie in the repeat region of α-synuclein. It seems likely that α-synuclein binds through its repeats to other cellular components. Recent work has shown that it does bind through the repeats to synthetic vesicles and to vesicle preparations from rat brain (Davidson *et al*. 1998; Jensen *et al*. 1998). Interestingly, the A30P mutation was found to be devoid of significant vesicle-binding activity (Jensen *et al*. 1998).

Although the A53T mutation in α-synuclein accounts for only a small percentage of familial cases of Parkinson's disease, its identification was quickly followed by the discovery that α-synuclein is the major component of Lewy bodies and Lewy neurites in all cases of Parkinson's disease (table 1, figure 9) (Spillantini *et al*. 1997*a*). Full-length, or close to full-length, α-synuclein has been found in Lewy bodies and Lewy neurites, with both the core and the corona of the Lewy body being stained. Staining for α-synuclein has been found to be more extensive than staining for ubiquitin, which was until then the most sensitive marker for Lewy bodies and Lewy neurites (Kuzuhara *et al*. 1988; Spillantini *et al*. 1998*a*). The Lewy body pathology does not stain for β-synuclein or γ-synuclein. Thus, of the three brain synucleins, only α-synuclein is of relevance in the context of Parkinson's disease. The original finding that α-synuclein is present in Lewy bodies and Lewy neurites (Spillantini *et al*. 1997*a*) was rapidly confirmed and extended (Wakabayashi *et al*. 1997, 1998*b*; Takeda *et al*. 1998*a*,*b*; Baba *et al*. 1998; Irizarry *et al*. 1998; Mezey *et al*. 1998*a*,*b*; Arima *et al*. 1998*b*; Lippa *et al*. 1998).

The A30P and A53T mutations might promote the aggregation of α-synuclein into filaments, resulting in the formation of Lewy bodies and Lewy neurites. Alternatively, they might interfere with a normal property of α-synuclein that could in turn indirectly facilitate

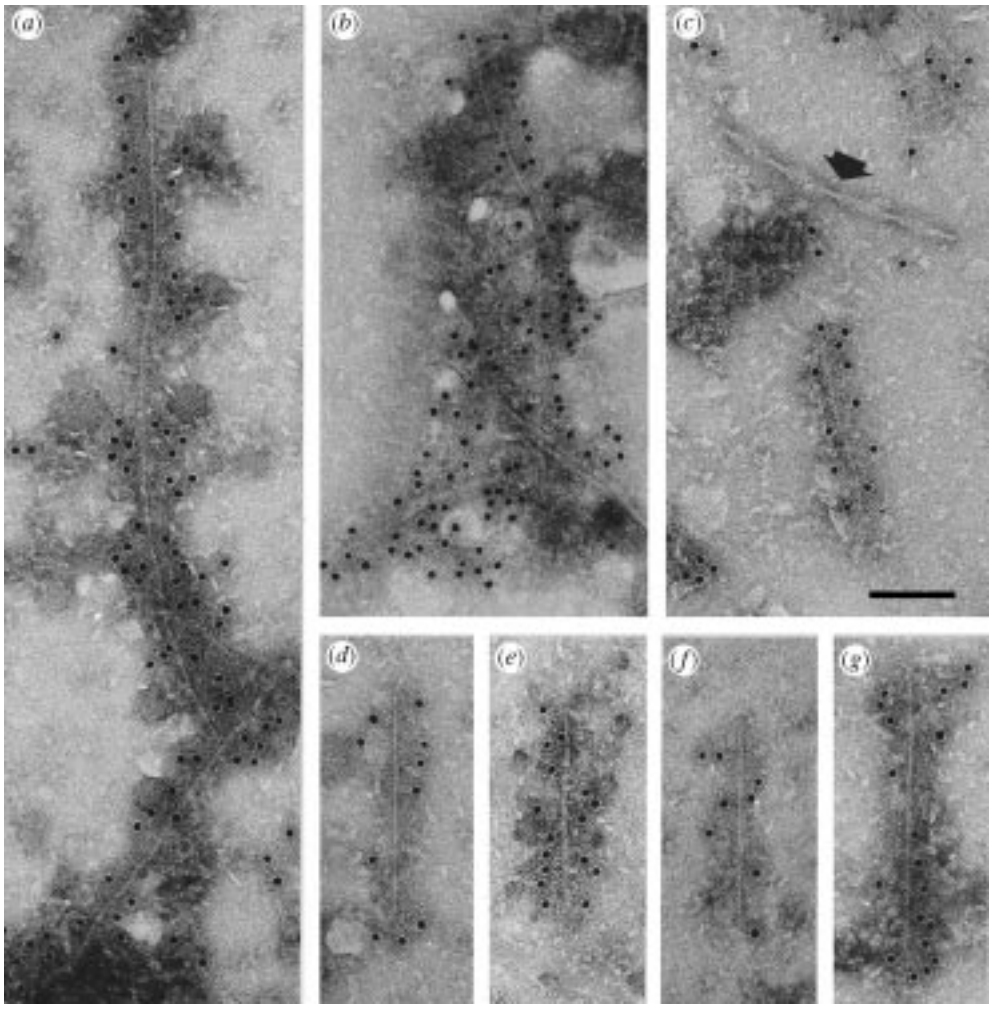

Figure 11. (*a*,*b*) Filaments from cingulate cortex of patients with dementia with Lewy bodies immunolabelled for α-synuclein. Small clumps of α-synuclein filaments. (*c*) A labelled α-synuclein filament and an unlabelled paired helical filament (arrow). (*d*–*g*) The labelled filaments have various morphologies, including 5 nm filament (*d*), 10 nm filament with dark stain penetrating centre line (*e*), twisted filament showing alternating width (*f*) and 10 nm filament with slender 5 nm extensions at ends ((*g*), also (*c*)). The 10 nm gold particles attached to the secondary antibody appear as black dots. Scale bar, 100 nm (in (*c*)). (Reproduced from Spillantini *et al*. (1998*a*).)

assembly into filaments. In either case, the net effect would be akin to a gain of toxic function. In idiopathic Parkinson's disease, as yet unknown modifications in α-synuclein or interactions with other components might lead to aggregation into filaments. Lewy bodies and Lewy neurites are space-occupying lesions that fill most of the cytoplasm of affected nerve cells. This might, in turn, lead to the entrapment of normal cellular components, possibly explaining the variable staining of Lewy bodies and Lewy neurites for neurofilaments and other proteins. Over time, the presence of Lewy bodies and Lewy neurites is likely to lead to nerve cell degeneration (Goedert 1997; Goedert & Spillantini 1998).

(b) *Dementia with Lewy bodies*

Lewy bodies and Lewy neurites also constitute the defining neuropathological characteristics of dementia with Lewy bodies, a common late-life dementia that exists in a pure form or overlaps with the neuropathological characteristics of Alzheimer's disease, especially Aβ deposits. Some studies have suggested that dementia with Lewy bodies is the second most common cause of dementia, after Alzheimer's disease.

Unlike Parkinson's disease, it is characterized by the presence of numerous Lewy bodies and Lewy neurites in cerebral cortex (Kosaka 1978). As in Parkinson's disease, the Lewy body pathology is also present in the substantia nigra and other subcortical regions. Lewy bodies and Lewy neurites from dementia with Lewy bodies are strongly immunoreactive for α-synuclein, exactly as in the pathological features of Parkinson's disease (table 1, figure 10) (Spillantini *et al*. 1997*a*). It suggests, but does not prove, that α-synuclein is the major component of the abnormal filaments that make up Lewy bodies and Lewy neurites. The pathological changes are particularly numerous in cingulate cortex, facilitating the extraction of filaments. Isolated filaments were strongly labelled for α-synuclein along their entire lengths, demonstrating that they contain α-synuclein as a major component (figure 11) (Spillantini *et al*. 1998*a*). Filament morphologies and staining characteristics with several antibodies have led to the suggestion that α-synuclein molecules might run parallel to the filament axis and that the filaments are polar structures (figure 12). Moreover, under the electron microscope, some filaments and granular material in partly purified Lewy bodies seem to be labelled by

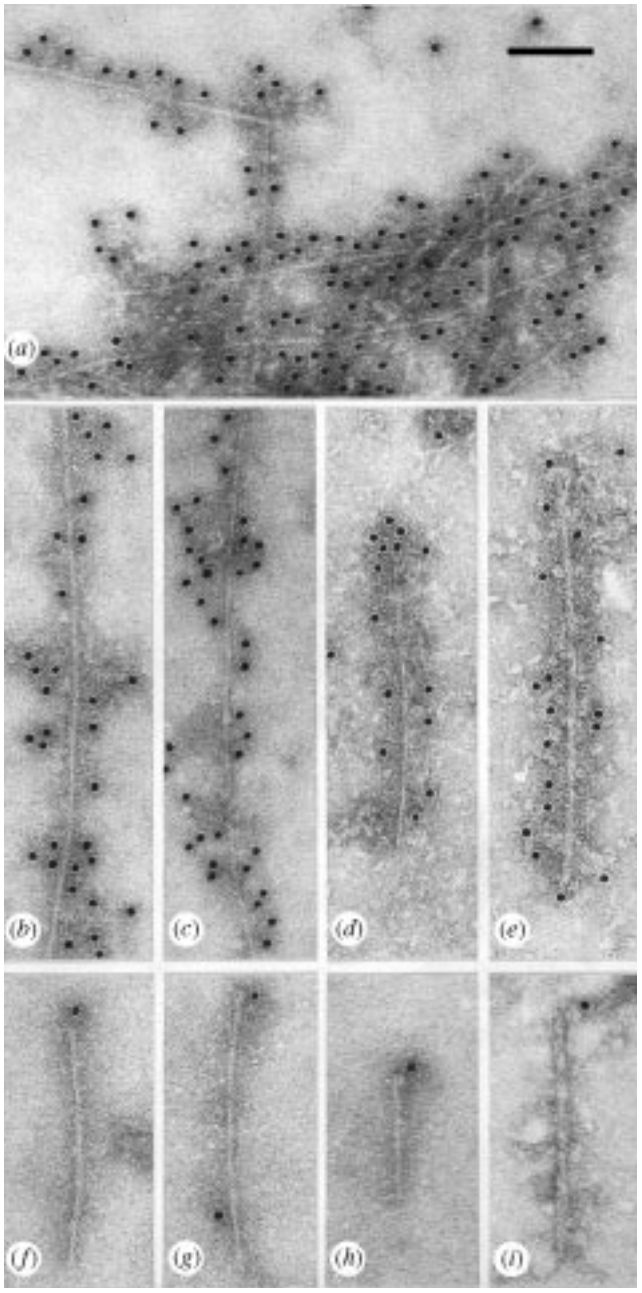

Figure 12. Immunolabelling of synthetic α-synuclein(1–120) filaments and filaments extracted from diseased brains, labelled with an antibody against the C-terminal region of α-synuclein (*a–e*) or labelled with an antibody directed against the N-terminal region of α-synuclein (*f–i*). (*a–c*) α-Synuclein(1–120) filaments showing a labelled clump and individual filaments. (*d*,*e*) Filaments extracted from brains with Lewy body dementia (*d*) or multiple system atrophy (*e*). (*f–i*) End-labelled filaments, showing α-synuclein (1–120) filaments (*f–h*) and a filament from a brain with multiple system atrophy (*i*). The 10 nm gold particles attached to the secondary antibody appear as black dots. Scale bar, 100 nm. (Reproduced from Crowther *et al.* (1998).)

α-synuclein antibodies (Baba *et al.* 1998). Immunoelectron microscopy has shown decoration of Lewy body filaments in tissue sections from brain of individuals with dementia with Lewy bodies.

As in Parkinson's disease, the presence of abnormal filamentous α-synuclein inclusions in nerve cells is probably the cause of nerve cell degeneration in dementia with Lewy bodies. Although most Lewy bodies are confined to the cell soma, this is not their only location. Thus, the intraneuritic Lewy body, which consists of a large, circular Lewy body within a neurite, is a most striking pathological feature of Parkinson's disease and dementia with Lewy bodies (figure 10*e*). Its presence is bound to lead to an interruption of axonal transport, akin to a nerve ligation, with obvious deleterious consequences for the whole nerve cell. Pathological structures such as this serve to illustrate the implausibility of the view expressed by some in the context of glutamine repeat diseases, namely that filamentous intraneuronal inclusions might be neutral or even have a protective effect (Saudou *et al.* 1998; Sisodia 1998).

(c) *Synthetic α-synuclein filaments*

The discovery of α-synuclein filaments in Parkinson's disease and dementia with Lewy bodies has led to attempts aimed at producing synthetic α-synuclein filaments. A first study has reported that removal of the C-terminal 20–30 residues of α-synuclein leads to spontaneous assembly into filaments within 24–48 h at 37 °C, with morphologies and staining characteristics indistinguishable from those of Lewy body filaments (figure 12) (Crowther *et al.* 1998). This indicates that the packing of α-synuclein molecules in the filaments *in vitro* is very similar to that of filaments extracted from brain. A proportion of α-synuclein extracted from partly purified Lewy bodies has been found to be truncated (Baba *et al.* 1998). In conjunction with the results of studies *in vitro*, this suggests that proteolytic degradation might have a role in the assembly of α-synuclein in Lewy body diseases. A second study on synthetic α-synuclein filaments has reported assembly from full-length protein with the A53T mutation, after incubations ranging from three weeks to two months at 37 °C (Conway *et al.* 1998). It remains to be seen whether synthetic filaments can be produced from full-length α-synuclein under certain conditions or whether C-terminal truncation is an obligatory step for assembly.

Whatever exact mechanisms underlie assembly, these findings help to establish firmly that Lewy body filaments are made of α-synuclein. Together with the light microscopic and electron microscopic studies of Lewy bodies and Lewy neurites, they refute the notion that Lewy body filaments are made of neurofilaments. They also provide first assays for the testing of compounds aimed at preventing the assembly of α-synuclein into Lewy body-like filaments.

5. MULTIPLE SYSTEM ATROPHY

Multiple system atrophy is a neurodegenerative disorder that comprises cases of olivopontocerebellar atrophy, striatonigral degeneration and Shy–Drager syndrome (Graham & Oppenheimer 1969). Clinically, it is characterized by a combination of cerebellar, extrapyramidal and autonomic symptoms.

Neuropathologically, glial cytoplasmic inclusions (GCIs), which consist of filamentous aggregates, are the defining feature of multiple system atrophy (Papp *et al.* 1989). They are found mostly in the cytoplasm and, to a smaller extent, in the nucleus of oligodendrocytes.

Inclusions are also observed in the cytoplasm and nucleus of some nerve cells, as well as in neuropil threads. They consist of straight and twisted filaments, with reported diameters of 10–30 nm (Kato & Nakamura 1990). At the light microscopic level, GCIs are immunoreactive for ubiquitin and, to a smaller extent, for cytoskeletal proteins such as tau and tubulin. However, until recently, the biochemical composition of GCI filaments was unknown.

This has changed with the discovery that GCIs are strongly immunoreactive for α-synuclein and that filaments isolated from the brains of patients with multiple system atrophy are strongly labelled by α-synuclein antibodies (table 1) (Wakabayashi *et al.* 1998*a*,*b*; Mezey *et al.* 1998*a*; Spillantini *et al.* 1998*d*; Gai *et al.* 1998; Tu *et al.* 1998; Arima *et al.* 1998*a*). The filament morphologies and their staining characteristics were found to be very similar to those of filaments extracted from cingulate cortex of patients with dementia with Lewy bodies (figure 12) (Spillantini *et al.* 1998*d*). As for the latter, staining for α-synuclein was far more extensive than staining for ubiquitin, until then the most sensitive immunohistochemical marker of GCIs (Spillantini *et al.* 1998*d*). This work refutes the view that filaments from brain with multiple system atrophy are made of tau protein or other cytoskeletal components. It indicates that α-synuclein is the major component of the GCI filaments and reveals an unexpected molecular link between multiple system atrophy and the Lewy body disorders Parkinson's disease and dementia with Lewy bodies.

6. CONCLUSION

The discovery that tau protein and α-synuclein account for the filamentous neuronal and glial inclusions of most late-onset neurodegenerative diseases has provided a unifying theme to our understanding of these disorders. The presence of mutations in the tau gene in FTDP-17 and in the α-synuclein gene in familial Parkinson's disease has underscored the crucial importance of tau and α-synuclein for the neurodegenerative process. Tau and α-synuclein are soluble proteins in normal brain. Understanding their abnormal assembly into filaments is thus central to the study of these diseases. Filament assembly seems to be an energetically unfavourable, nucleation-dependent process that requires a critical concentration of tau or α-synuclein (Goedert *et al.* 1996; Crowther *et al.* 1998). The concentration dependence of assembly might be part of the reason why some cells are much more prone to developing pathology than others. Many cells might have levels of tau or α-synuclein below the critical concentration. Other cells might have effective mechanisms for preventing the formation of nuclei or might be able to degrade them once they have formed. Insufficient protective mechanisms and tau or α-synuclein concentrations above the critical concentration might underlie the selective degeneration of nerve cells and glial cells, which constitutes a central characteristic of most neurodegenerative diseases and is responsible for the distinctive clinical phenotype of each disease (Goedert *et al.* 1998*b*).

Although tau and α-synuclein share no sequence similarities, they have some properties in common. They are both natively unfolded proteins, without much secondary structure, as reflected in the fact that they are both heat-stable (Jakes *et al.* 1994; Schweers *et al.* 1994; Weinreb *et al.* 1996). Like tau, α-synuclein contains repeats through which it can bind to other cellular components and become structured in the process. It seems that the primary effect of the tau and α-synuclein mutations is to decrease their ability to interact effectively with their respective binding partners (Hasegawa *et al.* 1998; Jensen *et al.* 1998). This partial loss of function might be necessary for setting in motion the mechanisms that lead to filament formation and the subsequent demise of affected nerve cells and glial cells. Ordered assembly into filaments as the gain of toxic function is an emerging theme in the study of neurodegenerative diseases.

REFERENCES

Alzheimer, A. 1907 Über eine eigenartige Erkrankung der Hirnrinde. *Allg. Z. Psychiat. Psych. Gerichtl. Med.* **64**, 146–148.

Alzheimer, A. 1911 Über eigenartige Krankheitsfälle des späteren Alters. *Z. Ges. Neurol. Psychiat.* **4**, 356–385.

Anderton, B. H. 1997 Changes in the ageing brain in health and disease. *Phil. Trans. R. Soc. Lond.* B **352**, 1781–1792.

Andreadis, A., Brown, M. W. & Kosik, K. S. 1992 Structure and novel exons of the human tau gene. *Biochemistry* **31**, 10 626–10 633.

Arima, K., Uéda, K., Sunohara, N., Arakawa, K., Hirai, S., Nakamura, M., Tonozuka-Uehara, H. & Kawai, M. 1998*a* NACP/α-synuclein immunoreactivity in fibrillary components of neuronal and oligodendroglial cytoplasmic inclusions in the pontine nuclei in multiple system atrophy. *Acta Neuropathol.* **96**, 439–444.

Arima, K., Uéda, K., Sunohara, N., Hirai, S., Izumiyama, Y., Tonozuka-Uehara, H. & Kawai, M. 1998*b* Immunoelectron-microscopic demonstration of NACP/α-synuclein epitopes on the filamentous component of Lewy bodies in Parkinson's disease and in dementia with Lewy bodies. *Brain Res.* **808**, 93–100.

Arrasate, M., Pérez, M., Valpuesta, J. M. & Avila, J. 1997 Role of glycosaminoglycans in determining the helicity of paired helical filaments. *Am. J. Pathol.* **151**, 1115–1122.

Arriagada, P. V., Growdon, J. H., Hedley-White, E. T. & Hyman, B. T. 1992 Neurofibrillary tangles but not senile plaques parallel duration and severity of Alzheimer's disease. *Neurology* **42**, 631–638.

Baba, M., Nakajo, S., Tu, P.-H., Tomita, T., Nakaya, K., Lee, V. M.-Y., Trojanowski, J. Q. & Iwatsubo, T. 1998 Aggregation of α-synuclein in Lewy bodies of sporadic Parkinson's disease and dementia with Lewy bodies. *Am. J. Pathol.* **152**, 879–884.

Binder, L. I., Frankfurter, A. & Rebhun, L. I. 1985 The distribution of tau in the mammalian nervous system. *J. Cell Biol.* **101**, 1371–1378.

Bondareff, W., Mountjoy, C. Q., Roth, M. & Hauser, D. L. 1989 Neurofibrillary degeneration and neuronal loss in Alzheimer's disease. *Neurobiol. Aging* **10**, 709–715.

Braak, H. & Braak, E. 1991 Neuropathological staging of Alzheimer-related changes. *Acta Neuropathol.* **82**, 239–259.

Braak, H. & Braak, E. 1997 Frequency of stages of Alzheimer-related lesions in different age categories. *Neurobiol. Aging* **18**, 351–357.

Braak, E., Braak, H. & Mandelkow, E. M. 1994 A sequence of cytoskeleton changes related to the formation of neurofibrillary tangles and neuropil threads. *Acta Neuropathol.* **87**, 554–567.

Bramblett, G. T., Goedert, M., Jakes, R., Merrick, S. E., Trojanowski, J. Q. & Lee, V. M.-Y. 1993 Abnormal tau phosphorylation at Ser396 in Alzheimer's disease recapitulates development and contributes to reduced microtubule binding. *Neuron* **10**, 1089–1099.

Brion, J. P., Passareiro, H., Nunez, J. & Flament-Durand, J. 1985 Mise en évidence immunologique de la protéine tau au niveau des lésions de dégénérescence neurofibrillaire de la maladie d'Alzheimer. *Arch. Biol.* **95**, 229–235.

Brion, J. P., Tremp, G. & Octave, J. N. 1999 Transgenic expression of the shortest human tau affects its compartmentalization and its phosphorylation as in the pretangle stage of Alzheimer's disease. *Am. J. Pathol.* **154**, 255–270.

Bugiani, O. (and 15 others) 1999 Frontotemporal dementia and corticobasal degeneration in a family with a P301S mutation in tau. *J. Neuropathol. Exp. Neurol.* (In the press.)

Calhoun, M. E., Wiederholt, K. H., Abramowski, D., Phinney, A. L., Probst, A., Sturchler-Pierrat, C., Staufenbiel, M., Sommer, B. & Jucker, M. 1998 Neuron loss in APP transgenic mice. *Nature* **395**, 755–756.

Clark, L. N. (and 18 others) 1998 Pathogenic implications of mutations in the tau gene in pallido-ponto-nigral degeneration and related neurodegenerative disorders linked to chromosome 17. *Proc. Natl Acad. Sci. USA* **95**, 13 103–13 107.

Conrad, C. (and 12 others) 1997 Genetic evidence for the involvement of tau in progressive supranuclear palsy. *Ann. Neurol.* **41**, 277–181.

Conway, K. A., Harper, J. D. & Lansbury, P. T. 1998 Accelerated *in vitro* fibril formation by a mutant α-synuclein linked to early-onset Parkinson disease. *Nature Med.* **4**, 1318–1320.

Couchie, D., Mavilia, C., Georgieff, I. S., Liem, R. K. H., Shelanski, M. L. & Nunez, J. 1992 Primary structure of high molecular weight tau present in the peripheral nervous system. *Proc. Natl Acad. Sci. USA* **89**, 4378–4381.

Cras, P., Smith, M. A., Richey, P. L., Siedlak, S. L., Mulvihill, P. & Perry, G. 1995 Extracellular neurofibrillary tangles reflect neuronal loss and provide further evidence of extensive protein cross-linking in Alzheimer disease. *Acta Neuropathol.* **89**, 291–295.

Crowther, R. A. 1991 Straight and paired helical filaments in Alzheimer disease have a common structural unit. *Proc. Natl Acad. Sci. USA* **88**, 2288–2292.

Crowther, R. A., Jakes, R., Spillantini, M. G. & Goedert, M. 1998 Synthetic filaments assembled from C-terminally truncated α-synuclein. *FEBS Lett.* **436**, 309–312.

Davidson, W. S., Jonas, A., Clayton, D. F. & George, J. M. 1998 Stabilization of α-synuclein secondary structure upon binding to synthetic membranes. *J. Biol. Chem.* **273**, 9443–9449.

Delacourte, A., Sergeant, N., Wattez, A., Gauvreau, D. & Robitaille, Y. 1998 Vulnerable neuronal subsets in Alzheimer's and Pick's diseases are distinguished by their tau isoform distribution and phosphorylation. *Ann. Neurol.* **43**, 193–204.

Duff, K. & Hardy, J. 1995 Alzheimer's disease. Mouse model made. *Nature* **373**, 476–477.

Duffy, P. E. & Tennyson, V. M. 1965 Phase and electron microscopic observations of Lewy bodies and melanin granules in the substantia nigra and locus coeruleus in Parkinson's disease. *J. Neuropathol. Exp. Neurol.* **24**, 398–414.

Dumanchin, C. (and 12 others) 1998 Segregation of a missense mutation in the microtubule-associated protein tau gene with familial frontotemporal dementia and parkinsonism. *Hum. Mol. Genet.* **7**, 1825–1829.

Flament, S., Delacourte, A., Verny, M., Hauw, J. J. & Javoy-Agid, F. 1991 Abnormal tau proteins in progressive supranuclear palsy. Similarities and differences with the neurofibrillary degeneration of the Alzheimer type. *Acta Neuropathol.* **81**, 591–596.

Forno, L. S. 1996 Neuropathology of Parkinson's disease. *J. Neuropathol. Exp. Neurol.* **55**, 259–272.

Foster, N. L. (and 40 others) 1997 Frontotemporal dementia and Parkinsonism linked to chromosome 17: a consensus statement. *Ann. Neurol.* **41**, 706–715.

Friedhoff, P., Schneider, A., Mandelkow, E. M. & Mandelkow, E. 1998 Rapid assembly of Alzheimer-like paired helical filaments from microtubule-associated protein tau monitored by fluorescence in solution. *Biochemistry* **37**, 10 223–10 230.

Fukutani, Y., Kobayashi, K., Nakamura, I., Watanabe, K., Isaki, K. & Cairns, N. J. 1995 Neurons, intracellular and extracellular neurofibrillary tangles in subdivisions of the hippocampal cortex in normal ageing and Alzheimer's disease. *Neurosci. Lett.* **200**, 57–60.

Gai, W. P., Power, J. H. T., Blumbergs, P. C. & Blessing, W. W. 1998 Multiple system atrophy: a new α-synuclein disease? *Lancet* **352**, 547–548.

Games, D. (and 23 others) 1995 Alzheimer-type neuropathology in transgenic mice overexpressing V717F β-amyloid precursor protein. *Nature* **373**, 523–527.

Ginsberg, S. D., Crino, P. B., Lee, V. M.-Y., Eberwine, J. H. & Trojanowski, J. Q. 1997 Sequestration of RNA in Alzheimer's disease neurofibrillary tangles and senile plaques. *Ann. Neurol.* **41**, 200–209.

Ginsberg, S. D., Galvin, J. E., Chiu, T. S., Lee, V. M.-Y, Masliah, E. & Trojanowski, J. Q. 1998 RNA sequestration to pathological lesions of neurodegenerative diseases. *Acta Neuropathol.* **96**, 487–494.

Glenner, G. G. & Wong, C. W. 1984 Alzheimer's disease: initial report of the purification and characterization of a novel cerebrovascular amyloid protein. *Biochem. Biophys. Res. Commun.* **120**, 885–890.

Goate, A. (and 20 others) 1991 Segregation of a missense mutation in the amyloid precursor protein gene with familial Alzheimer's disease. *Nature* **349**, 704–706.

Goedert, M. 1997 Familial Parkinson's disease. The awakening of α-synuclein. *Nature* **388**, 232–233.

Goedert, M. & Hasegawa, M. 1999 The tauopathies. Toward an experimental animal model. *Am. J. Pathol.* **154**, 1–6.

Goedert, M. & Jakes, R. 1990 Expression of separate isoforms of human tau protein: correlation with the tau pattern in brain and effects on tubulin polymerization. *EMBO J.* **9**, 4225–4230.

Goedert, M. & Spillantini, M. G. 1998 Lewy body diseases and multiple system atrophy as α-synucleinopathies. *Mol. Psychiatr.* **3**, 462–465.

Goedert, M., Wischik, C. M., Crowther, R. A., Walker, J. E. & Klug, A. 1988 Cloning and sequencing of the cDNA encoding a core protein of the paired helical filament of Alzheimer disease. *Proc. Natl Acad. Sci. USA* **85**, 4051–4055.

Goedert, M., Spillantini, M. G., Potier, M. C., Ulrich, J. & Crowther, R. A. 1989*a* Cloning and sequencing of the cDNA encoding an isoform of microtubule-associated protein tau containing four tandem repeats: differential expression of tau protein mRNAs in human brain. *EMBO J.* **8**, 393–399.

Goedert, M., Spillantini, M. G., Jakes, R., Rutherford, D. & Crowther, R. A. 1989*b* Multiple isoforms of human microtubule-associated protein tau: sequences and localization in neurofibrillary tangles of Alzheimer's disease. *Neuron* **3**, 519–526.

Goedert, M., Spillantini, M. G. & Crowther, R. A. 1992*a* Cloning of a big tau microtubule-associated protein characteristic of the peripheral nervous system. *Proc. Natl Acad. Sci. USA* **89**, 1983–1987.

Goedert, M., Spillantini, M. G., Cairns, N. J. & Crowther, R. A. 1992*b* Tau proteins of Alzheimer paired helical filaments: abnormal phosphorylation of all six brain isoforms. *Neuron* **8**, 159–168.

Goedert, M., Cohen, E. S., Jakes, R. & Cohen, P. 1992*c* p42 MAP kinase phosphorylation sites in microtubule-associated

protein tau are dephosphorylated by protein phosphatase $2A_1$. *FEBS Lett.* **312**, 95–99.

Goedert, M., Jakes, R., Crowther, R. A., Six, J., Lübke, U., Vandermeeren, M., Cras, P., Trojanowski, J. Q. & Lee, V. M.-Y. 1993 The abnormal phosphorylation of tau protein at Ser-202 in Alzheimer disease recapitulates phosphorylation during development. *Proc. Natl Acad. Sci. USA* **90**, 5066–5070.

Goedert, M., Jakes, R., Spillantini, M. G., Hasegawa, M., Smith, M. J. & Crowther, R. A. 1996 Assembly of microtubule-associated protein tau into Alzheimer-like filaments induced by sulphated glycosaminoglycans. *Nature* **383**, 550–553.

Goedert, M., Hasegawa, M., Jakes, R., Lawler, S., Cuenda, A. & Cohen, P. 1997 Phosphorylation of microtubule-associated protein tau by stress-activated protein kinases. *FEBS Lett.* **409**, 57–62.

Goedert, M., Spillantini, M. G. & Davies, S. W. 1998*a* Filamentous nerve cell deposits in neurodegenerative diseases. *Curr. Opin. Neurobiol.* **8**, 619–632.

Goedert, M., Crowther, R. A. & Spillantini, M. G. 1998*b* Tau mutations cause frontotemporal dementias. *Neuron* **21**, 955–958.

Goedert, M. (and 11 others) 1999 Tau gene mutation in familial progressive subcortical gliosis. *Nature Med.* **5**, 454–457.

Goode, B. L. & Feinstein, S. C. 1994 Identification of a novel microtubule binding and assembly domain in the developmentally regulated inter-repeat region of tau. *J. Cell Biol.* **124**, 769–782.

Götz, J., Probst, A., Spillantini, M. G., Schäfer, T., Jakes, R., Bürki, K. & Goedert, M. 1995 Somatodendritic localisation and hyperphosphorylation of tau protein in transgenic mice expressing the longest human brain tau isoform. *EMBO J.* **14**, 1304–1313.

Graham, J. C. & Oppenheimer, D. R. 1969 Orthostatic hypotension and nicotine sensitivity in a case of multiple system atrophy. *J. Neurol. Neurosurg. Psychiatr.* **32**, 28–34.

Greenberg, S. G. & Davies, P. 1990 A preparation of Alzheimer paired helical filaments that displays distinct tau proteins by polyacrylamide gel electrophoresis. *Proc. Natl Acad. Sci. USA* **87**, 5827–5831.

Gustke, N., Trincczek, B., Biernat, J., Mandelkow, E. M. & Mandelkow, E. 1994 Domains of tau protein and interaction with microtubules. *Biochemistry* **33**, 9511–9522.

Hall, G. F., Yao, J. & Lee, G. 1997 Human tau becomes phosphorylated and forms filamentous deposits when overexpressed in lamprey central neurons *in situ*. *Proc. Natl Acad. Sci. USA* **94**, 4733–4738.

Hanger, D. P., Betts, J. C., Loviny, T. L. F., Blackstock, W. P. & Anderton, B. H. 1998 New phosphorylation sites identified in hyperphosphorylated tau (paired helical filament-tau) from Alzheimer's disease brain using nanoelectrospray mass spectrometry. *J. Neurochem.* **71**, 2465–2476.

Harada, A., Oguchi, K., Okabe, S., Kuno, J., Terada, S., Ohshima, T., Sato-Yoshitake, R., Takei, Y., Noda, T. & Hirokawa, N. 1994 Altered microtubule organization in small-calibre axons of mice lacking tau protein. *Nature* **369**, 488–491.

Hardy, J. & Gwinn Hardy, K. 1998 Genetic classification of primary neurodegenerative disease. *Science* **282**, 1075–1079.

Hardy, J., Duff, K., Gwinn Hardy, K., Perez-Tur, J. & Hutton, M. 1998 Genetic dissection of Alzheimer's disease and related dementias: amyloid and its relationship to tau. *Nature Neurosci.* **1**, 355–358.

Hasegawa, M., Crowther, R. A., Jakes, R. & Goedert, M. 1997 Alzheimer-like changes in microtubule-associated protein tau induced by sulfated glycosaminoglycans. Inhibition of microtubule binding, stimulation of phosphorylation, and filament assembly depend on the degree of sulfation. *J. Biol. Chem.* **272**, 33 118–33 124.

Hasegawa, M., Smith, M. J. & Goedert, M. 1998 Tau proteins with FTDP-17 mutations have a reduced ability to promote microtubule assembly. *FEBS Lett.* **437**, 207–210.

Hasegawa, M., Smith, M. J., Iijima, M., Tabira, T. & Goedert, M. 1999 FTDP-17 mutations N279K and S305N in tau produce increased splicing of exon 10. *FEBS Lett.* **443**, 93–96.

Hirokawa, N. 1994 Microtubule organization and dynamics dependent on microtubule-associated proteins. *Curr. Opin. Cell Biol.* **6**, 74–81.

Hong, M., Chen, D. C. R., Klein, P. S. & Lee, V. M.-Y. 1997 Lithium reduces tau phosphorylation by inhibition of glycogen synthase kinase-3. *J. Biol. Chem.* **272**, 25 326–25 332.

Hong, M. (and 14 others) 1998 Mutation-specific functional impairments in distinct tau isoforms and hereditary FTDP-17. *Science* **282**, 1914–1917.

Hsiao, K., Chapman, P., Nilsen, S., Eckman, C., Harigaya, Y., Younkin, S., Yang, F. & Cole, G. 1996 Correlative memory deficits, Aβ elevation, and amyloid plaques in transgenic mice. *Science* **274**, 99–102.

Hutton, M. (and 50 others) 1998 Association of missense and 5′-splice-site mutations in tau with the inherited dementia FTDP-17. *Nature* **393**, 702–705.

Iijima, M. (and 12 others) 1999 A distinct familial presenile dementia with a novel missense mutation in the tau gene. *NeuroReport* **10**, 497–501.

Irizarry, M. C., Soriano, F., McNamara, M., Page, K. J., Schenk, D., Games, D. & Hyman, B. T. 1997*a* Aβ deposition is associated with neuropil changes, but not with overt neuronal loss in the human amyloid precursor protein V717F (PDAPP) transgenic mouse. *J. Neurosci.* **17**, 7053–7059.

Irizarry, M. C., McNamara, M., Fedorchak, K., Hsiao, K. & Hyman, B. T. 1997*b* APPSw transgenic mice develop age-related Aβ deposits and neuropil abnormalities, but no neuronal loss in CA1. *J. Neuropathol. Exp. Neurol.* **56**, 965–973.

Irizarry, M. C., Growdon, W., Gomez-Isla, T., Newell, K., George, J. M., Clayton, D. F. & Hyman, B. T. 1998 Nigral and cortical Lewy bodies and dystrophic nigral neurites in Parkinson's disease and cortical Lewy body disease contain α-synuclein immunoreactivity. *J. Neuropathol. Exp. Neurol.* **57**, 334–337.

Iwatsubo, T., Yamaguchi, H., Fujimoro, M., Yokosawa, H., Ihara, Y., Trojanowski, J. Q. & Lee, V. M.-Y. 1996 Purification and characterization of Lewy bodies from the brains of patients with diffuse Lewy body disease. *Am. J. Pathol.* **148**, 1517–1529.

Jakes, R., Spillantini, M. G. & Goedert, M. 1994 Identification of two distinct synucleins from human brain. *FEBS Lett.* **345**, 27–32.

Jensen, P. H., Nielsen, M. H., Jakes, R., Dotti, C. G. & Goedert, M. 1998 Binding of α-synuclein to rat brain vesicles is abolished by familial Parkinson's disease mutation. *J. Biol. Chem.* **273**, 26 292–26 294.

Ji, H., Liu, Y. E., Jia, T., Wang, M., Liu, J., Xiao, G., Joseph, B. K., Rosen, C. & Shi, Y. E. 1998 Identification of a breast cancer-specific gene, *BCSG1*, by direct differential cDNA sequencing. *Cancer Res.* **57**, 759–764.

Kampers, T., Friedhoff, P., Biernat, J., Mandelkow, E. M. & Mandelkow, E. 1996 RNA stimulates aggregation of microtubule-associated protein tau into Alzheimer-like paired helical filaments. *FEBS Lett.* **399**, 344–349.

Kanemura, K., Takio, K., Miura, R., Titani, K. & Ihara, Y. 1992 Fetal-type phosphorylation of the tau in paired helical filaments. *J. Neurochem.* **58**, 1667–1675.

Kang, J., Lemaire, H. G., Unterbeck, A., Salbaum, J. M., Masters, C. L., Grzeschik, K. H., Multhaup, G., Beyreuther, K. & Müller-Hill, B. 1987 The precursor of Alzheimer's disease amyloid A4 protein resembles a cell-surface receptor. *Nature* **325**, 733–736.

Kato, S. & Nakamura, H. 1990 Cytoplasmic argyrophilic inclusions in neurons of pontine nuclei in patients with

olivopontocerebellar atrophy: immunohistochemical and ultrastructural studies. *Acta Neuropathol.* **79**, 584–594.

Kidd, M. 1963 Paired helical filaments in electron microscopy of Alzheimer's disease. *Nature* **197**, 192–193.

Kondo, J., Honda, T., Mori, H., Hamada, Y., Miura, R., Ogawara, H. & Ihara, Y. 1988 The carboxyl third of tau is tightly bound to paired helical filaments. *Neuron* **1**, 827–837.

Kosaka, K. 1978 Lewy bodies in cerebral cortex. Report of three cases. *Acta Neuropathol.* **42**, 127–134.

Krüger, R., Kuhn, W., Müller, T., Woitalla, D., Graeber, M., Kösel, S., Przuntek, H., Epplen, J. T., Schöls, L. & Riess, O. 1998 Ala30Pro mutation in the gene encoding α-synuclein in Parkinson's disease. *Nature Genet.* **18**, 106–108.

Ksiezak-Reding, H., Morgan, K., Mattiace, L. A., Davies, P., Liu, W. K., Yen, S.-H., Weidenheim, K. & Dickson, D. W. 1994 Ultrastructure and biochemical composition of paired helical filaments in corticobasal degeneration. *Am. J. Pathol.* **145**, 1496–1508.

Kuzuhara, S., Mori, H., Izumiyama, N., Yoshimura, M. & Ihara, Y. 1988 Lewy bodies are ubiquitinated. A light and electron microscopic immunocytochemical study. *Acta Neuropathol.* **75**, 345–353.

Lee, V. M.-Y., Balin, B. J., Otvos, L. & Trojanowski, J. Q. 1991 A68—a major subunit of paired helical filaments and derivatized forms of normal tau. *Science* **251**, 675–678.

Lewy, F. 1912 Paralysis agitans. In *Handbuch der Neurologie*, vol. 3 (ed. M. Lewandowski), pp. 920–933. Berlin: Springer.

Lippa, C. F. (and 16 others) 1998 Lewy bodies contain altered α-synuclein in brains of many familial Alzheimer's disease patients with mutations in presenilin and amyloid precursor protein genes. *Am. J. Pathol.* **153**, 1365–1370.

Masters, C. L. & Beyreuther, K. 1998 Alzheimer's disease. *Br. Med. J.* **316**, 446–448.

Masters, C. L., Simms, G., Weinman, N. A., Multhaup, G., McDonald, B. L. & Beyreuther, K. 1985 Amyloid plaque core protein in Alzheimer disease and Down syndrome. *Proc. Natl Acad. Sci. USA* **82**, 4245–4249.

Mezey, E., Dehejia, A., Harta, G., Papp, M. I., Polymeropoulos, M. H. & Brownstein, M. J. 1998*a* Alpha synuclein in neurodegenerative disorders: murderer or accomplice? *Nature Med.* **4**, 755–757.

Mezey, E., Dehejia, A. M., Harta, G., Suchy, S. F., Nussbaum, R. L., Brownstein, M. J. & Polymeropoulos, M. H. 1998*b* Alpha synuclein is present in Lewy bodies in sporadic Parkinson's disease. *Mol. Psychiatr.* **3**, 493–499.

Mirra, S. S. (and 13 others) 1999 Tau pathology in a family with dementia and a P301L mutation in tau. *J. Neuropathol. Exp. Neurol.* **58**, 335–345.

Mori, H., Kondo, J. & Ihara, Y. 1987 Ubiquitin is a component of paired helical filaments in Alzheimer's disease. *Science* **235**, 1641–1644.

Morishima-Kawashima, M., Hasegawa, M., Takio, K., Suzuki, M., Titani, K. & Ihara, Y. 1993 Ubiquitin is conjugated with N-terminally processed tau in paired helical filaments. *Neuron* **10**, 1151–1160.

Morishima-Kawashima, M., Hasegawa, M., Takio, K., Suzuki, M., Yoshida, H., Titani, K. & Ihara, Y. 1995 Proline-directed and non-proline-directed phosphorylation of PHF-tau. *J. Biol. Chem.* **270**, 823–829.

Mulot, S. F. C., Hughes, K., Woodgett, J. R., Anderton, B. H. & Hanger, D. P. 1994 PHF-tau from Alzheimer's brain comprises four species on SDS-PAGE which can be mimicked by in vitro phosphorylation of human tau by glycogen synthase kinase-3β. *FEBS Lett.* **349**, 359–364.

Munoz-Montado, J. R., Moreno, F. J., Avila, J. & Diaz-Nido, J. 1997 Lithium inhibits Alzheimer's disease-like tau protein phosphorylation in neurons. *FEBS Lett.* **411**, 183–188.

Nakajo, S., Tsukada, K., Omata, K., Nakamura, Y. & Nakaya, K. 1993 A new brain-specific 14-kDa protein is a phosphoprotein. Its complete amino acid sequence and evidence for phosphorylation. *Eur. J. Biochem.* **217**, 1057–1063.

Papp, M. I., Kahn, J. E. & Lantos, P. L. 1989 Glial cytoplasmic inclusions in the CNS of patients with multiple system atrophy. *J. Neurol. Sci.* **94**, 79–100.

Pérez, M., Valpuesta, J. M., Medina, M., Montejo de Garcini, E. & Avila, J. 1996 Polymerization of tau into filaments in the presence of heparin: the minimal sequence requirement for tau–tau interaction. *J. Neurochem.* **67**, 1183–1190.

Pollock, N. J., Mirra, S. S., Binder, L. I., Hansen, L. A. & Wood, J. G. 1986 Filamentous aggregates in Pick's disease, progressive supranuclear palsy, and Alzheimer's disease share antigenic determinants with microtubule-associated protein, tau. *Lancet* **ii**, 1211.

Polymeropoulos, M. H. (and 19 others) 1997 Mutation in the α-synuclein gene identified in families with Parkinson's disease. *Science* **276**, 2045–2047.

Poorkaj, P., Bird, T. D., Wijsman, E., Nemens, E., Garruto, R. M., Anderson, L., Andreadis, A., Wiederholt, W. C., Raskind, M. & Schellenberg, G. D. 1998 Tau is a candidate gene for chromosome 17 frontotemporal dementia. *Ann. Neurol.* **43**, 815–825.

Qi, Z., Zhu, X., Goedert, M., Fujita, D. J. & Wang, J. H. 1998 Effect of heparin on phosphorylation site specificity of neuronal Cdc2-like kinase. *FEBS Lett.* **423**, 227–230.

Reed, L. A. (and 10 others) 1997 Autosomal dominant dementia with widespread neurofibrillary tangles. *Ann. Neurol.* **42**, 564–572.

Reed, L. A., Schmidt, M. L., Wszolek, Z. K., Balin, B. J., Soontornniyomkij, V., Lee, V. M.-Y., Trojanowski, J. Q. & Schelper, R. L. 1998 The neuropathology of a chromosome 17-linked autosomal dominant Parkinsonism and dementia (pallido-ponto-nigral degeneration). *J. Neuropathol. Exp. Neurol.* **57**, 588–601.

Rewcastle, N. B. & Ball, M. J. 1968 Electron microscopic structure of the inclusion bodies in Pick's disease. *Neurology* **18**, 1205–1213.

Rizzu, P. (and 12 others) 1999 High prevalence of mutations in the microtubule-associated protein tau in a population study of frontotemporal dementia in the Netherlands. *Am. J. Hum. Genet.* **64**, 414–421.

Saudou, F., Finkbeiner, S., Devys, D. & Greenberg, M. E. 1998 Huntingtin acts in the nucleus to induce apoptosis but death does not correlate with the formation of intranuclear inclusions. *Cell* **95**, 55–66.

Schweers, O., Schönbrunn-Hanebeck, E., Marx, A. & Mandelkow, E. 1994 Structural studies of tau protein and Alzheimer paired helical filaments show no evidence for beta-structure. *J. Biol. Chem.* **269**, 24 290–24 297.

Sergeant, N., David, J. P., Lefranc, D., Vermersch, P., Wattez, A. & Delacourte, A. 1997*a* Different distribution of phosphorylated tau protein isoforms in Alzheimer's and Pick's diseases. *FEBS Lett.* **412**, 578–582.

Sergeant, N., David, J. P., Goedert, M., Jakes, R., Vermersch, P., Buée, L., Lefranc, D., Wattez, A. & Delacourte, A. 1997*b* Two-dimensional characterization of paired helical filament-tau from Alzheimer's disease: demonstration of an additional 74-kDa component and age-related biochemical modifications. *J. Neurochem.* **69**, 834–844.

Sisodia, S. S. 1998 Nuclear inclusions in glutamine repeat disorders: are they pernicious, coincidental, or beneficial? *Cell* **95**, 1–4.

Snow, A. D., Mar, S., Nochlin, D. & Wight, T. N. 1989 Cationic dyes reveal proteoglycans structurally integrated within the characteristic lesions of Alzheimer's disease. *Acta Neuropathol.* **78**, 113–123.

Sontag, E., Nunbhadki-Craig, V., Bloom, G. S. & Mumby, M. C. 1996 Regulation of the phosphorylation state and microtubule-binding activity of tau by protein phosphatase 2A. *Neuron* **17**, 1201–1207.

Spillantini, M. G. & Goedert, M. 1998 Tau protein pathology in neurodegenerative diseases. *Trends Neurosci.* **21**, 428–433.

Spillantini, M. G., Crowther, R. A. & Goedert, M. 1996 Comparison of the neurofibrillary pathology in Alzheimer's disease and familial presenile dementia with tangles. *Acta Neuropathol.* **92**, 42–48.

Spillantini, M. G., Schmidt, M. L., Lee, V. M.-Y., Trojanowski, J. Q., Jakes, R. & Goedert, M. 1997*a* α-Synuclein in Lewy bodies. *Nature* **388**, 839–840.

Spillantini, M. G., Goedert, M., Crowther, R. A., Murrell, J. R., Farlow, M. J. & Ghetti, B. 1997*b* Familial multiple system tauopathy with presenile dementia: a disease with abundant neuronal and glial tau filaments. *Proc. Natl Acad. Sci. USA* **94**, 4113–4118.

Spillantini, M. G., Crowther, R. A., Jakes, R., Hasegawa, M. & Goedert, M. 1998*a* α-Synuclein in filamentous inclusions of Lewy bodies from Parkinson's disease and dementia with Lewy bodies. *Proc. Natl Acad. Sci. USA* **95**, 6469–6473.

Spillantini, M. G., Crowther, R. A., Jakes, R., Cairns, N. J., Lantos, P. L. & Goedert, M. 1998*b* Filamentous α-synuclein inclusions link multiple system atrophy with Parkinson's disease and dementia with Lewy bodies. *Neurosci. Lett.* **251**, 205–208.

Spillantini, M. G., Bird, T. D. & Ghetti, B. 1998*c* Frontotemporal dementia and Parkinsonism linked to chromosome 17: a new group of tauopathies. *Brain Pathol.* **8**, 387–402.

Spillantini, M. G., Murrell, J. R., Goedert, M., Farlow, M. R., Klug, A. & Ghetti, B. 1998*d* Mutation in the tau gene in familial multiple system tauopathy with presenile dementia. *Proc. Natl Acad. Sci. USA* **95**, 7737–7741.

Spillantini, M. G., Crowther, R. A., Kamphorst, W., Heutink, P. & Van Swieten, J. C. 1998*e* Tau pathology in two Dutch families with mutations in the microtubule-binding region of tau. *Am. J. Pathol.* **153**, 1359–1363.

Sturchler-Pierrat, C. (and 15 others) 1997 Two amyloid precursor protein transgenic mouse models with Alzheimer disease-like pathology. *Proc. Natl Acad. Sci. USA* **94**, 13 287–13 292.

Takeda, A., Mallory, M., Sundsmo, M., Honer, W., Hansen, L. & Masliah, E. 1998*a* Abnormal accumulation of NACP/α-synuclein in neurodegenerative disorders. *Am. J. Pathol.* **152**, 367–372.

Takeda, A., Hashimoto, M., Mallory, M., Sundsmo, M., Hansen, L., Sisk, A. & Masliah, E. 1998*b* Abnormal distribution of the non-Aβ component of Alzheimer's disease amyloid precursor/α-synuclein in Lewy body disease as revealed by proteinase K and formic acid pretreatment. *Lab. Invest.* **78**, 1169–1177.

Trinczek, B., Biernat, J., Baumann, K., Mandelkow, E. M. & Mandelkow, E. 1995 Domains of tau protein, differential phosphorylation, and dynamic instability of microtubules. *Mol. Biol. Cell* **6**, 1887–1902.

Tu, P. H., Galvin, J. E., Baba, M., Giasson, B., Tomita, T., Leight, S., Nakajo, S., Iwatsubo, T., Trojanowski, J. Q. & Lee, V. M.-Y. 1998 Glial cytoplasmic inclusions in white matter oligodendrocytes of multiple system atrophy brains contain insoluble α-synuclein. *Ann. Neurol.* **44**, 415–422.

Uéda, K. (and 10 others) 1993 Molecular cloning of cDNA encoding an unrecognized component of amyloid in Alzheimer disease. *Proc. Natl Acad. Sci. USA* **90**, 11 282–11 286.

Varani, L., Hasegawa, M., Spillantini, M. G., Smith, M. J., Murrell, J. R., Ghetti, B., Klug, A., Goedert, M. & Varani, G. 1999 Structure of tau exon 10 splicing regulatory element RNA and destabilization by mutation of frontotemporal dementia and Parkinsonism linked to chromosome 17. *Proc. Natl Acad. Sci. USA*. (In the press.)

Wakabayashi, K., Matsumoto, K., Takayama, K., Yoshimoto & Takahashi, H. 1997 NACP, a presynaptic protein, immunoreactivity in Lewy bodies in Parkinson's disease. *Neurosci. Lett.* **239**, 45–48.

Wakabayashi, K., Yoshimoto, M., Tsuji, S. & Takahashi, H. 1998*a* α-Synuclein immunoreactivity in glial cytoplasmic inclusions in multiple system atrophy. *Neurosci. Lett.* **249**, 180–182.

Wakabayashi, K., Hayashi, S., Kakita, A., Yamada, M., Toyoshima, Y., Yoshimoto, M. & Takahashi, H. 1998*b* Accumulation of α-synuclein/NACP is a cytopathological feature common to Lewy body disease and multiple system atrophy. *Acta Neuropathol.* **96**, 445–452.

Weinreb, P. H., Zhen, W., Poon, A. W., Conway, K. A. & Lansbury, P. T. 1996 NACP, a protein implicated in Alzheimer's disease and learning, is natively unfolded. *Biochemistry* **35**, 13 710–13 715.

Wilhelmsen, K. C., Lynch, T., Pavlou, E., Higgins, M. & Nygaard, T. G. 1994 Localization of disinhibition-dementia-Parkinsonism-amyotrophy complex to 17q21–22. *Am. J. Hum. Genet.* **55**, 1159–1165.

Wischik, C. M., Novak, M., Thogersen, H. C., Edwards, P. C., Runswick, M. J., Jakes, R., Walker, J. E., Milstein, C., Roth, M. & Klug, A. 1988 Isolation of a fragment of tau derived from the core of the paired helical filament of Alzheimer disease. *Proc. Natl Acad. Sci. USA* **85**, 4506–4510.

Yoshida, H. & Ihara, Y. 1993 Tau in paired helical filaments is functionally distinct from fetal tau: assembly incompetence of paired helical filament tau. *J. Neurochem.* **61**, 1183–1186.