Tracheal foreign body in a cat

Lyndell Levitt, G. Ross Clark, Vicki Adams

Upper airway obstruction in the cat may occur due to a number of different causes, including foreign bodies, neoplasia, trauma, pharyngeal polyps, and inflammation (1–8). These may be differentiated by physical examination, radiography, endoscopy, biopsy, or exploratory surgery. In this report, we describe the clinical presentation and surgical treatment of a tracheal foreign body.

A six-year-old, 4 kg, domestic shorthair, female/spayed cat was initially examined with a complaint of choking and coughing of one day's duration. On physical examination, the cat was bright and alert but febrile (39.4°C), with increased upper respiratory sounds evident on thoracic auscultation. The left mandibular lymph node and left tonsil were swollen, and the caudal pharynx appeared inflamed. A tentative diagnosis of acute pharyngitis was made and the cat was given a single dose of 0.5 mg dexamethasone phosphate IM (Azium, Schering Canada Inc., Pointe-Claire, Quebec) and discharged with a 10-day course of amoxicillin/clavulanate (Clavamox, Beecham Laboratories, Bristol, Tennessee, USA) at 13.7 mg/kg PO every 12 hours.

The cat was reexamined 17 days later, at which time the owners reported she had improved slightly while on the antibiotics, but intermittent coughing had recurred within one week of discontinuing the antibiotics. On examination, the cat was alert and afebrile (38.8°C); however, both tonsils were enlarged, the pharynx was inflamed, and loud upper respiratory sounds were evident. A persistent pharyngitis was suspected and treatment consisted of 20 mg methylprednisolone acetate IM (Depomedrol, Tuco Products, Orangeville, Ontario) and 50 mg gentamicin SQ (Gentocin, Schering Corp., Kenilworth, New Jersey, USA).

Two days later, the cat was presented with a complaint of being restless and unable to swallow properly, and exhibiting abnormal respiratory sounds associated with an explosive, persistent cough. A marked respiratory stridor was evident. A cough could not be elicited on tracheal palpation, and there was no evidence of cyanosis, although the cat appeared to be in mild respiratory distress. The pharyngeal region was moderately inflamed.

Can Vet J 1993; 34: 172–173

Veterinary Referral Services, 1635 West 4th Avenue, Vancouver, British Columbia V6J 1L8 (Levitt, Adams); Lynn Valley Veterinary Clinic, 1268 Lynn Valley Road, North Vancouver, British Columbia V7J 2A3 (Clark). Present address of Dr. L. Levitt: Amherst Veterinary Hospital, 4202 Dunbar Street, Vancouver, British Columbia V6S 2E9. Present address of Dr. V. Adams: Vancouver Animal Emergency Clinic, 1590 West 4th Avenue, Vancouver, British Columbia V6J 1L7.

Reprints will not be available.

Lateral thoracic radiographs were taken and a radiodense object was visualized within the thoracic trachea just cranial to the tracheal bifurcation (Figure 1). Hyperinflation of the lung fields and dilation of the trachea cranial to the foreign body were also present. Attempts to dislodge the tracheal foreign body with coupage and a type of Heimleich maneuver were unsuccessful. The cat was then referred for surgical removal of the tracheal foreign body.

Following the induction of anesthesia with an intravenous mixture of 4 mg/kg of ketamine (Ketaset, Bristol Laboratories, Syracuse, New York, USA) and 0.2 mg/kg of diazepam (Sabex, Boucherville, Quebec), the cat was intubated and general anesthesia was maintained with isoflurane (AErrane, Anaquest, Pointe-Claire, Quebec) and oxygen. Several attempts to dislodge the foreign body with a wire snare under fluoroscopy were unsuccessful, as the foreign body appeared to be adherent to the tracheal mucosa.

The cat was prepared for a right lateral thoracotomy. A standard right lateral thoracotomy at the fourth intercostal space was performed. The tracheal bifurcation was isolated and a 150 degree circumferential incision made between the tracheal rings, just cranial to the carina. The foreign body was grasped with a pair of Debakey forceps, manipulated, and delivered through the tracheotomy site. Direct culture of the tracheal lumen was obtained with a culturette swab (Starswab, Scientific, Etobicoke, Ontario). The edges of the tracheotomy incision were held together with preplaced stay sutures to allow adequate positive pressure ventilation while the tracheal rings were reapposed. The tracheotomy incision was closed with a combination of encircling tension relief sutures and multiple simple interrupted nonabsorbable 4–0 nylon sutures. The suture line was inspected for air leaks, and a chest tube was placed prior to closure of the thoracotomy.

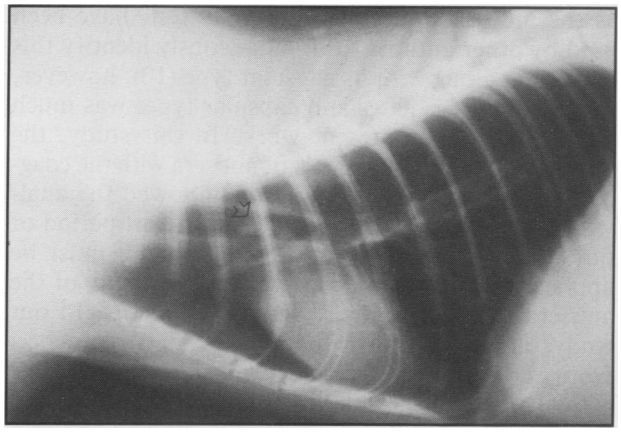

Figure 1. Lateral radiographic view of the thorax demonstrating a radiodense tracheal foreign body (arrow). (This radiograph was taken under a general anesthetic while fluoroscopic retrieval of the foreign body was attempted; the position of the foreign body is identical with that evident on initial radiographs.)

Postoperative radiographs were taken, and complete removal of the radiodense tracheal foreign body, a mild pneumothorax, and acceptable placement of the chest tube were evident.

Recovery from anesthesia was uncomplicated, and the chest tube was removed 24 hours after surgery. A heavy growth of *Pasteurella multocida* was isolated from the culture of the tracheal lumen. Based on the bacterial sensitivity results, a course of antibiotic therapy, consisting of amoxicillin (Amoxil, Ayerst Laboratories, Montreal, Québec) at 22 mg/kg PO twice a day for 10 days followed by enrofloxacin (Baytril, Bayvet Division, Chemagro Limited, Etobicoke, Ontario) at 2.5 mg/kg twice a day for two weeks, was instituted. The cat made an unremarkable recovery from the surgery and was asymptomatic at the last recheck, 18 months postsurgery. The tracheal foreign body was identified as a piece of wood mulch.

Tracheal and bronchial foreign bodies in the cat have been infrequently reported in the veterinary literature (1-3). Small foreign bodies may be coughed up or pass beyond the tracheal bifurcation to lodge deep within the bronchial tree with the subsequent development of pneumonia. When foreign bodies are large, they often lodge at the tracheal bifurcation, as seen in the cat reported here.

The clinical signs most often associated with tracheal foreign bodies include chronic coughing, respiratory stridor, respiratory distress, and dyspnea (9,10). In cases of partial tracheal obstruction, chronic coughing may be the only recognized clinical problem. Persistent signs of coughing, dyspnea, and respiratory stridor in the absence of a known cause are definite indications for further diagnostics, such as plain or contrast thoracic radiography, and/or bronchoscopy.

The diagnosis of radiodense foreign bodies is confirmed with plain radiography. Radiolucent foreign bodies can be demonstrated by positive contrast bronchography or bronchoscopy (3,9).

Foreign bodies within the trachea or mainstem bronchi may be removed with a bronchoscope and appropriate grasping forceps (3). Removal of tracheal foreign bodies via bronchoscopy is limited in most cats by the small diameter of the trachea. Alternative methods of foreign body retrieval include performing a presternal tracheotomy to illuminate and view the object prior to grasping with forceps or performing a thoracotomy for direct removal via thoracic tracheotomy (1,2). In the case reported here, the inability to deliver the foreign body orally under fluoroscopy precluded any noninvasive method of retrieval, and a thoracotomy was chosen as the best approach.

Acknowledgments

We thank Drs. SueAnn Hosie and Ann McDonald and the staff of the Vancouver Animal Emergency Clinic for their emergency care of this patient and for the referral of this case. CVJ

References

1. Eyster GA, Evans AT, O'Handley P, Steffers J. Surgical removal of a foreign body from the tracheal bifurcation of a cat. J Am Anim Hosp Assoc 1976; 12: 481-483.
2. McGlennon NJ, Platt D, Dunn JK, Chambers JP. Tracheal foreign body in a cat: A case report. J Small Anim Pract 1986; 27: 457-461.
3. Jones BD, Roudebush P. The use of fiberoptic endoscopy in the diagnosis and treatment of tracheobronchial foreign bodies. J Am Anim Hosp Assoc 1984; 20: 497-504.
4. Hendricks JC, O'Brien JA. Tracheal collapse in two cats. J Am Vet Med Assoc 1985; 187: 418-419.
5. McMillian FD. Iatrogenic tracheal stenosis in a cat. J Am Anim Hosp Assoc 1985; 21: 747-750.
6. Neer MT, Zemon D. Tracheal adenocarcinoma in a cat and review of the literature. J Am Anim Hosp Assoc 1987; 23: 377-380.
7. Schneider PR, Smith CW, Feller DL. Histiocytic lymphosarcoma of the trachea in a cat. J Am Anim Hosp Assoc 1979; 15: 485-487.
8. Veith LA. Squamous cell carcinoma of the trachea in a cat. Feline Pract 1974; 4: 30-32.
9. Ettinger SJ, Ticer JW. Diseases of the trachea. In: Ettinger SJ, ed. Veterinary Internal Medicine. 1st ed. Philadelphia: WB Saunders, 1975: 620-621.
10. Nelson AW. Lower respiratory system. In: Slatter DH, ed. Textbook of Small Animal Surgery. 1st ed. Philadelphia: WB Saunders, 1985: 997-998.

Need Cages?
Save 33 1/3%

Clark Cages
- Formica Lined
- Quiet & Warm
- Sensibly Priced
- Durable
- Attractive
- Easy To Assemble



Clark Cage Dryer
- Heavy-duty construction
- Fully assembled



- Virtually maintenance-free
- Dries animal quickly and safely
- Space-saver design

Thrifty Cage and Run Floors
- Lightweight polypropylene plastic panels
- Easy-to-clean
- Cage floors elevated on 3/4" legs
- 2' x 2' panels snap together for large run floor
- Available in custom sizes

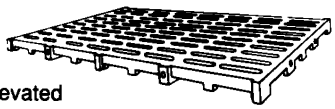

For a free colour brochure and price list contact

Clark Cages Inc. Committed To Excellence

Canada (705) 497-8900
USA Texas (214) 744-5954
Penn. (215) 922-5564
Calif. (213) 689-9324