CLINICAL REPORT

Episodic Muscle Tremors in a Quarter Horse: Resemblance to Hyperkalemic Periodic Paralysis

JANET E. STEISS AND JONATHAN M. NAYLOR

Department of Veterinary Physiological Sciences (Steiss) and Veterinary Internal Medicine (Naylor), Western College of Veterinary Medicine, University of Saskatchewan, Saskatoon, Saskatchewan S7N 0W0.

Abstract

A three year old Quarter Horse stallion was presented with a one year history of episodes of generalized muscle tremors and stiffness, and spasm of the muscles of facial expression, lasting 10-15 minutes. Between attacks, the horse was either normal or had a localized muscle tremor in the flank region. Episodes appeared unrelated to exercise. The major abnormal findings included 1) a rise in plasma potassium from a resting level of 4.4 to 7.9 mmol/L during an attack and 2) electromyographic findings of generalized increased insertion activity and myotonic discharges. The horse was treated with hydrochlorothiazide tablets for nine months, during which time no further attacks were noted. However, four months after the drug was stopped, sporadic focal muscle tremors reappeared; two months later, generalized attacks were seen. Despite reinstitution of the diuretic, a focal flank tremor persisted. Two related horses in the same stable also were reported by the owner to exhibit sporadic generalized muscle twitching. The abnormal findings of the present case differ from clinical syndromes previously reported in horses. Some similarities to hyperkalemic periodic paralysis in humans are noted.

Key words: Horse, muscle tremor, hyperkalemic periodic paralysis, myopathy.

Résumé

Ressemblance des tremblements musculaires épisodiques d'un Quarter Horse à la paralysie périodique due à une hyperkaliémie

Le propriétaire d'un étalon Quarter Horse, âgé de trois ans, l'hospitalisa parce qu'il présentait des épisodes de tremblements musculaires généralisés et de raideur, ainsi que des spasmes des muscles faciaux, qui duraient de dix à 15 minutes. Entre les attaques, l'étalon était normal ou il affichait des tremblements musculaires localisés aux flancs. Les épisodes précités ne semblaient pas reliés à l'exercice. Les anormalités principales incluaient : 1 — une élévation du potassium plasmatique qui passa de 4,4 mmol/L, durant le repos, à 7,9 mmol/L, au cours d'une attaque; 2 — une augmentation généralisée de l'activité d'insertion et des décharges myotoniques, comme le réléva l'électromyographie. Le cheval reçut des tablettes d'hydrochlorothiazide pendant neuf mois au cours desquels il ne manifesta aucune attaque. Toutefois, quatre mois après l'arrêt de la médication, des tremblements musculaires focaux sporadiques réappaururent et, deux mois plus tard, on observa des attaques généralisées. En dépit du retour au diurétique précité, le tremblement des flancs persista. Le propriétaire rapporta aussi que deux autres de ses chevaux, apparentés, manifestaient des contractions musculaires généralisées, de façon sporadique. Les anormalités de ce cas diffèrent des syndromes similaires, déjà rapportés chez le cheval; elles ressemblent cependant un peu à celles de la paralysie périodique des humains, due à une hyperkaliémie.

Mots clés : cheval, tremblement musculaire, paralysie périodique due à une hyperkaliémie, myopathie.

Introduction

There have been a number of established reports of periodic muscle spasm, occasionally culminating in death, in certain lines of North American show Quarter Horses. The cause of this problem is unclear. We recently examined an affected Quarter Horse. Our findings suggested that it suffered from a form of primary myopathy that has not been previously described in horses (1).

History

A three year old Quarter Horse stallion exhibited sporadic episodes of generalized muscle tremors and stiffness lasting 10-15 minutes. There was no apparent association of the attacks with exercise. Attacks were first noticed the previous year and had occurred less than once per month

Present address of Dr. Steiss: Scott-Ritchey Research Program, College of Veterinary Medicine, Auburn University, Auburn, Alabama 36849.
Reprint requests to Dr. Naylor.
Supported in part by a grant from the Equine Health Research Fund, Western College of Veterinary Medicine.
Dr. Steiss is the recipient of a University Research Fellowship from the Natural Sciences and Engineering Research Council of Canada.

until three weeks prior to presentation at the Western College of Veterinary Medicine, when two attacks occurred on consecutive days, followed by a third attack two weeks later. For one attack, the plasma potassium levels, which were determined by the local laboratory on nonhemolyzed blood samples that had been centrifuged within 20 minutes of sampling, were 4.4 mmol/L (two hours before an attack) and 7.9 mmol/L (immediately after an attack). These samples were later reanalyzed, with similar results, by the Clinical Pathology Laboratory, WCVM (normal potassium for horses, 3.0 to 5.0 mmol/L). Serum creatine kinase did not rise significantly. The referring veterinarian noted that during an episode, twitching usually started in the flank region, followed by generalized muscle stiffness. Twitching and spasm were also visible in facial muscles such as the masseter, temporalis and levator nasolabialis, producing the appearance of "risus sardonicus." The third eyelid intermittently prolapsed bilaterally and the upper lip curled outwards into a flehmen position. These signs were accompanied by generalized sweating and elevations in heart and respiratory rates. The horse appeared stressed, but seemed aware of its surroundings and remained standing. The owner and trainer felt that the attacks occurred more frequently when the animal was fed alfalfa hay.

Clinical Findings

At the time of presentation to WCVM, the stallion was in excellent body condition. Results of the physical examination were normal. A complete blood count, serum electrolytes and creatinine were normal. The stallion was admitted for five days, during which time no episodes were seen. On days 2 and 4, the horse was lunged at a trot for five minutes and blood was drawn from the jugular vein for electrolyte and muscle enzyme determinations before, immediately after, and 15 minutes after exercise; there were no abnormal findings (Table I). On days 3, 4 and 5, needle electromyographic (EMG) examinations were performed with the horse restrained in a stanchion. On all three EMG examinations, there was abnormal increased insertion activity in all muscles examined (*gluteus medius, quadriceps femoris, biceps femoris, supraspinatus, infraspinatus, triceps brachii, masseter* and *temporalis*). Myotonic discharges, heard as "dive-bomber" sounds, were consistently present in the *triceps brachii* (Figure 1). On day 3, a muscle biopsy was taken from the semitendinosus muscle, using local anesthesia and a Bergstrom biopsy needle. The tissue was frozen in isopentane cooled in liquid nitrogen, and stored at -70°C. Sections (8μ) were cut on a cryostat and stained with hematoxylin and eosin, periodic acid Schiff and modified Gomori trichrome stains. Histochemical stains for NADH and myosin ATPase at pH 10.3 and 4.6 were also done (2). All sections were normal on light microscopic examination. In attempts to induce muscle stiffness, the hay was switched from grass to alfalfa on day 3 and a front limb was hosed with cold water for 15 minutes on day 4. The latter procedure was performed because exposure to cold can worsen the clinical signs in paramyotonia congenita, a disease in humans which resembles hyperkalemic periodic paralysis (3). Both

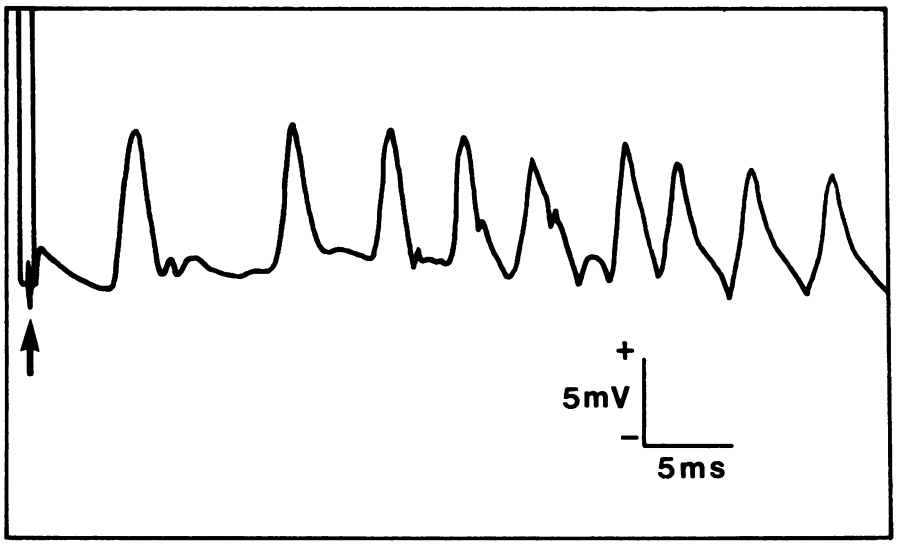

FIGURE 1. Electromyographic recording from the *triceps brachii* of myotonic discharges after needle insertion activity (arrow).

TABLE I
SERUM CHEMISTRY VALUES BEFORE AND AFTER FIVE MINUTES OF LUNGING AT A TROT

	Day 2			Day 4			
	Preexercise	Postexercise 1 min	Postexercise 15 min	Preexercise	Postexercise 1 min	Postexercise 15 min	Normal values
Sodium (mmol/L)	138	140	139	137	135	133	(132-150)
Potassium (mmol/L)	3.8	4.6	4.0	4.2	4.8	4.2	(3.0-5.0)
Chloride (mmol/L)	107	107	106	100	100	99	(98-110)
Calcium (mmol/L)	2.88	2.99	2.80	ND	ND	ND	(2.80-3.44)
CK (U/L)	153	170	155	229	234	227	(< 500)
AST (U/L)	436	476	441	406	432	382	(313 ± 116)[a]

ND = not determined
[a]X ± SD.

procedures failed to induce muscle tremors or stiffness.

Treatment and Follow-up

A trial with hydrochlorothiazide (250 mg, BID) was started on the evening of day 4. The horse was sent home on day 5 with instructions to continue the diuretic tablets in the feed.

The owner was contacted 15 months later. For nine months following referral, the horse had been kept on diuretic tablets, alfalfa hay had been omitted from the diet and no episodes were seen. Four months after the drug was stopped, however, mild attacks with muscle tremors restricted to the flank region recurred. These progressed to generalized attacks with a persistent mild flank tremor despite reinstituted administration of the diuretic. However, the intensity and frequency of the tremor gradually decreased during three months of therapy.

The owner also reported that two related horses (one filly and one mare, see Figure 2) in the stable, which housed 24 horses, including foals, were also showing intermittent generalized muscle twitching. The attending veterinarian had treated some of these episodes with intravenous calcium, which appeared to have a beneficial effect.

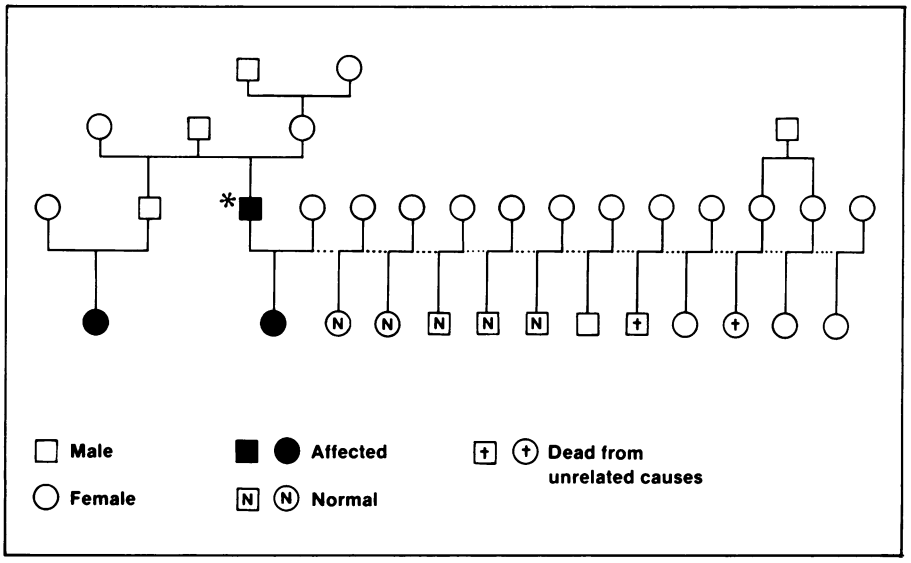

FIGURE 2. Pedigree including proband (*) and closely related horses.

Discussion

The findings of 1) intermittent and unpredictable episodes of muscle tremors and stiffness in an otherwise clinically normal animal, 2) an increased plasma potassium level but normal serum creatine kinase during an attack, 3) EMG evidence of increased muscle excitability between attacks and 4) a suspected familial predisposition, differentiate this syndrome from other documented equine myopathies such as exertional rhabdomyolysis or hypothyroid myopathy. The rise in the plasma potassium at the time of a generalized attack resembles a disease known as primary hyperkalemic periodic paralysis in humans (3). The resemblance is further supported by the EMG findings of abnormal electrical muscle activity, namely, increased insertion activity and myotonic discharges. Hyperkalemic periodic paralysis with myotonia is a recognized variant in humans (3). The needle EMG examination may show increased insertion activity, fibrillation potentials, positive sharp waves, and/or myotonic discharges (4). Myotonia is also seen in people suffering from myotonic dystrophy, myotonia congenita, paramyotonia, polymyositis and acid maltase deficiency (5), and it can be induced experimentally by exposure to diazacholesterol (5) or 2,4-D (6). As pointed out by Farnbach (7), equine myopathies accompanied by myotonia are too poorly understood at present to be adequately classified.

Further similarities to hyperkalemic periodic paralysis include: 1) the attack lasting minutes, not hours and 2) the frequency of attacks varying widely, being largely unpredictable. However, there are also significant differences. In affected humans, attacks tend to occur during rest after exercise, whereas in this case, there was no apparent relation to exercise. Secondly, unlike the condition in man, these episodes in the horse were marked by muscle twitching and stiffness, not flaccidity. Thirdly, the disease is inherited in an autosomal dominant manner (8); autosomal dominance is not indicated by this horse's pedigree (Figure 2). However, there is some indication that this condition could be familial since out of 23 horses stabled with this stallion, two related horses, but no unrelated ones, showed similar but less frequent episodes.

Muscle histology, including histochemistry, was normal. Electron microscopy was not done. Biopsies from people with hyperkalemic periodic paralysis may show PAS positive vacuoles in muscle fibers on light microscopy (8); the corresponding electron microscopic findings have been reviewed (9).

It is difficult to evaluate objectively the therapy in this case since the attacks were unpredictable. However, the absence of signs during nine months of chlorthiazide therapy suggests this may be beneficial. The chlorthiazides have been successfully used in affected people (3,8). Intravenous calcium has been recommended to treat severe attacks (3).

The potassium content of the alfalfa and grass hays in the horse's diet was not determined. However, one reference (10) has reported alfalfa hay to have a relatively high potassium content (2.18%, dry basis) compared to such hays as brome grass (2.07%), timothy (1.59%) or Bermuda grass (1.57%).

In summary, it is suggested that the horse described in this report was suffering from a primary myopathy which had several features in common with hyperkalemic periodic paralysis in humans.

Acknowledgments

The authors thank Dr. C.A. Piché for referring this case.

References

1. WALDRON-MEASE E, RAKER CW, HAMMEL EP. The muscular system. In: Mansmann RA, McAllister ES, eds. Equine medicine and surgery. Vol. 2. Santa Barbara: American Veterinary Publications, 1982: 923-943.
2. ESSEN B, LINDHOLM A, THORNTON J. Histochemical properties of muscle fiber types and enzyme activities in skeletal muscles of Standardbred trotters of different ages. Equine Vet J 1980; 12: 175-180.
3. BROOKE MH. A clinician's view of neuromuscular diseases. Baltimore: Williams and Wilkins Co., 1977.
4. ANON. Neuromuscular transmission defects and periodic paralysis. Handbook Electroencephalogr and Clin Neurophysiol. 1975; 16A: 55-70.
5. DAUBE JR. Needle examination in clinical electromyography. In: Fundamentals of EMG. Proc. Sixth Annual Continuing Education Course, Am Assoc Electromyogr Electrodiag, Toronto, 1983: 35-46.
6. DANON JM, KARPATI G, CARPENTER S. Subacute skeletal myopathy induced by 2,4-dichlorophenoxyacetate in rats and guinea pigs. Muscle and Nerve 1978; 1: 89-102.
7. FARNBACH GC. Myotonia. In: Mansmann RA, McAllister ES, eds. Equine medicine and surgery. Vol. 2. Santa Barbara: American Veterinary Publications, 1982: 935-936.
8. BURUMA OJS, SCHIPPERHEYN JJ. Periodic paralysis. In: Vinken PJ, Bruyn GW, Ringel SP, eds. Handbook of clinical neurology. Vol. 41. Amsterdam: North-Holland Publ., 1979: 147-174.
9. ENGEL AG. Metabolic and endocrine myopathies. In: Walton J, ed. Disorders of voluntary muscle. Edinburgh: Churchill Livingstone, 1981: 664-711.
10. CULLISON AE. Feeds and feeding. Reston: Reston Publ. Co., 1982: 580-585.

LETTER TO THE EDITOR

The Editor
Canadian Veterinary Journal

DEAR SIR:

Horses are as afflicted by respiratory disease as ever, yet a change seems to have occurred in the array of infectious agents that cause them. Isolations of equine influenza virus type I (A/equine/Prague/1/1956-H7N7) have declined in recent years to a level of uncertainty whether the virus is still circulating in the equine populations of the world. To clarify this point, which has not only academic but also practical interest for determining the composition of vaccines, the Collaborating Center for the Ecology of Influenza Viruses in Animals and Birds (Dr. R.G. Webster, Memphis, Tennessee) and the World Influenza Center (Dr. J.J. Skehel, Mill Hill, London) under the aegis of the World Health Organization have launched a search for recent cases of equine influenza by virus type I authenticated by isolation and/or seroconversion in unvaccinated horses. A call is made to equine practitioners and veterinary diagnostic services in Canada to inform the undersigned or the WHO laboratories directly on their last proven case of equine I influenza. The results of the survey will be brought to the attention of the public in due course.

DR. GERHARD LANG
Ontario Veterinary College
University of Guelph