were started. His condition before that was extremely grave, and he made a rapid and continuous recovery as soon as air-injection treatment was instituted.

REPORT OF CASE

Mr. Ernest R., age 38, ranch laborer, married, father of five children. Past medical history essentially negative.

Present Illness.—The patient noticed some headaches for three days prior to admission to the hospital on August 6, 1938, but had continued working on his ranch because he did not consider the headache particularly significant. The night before his admission he developed a fever, but he did not know how much; he felt extremely weak and had rather severe pains in his back. A physician was consulted the next morning, as his illness continued to become worse, and he was sent to the hospital at once. His temperature on entrance was 104.6 degrees. He was acutely ill, semi-stuporous and irrational, and was troubled with frequent involuntary urinations. A negative Widal reaction ruled out the possibility of a typhoid infection. He had a leukocyte count of 13,400, 26 per cent of which were large lymphocytes, and urinalysis showed the findings negative except for a high degree of acidity. The patient was given a sedative and was started on a daily regimen of potassium citrate, 20 grains three times a day.

On the second day he was worse. He began having involuntary defecations as well as urinations, he was very drowsy and more irrational than on the previous day, and a spinal puncture was decided on for diagnostic purposes. The spinal fluid was under no increased pressure. The laboratory reported a white cell count of 229 per cubic millimeters of fluid, 96 per cent of which were young polymorphonuclear leukocytes. On the following day he was unable to take any food, he was more irrational, and had developed a tremor in both arms. His temperature did not go above 101.6 degrees during the dav. Treatment that day consisted of intravenous hypertonic glucose, 50 cubic centimeters of 50 per cent glucose, and some Hartmann's solution subcutaneously later in the day. On the fourth day after entrance he developed a severe quivering of the entire body, and was unable to swallow. His general condition became serious. The next day, the fifth after entrance, he was given 50 cubic centimeters of 50 per cent glucose, intravenously, and received his first air injection. A spinal puncture was done as soon as he had received the glucose, and the spinal fluid was seen to be under no great pressure. Without removing any spinal fluid, 20 cubic centimeters of air were injected. The patient made some improvement that day, and spent a more comfortable night. The entire procedure was repeated the next day, 20 cubic centimeters of air being injected a second time. Later, that same day, the patient's improvement was very noticeable. He began to eat liquid foods, became more rational, had a temperature less than 100 degrees all that day and night, and was less troubled by involuntary urinations. There were no involuntary defecations after that day. On the following day the procedure was repeated a third time, the patient getting 30 cubic centimeters of air into the spinal canal instead of 20 cubic centimeters as on the previous two days. He started to eat well, and ceased to void involuntarily.

On the following two days he received no air injections, and received no hypertonic intravenous solutions. He continued to show steady improvement and was eating a soft diet without difficulty. He suffered a relapse on the third day since discontinuing the air injections and the hypertonic glucose. He became irrational again, and had a return of his former symptom of involuntary passage of urine. His temperature rose to 102 degrees. On the following day there was a serious weakening of the pulse, and his condition became critical.

At that time another spinal puncture was decided on for the purpose of injecting air into the cranial and ventricular cavities. The patient was given 50 cubic centimeters of hypertonic glucose solution intravenously, and a spinal puncture was done. Without removing any fluid, 20 cubic centimeters of air were injected into the spinal canal. The patient showed improvement later that same day. He was more alert until late that night, when he became irrational again to a slight degree, and voided once involuntarily. He was noticeably better the next day, and continued to show improvement on each succeeding day. He had no more spinal punctures and no more hypertonic glucose solution after the single treatment given at the time of his relapse. He received no medication after that last injection, except some Epsom salts the second day. He was eating a general diet three days after the last spinal injection, and was sitting up in a chair after four days. He continued to make a steady uneventful recovery, and left the hospital three weeks after his admission. His subsequent history has shown almost complete recovery, and he has begun work on his ranch.

CONCLUSIONS

1. It is our opinion that a great number of patients having encephalitis who now die will recover if this treatment is properly pursued.

2. This suggests a new treatment for cerebral concussion, cerebral hemorrhage, etc.

1410 Pacific Southwest Building.

MIKULICZ'S DISEASE

A CASE REPORT

By ALFRED C. REED, M.D.
AND
FRANCIS ROCHEX, M.D.
San Francisco

IN 1892 Mikulicz [1] described a clinical syndrome, characterized by a chronic, painless, uniform enlargement of the lacrimal and salivary glands in an individual with a normal blood picture. There was neither involvement of the lymph nodes nor of the spleen. Histologically the tissue resembled that of a lymphoma, in which the lymphoid hyperplasia lay between and compressed the secretory cells.

Some observers have noted that there may be no involvement of the lacrimal glands. Others have recorded the presence of exophthalmos associated with involvement of the lacrimal glands. There have been many and varied suggestions which have been offered regarding the possible etiologic factors. Favor has been given to the idea of a chronic infectious agent extending from the nasopharynx or operating from some distant focus. Many have stressed the importance of tuberculosis in the etiology, but the relationship has never been definitely established.

Mikulicz's syndrome is to be differentiated from atypical leukemia, chronic relapsing parotitis and simple hypertrophy of the glands. The glandular tissue often returns to its original size, following the administration of iodids or arsenicals. Roentgenotherapy is usually successful and surgery may be resorted to if other measures have proved ineffective.

1 Mikulicz, J.: Beitr. z. Chir. Festschr., 610, 1892.

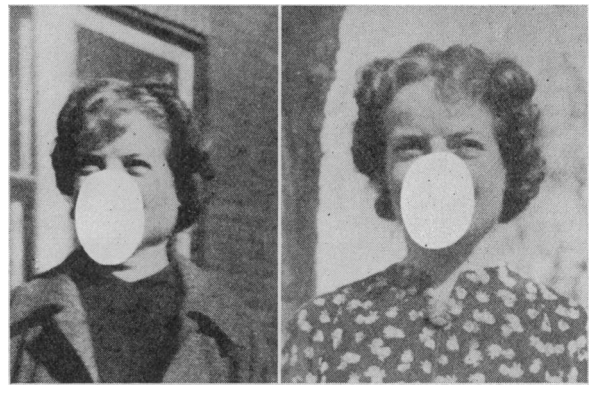

Fig. 1.—Before and after treatment.

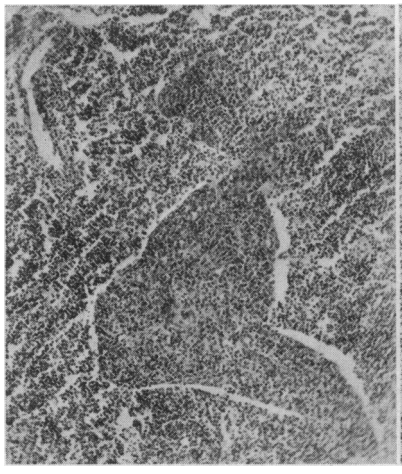

Fig. 2.—Parotid gland section, low power.

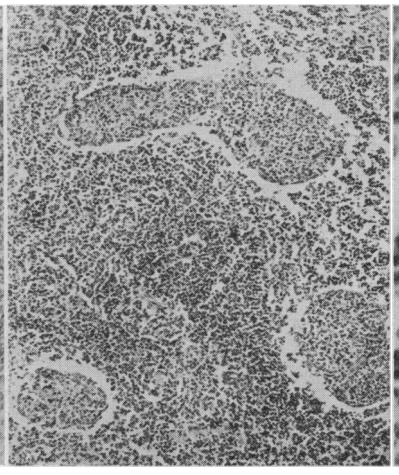

Fig. 3.—Parotid gland section, low power.

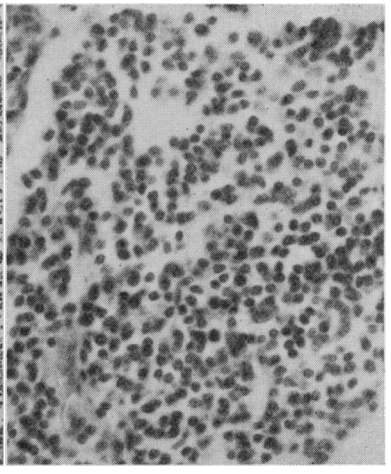

Fig. 4.—Parotid gland section, high power.

REPORT OF CASE

Mrs. H. A., age 35, was first seen by us on January 27, 1938.

Chief Complaint.—Swelling of the parotid glands bilaterally, which had begun with a severe head and chest cold three years before, and had been gradually enlarging since. She also complained of amebic dysentery, for which she had been under treatment for seven years past, recurring arthritis, and a tendency to anemia.

Past History.—She was born in northern California, went to Brazil in 1930, and returned to northern California in February, 1932.

Diseases: There were no hereditary diseases in the family. She had some of the minor childhood diseases only, and at one time had an enlarged liver, with jaundice. Tonsillectomy in 1922 was followed by severe hemorrhage. In 1929 her appendix was removed and internal hemorrhoids were cauterized. She was always troubled with constipation. Following this operation she was found to be anemic.

In 1930, a few days after her arrival in Brazil, she had her first attack of dysentery, which was diagnosed as ptomain poisoning. For the following year and a half she was treated almost continually for anemia.

In October, 1931, she became very ill, and Entameba histolytica was demonstrated in the stool. Treatment was with stovarsol. During her stay in Brazil her weight dropped from 116 to 96 pounds.

In February, 1932, she returned to California. During the following year she suffered from arthritis, neuritis, and amebic dysentery. She took many antiamebic drugs, but no emetin. Her stools were last positive for amebas in 1933.

In May, 1934, her arm swelled from elbow to wrist, but no diagnosis was made as to cause. Later that same year she had influenza, followed by colds which persisted all winter. In February, 1935, following a very severe head and chest cold, she first noted swelling of the parotid glands, which swellings has gradually increased to date. At no time has there been any pain or soreness in the glands.

From February, 1935, to January 27, 1938, when she first came under our observation, she received much medical treatment for anemia and amebiasis, and some medication for arthritis.

In December, 1935, her hemoglobin was 75 per cent, red blood cells 4,500,000, and leukocytes 11,850. In July, 1936, the hemoglobin was 58 per cent, and this varied from time to time to January 24, 1938, when it was 62 per cent.

During this time she states that she took, among other medicines, at least eight courses of carbarsone, extralin, lextron, haliver oil with viosterol, tabloid reduced iron, salicionyl, potassium iodid dicalcium phosphate, and yeast. She was nervous, lacking in energy, could not stand crowds, and was troubled with occasional arthritis. In July, 1936, she suffered from extreme dryness of the mouth and throat, which was eventually relieved by dilatation of the ducts of the parotid glands. An x-ray of the sinuses and parotid glands at this time showed no evidence of pathology.

Physical Examination.—Temperature, 99.4 degrees F. Teeth were in poor condition. There was bilateral, moderately marked, uniform, painless enlargement of the parotid glands. The thyroid gland was palpable and soft. The abdomen was tender in both lower quadrants.

Sigmoidoscopic examination showed redness and excoriation of the mucous membrane, which was thickened between the valves. Smears for aerobic and anaerobic cultures were taken from this area. No deep ulceration was noted.

Laboratory Tests:

Blood Count: Red blood cells, 4,310,000; hemoglobin, 79 per cent, Sahli (12.5 grams); color index, 92; leukocytes, 6,280; polymorphonuclears, 70 per cent; lymphocytes, 27 per cent; mononuclears, 2 per cent; eosinophils, 1 per cent.

There was slight anisocytosis and poikilocytosis. Red cells showed achromia. (On March 15, the red-cell count and hemoglobin had risen to normal.)

Urinalysis: P_H 6.0; specific gravity, 1.018; albumin (—); sugar (—); rare pus cell; rare epithelial cell.

Basal metabolic rate: 7.2 per cent minus.

Eriometer reading: 7.9 micra.

Gastric analysis: (Alcohol test-meal.)

	Free HCl.	*Total Acid*
Fasting specimen 20 cc. Slight bile	0.	4.
Specimen I. No bile	0.	3.
Specimen II	0.	4.
Specimen III	0.	3.

Stools: Black color, normal odor. Formed, firm consistency. No food remnants. No mucus. Good digestion. Occult blood negative. Dominant bacteria mostly Gram-negative rods. Microscopic examination entirely negative. No parasites nor ova seen. (Series examined, including three specimens after saline laxative.)

Cultures: Taken by sigmoidoscope from upper rectal and lower sigmoid mucosa. Results were as follows:

(1) January 28, 1938:

Aerobic: No typhoid-dysentery organisms. Positive for a mixed culture of B. coli and a few Alpha hemolytic streptococci.

Anaerobic: Also showed a mixed culture of B. coli and an Alpha hemolytic streptococcus. Also, Bacterium necrophorum was isolated, using Dack's technique. This was lost in subcultures.

(2) March 24, 1938:

Aerobic: No typhoid-dysentery organisms. Positive for a mixed culture of B. coli, Staphylococcus albus and Corynebacterium flavidum.

Anaerobic: Positive for a mixed culture of B. coli, corynebacterium flavidum, an Alpha hemolytic streptococcus and a Gamma hemolytic streptococcus.

Wassermann: Reported negative by the patient.

Roentgen Examination.—X-ray of the gastro-intestinal tract, with special study of the small intestine, by Doctors Ingber and Rodenbaugh, gave the following result:

"Fluoroscopic examination of the chest; no abnormality.

"The stomach outlines are smooth, peristalsis is not increased, and there is no delay in emptying. The antrum is not spastic. The duodenal bulb fills readily, smooth in outline, and empties normally. The course of the duodenum is regular.

"Films taken at fifteen minutes, thirty minutes, one hour, two hours, four hours, and six hours show normal distribution of the meal through the small intestines, and no abnormality is noted.

"At six hours distribution is normal, the stomach being empty.

"At twenty-four hours barium is well distributed throughout the large bowel. The cecum has begun to empty, is movable and not tender."

Biopsy.—A biopsy of the left parotid gland was done by Dr. Frederick Foote under local anesthesia. His report is as follows:

"Grossly, this enlargement appeared to be of the gland itself, with the tissue thrown up in nodules. On cutting through it, the gland appeared to be particularly meaty, with small areas of cystic dilatation. These small cysts appeared to contain saliva."

The tissue was sent to Dr. Jesse L. Carr for examination. His report follows:

"Sections show an effuse replacement of the gland by large fields of lymphocytes between which are small islands of cells which are larger, more pale staining, and closely knit. Through this whole mass run dilated salivary ducts which are filled with granular blue coagulum. No normal gland remains.

"Pathologic diagnosis: Mikulicz's disease."

Diagnosis: Mikulicz's disease; chronic colitis; achylia.

Further Course.—X-ray treatment of the parotid glands was followed by rapid reduction in size to normal.

COMMENT

The question arises as to whether the bacterial colitis and achylia may have had an etiologic relation to the parotitis. The achylia may have predisposed to abnormal bacterial flora in the colon. The colonic bacteria, especially some of the streptococci, may have been involved. Of this we have no proof. The upper respiratory infections immediately preceding the parotid enlargement are apparently more closely related to the parotitis. Failing recovery of bacteria from biopsy material from the affected glands, the question of bacterial relations cannot be settled in this case, and we did not think of biopsy tissue culture until too late.

350 Post Street.

CATASTROPHIES FOLLOWING HEMORRHOID INJECTIONS*

By James W. Morgan, M.D.
San Francisco

THE injection treatment for internal hemorrhoids, when bleeding at stool is the only symptom, is based on sound therapeutic principles. In selected cases the results are excellent. Injection may sometimes be used as a palliative measure when the hemorrhoids protrude through the anal orifice. The technique of injection is not easy and requires much practice. All this has been said hundreds of times, but no one seems to have called attention to the disastrous sequelae which often follow hemorrhoid injections.

* From the Department of Surgery, University of California Hospital.

Fig. 1.—Photograph of the perineum of a male patient nineteen days after an injection treatment for internal hemorrhoids. The lower rectum and anus have sloughed away. The patient now has four anal orifices, with no control of bowels or bladder. This patient won a large award in a malpractice suit, but he has lost his rectum.

Gabriel reports a case of a patient with tubular stricture necessitating colostomy as a sequel to an injection treatment. Some rectal surgeons are opposed to any injections, and I predict that in the future we shall all use this treatment less frequently and with much greater discrimination.

The following is a summarized list of the more severe complications in patients who have come under my care following injection treatments:

A. Slough (chemical necrosis):
   1. Localized necrosis causing pain, but unattended by other sequelae.
   2. Generalized necrosis resulting in:
      (a) Mechanical hemorrhoidectomy.
      (b) Cellulitis, with sloughing of entire rectum and complete loss of control.
      (c) Septicemia.

B. Abscess (requiring surgical treatment):
   1. Local abscess.
   2. Anorectal fistula.
   3. Abscess terminating in chronic ulcerative proctitis and colitis.

C. Injury to contiguous structures:
   1. Rectovaginal fistula.
   2. Periprostatic abscess.
   3. Epididymitis.
   4. Vesiculitis with urethral hemorrhage.

D. Severe secondary hemorrhage.

I do not advocate hemorrhoidectomy in all patients with internal hemorrhoids. This operation is attended by some slight risk, and the patient needs to be away from his work for two weeks. The operation offers, however, the only cure, and injection treatments might do more harm than good.

384 Post Street.