In a recent communication she stated that she was well, except for a slight pain over the left shoulder which apparently had no connection with the foreign-body incidence.

SUMMARY

1. This case forcibly impresses upon us the reliability of the history of the accident in all foreign-body cases.

2. That the negative roentgenogram is not in itself proof of absence of usual radio-opaque substance like pork bone.

3. That exploratory bronchoscopy is indicated in every doubtful foreign-body case; and,

4. That the human glottic chink is capable of admitting a large-sized foreign body.

432 South Boyle Avenue.

RUDIMENTARY GALL BLADDER AND CONGENITALLY ABSENT COMMON DUCT

REPORT OF CASE

By J. M. Frawley, M. D., *Fresno*
AND
Stanley H. Mentzer, M. D., *San Francisco*

MARTHA T., an American child, three months of age, was admitted to the Fresno General Hospital because of gradually increasing yellow color of the skin.

The jaundice was not noticed until the baby was at least a month old. Labor was normal; there was no asphyxia. The birth weight was six pounds.

The breast was given for three weeks, then a cow's milk mixture which was not tolerated, and for the last three weeks before admission she had been getting sweetened condensed milk.

When admitted to the hospital there was a marked icterus of the skin and sclerae. The liver was greatly enlarged, emaciation was considerable, and the child's weight was five pounds, thirteen and one-half ounces. The red cells of the blood were 4,150,000 per cubic millimeter; the white cells, 16,000. The blood smear was essentially normal.

The Wassermann was negative, both for the child and the mother. The urine was acid, yellow in color, and showed a trace of albumin.

The stool was white and had the appearance of milk curd. It showed no trace of bile.

The serum was bile-colored and gave a prompt van den Bergh reaction.

There was no increased fragility of the red cells.

Ladd[1] in 1928 reported histories of nine infants, five months or younger, with atresia of the bile duct. In these cases operation was done with recovery in four cases. Encouraged by these results, operation was performed in this case by Dr. J. H. Pettis. No trace of the gall bladder or common bile duct could be found, and therefore it was impossible to do the plastic operation described by Ladd.

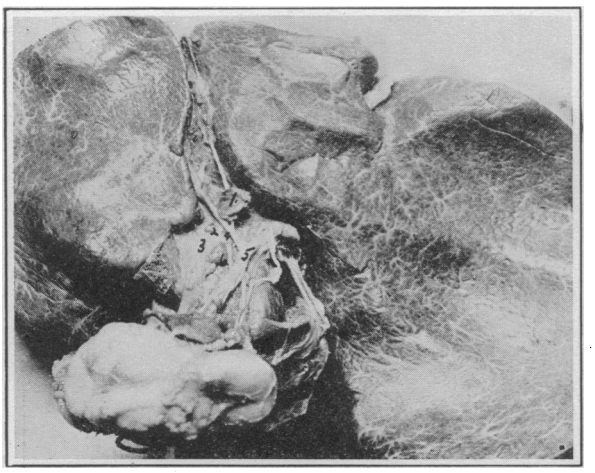

1. Remnant gall bladder. 2. Cystic duct. 3. Right hepatic duct. 4. Stump of common duct. 5. Portal vein. 6. Hepatic artery.

In our case autopsy two days later, the liver was found greatly enlarged and dark green in color. The gall bladder was present, but only about one-tenth of its normal size. There was a true cystic duct which joined the right hepatic duct to form a blind stump one centimeter in length. There was no communication or even rudimentary fibrous cord between this stump and the duodenum. The pancreatic ducts were present and patent.

SUMMARY

A case of congenital absence of the common bile duct is reported. The findings are unusual because:

1. The common bile duct was completely absent, except for a patent stump one centimeter long.

2. The gall bladder was rudimentary and the cystic duct drained into the right hepatic duct instead of the common duct.

Patterson Building, Fresno.
450 Sutter Street, San Francisco.

REFERENCE

1. Journal American Medical Association, 1928, Vol. 91, p. 1082.

AGRANULOCYTIC LEUKOPENIA IN RELATION TO ACUTE FEBRILE UPPER RESPIRATORY INFECTION

REPORT OF CASE

By Eugene R. Lewis, M. D.
Los Angeles

THE first reference I have found to agranulocytosis is Schultz in 1922. Subsequent cases have been reported by various observers, Kastlin collecting forty cases in 1927; Linthicum, Uren, and others reporting additional single cases since. Many of these cases have been anginas in which the main bacteriologic factor has been the *Bacillus pyocyaneus,* although symbiosis of Vincent, the colon bacillus and various strepto- and staphylococci have been reported. While it is apparently possible in any individual, the mass of clinical evidence points to its typical incidence in middle age, and the female sex.

In the literature on this subject there is found nothing significant in the history. The disease is usually of sudden onset, often with chill, fever, malaise, and sore throat, and is usually rapidly fatal. The clinical course of the disease is characterized by general signs of illness out of proportion to local pathology; temperature and pulse rate are high, asthenia and depression are marked, local swelling, edema, and sloughing sometimes ultimately extensive; the first differential blood cell count reveals leukopenia, with disproportionately low granular and polymorphonuclear counts. Eventually the white cells may fall below 500, and in exceptional cases, below 100, with absence of polymorphonuclears and granulocytes.

Uren has compared the pictures of agranulocytic leukopenia and infectious mononucleosis, which is more apt to occur in younger individuals. There is a white cell count between 7500 and 15,000, with increase of mononuclear and decrease of granular cells. Its clinical course is mild and recovery is the rule.

REPORT OF CASE

On November 30, 1928, I was called to see Mrs. B. H., a young married woman, aet. 35. Previous health had been frequently below par, but only vague complaints could be elicited. Tuberculosis had been repeatedly excluded; gastro-intestinal, respiratory, and endocrine studies had never revealed overt pathology. She had had one normal pregnancy, and for a year or two previous to this illness she had been in good flesh and strength. The day before I saw her she had noticed sore throat, general malaise, and aching. Her pulse on first examination was 92, temperature 100.8; tongue slightly coated, pharynx red, nasal mucosa congested, and there was mild tracheobronchial irritation. No râles or chest symptoms, no abnormalities of heart or circulation, abdomen or extremities noted on casual inspection; blood pressure was 98/70. Chief complaints were headache, general pains, sore throat, and weakness. She was put to bed on fluid alkalinization and hot fomentations. The following forty-eight hours the clinical picture remained about the same, temperature ranging higher, but less headache and cough.

On December 2 the blood picture was: white blood cells, 1600—45 per cent polymorphonuclears, 50 per cent lymphocytes, and 5 per cent transitional.

	White Cells	Polys.	Lymph.	Trans.
December 3	1400	37%	50%	4%
December 4	600	40%	55%	5%
December 5	1500	26%	68%	6%
December 6	1400	43%	55%	2%
December 7	1600	25%	73%	2%
December 8	2300	25%	73%	2%
December 9	3600	24%	73%	3%
December 10	2500	52%	47%	2%

After December 10, the white count rose gradually, reaching 6200 by December 16, with 62 per cent polymorphonuclears and 37 per cent lymphocytes. No correlation seen at any time between the daily blood count and the clinical condition. On December 2 and 4, with 1600 white cells, 43 per cent polymorphonuclears; and 600, 25 per cent polymorphonuclears, respectively, the patient experienced profound improvement. The accuracy and reliability of all blood counts was carefully rechecked and is unquestionable. The clinical course was satisfactory in every respect from the start. Throat symptoms, cough, headache, and general discomfort subsided gradually, with no new developments. At the end of the eighth day, temperature reached normal; the white count rose gradually; The patient made a complete recovery and has remained well for nine months.

COMMENT

At the time this case occurred there were many cases of acute "grip" or so-called "flu"—not sufficient to warrant the term "an epidemic," however. The white counts of fifteen or twenty clinically similar cases at this time were between 7500 to 20,000, with granular cells and polymorphonuclear cells present in the usual proportions. Inquiry revealed a few cases of moderate leukopenia at this time in patients of other physicians—none below 5000, and none with falling granulocyte and polymorphonuclear cell counts.

This case fails to support the usually accepted thought that the white and differential count sheds definite light on the reaction of the individual's mechanism of resistance to the present infectious invasion; and also gives some indication of the measure of acquisition of immediate immunity to that infection.

1154 Roosevelt Building.

A NEW KNEE BANDAGE

By MAST WOLFSON, M. D.
San Francisco

FOR knee injuries many devices and bandages for ambulatory treatment have been made. These have ranged from simple covering with the elastic knee bandage to the more intricate metal braces.

The object of this article is to report and describe a bandage which has been useful in the hands of the author in the treatment of some acute and chronic knee injuries.

This bandage is essentially the old figure eight bandage, made out of four-inch flannel. It must be made to order for each knee treated so as to conform exactly to the patient's contour. After several layers of bandage have been placed snugly about the knee in a figure eight, they are pinned in position and basted there. In the middle of the external surfaces the bandage is cut between longitudinal bastings. Machine stitching and cross stitching now take the place of the bastings, and reinforcements of strong cloth are made about the edges. A tongue is placed within the bandage.

Four special toothless buckles are placed on the cut edge—two above the knee-joint, and two below it; with these the patient can slip it on and off and tighten the bandage where it is necessary. The line of force of the figure eight bandage remains constant (see plates 1 and 2). Pressure pads may be placed over various areas inside the bandage if needed.

This bandage has proved effective, comfortable, and warm. It is inexpensive and easily washed. Complete flexion of the knee is possible without distorting the bandage.

490 Post Street.

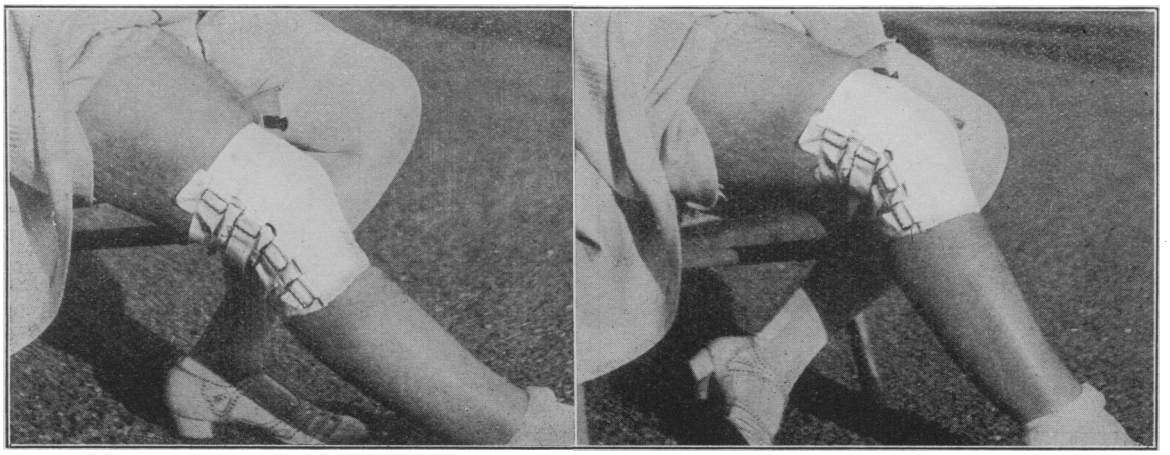

Plate 1 Plate 2

Illustration of new knee bandage