vessels, are numerous bone trabeculae. The capillary vessels are surrounded by a few or a dense mass of lymphoid cells. The larger blood vessels are greatly engorged with blood. The bone trabeculae surrounding the marrow spaces are covered with a thin layer of osteoid tissue to which numerous osteoclasts are attached. Here and there are a few osteoblasts causing a moderate resorption of the bone trabeculae. Some bone trabeculae do not show lamellary formation, but the structures of immature bone tissue, consisting of irregularly arranged cells within the bone trabeculae, surrounded by a layer of osteoid tissue to which numerous osteoblasts are attached. The connective tissue in the immediate neighborhood contains a great many nuclei, forming an intermediate proliferation zone. A few bone trabeculae contain small islands of non-calcified cartilage cells. Of interest are some areas which are suggestive of an enchondral ossification, on the basis of calcified cartilage. The bone trabeculae are of irregular shape and made up of embryonal bone tissue containing small marrow spaces.

Garden City Bank Building.

REFERENCES

1. Baetjer and Waters: Injuries and Diseases of the Bones and Joints, p. 278.
2. Surgery, Gynecology and Obstetrics, Vol. 39, p. 795.
3. Rosenstirn, J.: Myositis Ossificans, Ann. Surg., 1918, Vol. 68, p. 485.

DISCUSSION

RAYMOND G. TAYLOR, M. D. (1136 West Sixth Street, Los Angeles)—Doctor Bullitt's comprehensive presentation of this subject and his rather complete discussion of the various theories and classifications leave but little to be said except to confirm his expressed deductions and opinions.

I have had the same experience in reference to being unable to reconcile the clinical and roentgen appearance of some of these lesions with the description given by Baetjer and Waters, and I feel with the essayist that their description certainly does not cover many of the lesions we see that are of traumatic origin. I have seen at least one rather extensive lesion of traumatic origin in the femur that certainly was not covered by periosteum. This recurred twice after removal, and after the third operation did not recur. The very limited experience we have had in observing these lesions leads us to believe that recurrences are probably, in most cases, due to incomplete removal.

HOWARD E. RUGGLES, M. D. (Fitzhugh Building, San Francisco)—In Rosenstirn's[3] extended discussion of myositis ossificans he calls attention to the fact that the posttraumatic and progressive forms of this unusual condition are identical in their pathology, both showing a progressive ossification of a pre-existing hemorrhage, the only difference being that in the traumatic cases the hemorrhage and the ossification are limited in extent.

A somewhat similar condition is also seen at times particularly about the elbow joint where there has been a dislocation resulting in hemorrhage which is followed by ossification.

Apparently the periosteum plays no part in this bone formation.

Doctor Bullitt is to be congratulated upon his presentation of this interesting condition.

JOHN D. LAWSON, M. D. (Woodland Clinic, Woodland)—Doctor Bullitt has presented this subject with his usual thoroughness, and is entitled to much commendation on his effort.

These lesions which are rather typical are generally not difficult of diagnosis, which can be made only by roentgenogram.

Some confusion has existed in regard to the differential diagnosis between ossifying hematoma and myositis ossificans.

Stone especially holds to the view that all ossifying hematomas must be covered with periosteum. I think the majority of the men will not concur in this, inasmuch as these lesions may be noted somewhat distant from periosteum, and biopsy reveals no evidence of this tissue.

The lesions which we have noted have occurred during the second and third decades, because it is about this time that patients are subjected to violent traumatic agencies. They are much more common in the male for this reason.

Probably many cases of ossifying hematoma are passed up without diagnosis by the surgeon and internist for lack of roentgen investigation. Any disability following violent trauma to the soft tissues, which persists longer than one would ordinarily expect, should be very carefully investigated to show the presence of absence of this condition.

ROSCOE G. VAN NUYS, M. D. (Oakland Bank Building, Oakland)—This excellent discussion of Doctor Bullitt's is certainly a contribution to the subject. My observations of this condition have been very limited. The two cases which I can remember having seen certainly did not seem to be of periosteal origin.

In the future I shall look for these cases with greater interest.

NON-TUBERCULOUS PULMONARY SUPPURATION *

By PHILIP H. PIERSON, M. D.
San Francisco

DISCUSSION *by S. C. Davis, M. D., Tucson, Arizona; Harold Guyon Trimble, M. D., Oakland; Robert L. Cunningham, M. D., Los Angeles.*

DURING the past decade there has been a pronounced tendency to classify as tuberculous a great many people suffering from chronic lung suppurations. This has had its favorable aspect, for it emphasized the importance of recognizing many signs and symptoms present in tuberculosis. But it also had a disadvantage which many of these waves of enthusiasm have, namely, of considering many patients as tuberculous who were suffering from some other disease. Within the last two years or so the pendulum has been swinging in the other direction, and there has been a desire to avoid the diagnosis of tuberculosis whenever it is not evident. The natural consequence will be a benefit to us all through a greater interest in studying these cases, and through a more careful and early diagnosis of tuberculosis, and patients will be benefited by receiving specific treatment outside of sanatoria for chronic infections. It is hoped that the data presented in this paper will help to clarify the symptom complex assigned to abscess, bronchiectasis and chronic pneumonia. Let us first consider pulmonary abscess.

PULMONARY ABSCESS

Many etiological factors have been mentioned, but for simplicity's sake, I will group the cases reported under five headings: Those due to aspiration, embolism, pneumonia, rupture of an

* Read before the General Medicine Section, California Medical Association, at its Fifty-Sixth Annual Session, April 25-28, 1927.

empyema and trauma. One of the most important helps in diagnosis of diseases of the lungs is a carefully taken history. Non-tuberculous disease is to be suspected in an adult whose infection has been chronic since early childhood. Some of these arise from the aspiration of a foreign body, and careful questioning will reveal this as an etiological factor. But it is not always possible to elicit this information on questioning, even if it is the cause. Roentgenologic study reveals opaque bodies and gives suspicious evidence on non-opaque objects, such as a kernel of corn, peanut husk, etc., which form a ball-like valve in a bronchus. As inspiration is stronger than expiration, air enters the lung beyond the obstruction, where its partial retention causes a localized emphysema, distal to the object.

In the group of abscesses here reported, six were the result of aspiration, and reference to the chart will show that there were several materials causing the damage—seawater, chicken bone, blade of grass, a piece of nasal bone following operation on the nose, septic material from the mouth—pus from an osteomyelitis of the jaw, and bloody mucus following tonsillectomy under heavy ether anesthesia. Following such aspiration, there is generally a period of twelve to fifteen days, during which time, there may be no symptoms, or there may be the gradual onset of fever, malaise and an unproductive cough; towards the end of this time, chills and sweats are added to the picture, which persist until the abscess ruptures.

		Cured	Improved	Unimproved	Dead
Medical	15	10	3	2	0
Bronchoscopy	2	1		1	
Surgery	10	4	2		4
Pneumothorax	3		1	1	1
Totals	30	15	6	4	5

ETIOLOGY

			Lobe
Pneumonia	10		LLL Improved
			RML Improved
			RML Cured
			RLL Unimproved
			RLL Unimproved
			LLL Improved
			LLL Dead
			RLL Unimproved
			RML Cured
			RML Cured
Aspiration	6	1 Posttonsillectomy	RLL
		1 Sea Water	LLL Cured
		1 Blade of grass	RLL Dead
		1 Nasal bone, post-operative	RLL Cured
		1 Chicken bone	RLL Improved
		1 Pus from disch. Osteomyelitis (jaw)	LLL Cured
Embolic	11	1 Hernia	RLL Cured
		1 Postpartum	RLL Cured
		1 Kidney stone	LLL Cured
		1 Operation on lip	LUL Unimproved
		1 Appendix	RLL Dead
		1 Gall bladder	RLL Cured
		1 Laceration of face	LUL Cured
		1 Fibroid	LLL Cured
		3 Posttonsillectomy	RUL Dead LLL Improved RLL Improved
Trauma	2		RUL Cured
		1 Fractured ribs	LUL Cured
Chronic Empyema	1		LLL Dead

AGE

Under 10	10-20	20-30	30-40	40-50	Over 50	Unknown
3	2	2	11	4	6	2

Table 1—Results of Lung Abscess Cases.

The history of the patient who aspirated seawater was briefly as follows: Prior to his fall from a ship, he had been well except for occasional "head colds." Following the accident, during which he was thoroughly chilled, he had a slight, non-productive cough, not relieved by medicine, for two weeks. He then began to have some chills and fever. On the twentieth day, this had reached 103 degrees F. and he expectorated foul sputum. Both temperature and sputum gradually subsided and he was practically well two months later. The anerobic bacteria, probably the cause in this case, explain the long latent period.

Eleven of these abscesses were the result of emboli, three of which followed tonsillectomy, one each followed operation for cancer of lip, laceration of the face, disease of the gall bladder, acute appendicitis, fibromyoma of the uterus, hernia, stone in the kidney, and one was a postpartum embolus.

The history of the case of the abscess caused by a postpartum septic embolus from an infected vessel in the broad ligament is presented for comparison with the abscess caused by the aspiration of seawater. The patient, a woman of 30 years, entered the hospital for confinement of her fourth child on November 20, 1926. She had been having pain in her right lower quadrant for some weeks. Three or four days prior to and following her delivery, she had a temperature ranging from 100 degrees to 101.5 degrees F., this being due to a probable pelvic phlebitis, and on the fourth day she was seized with a sharp pain in her right lower chest, more pronounced with breathing. She had no cough or expectoration. Locally there was slight dullness, but no change in breath sounds. Within the next six days, during which time the temperature remained about 101 degrees, signs at the right base developed including dullness, diminished breathing and slight egophany. On this day, I aspirated one ounce of blood-stained, cloudy fluid. The breath sounds gradually became harsher and closer to the ear. On the 7th day of December she expectorated 150 ccm. of purulent sputum. Postural treatment was instituted, and within seven days expectoration had ceased and the patient was afebrile. A roentgenogram taken on the 7th day of December showed a definite cavity 1½ inches in diameter with a fluid level. Within four days this had become very much smaller and within three weeks it had entirely disappeared.

I think the importance of small emboli as factors in the production of postoperative complications has not received sufficient attention, or at any rate, not sufficient data has been kept to give us an estimate as to how often emboli

occur following operations. A small, sterile embolus frequently breaks off from tissue which has been roughly handled or crushed, and on reaching the lung may cause very few signs or symptoms, provided the circulation in that part is good and there is no chronic infection present. In such instances, the patient may complain of a small amount of pain, there may be a slight rise in temperature, both of which are attributed to some other cause during the early days of convalescence. But if this embolus lodges in a portion of the lung where there is more or less congestion, a pneumonic patch will develop, which often undergoes necrosis with the formation of an abscess. An embolus from a septic field, such as was present in this case, frequently causes an abscess. Some writers have reported a proportionately large number of abscesses following tonsillectomy. It is possible that some abscesses are the result of aspiration of infected material into a part of the lung which is locally less resistant. Aspiration was apparently the cause of the formation of an abscess in one of my patients who was suffering from a chronic bronchitis, as the result of an upper respiratory infection when he was operated upon under a long ether anesthesia. The experimental work of Holman and Chandler leads us to believe that a great many of these posttonsillectomic abscesses following tonsillectomy are the result of infected emboli from the seat of operation, especially where there is infection and considerable crushing of tissue. In this series, four such abscesses were found, three of which I attributed to emboli, and the fourth to aspiration. The diminished frequency of abscess following tonsillectomy is probably due to better administration of the anesthetic and to the suction apparatus devised by Sewell, which keeps the pharynx freer from blood and mucus. Bleeding is controlled by tying the vessels. This leaves a cleaner postoperative field.

Ten cases of pneumonia, all of the bronchopneumonic type, resulted in abscesses. The important point, so far as the history with reference to pneumonia is concerned, is that a protracted fever recurring after the initial infection has apparently subsided, very often represents the formation of an abscess or the development of an empyema. Under this heading, I placed a few abscesses of which the etiology was not clear, although their history suggested pneumonia. In abscesses, as in chronic pneumonia, an infection in the upper respiratory tract plays an important rôle. This will be dealt with more fully later. The dullness, diminished or absent breath sounds and tactile fremitus found in parietal empyema may justify aspiration for diagnosis. If there is doubt as to whether empyema or abscess is present, do not push the needle too far and so enter the lung. Abscesses and interlobar empyemas should never be needled for diagnosis, unless there is visible evidence of adhesions between visceral and parietal pleurae. In one case of this series this procedure of needling was followed by empyema. This danger is too imminent not to mention it in the most disparaging terms.

The question has often been raised as to why trauma to the chest wall results in pneumonia, abscess or exacerbation of a tuberculous focus in some instances, and not in others. I do not know that anyone has been able to explain this conclusively. But the lowering of one's resistance

		TREATMENT				RESULT			
Etiology	No.	Medical	Surgical	Pneumothorax	Bronchoscopy	Cured	Improved	Unimproved	Dead
Pneumonia	10	4				1 (RML)	1 (LLL)	1 (RLL)	
			3			1 (RML)	1 (LLL)		1 (LLL)
				2			1 (RML)	1 (RLL)	
					1			1 (RLL)	
Aspiration	6	2				1 (LLL)	1 (RLL)		
			3			1 (LLL)			1 (RLL)
						1 (RLL)			
					1	1 (RLL)			
						2 (RLL)			
						2 (LLL)			
						1 (LUL)			
Emboli	11	7				5	1 (LLL)	1 (LUL)	
			3			1 (RLL)	1 (RLL)		1 (RLL)
				1					1 (RLL)
						1 (RUL)			
						1 (LUL)			
Trauma	2	2				2			
Chronic Empyema	1		1						1 (LLL)
Totals	30	15	10	3	2	15	6	4	5

LOBES

R. U. L.	R. M. L.	R. L. L.	L. U. L.	L. L. L.
2	4	12	3	9

SEX

Male	Female
18	12

Table 2—Treatment and results following various types of lung abscess.

as a result of an accident, an irritation of the pleura with congestion of the underlying lung, in the presence of the pneumococcus, streptococcus or tubercle bacillus, is the most plausible explanation for the development of disease in the group of cases here discussed. Broken ribs are often treated very casually with adhesive strapping, but an accompanying damage to the lung should always be kept in mind, and repeated examinations of the lungs made to determine whether a resultant disease has developed.

Let me here stress the great value of a careful roentgenologic study in determining the location and character of all abscesses as well as the etiology in some instances. Before the rupture of an abscess, it is difficult to distinguish, radiologically, abscess from pneumonia. Following the rupture, winking of the cavity is seen fluroscopically and a fluid level is usually present. Its disappearance following postural drainage, the regression of the pneumonic infiltration and of the size of the abscess are most clearly brought out by roentgenographic studies.

Repeated negative examinations of the sputum for tubercle bacilli in the face of considerable expectoration are in favor of a pyogenic abscess rather than of a tuberculous lesion. Elastic fibres in the early stage of an abscess are very often found when a thorough search is made.

THREE MAJOR FACTORS IN DIAGNOSIS

I feel that these three factors, namely, history, careful roentgenographic study and examination of the sputum are of prime importance in the diagnosis and treatment of pulmonary abscess. Physical findings are often very indefinite. If the abscess is near the pleura, the most constant signs are dullness, diminished breathing, which becomes bronchial as the pneumonic area progresses. After the rupture of the cavity, we sometimes hear an amphoric whisper, but this is not at all constant. Later on, râles appear, but in relatively small numbers. A centrally located abscess may give no physical signs, due to the overlying normal lung. A slight dullness is sometimes present. Hemoptysis has often been mentioned as pathognomonic of pulmonary tuberculosis, but in this series, there were definite hemoptyses of over an ounce in ten of the cases, and of some blood in practically all of the others. Tuberculosis may be localized either in the upper or lower lobes, which further confuses the differential diagnosis.

TREATMENT

As soon as the diagnosis of pulmonary abscess is established, whether before or after rupture, medical treatment is indicated for a period of time, its length depending upon the progress of the lesion and the ability of the patient to cope with the infection. Admitting that my series is small, which may lend a rather unfair aspect as to treatment in general, it nevertheless shows a mortality of 16 2/3 per cent. Of fifteen cases treated medically, none died and only two were reported as unimproved, this being at least partially due to their refusal to submit to surgical treatment. Postural treatment is of more value in acute pulmonary abscesses than in chronic abscesses, and should always be instituted for at least three or four weeks following the rupture of an abscess, and longer if needed, provided the patient is making satisfactory progress. If at the end of this period, no progress is noted, either as evidenced by diminution of temperature, amount of expectoration or improvement in general well-being, bronchoscopy should be considered.

I do not mean that one should delay bronchoscopy four to six weeks in cases in which either the history or roentgenogram gives evidence of a foreign body, since the removal of these, causes abscesses to clear up promptly. Its use at the time indicated is largely to remove obstructing granulation tissue and allow freer drainage. Patients treated by bronchoscopy have been temporarily very much inconvenienced by the procedure, and I fail to see the value therapeutically of the aspiration of a relatively small amount of pus once or twice weekly. In more experienced hands or in a larger series, this procedure may have benefits not at present apparent to me.

Pneumothorax has been recommended by some, including Edouard Rist, but when the abscess is close to the pleura, it is a dangerous procedure to undertake. Even in giving small amounts of air, a slight tear in the pleura frequently results in pyopneumothorax. Occasionally this air may be under pressure, the result of leakage in only one direction. In centrally located abscesses, it is indicated and often of great benefit. The case reported in this series, I would be inclined to call cured, had the patient not disappeared after about eighteen months of most favorable progress.

During the period of waiting, counter irritants over the affected part of the lung are helpful, and bed rest, plenty of fresh air and sunshine and a high caloric diet are needed to keep the patient in as good physical condition as possible. It is rare that drugs are necessary. Occasionally a mild expectorant may be used to save the patient from the tiresome effort of raising thick sputum, and sedatives may be necessary at night to insure sufficient rest.

In these cases where medical treatment has failed after a period of about four to six weeks, surgery is indicated. It is generally agreed that in the absence of adhesions, the two-stage operation is necessary. The first procedure is to resect

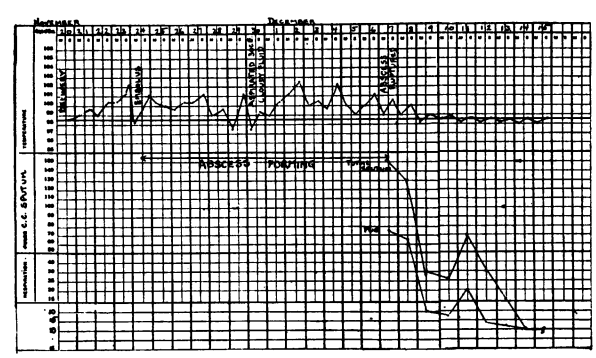

Fig. 3—Chart. Record of case quoted. Lung abscess due to septic embolus.

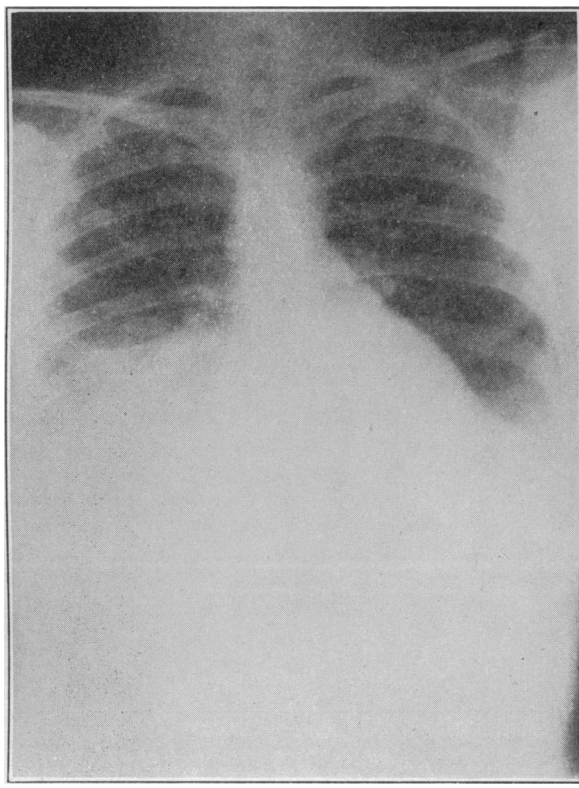

Fig. 4—X-ray of lung on December 7, showing abscess in right lower lobe with fluid level.

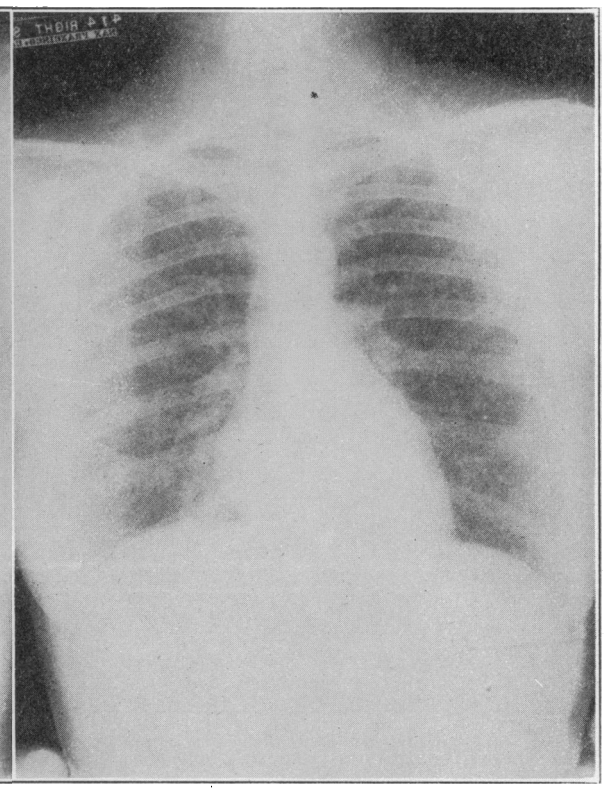

Fig. 5—X-ray of lung, same patient, February 1, showing complete disappearance of abscess shadows.

sections of one or two ribs and cause adhesions between the two layers of pleura, either by suturing or packing with gauze. After three or four days, incision with the cautery is made into the abscess and drainage is instituted. The mortality of this treatment in acute abscesses is relatively low and proportionately high in chronic abscesses, including those in which empyema has resulted. The bronchial fistula should be kept open for a considerable time so that thorough drainage may be obtained from all the small pockets surrounding the central abscess.

The after care is very essential, including sunshine, fresh air, high caloric diet, etc. For a year or more the patient must be very careful to avoid acute respiratory infections and whenever possible he should live in a warm, dry atmosphere.

To summarize, in regard to abscesses, let me say that a careful history is very important in defining the etiology of the lesion; the physical signs are very meager as compared with a tuberculous lesion of the same extent; the x-ray is indispensable for localization of the abscess and for a better knowledge as to the progress of the disease. Medical treatment should always be tried for at least four to six weeks. If no improvement is made by that time, surgical treatment is indicated. The mortality in general is low in acute abscesses but high in the case of chronic disease.

CHRONIC PNEUMONIA AND BRONCHIECTASIS

A large number of patients with chronic cough and purulent expectoration have been diagnosed as having bronchiectasis, but I feel that if a more accurate diagnosis were made, some being classified as having a bronchiectasis and others a chronic pneumonia, our prognosis would be better in the latter group than in the former. First, let me describe the chief difference in the pathology of the two conditions.

Given a streptococcic pneumonia of the type so often seen associated with influenza, the infectious process is located in the peribronchial tissue surrounding the smaller as well as larger bronchi, and also invades the stroma of the alveoli. In some instances the infection weakens the bronchial wall, replacing some of the normal elastic tissue with fibrous tissue and by its dilatation, saccular cavities or cylindrical widening of the bronchi result. Chronic infection becomes implanted upon the mucous membrane divesting it of its normal epithelium, and a true bronchiectasis is produced.

Very often the infection while present in the peribronchial tissue extends by contact into the alveoli whose interstitial tissue is infiltrated and replaced by scar tissue, resulting in a fibrosis extending beyond the bronchial walls and throughout the parenchymatous tissue. The term "chronic pneumonia" is applied to that group of cases in which the fibrosis in the parenchyma predominates, at least relatively, over that surrounding the bronchi, and in which slight cylindrical dilation may be present or less often, saccular cavities. This pulmonary fibrosis without marked bronchial dilatation generally does not cause the severe symptoms present in bronchiectasis. A mild phase of this fibrosis exists which is yearly represented by recurring attacks

Fig. 6—Pathological section of chronic pneumonia. Note interstitial fibrosis predominating over bronchiectasis.

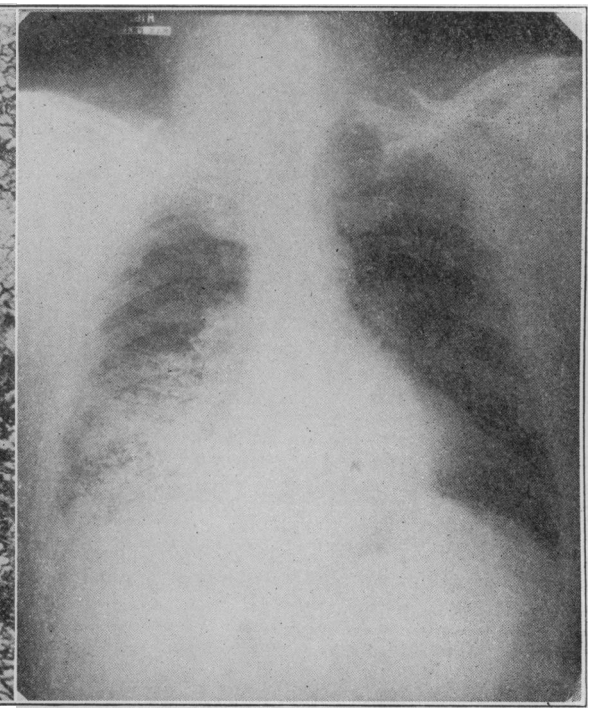

Fig. 7—Chronic pneumonia. Right base with "normal" lipiodol study.

of infection in the winter, disappearing in warm weather. On physical examination, a patch of coarse indeterminate râles are periodically found in the same place, generally disappearing some time after the symptoms of the respiratory infection have passed. As this type of infection resulting in fibrosis does not cause very marked shadows in the x-ray, nor sufficient distortion to produce a typically abnormal picture after the lipiodol injection, it is often overlooked. This mild form of chronic pneumonia can bear particular emphasis, because it is so often the seat of chronic recurring infections, attracting little attention. It is in this mild form while still in its early stages that upper respiratory infections from the sinuses and tonsils play a very important rôle. Repeated infections with involvement of this fibrous tissue cause a progressive disappearance of normal parenchyma, which is followed as a rule by a tendency toward bronchiectasis. Consequently, the early recognition of these changes and their correction will prevent subsequent damage which is irreparable.

In reviewing a considerable number of cases in private practice and in the Stanford Chest Clinic, it would seem that pneumonia, influenza and sinus infection play a prominent part as etiological factors. Whooping cough, and, less often, measles in childhood should also be mentioned.

TREATMENT

It is evident, then, that the early recognition of this gradual infectious process in the lung offers a considerable field for preventive measures. Local treatment is often of help, including among other things, diathermy and the radical clearing up of upper respiratory infections. A change to a warm, dry climate is also very beneficial in preventing further progress. This is particularly true in children in whom with energetic therapy, the process clears up permanently.

Whenever there is retention of mucus or pus, postural drainage should be instituted. In the more advanced stages of this fibrosis, as well as in bronchiectasis, postural drainage is of some benefit, but it does not have the lasting effect obtained in the earlier stages of the disease.

Improving the general health of the individual is of value. Sun baths, either natural or artificial, regulation of diet, proper exercise and plenty of rest are essential. In advanced cases of bronchiectasis, or chronic pneumonia, medical treatment may alleviate symptoms but rarely eradicates the disease. In spirochetal infections, as well as in some bacterial infections, salvarsan may be distinctly helpful. Patients may be made more comfortable by emptying these pockets by postural drainage at certain times during the day, an endeavor being made to prevent their overflowing and infecting neighboring tissue. This will relieve them of the constant cough and expectoration which makes them so unacceptable in society or in a gainful occupation. Here again, bronchoscopy has been recommended by some, with great benefit, due largely, I feel, to the removal of granulations and better drainage with posture.

Of forty cases treated with autogenous vaccine, 50 per cent were distinctly relieved of cough and expectoration for varying periods. This seems to be the extent of its therapeutic value; but even this to a person with such distressing symptoms as are present in this group of cases, is very welcome. Unfortunately, the disease is bilateral

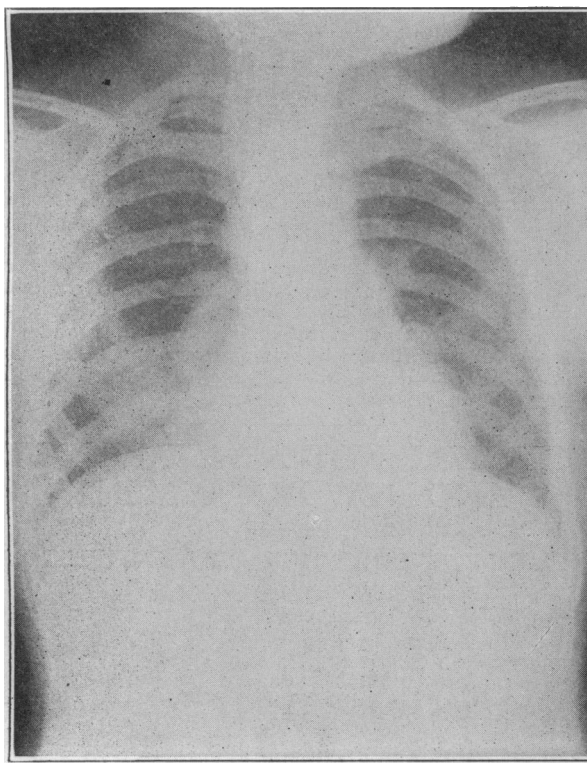

Fig. 8—Base of right lung of child with chronic pneumonia of six months' duration.

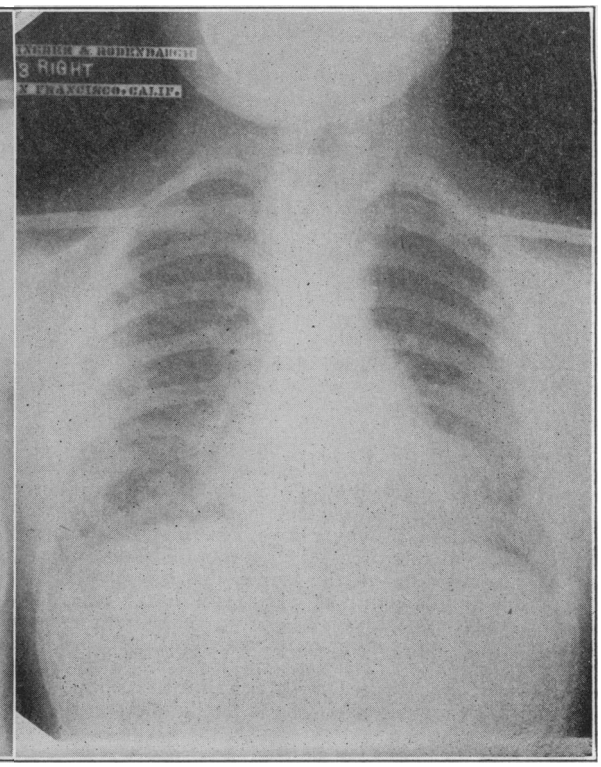

Fig. 9—Same, six months later. Note clearing at right base.

in a large proportion of cases. Whenever a unilateral condition exists which does not improve with medical treatment, surgical measures are indicated which may consist either of thoracotomy with drainage of one or more large cavities, or of Graham's cautery lobectomy. Opinions differ as to the value of this procedure because of the considerable risk of hemorrhage and cerebral emboli, but theoretically it has many advantages. Extrapleural thoracoplasty may be of value in unilateral cases, together with avulsion of the phrenic nerve, which offers a means of compressing the affected lung. Benefits from pneumothorax are very few and have the same disadvantage as previously discussed under pulmonary abscess.

A few words should be said with regard to lipiodol. Its use has been very helpful in distinguishing true bronchiectatic cavities, with marked cylindrical or saccular dilatation from a diffuse fibrosis. Its administration is relatively simple, requiring only at time a small amount of local anesthetic in the pharynx and larynx, the warmed oil being dropped slowly down through the larynx, while the patient holds his own tongue in full extension. Before the procedure is started, I feel that it is very important to prepare the patient by postural drainage of the cavities for at least one hour. Then the patient should undergo no exertion from the time he receives the lipiodol until the picture is taken, for exertion often starts a paroxysm of coughing and expectoration of the oil.

Summarizing our considerations of bronchiectasis and chronic pneumonia, the early recognition of the latter disease, the energetic treatment of upper respiratory foci of infections, local treatment and attention to general health will often offer a better prognosis in chronic pneumonia alone than when associated with bronchiectasis. A negative lipiodol study, if carefully carried out, gives evidence against bronchiectasis and in favor of chronic pneumonia. Postural treatment and autogenous vaccines make life more bearable for the inoperable cases of bronchiectasis, while in unilateral disease, surgical treatment offers increasing hope of alleviation of symptoms and cure of the disease.

490 Post Street.

DISCUSSION

S. C. Davis, M. D. (27 South Scott Street, Tucson, Arizona)—I have never heard this subject so ably discussed. Non-tuberculous pulmonary pathology is especially of interest to us, located as we are, where many come to find the mild, dry climate that Doctor Pierson speaks of in his treatment. Especially are we interested in the chronic pneumonias and bronchiectasis and our opinion that some of the cases that are reported to have repeated attacks of pneumonia, the pathology is none other than an acute inflammatory condition of the lung tissue surrounding a bronchiectatic process.

Many such cases of pneumonitis remain practically free of attacks while residing in Tucson.

We are very cautious in making or corroborating a diagnosis of tuberculosis in basal pathology unless we have a positive sputum.

We hope many will have the opportunity of reading this paper, which covers the subject in detail and be benefited to the extent that many cases previously diagnosed tuberculous will be properly cared for.

Harold Guyon Trimble, M. D. (707 Latham Square Building, Oakland)—There is nothing I can add to this splendid paper. It gives in detail the current thought on these relatively common types of lung infections. There are some points I feel sure that

Doctor Pierson would have elaborated, had space permitted.

Carefully controlled heliotherapy, preferably natural sunshine—the various lamps being only a substitute—is of definite value even during the more acute phases of lung abscess. In the chronic stages of all the non-tuberculous lung suppurations it is of marked benefit. The direct effect on the lung itself may not be marked, but the general improvement in the patient's condition is usually such that if surgical measures are indicated, the attending shock is greatly minimized. This type of therapy is particularly neglected by surgeons who have not the opportunity of frequent contact with a chest consultant.

In chronic pneumonia and bronchiectasis the "radical clearing up of upper respiratory infections" is fundamental and frequently neglected. One can have but little hope of a permanently successful result if this is overlooked.

Drugs offer little except symptomatic relief in all of these infections. However, the time-honored creosote is often of marked value in chronic pneumonitis. It is best given as guiacol carbonate in 5-grain capsules as often as every two hours. Occasionally this is not well tolerated—then the soluble potassium guiacol sulphonate in the same dosage is usually accepted. This sometimes clears up basal râles of months standing.

For autogenous vaccine we are using the "selective pathogen" method of preparation (culturing a sample of the carefully collected fresh sputum in a sample of the patient's own blood). Theoretically, those organisms will grow most abundantly against which the patient has the least resistance. Practically it seems to work. This method has given us decidedly better response, as judged by the focal reaction, during the three years it has been used.

In closing, I would make a plea for the use of surgery, not as a last resort, but judiciously, in properly selected cases, after careful medical supervision alone, has failed to achieve a satisfactory result.

❦

ROBERT L. CUNNINGHAM, M. D. (506 Medical Office Building, Los Angeles)—For many years, emphasis was laid upon the early diagnosis of pulmonary tuberculosis and the tendency was to designate as tuberculous conditions which possibly were not really such. This was amply illustrated by the large number of men rejected for service in the army and navy during the war as being tuberculous, who were later found to have some other pathological condition. The prevalence of influenza and kindred infections since 1918 has also given rise to a host of pulmonary conditions which were rare or unrecognized before. These circumstances, together with new refinements in the technique of study and more critical observation, may account for the increasing frequency with which non-tuberculous pulmonary suppurations are now demonstrated and for the many excellent papers appearing upon this subject within the last two or three years. I have read with interest many splendid contributions but can recall none covering the field more adequately than does this presentation by Doctor Pierson.

In this paper, there is material for an extensive monograph. The one paragraph upon foreign bodies in the lung might well be expanded to an interesting chapter, while aspiration, pneumonia or pulmonary embolism offer equally inviting opportunities. Doctor Pierson has shown great restraint, which, I trust, simply means that he intends to treat those questions more fully later.

A diagnostic point, which has seemed to me of value in hinting at intrapulmonary abscess rather than pneumonia or empyema when differentiation has been in question, is the presence of pain referred to the shoulder or acromion process on the affected side. It always makes me suspicious because of the frequency with which I have found it in proven cases of pulmonary abscess but seldom elsewhere.

Under the treatment of abscess, Doctor Pierson does not mention the injection of lipiodol either through the bronchoscope or by intratracheal instillation. We have noted marked benefit following its use, though in suspected tuberculous abscess, it is to be shunned. Otherwise the therapeutic measures described seem complete. The importance attributed to postural drainage is most gratifying; it is a measure of the greatest importance and one too often neglected. My limited employment of vaccines has given me no enthusiasm for that mode of treatment, but I shall make further trial of it because Doctor Pierson has found it helpful.

Those who suffer from any of these types of pulmonary affection need all of the help available in order to render life tolerable and such work as Doctor Pierson has given us is encouraging and will stimulate us to better efforts of study and more thorough trials of the various methods of treatment indicated in this splendid report.

CLINICAL NOTES, CASE REPORTS AND NEW INSTRUMENTS

THE RECONSTRUCTION OF A COMPLETELY DESTROYED AURICLE*

CASE REPORT

By HARRINGTON B. GRAHAM, M. D.
San Francisco

THE opportunity of reconstructing the auricle occurs so infrequently that the operator seldom has a chance to learn how to improve his technique from personal experience. He must look to the description of the operation by others and so far the errors one may fall into have been very casually dealt with. I am attempting to describe two cases, one of my own, and the other by Dr. George Pierce of San Francisco, quite differently done, both of which could have been improved on by experience.

TECHNIQUE

The important factors involved in the operation are:

1. The tissue used must be in appearance and consistency similar to the original ear.
2. The support must be sufficient to keep the new tissue erect and away from the skull.
3. The new ear should be as thin as it is possible to make it.

If the tissues behind the ear have been uninjured, they are available for the reconstruction and even the hairy parts may be used, as they may be folded back so as to bring the hair onto the posterior surface, where it may be easily kept short. If this tissue is not available, the whole ear must be reconstructed from the skin of the chest, abdomen, or arm, none of which has the appearance of the original ear and can in nowise be as satisfactory as the scalp tissue.

The support may be celluloid, in which case there is a grave chance that it may later on be extruded. Of course, its thinness and maleable quality is a great asset. Personally, I prefer cartilage and have found the nasal septal cartilage satisfactory. The assertion that this is absorbed more frequently than is rib cartilage, has not been found to be true in my nasal plastic work;

* Read before the Pacific Coast Ophthalmological Society, Spokane, Washington, June, 1927.