MUCOCELE OF THE FRONTAL SINUS CAUSED BY AN OSTEOMA

REPORT OF A CASE

By J. A. BACHER, M. D.

Report of a case.

Discussed by Harold A. Fletcher, San Francisco; Francis L. Rogers, Long Beach.

OSTEOMA of the frontal sinus is not rare; nor is mucocele of the frontal sinus. But osteoma as a cause of mucocele is. Howarth, in recording a case, has not been able to collect as many as twenty cases. I operated on such a case in 1921, and wish to record it on account of its rarity. My own case is as follows:

Male, 25. Salesman. Headache, six years.

P. H.—Impairment nasal breathing, years, relieved by swimming in salt water. Not frequent acute rhinitis. No excess post-nasal discharge. Not frequent sore throats. Never any discharge from or pain in ears. Six years ago, struck on left orbital region by baseball.

P. I.—*Left* frontal headache for about an hour daily for past six years, usually at midday, increasing in frequency and intensity. No relation to work or use of eyes. Often coincident with nasal obstruction, flushed face. Left eye becomes red during attacks.

P. E.—There were no external deformities or swellings to indicate the presence of a tumor. Nose: External deformity, nasal bones to right, tip to left. Septum markedly deflected to right, turbinates engorged, no pus seen, poor space. Septum irregular on left, no pus seen, good space. Throat: Tonsils moderate size, wide crypts, purulent debris in crypts. Nasopharynx: Clear. Ears: Both membranae tympani retracted, slightly fibrous. Washed both antra with trocar through inferior meatal wall, and fluid returned clear. X-ray of sinuses: "In the *right* frontal sinus, an opacity definitely interpreted as due to an osteoma."

Operation—Brow not shaved. Killian incision. Right frontal sinus entered externally, keeping away from site of osteoma. Upon penetration of outer table, greenish-blue thick membrane as of mucocele presented, filling sinus. Membrane incised and thick, yellow fluid evacuated. Culture made which showed "a scanty growth of streptococcus." Heavy lining of sinus removed, and tumor revealed, seeming to present on outer table at superior junction of inner and outer table. Bone of outer table removed up to attachment. Probe reveals that it is a sessile tumor with attachment superiorly, anteriorly, posteriorly, and internally, as if crowded up into the supero-internal angle of sinus. Very eburnated and regular in shape. Unable to pry it off. With chisel removed it from its attachment, which was most firm posteriorly. Removal revealed a depression of inner table caused by tumor, partly in right sinus and partly in left, as there was no septum between the sinuses. No dehiscence in this depression, but bone felt very thin. Probe passed freely through ostium frontale, into nose. *Frontal ostium* and *ethmoid cells not curetted.* Wound closed tightly with six silkworm sutures. No drain. Benzoin dressing. Convalescence: On account of swelling at outer angle of incision, it was opened and small drain used for four days. Closed. Absolutely free from headaches for over three years now since operation.

Microscopical Examination by Dr. F. E. Blaisdell—"Osseous tissue, in which the trabeculae are very irregular, most widely separated in the central area, becoming thicker and more compact peripherally beneath the periosteum, here the marrow spaces are reduced more or less to a minimum size. There is no distinct cortical layer, other than that formed by the compact and very irregular trabeculae, which even here exhibit variation in thickness, for in places the wider marrow spaces attain the surface beneath the periosteum. No true cortex (compacta) is recognizable. The surface is invested by a thin fibrous periosteum. The marrow spaces are filled by a fibrous marrow. At one point of the surface the osseous tissue projects, and here shows a distinct lamellated structure. This is evidently the remains of the pedicle by which the growth was attached to the wall of the sinus.

Microscopical Details — The trabeculae stain irregularly, part of them take the eosin and are apparently osteoid in character; elsewhere the hematoxylin staining predominates and varies in intensity, delimiting irregular and more strongly calcified areas. Lacunae are everywhere present and empty, except in and about the pedicle, where each contains a bone cell and lamellization is distinct and quite normal. Careful examination under high, dry magnification shows the presence of an imperfect canalicular system. Trabecular lamellae are entirely indistinct, imperfectly and vaguely indicated, or distinct; the latter observed chiefly in the osteoid or eosin-staining trabeculae. In the superficial and condensed area an occasional Haversian canal seems to be present, surrounded by the concentrically arranged lamellae with intervening lacunae. Bone cells are only observed in the lacunae of the pedicle. There is distinct evidence of destructive and constructive changes having taken place during the growth of the tumor, for in places the deeply stained calcified trabeculae end abruptly against very irregular edges of the osteoid areas. The irregular edges of the osteoid tissue indicate the past activity of osteoclasts.

In the series of sections studied the marrow is fibrous throughout. Differential staining shows the presence of collaginous fibrils and bundles. Marrow cells are entirely absent, unless a few scattered and poorly stained cells

Figure I. Two days after operation

Figurt 11. Six months after operation

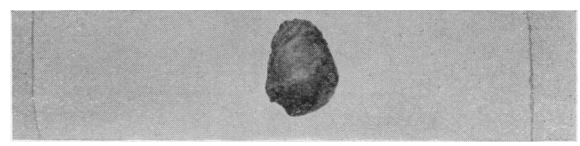

Figure III. Osteoma, natural size

Figure IV. Photomicrograph. Zeiss: Oc. 4; obj. 1 inch (B. & L.)

be such. Osteoblasts and osteoclasts are absent. Blood-vessels have not been recognized. Diagnosis: Osteoma (osteoma spongiosum)."

DISCUSSION

HAROLD A. FLETCHER, M. D. (Butler Building, San Francisco)—Either mucocele or osteoma of the sinuses is always interesting. Those of the frontal and ethmoid sinuses, because of their complicating features, are most interesting, while mucocele of the frontal sinus, with osteoma as the etiological factor in its production, is most interesting and most rare. It is even more rare than the author has quoted, as my interpretation of Howarth's series is, that, of his twenty cases of mucocele, only one had osteoma as the etiological cause.

Osteoma of the anterior ethmoids or of the region of the floor or duct of the frontal sinus would, in its very nature, by its slow but steady increase in size and pressure, most surely cause absorption of the frail bony partitions here, and soon occlude the frontal duct and cause a mucocele.

Clinically the differential diagnosis between osteoma and mucocele is difficult, except by the careful study with the x-ray. The x-ray, of course, clinches the diagnosis. Where both are present, as in this case, the diagnosis would be osteoma, from the x-ray findings. Mucocele apparently was not diagnosed until operation.

It is a pleasure to have a careful and complete pathological report with such a case as this. Too often the diagnosis of osteoma or some such tumor is made at operation from the gross specimen, and no study made of the pathology. A review of the literature would reveal many such cases, and only a very occasional study of the microscopical picture, with a view ever present of determining the cause of this new growth, as well as other types. Eckert mentions this in his study of osteoma of the nasal fossa. His pathological reports agree with the pathological report of Dr. Bacher's case.

FRANCIS L. ROGERS, M. D. (Markwell Building, Long Beach, Calif.)—Such contributions as this from Doctor Bacher are, I believe, valuable because both osteoma and mucocele of the sinuses are undoubtedly less rare than our past and present literature would lead us to believe.

Whether the tumor is a mucous polypus, a retention cyst, or bony growth in the frontal sinuses, there is the symptom of more or less constant pain, headache. The numerous cases of frontal headache met with which do not yield to refractive corrections or general treatment and give no adequate nasal symptoms should suggest to us all to routinely secure x-ray and other modern diagnostic measures in our search for intrasinus tumors. In mucocele of the polypoid type it is my impression the fluid contents are usually sterile, unless the tumor sac has been ruptured, while the retention cyst type are apt to contain infective organisms of the staphylococcic or streptococcic types with some previous drainage to the nose or elsewhere. Early recognition of these conditions is quite important because of the fact that pressure from the mucocele may cause extensive absorption of its adjacent normal bony structures.

A case in point was recently seen by me here in a woman, age 56, whose primary complaint was a badly swollen left eye. There was no history of injury, but extensive ecchymosis of eyelids and marked exophthalmos, and a very profuse muco-purulent discharge. The discharge was found to contain both strep and staphylococci, but no gonococci, as was first suspected. A deep central corneal ulcer was present, and perforation to the anterior chamber and infection had already taken place, rendering the eye hopelessly lost. A distinct fluctuating tumor in the ethmoid region of the orbit was readily made out, which, on pressure, provoked added discharge of a heavy, pale yellow muco-purulent character from under the upper eyelid. The throat and nasal passages appeared free from disease or bony deformity, and there was no history obtainable of rhinitis or other disease from patient or relatives. She was removed to the hospital, where x-ray plates were taken, indicating a complete filling of the left frontal sinus with a fluid deposit. The eye was enucleated and a digital examination of the orbit revealed the fact that almost the entire fronto-orbital wall had been dissected out, not by necrosis, but evidently by the absorption, due to intra-frontal pressure from a soft fluctuating tumor. A later operation confirmed the fact that the frontal sinus was filled with a large mucocele. The mental state of this patient was that of a moderately advanced case of senile dementia, which was suspected might be due to pressure from extension of the mucocele into the cranial cavity. But this was not confirmed at the frontal sinus operation, and the report from the laboratory of a 4 plus Wassermann indicated that the mucocele had probably little or nothing to do with the mental condition. This patient made a slow but uneventful recovery, and is able to wear an artificial eye. Under suitable medication her mental condition has also improved somewhat.

DOCTOR BACHER (closing)—As to the frequency of such cases, Howarth's words are: "Osteoma, however, as a cause of mucocele is rather rare. Cases have been described by Luc, Laurens, Axenfeld, and others, but I have not been able to collect as many as twenty."

BLOOD TRANSFUSION

By GEORGE H. JUILLY, M. D., *San Francisco*
(From the French Hospital)

Long before Harvey's discovery of the circulation of blood, physicians had tried to rejuvenate old men by introducing into their veins the blood of young and vigorous individuals.

Blood transfusion is especially effective in patients who have become acutely anemic, as the result of a large and sudden loss of blood—hemorrhage from childbirth, gastric ulcer, intestinal, kidney and bladder hemorrhage, epistaxis, internal hemorrhage.

The only blood which needs to be considered is human blood, properly typed and carefully examined.

There is no question that the whole blood transfusion is superior to the citrated blood method.

DISCUSSION *by R. F. Grant, Alson R. Kilgore, A. N. Fregeau, W. J. Hawkins, E. S. Kilgore, J. K. Plincz, H. Marcus, San Francisco.*

BLOOD, as a therapeutic agent, has been used from the remotest antiquity. Men have not been slow to discover that when a wounded man lost too much blood he would die. Consequently, they reasoned out that blood was not only necessary to life, but that life itself—or the soul—was more or less concentrated in that blood. This fact explains why in all mythologies—those of the North especially—the drinking of blood was considered beneficial, just as eating the heart of ferocious animals and of man at times was thought to impart the strength and the courage of the animal from which it had been removed. This is still a common belief among the savages of Central Africa and the Bushmen of Central Australia.

But as the embalming of the dead in Egypt and the killing of various animals on the altars of Gaul, Greece and Rome had given men a certain understanding of anatomy and physiology, they began to search for a means of transfusing pure blood into the veins of the patient, rather than making him drink it, which showed no apparent benefit.

Of course, they found no way of accomplishing this, until Harvey discovered the circulation of the blood in the middle of the seventeenth century.

Yet, the actual drinking of blood for the cure of disease has not died down; and I remember very well when anemic patients and the consumptive were directed to the slaughterhouse for the purpose of drinking fresh, warm blood.

But formerly blood was thought of not only as