Hiatus Hernia: Coincident Hematemesis

A. LINCOLN BROWN, M. D., and
SANFORD E. LEEDS, M. D., *San Francisco*

HIATUS hernia has been cited as a cause of hematemesis or anemia. The frequency of hiatus hernia and coincident anemia or hemorrhage is sufficiently striking to make this problem one of practical interest. We agree with Shaler and Hampton[5] that unless gastritis or ulceration is present, hiatus hernia per se will not cause bleeding.

It is also true that when a hiatus hernia has been demonstrated to be present, the coincidental presence of other lesions in the gastrointestinal or cardiorespiratory systems must not be overlooked. Ulceration and incarceration of the herniated portion of the stomach may be demonstrated by barium studies. If no ulceration is demonstrated, other sources of the bleeding should be considered. Usually, marked constriction and fixation of the stomach at the hiatus ring is necessary to produce ulceration, and this condition may be demonstrated by roentgenologic methods.

The symptom of hematemesis associated with a hiatus hernia occurred in slightly more than 25 per cent of a group of Harrington's patients. In seven of eight cases in which bleeding occurred there were positive findings, upon operation, of ulceration of the herniated stomach. He states: "Hemorrhage . . . . usually is indicative of severe incarceration with fixation of the stomach in the thorax. The bleeding is caused by erosion of the mucous membrane due to the forceful pressure exerted during the attacks of vomiting on the large, distorted, congested and fixed stomach. This erosion may be superficial, or, in cases of long standing, may form a definite ulceration from repeated trauma."

Sahler and Hampton[4] reviewed 221 cases of hiatus hernia, in 32 of which the patients had either moderately marked anemia or a positive history of gastrointestinal-tract bleeding. They conclude: "Bleeding caused by hiatus hernia is probably due to constriction of the hernial ring with resultant gastritis and ulceration of the herniated fundus. *If neither gastritis nor ulceration is present, the lesion will not cause bleeding.*"

The association of anemia and chronic bleeding with a coincident diaphragmatic hernia has been commented upon by others[1,2,4,6,7] and is not unusual. We believe the anemia to have been formerly too often attributed erroneously to the hernia per se. When hematemesis occurs in the presence of hiatus hernia other causes of bleeding from the gastrointestinal tract, which must be considered, include esophageal varices, polyps, other benign and malignant tumors of the stomach with ulceration and peptic ulceration of the stomach or duodenum.

A case report illustrating the necessity for a search for another cause of hematemesis than the hiatus hernia per se, is presented.

The patient was an elderly white female 67 years of age who had an episode of hematemesis in 1942 without preceding symptoms. At that time, the hemoglobin dropped to 6.5 gm., and the erythrocyte count to 2.71 million. A roentgenologic examination revealed a diaphragmatic hernia of the hiatus type. At this time the hematemesis was attributed directly to the hiatus hernia.

The patient was then well until June 26, 1946, when she had a tarry stool associated with nausea and weakness. She felt ill and had periods of faintness until July 2, 1946, when she was admitted to the hospital because she fainted after vomiting dark brown material and some bright red blood.

The past history was not suggestive of peptic ulcer although the patient had occasionally been nauseated and had vomited during the preceding five years. She had been anemic and had "fainting" spells, the exact nature of which was not known. The stool was positive for occult blood on several occasions during the preceding four years. The normal hemoglobin level was well maintained on a convalescent diet including ferrous sulfate and vitamins. The patient had been on a reducing diet containing a moderate amount of raw vegetables for three months prior to the acute hemorrhage.

Physical Examination. Physical examination revealed a moderately obese woman of 67 who was pale and weak from recent loss of blood. The blood pressure on entry was 105 mm. systolic and 70 mm. diastolic, the pulse rate was 94, and the temperature 37.2° C. The heart was not enlarged, there were no murmurs, and the rhythm was regular. The previous day she had visited her doctor, who had found the rhythm was very irregular and suggestive of fibrillation. The abdomen was moderately obese and soft. There were no scars or masses palpable and no tenderness elicited.

Laboratory Data. The erythrocyte count on entry was 1.9 million and the hemoglobin 4.2 gm. (25 per cent). The leukocyte count was 12,000 with 83 per cent polymorphonuclears. The color index was 0.66. The urine was normal and results of Wasserman and Kahn tests were negative. A non-protein nitrogen determination was normal. An electrocardiogram tracing was normal.

Treatment and Course. Six transfusions of whole blood, Rh negative, were given in the next five days. The blood pressure had fallen to 92 mm. systolic, 60 mm. diastolic on July 3, remained in the neighborhood of 100 for several days and rose to 130/82 on July 7. The hemoglobin gradually rose to 10.5 gm. (62.5 per cent) and the erythrocyte count to 3.32 million on July 6. The pulse remained about 90, and the respirations 20. An electrocardiogram on July 2 was reported as showing evidence of myocardial damage of non-specific pattern.

On July 7, the patient was transferred to the hospital for operation. Her general condition was good. The blood pressure was 140 mm. systolic, 80 mm. diastolic, erythrocyte count was 3.5 million with hemoglobin 11 gm. (72 per cent). The total protein was 6.7 gm. per cent with albumin 4.9 gm. per cent and globulin 1.6 gm. per cent. It was considered that the condition of the patient did not warrant repeating the roentgenographic examination of the stomach.

Operation. On July 10, 1946, a transthoracic operation was performed on the left. Posterior to the heart and anterior to the aorta there was a large hernia consisting of the upper portion of the stomach, measuring 10x7 cm. The esophagus extended to within 3 cm. of the hiatus in the diaphragm. The hernia ring was large and did not constrict the stomach. There were no ulcerations, constriction or varices and no cause for the hematemesis was found, so it was decided to explore beneath the diaphragm. There was a true hernia sac over the herniated stomach. This was demonstrated when the diaphragm was opened and the stomach delivered into the chest cavity. On the lesser curvature of the stomach, approximately half way between the cardia and the pylorus, there was an intrinsic tumor mass, 3.5 cm. in diameter. This was round, firm, slightly nodular and freely movable. There was no enlargement of the neighboring lymph nodes and the tumor had the appearance of a benign leiomyoma of the stomach. (See Figure.)

A wedge resection of the stomach was carried out and the stomach closed at right angles to the long axis. The diaphragm was repaired and the hernia sac overlapped to obliterate the space formerly occupied by the hernia. The duration of the operation was two hours and thirty-three minutes.

Postoperative Course. The postoperative course was smooth. The temperature was 37° to 38° C. for eight days, after which the patient was afebrile. Thoracentesis was performed almost daily until July 18, the amount of fluid, thin and pink, obtained varied from 20 to 450 cc. After July 20 no fluid was obtainable. One transfusion was given during the operation,

From the Surgical Service, Thoracic Surgery Section, Mount Zion Hospital, San Francisco.

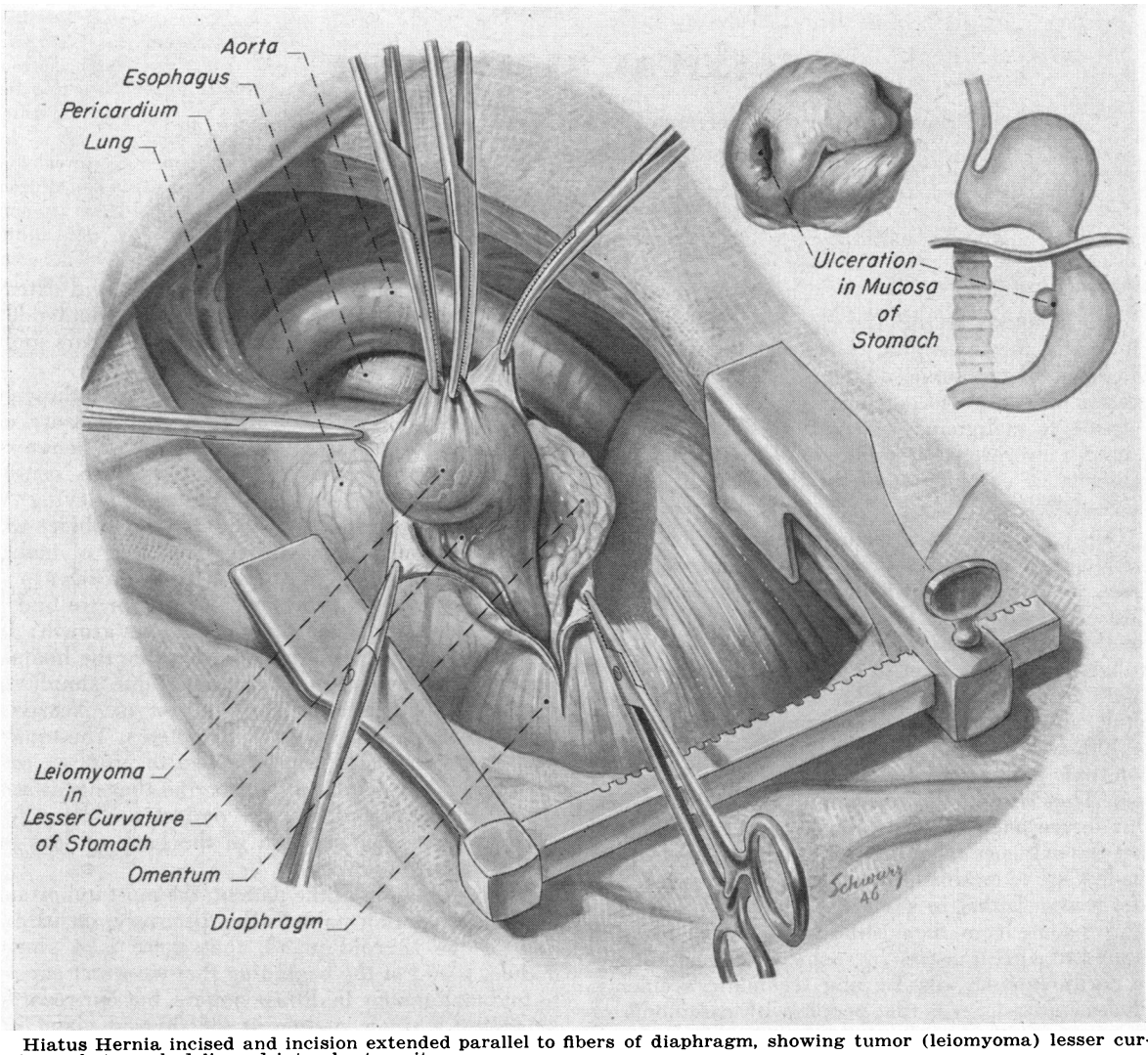

Hiatus Hernia incised and incision extended parallel to fibers of diaphragm, showing tumor (leiomyoma) lesser curvature of stomach delivered into chest cavity.

and 1,000 cc. of blood was given after the operation. An additional 500 cc. of blood was given on the 12th postoperative day. The wound healed per primum except for a small portion which contained a hematoma, and this was opened. This portion healed secondarily without difficulty. The patient was discharged from the hospital July 30, 1946, three weeks after operation.

SUMMARY AND CONCLUSIONS

1. Hiatus hernia is not a primary cause of hematemesis but only secondarily causes bleeding when incarceration of the stomach results in (a) gastritis (b) erosion and ulceration of the gastric mucosa (c) congestion and production of local varices. This latter is a possibility which is open to question.

2. Hiatus hernia, uncomplicated, rarely if ever causes hematemesis or anemia.

3. The presence of an hiatus hernia should not lead one astray in making a diagnosis when the presenting symptom is gastrointestinal hemorrhage.

4. If neither the preoperative studies nor the findings at operation reveal the cause of the bleeding, further search above and particularly below the diaphragm is strongly indicated before one could be satisfied that the hiatus hernia per se is the cause of the hematemesis or anemia.

5. A case of gastrointestinal bleeding due to an ulcerated leiomyoma of the stomach in a patient with a coincident hematemesis is reported.

REFERENCES

1. Bock, A. V., Dulin, S. W., and Brooke, P. A.: Diaphragmatic hernia and secondary anemia; ten cases, New England Journal of Medicine, 209:615 (Sept. 28), 1933.

2. Gardner, K. D.: Diaphragmatic hernia associated with secondary anemia, American Journal of Medical Science, 185:561 (April), 1933.

3. Harrington, S. W.: Diaphragmatic hernia associated with traumatic gastric erosion and ulcer, Collected Papers, Mayo Clinic, 21:790, 1929.

4. Moller, Folke: Zwerchfellhernie und Magenkarzinom. Zugleich einige Betrachtungen uber Blutungen und Anamien bei Zwerchfellhernien, Acta Med. Scandinav., 74:421, 1931.

5. Sahler, O. D., and Hampton, A. O.: Bleeding in hiatus hernia, American Journal of Roentgenology, 49:433 (April), 1943.

6. Segal, H. L.: Secondary anemia associated with diaphragmatic hernia, New York State Journal of Medicine, 31:692 (June 1), 1931.

7. Weitzen, Max: Diaphragmatic hernia with severe anemia, American Journal of Roentgenology, 28:808 (Dec.), 1932.