Environmental Health Perspectives
Vol. 23, pp. 247–255, 1978

PBB Fed to Immature Chickens: Its Effect on Organ Weights and Function and on the Cardiovascular System

by Robert K. Ringer*

In a series of polybrominated biphenyl (PBB) feeding trials in White Leghorn cockerel chicks, the effects of PBB on various physiological parameters and organ weights were determined. These measurements included: growth, thyroid function, ECG, cardiac output, blood pressure, hematocrit, erythropoietin levels, and spleen, bursa of Fabricius, thyroid, testes, comb, liver weights. In addition, tissues were histologically examined. PBB, in the commercial grade form of hexabromobiphenyl, was administered continuously in the diet at levels ranging from 50 to 250 ppm. Pair-feeding studies were conducted to ascertain the effects of the drug *per se* since preliminary trials indicated that PBB administration resulted in decreased feed intake.

Chronic administration resulted in depressed body weight as a result of decreased feed intake; decreased comb, testes, spleen, and bursa weights; increased liver and thyroid weight; hydropericardium and ascites; decreased hematological values due to depressed plasma erythropoietin levels; decreased heart rate, packed cell volume, hemoglobin and cardiac output; decreased voltage amplitude of the ECG and a shift in the mean electrical axis. No significant differences were found in blood pressure (mean arterial and pulse pressure), stroke volume, or respiratory rate.

Introduction

The toxicological significance of exposure to polybrominated biphenyl (PBB) and its biological effects has generated widespread concern. The vast majority of scientific investigations on the commercial forms of brominated biphenyls has dealt with the toxicological effects in mammalian species. As a result of an accidental contamination of feed (*1*), emphasis was placed on dairy cattle and the ultimate implications for human health and safety. In a previous paper (*2*) the biological effects of PBB in several avian species were reported and compared to those of polychlorinated biphenyl, a compound similar in structure and one that shares both chemical and biological properties. The objective of this paper is to summarize various studies from this laboratory conducted on growing chickens exposed to continuous dietary levels of PBB for variable periods of time.

Continuous dietary levels of commercial grade PBB (FireMaster FF-1 manufactured by Michigan Chemical Corporation, St. Louis, Michigan; hexabromobiphenyl-62.8%, heptabromobiphenyl-13.8%, pentabromobiphenyl-10.6%, tetrabromobiphenyl-2.0%, other bromobiphenyls-11.4%) were employed for two reasons: (a) the chemical was identical with that involved in the accidental contamination by indirect means of poultry feeds and (b) the single dose toxicity in poultry is of moderately low order. Repeated exposure over short-term periods (4 to 8 weeks) more nearly duplicated what occurred in commercial poultry operations and demonstrated the cumulative toxic effect at levels considerably below the acute toxic level.

Effect on Body Weight

Polybrominated biphenyls are excreted in feces and in lipid-containing products; thus, adult male birds excrete less than females producing eggs (*2*, *3*), and in some species the male tends to be more susceptible to toxicological effects. In the following studies only male, cockerel chickens were used.

That PBB causes inanition and thus loss of body weight (Fig. 1) has been previously reported (*2*). In that review it was shown by data from our laboratory that the liver was enlarged, as was the thyroid.

* Michigan State University, East Lansing, Michigan 48824.

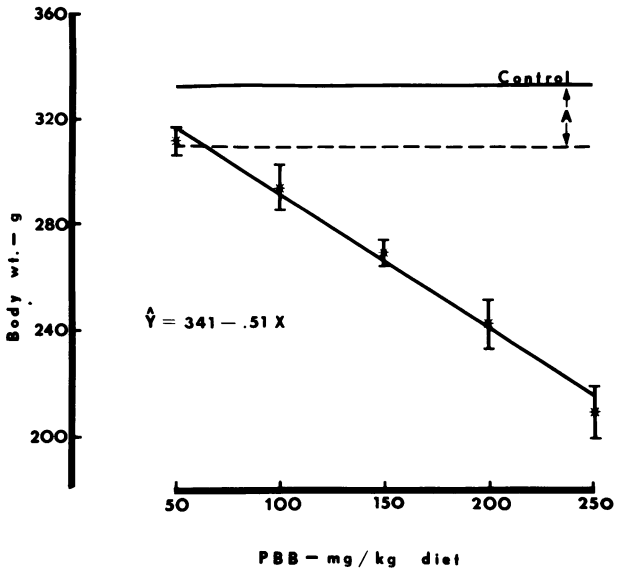

FIGURE 1. Body weight of 4-week-old White Leghorn cockerels fed PBB continuously in the diet at various levels from one day of age (*7*).

Induction of liver microsomal enzymes by PBB has been reported by several researchers. This induction of hepatic microsomal enzymes and the increased catabolism of endogenous hormones by the enzymes apparently accounts for the decrease in the comb size (*2*).

Effect on Cardiovascular System

In another study, 3-day-old White Leghorn chicks were divided into five groups and fed 0 ppm PBB (control), 75 ppm PBB, 150 ppm PBB, pair-fed to 75 ppm (control feed), and pair-fed to 150 ppm (control feed). At 9 weeks of age, packed cell volume, hemoglobin concentration (cyanmethemoglobin method), blood pressure (direct cannulation of carotid artery), cardiac output (dye dilution technique), and electrocardiogram (Grass model 5A polygraph) were determined. In addition, at autopsy a measurement of pericardial fluid was made to access the degree of hydropericardium and correlate this condition with cardiac alterations.

PBB significantly decreased packed cell volume and hemoglobin concentration at both dietary treatment levels. The action of this brominated hydrocarbon is apparently one of decreased erythropoietin production by the kidney and a direct action on the bone marrow (*4*). Bradycardia was observed at 150 ppm PBB administration, but mean arterial pressure was not influenced by PBB beyond that which occurred in the pair-fed controls (*5, 6*). Cardiac output decreased as a result of these dietary treatments with PBB, yet stroke volume remained unaltered. In general, electrocardiograms indicated decreased ventricular depolarization (R-S) voltage in PBB-fed birds, even beyond that of the pair-fed controls (Fig. 2) and also exhibited a shift in the mean electrical axis in a positive direction (*5*). These electrocardiogram changes were correlated with increased pericardial fluid volume. At autopsy the hearts appeared flaccid, distended (*7*) and upon histological examination, edematous.

A possible explanation of the anemic condition reported could be that the liver enhanced microsomal enzyme metabolism of circulating androgens. An altered androgen level was exemplified by decreased comb size. The depressed concentration of androgen in the blood may have influenced erythropoiesis since testosterone injection into castrated males markedly increases red blood cell formation in chickens (*8*).

Bradycardia has been reported for several species following chlorinated hydrocarbon exposure (*9–12*). The mode of action may be attributed to increased vagal tone but remains to be answered. The decreased R-S complex voltage observed was appar-

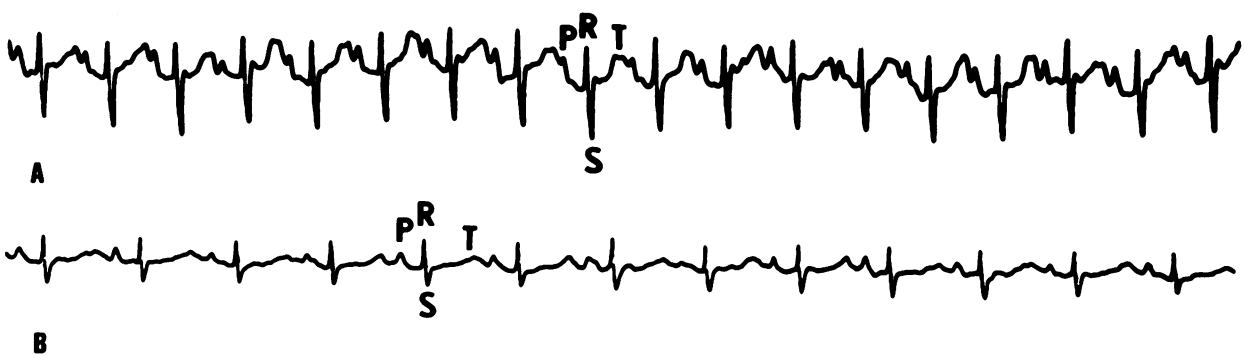

FIGURE 2. Typical electrocardiograms (lead II) of 9-week-old White Leghorn cockerels (B) fed 150 ppm PBB or (A) pair-fed the identical amount of feed without PBB. Chart speed = 50 mm/sec; 1 mV = 2.5 cm. Note typical bradycardia and decreased amplitude of RS complex (*5*).

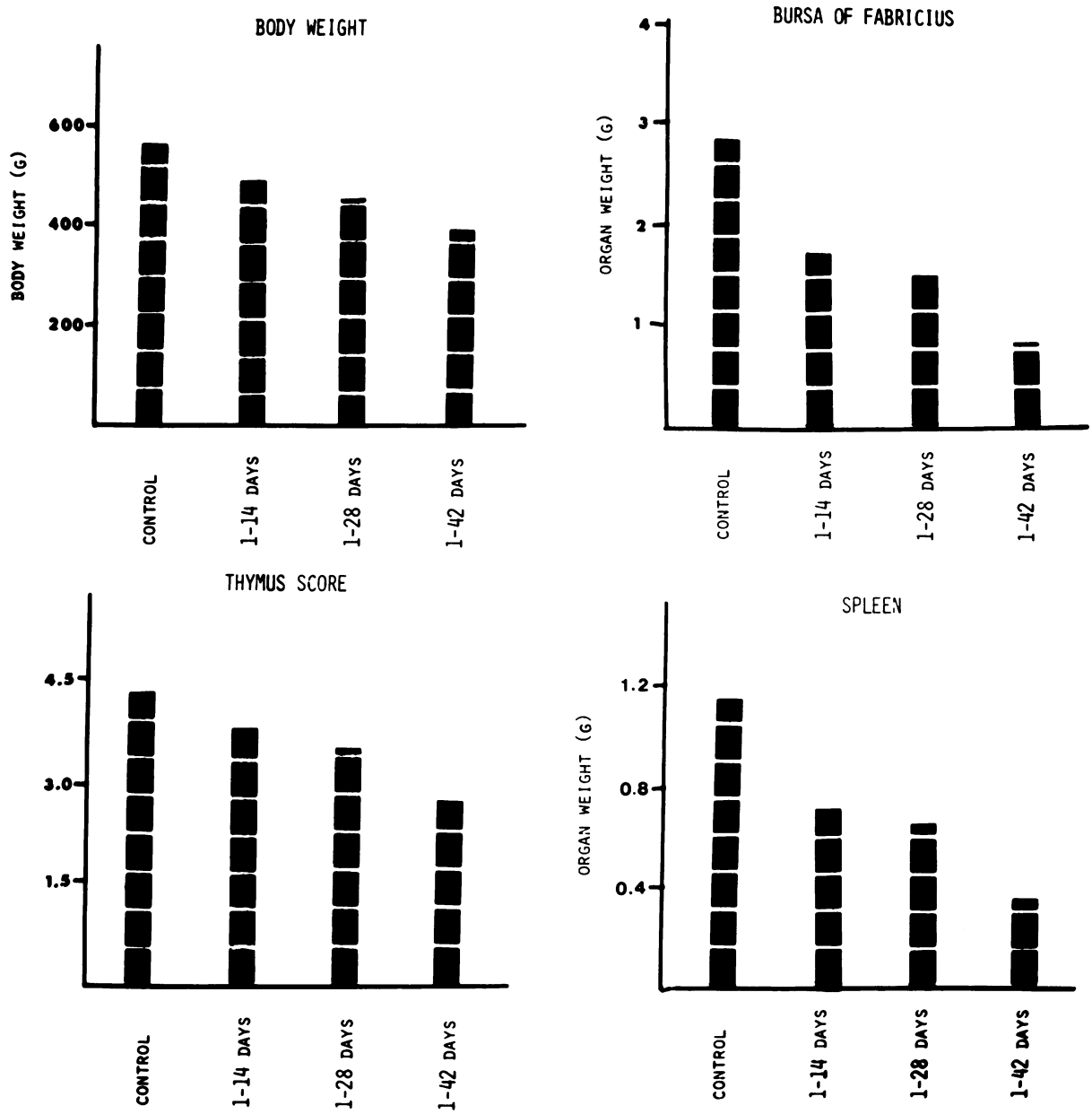

FIGURE 3. Effect of feeding PBB to White Leghorn cockerels during the first 14, 28, or 42 days of age. Following drug withdrawal the chicks were fed "clean" feed. Weights given are absolute weights. Thymus, because of its diffuse nature, was scored from 1 to 5 (5 indicating the greatest amount of tissue). All chicks killed at 42 days of age.

ently the result of hydropericardium since a similar finding was observed by Iturri and Ringer (*13*) in PCB-fed cockerels and like these results were correlated with pericardial fluid volume.

Effect on Lymphatic System

In the chick the bursa of Fabricius has been shown to be responsible for immunoglobulin formation (humoral immunity) and the production of B cells. The cell-mediated immunity is credited to the thymus. The spleen is influenced by both the bursa of Fabricius and thymus tissue. The number and size of splenic "germinal centers" are bursa-dependent. Diffuse splenic lymphoid tissue is thymus-dependent.

To study the influence of PBB on the immunological system, day-old chicks were randomly

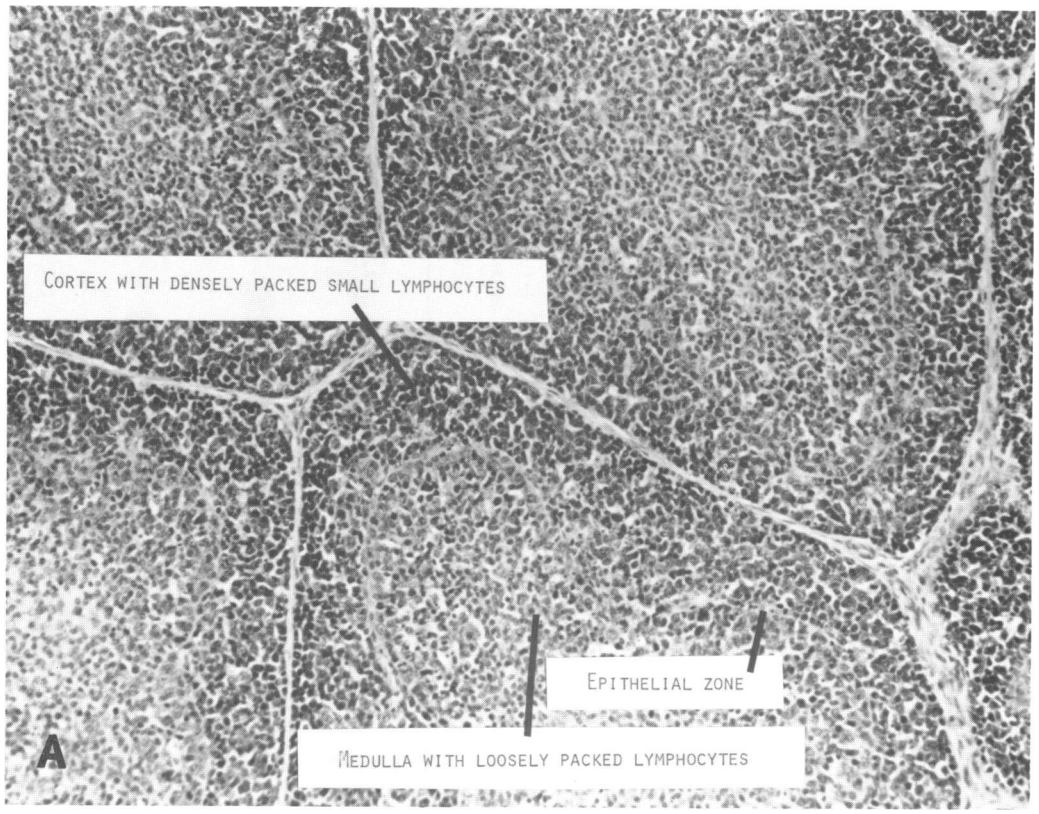
CORTEX WITH DENSELY PACKED SMALL LYMPHOCYTES
EPITHELIAL ZONE
MEDULLA WITH LOOSELY PACKED LYMPHOCYTES
A

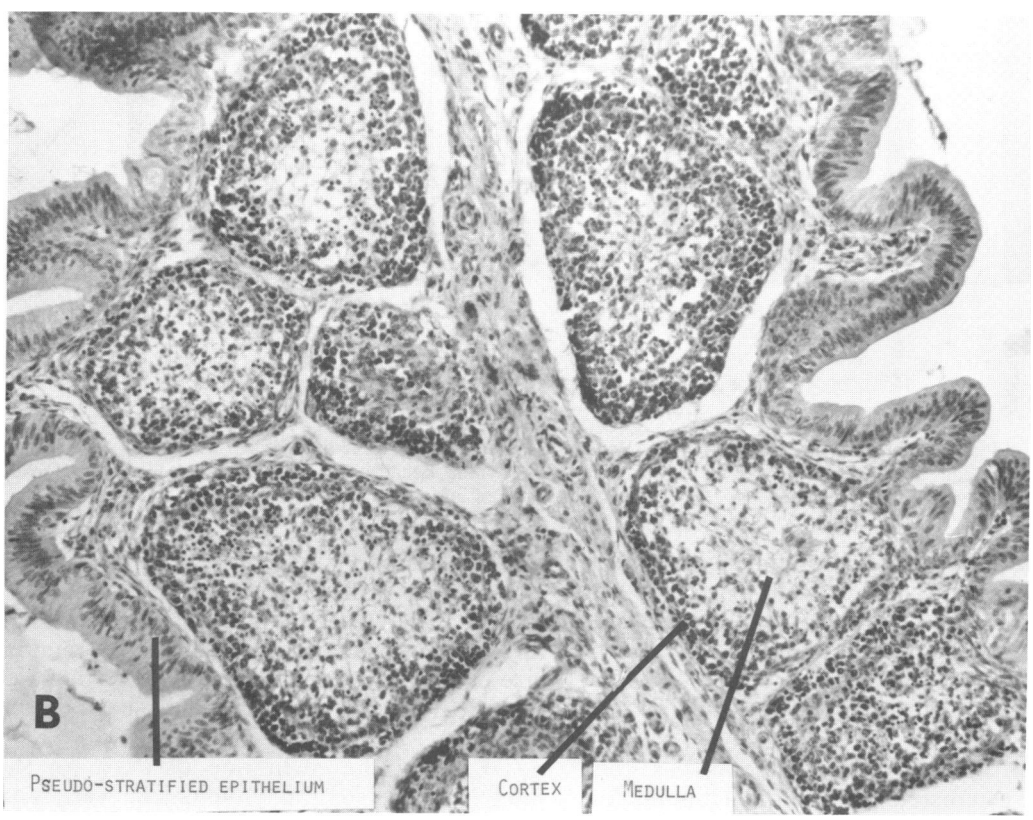
B
PSEUDO-STRATIFIED EPITHELIUM
CORTEX
MEDULLA

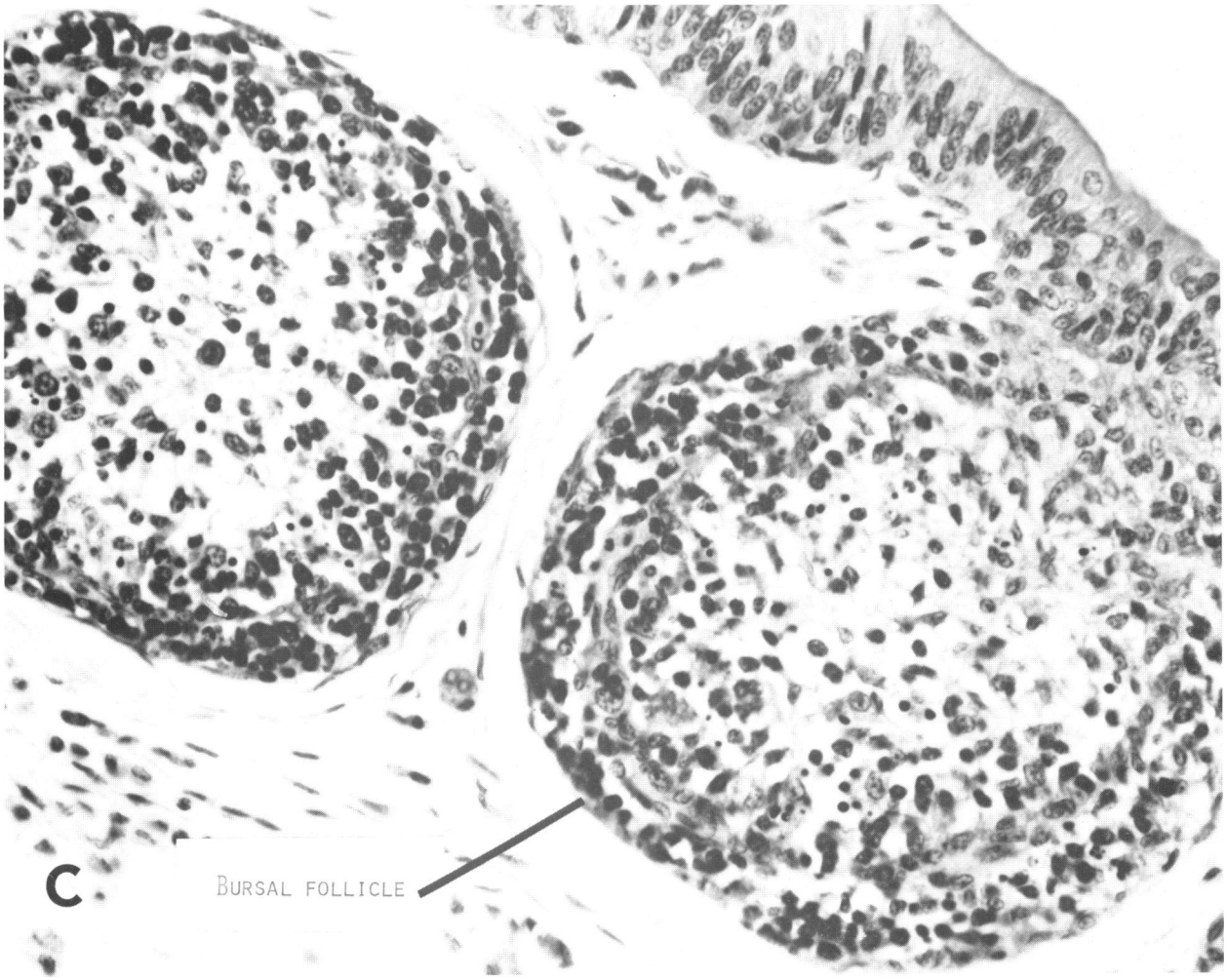

FIGURE 4. Photomicrographs of the bursa of Fabricius of 6-week-old White Leghorn cockerels: (*A*) normal; (*B*) after PBB feeding at 150 ppm, for 6 weeks (27 ×); (C) bursa of Fabricius follicles after PBB feeding (68 ×). Note the reduction in bursa follicular size with loss of lymphocytes from cortex and almost complete absence of lymphocytes in the medulla indicating premature regression initiated by PBB feeding.

distributed into four groups. Three groups were exposed to PBB for varying periods i.e., 1 to 14 days, 1 to 28 days, and 1 to 42 days. Following the exposure period, the chicks were placed on control diet until being killed at 42 days of age. A fourth group was given the control diet.

The results are graphically shown in Figure 3. Body weight was depressed as was the weights of the bursa of Fabricius and spleen. Thymus tissue, being difficult to remove and weigh, was scored from 1 to 5, with 5 connotating the largest mass. The score indicates that thymus tissue also decreased. When the organ weights were calculated relative to body weight (Table 1), the data indicate that 150 ppm of PBB depresses the organ weight and, that despite the removal of PBB from the diet, recovery of organ weight does not approach that of the normal weight.

Histologically (Fig. 4) the bursa showed marked depletion of lymphocytes from the normal density packed cortex and almost complete depletion of lymphocytes from the medulla. Withdrawal of PBB at various ages improved this picture but did not approach that of the normal control. It was evident that PBB caused premature regression of the bursa. The thymus (Fig. 5) also exhibited premature regression evidenced by almost complete loss of the cortex and depletion of lymphocytes from the remaining medullary tissue. Again, removal of PBB caused less regression but histologically the tissues were not normal. The spleen of chicks continuously fed PBB (Fig. 6) showed almost complete loss of "germinal centers" and reduction in the diffuse lymphoid tissue (white pulp). In one chick, only red pulp tissue was observed, all white pulp having been depleted.

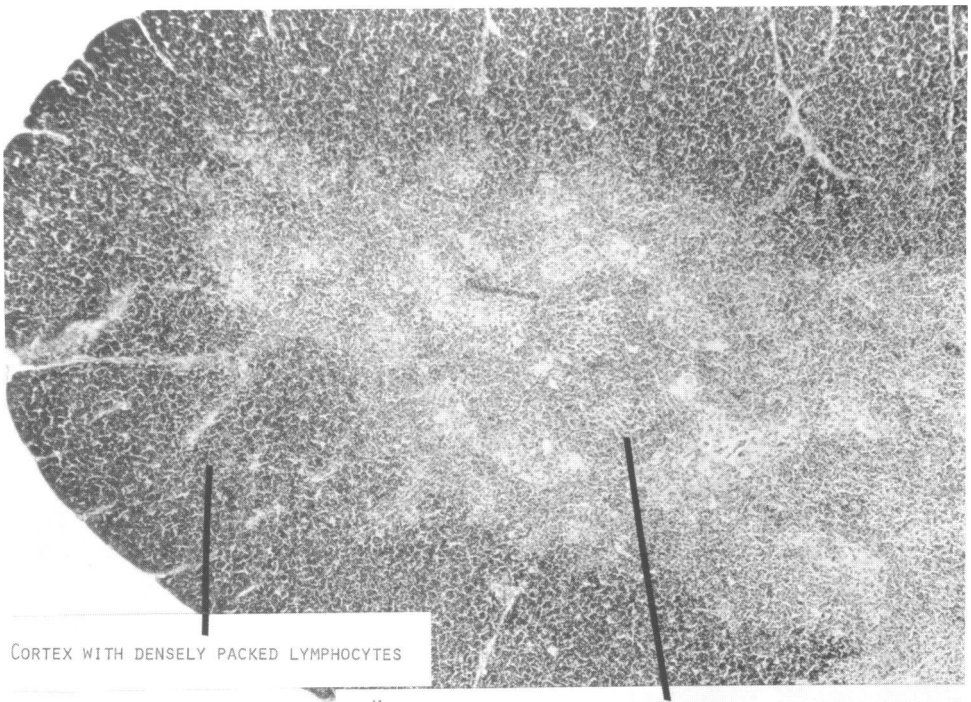
CORTEX WITH DENSELY PACKED LYMPHOCYTES
MEDULLA WITH LOOSELY ARRANGED LYMPHOCYTES, AND ISLANDS OF EPITHELIAL CELLS (HASSALL'S CORPUSCLES)

A

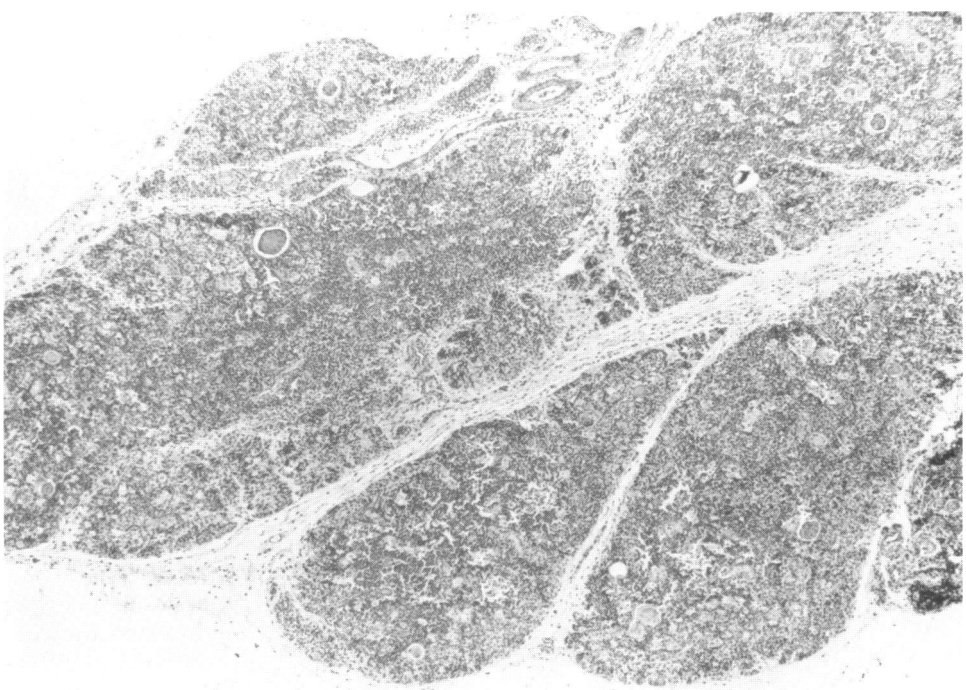

B

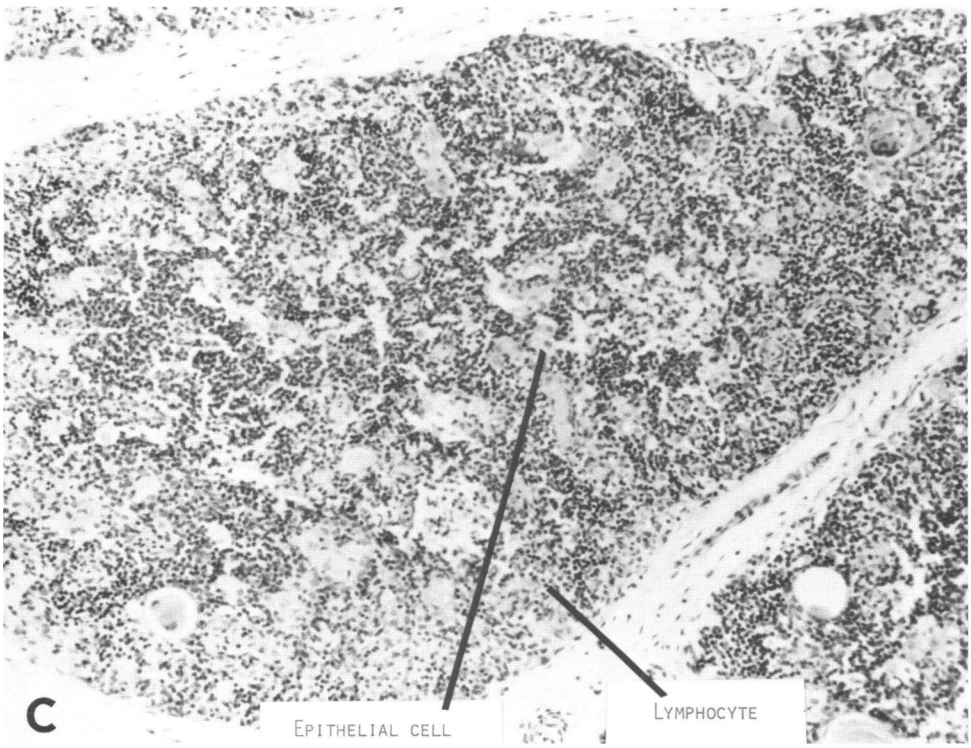

FIGURE 5. Photomicrographs of the thymus of 6-week-old White Leghorn cockerels: (*A*) normal; (*B*) after feeding 150 ppm PBB for 6 weeks (40×); (*C*) after PBB (100×). Note, after PBB feeding, the loss of the cortex with its densely packed small lymphocytes leaving only medullary-type tissue with few lymphocytes indicating premature regression.

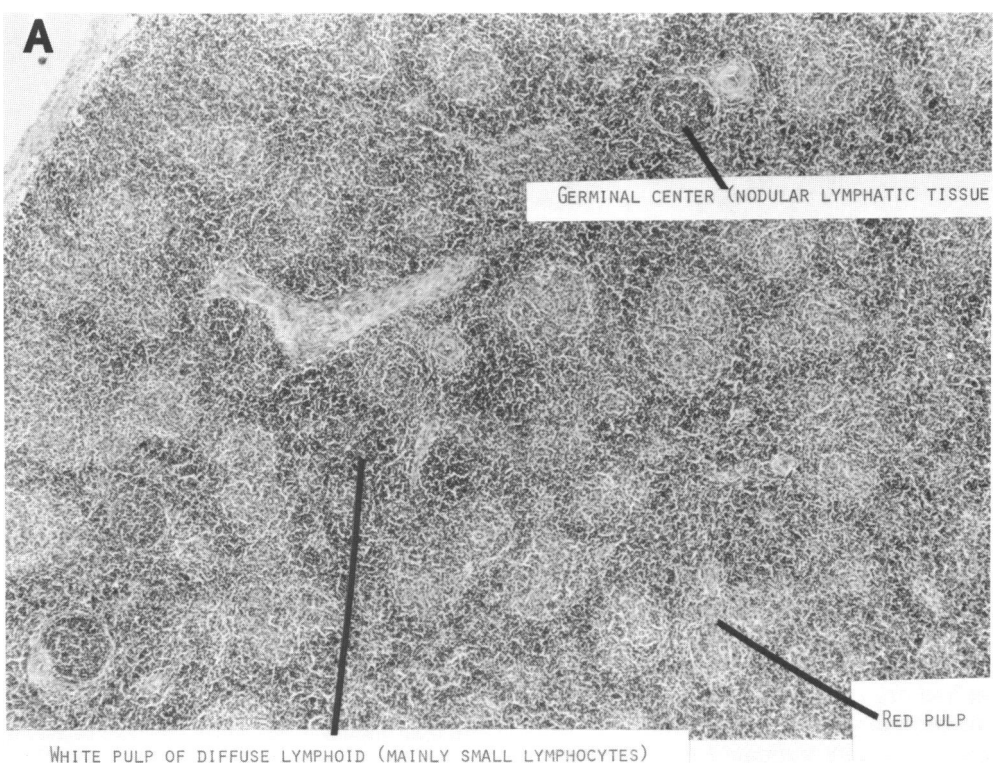

FIGURE 6A. See page 254.

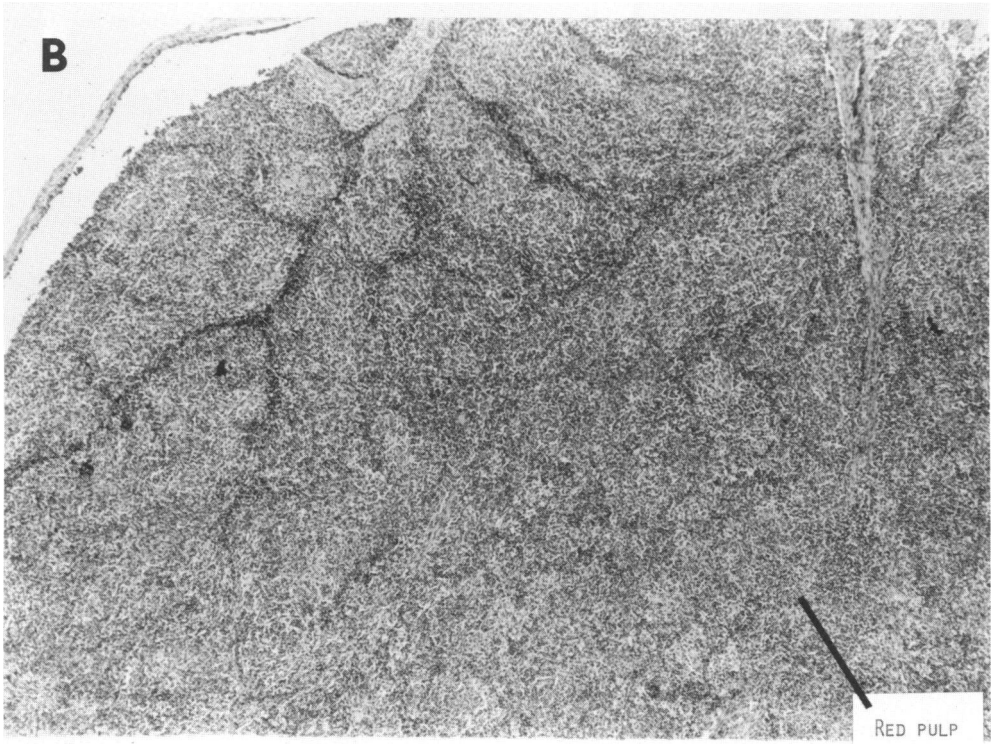

FIGURE 6. Photomicrographs of the spleen of 6-week-old White Leghorn cockerels: (*A*) normal; (*B*) after feeding 150 ppm PBB for 6 weeks (40×). Note loss of white pulp and germinal centers following PBB feeding. The term "germinal center" is used as defined by Payne (*15*). Lucas et al. (*16*) consider no germinal centers in the lymphoid area of normal chickens and suggest these areas represent blood vessels occluded by lymphocytes.

Table 1. Effect of feeding 150 ppm polybrominated biphenyl on body, spleen, bursa of Fabricius, and thymus score of 42-day-old chicks.

		Organ weight, g/100 g body weight	
Age PBB fed	Body weight, g	Spleen	Bursa of Fabricius
Control	548.4	0.21	0.51
1–14 days	474.5	0.14[a]	0.36[a]
1–28 days	445.9	0.14[a]	0.35[a]
1–42 days	394.9	0.11[a]	0.21[a]

[a] Significantly different from controls at $p = 0.05$.

Similar observations on the spleen and bursa of Fabricius have been reported by Vos and van Genderen (*14*) for chicks fed hexabromobiphenyl and on the thymus of guinea pigs administered PCB. These workers showed that 30 ppm of hexabromobiphenyl fed for 63 days depressed the bursa of Fabricius and spleen relative to body weight. Those chicks fed 15 ppm had organ weights relative to body weights similar to control values. In another study (Fig. 7) our laboratory results indicated that

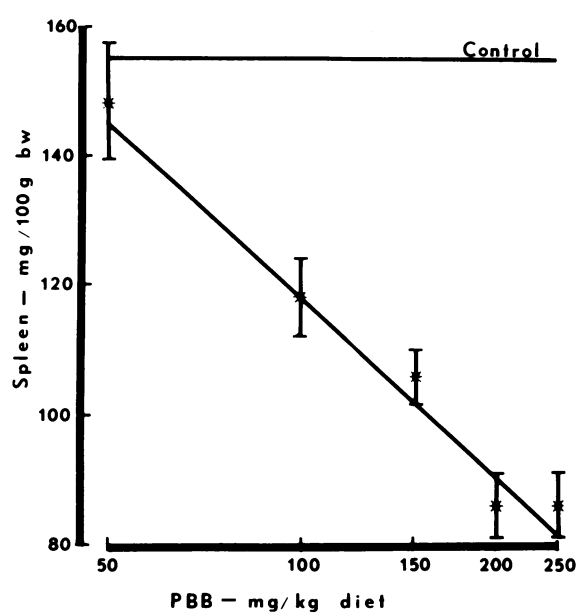

FIGURE 7. Spleen weight (mg/100 g body weight) of 4-week-old White Leghorn cockerels fed rations containing various levels of PBB from one day of age. Mean values given ± S. E. (*7*).

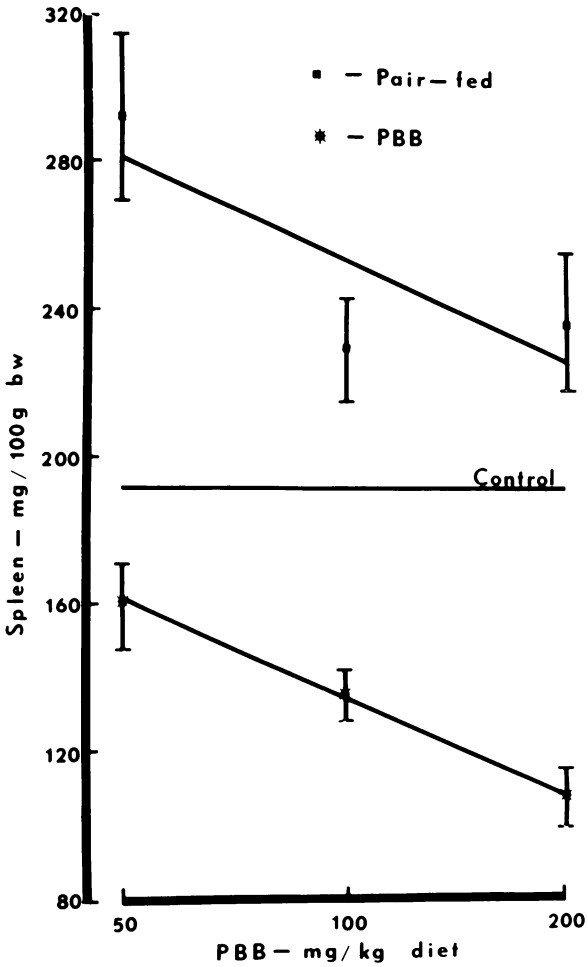

FIGURE 8. Spleen weight (mg/100 g body weight) of pair-fed White Leghorn cockerels fed rations containing various levels of PBB. Mean values ± S.E. (*7*).

spleen weight was significantly depressed in 4-week-old chicks fed levels just above 50 ppm PBB from day of age. However, in a pair-feeding study 50 ppm was shown to significantly alter the weight of the spleen since inanition caused the relative spleen weight to be increased above control values (see Fig. 8).

Whether the histological changes and weight changes in the organs of the immunological system reflect on the immunocompetence of this system remains to be clarified. Vos and van Genderen (*14*) indicated that humoral immunologic responses were impaired by hexabromobiphenyl.

Data reported in this paper were derived from that published in the theses of Edward H. Kowaleski, Jr., Frederick W. Heineman, and Linda Van Thiel to whom special thanks are given. Thanks is also given to Robert Cline, Sulo Hulkonen, and Beverly Trosko.

Journal article No. 8401, Michigan Agricultural Experiment Station.

REFERENCES

1. Carter, L. J. Michigan's PBB incident: Chemical mixup leads to disaster. Science. 192: 240 (1976).
2. Ringer, R. K., and Polin, D. The biological effects of polybrominated biphenyls in avian species. Fed. Proc. 36: 1894 (1977).
3. Babish, J. G., Gutenmann, W. H., and Stolesand, G. S. Polybrominated biphenyls: Tissue distribution and effect on hepatic microsomal enzymes in Japanese quail. J. Agr. Food Chem. 23: 879 (1975).
4. Van Thiel, L. R. The effects of polybrominated biphenyls on the hematology and plasma erythropoietin levels of the single comb White Leghorn cockerel. M. S. thesis, Michigan State University, 1977.
5. Heineman, F. W. The effects of polybrominated biphenyls on the cardiovascular physiology of the single comb White Leghorn cockerel. M. S. thesis, Michigan State University, 1976.
6. Heineman, F. W., and Ringer, R. K. Cardiovascular effects of a halogenated hydrocarbon, polybrominated biphenyl. Fed. Proc. 35(3): 399 (1976).
7. Kowaleski, E. H. Organ weights of single comb White Leghorn cockerels fed PBB. M. S. thesis, Michigan State University, 1976.
8. Sturkie, P. D. Avian Physiology. Springer-Verlag, New York, 1976.
9. Reins, D. A., Holmes, D. D., and Hinshaw, L. B. Acute and chronic effects of the insecticide endrin on renal function and renal hemodynamics. Can. J. Physiol. Pharmacol. 42: 599 (1964).
10. Emerson, T. E., Jr., Brake, C. M., and Hinshaw, L. B. Cardiovascular effects of the insecticide endrin. Can. J. Physiol. Pharmacol. 42: 41 (1964).
11. Jefferies, D. J., and French, M. C. The effect of *p*, *p'*-DDT on the rate, amplitude and weight of the heart of the pigeon and Bengalese finch. Brit. Poultry Sci. 12: 387 (1969).
12. Iturri, S. J., Cogger, E. A., and Ringer, R. K. Cardiovascular and hematological parameters affected by feeding various polychlorinated biphenyls to the single comb White Leghorn cockerel. Arch. Environ. Contam. Toxicol. 2: 130 (1974).
13. Iturri, S. J., and Ringer, R. K. unpublished data.
14. Vos, J. G., and van Genderen, H. Toxicological aspects of immunosuppression. In: Pesticides and the Environment: A Continuing Controversy. William B. Deichmann, Ed., Intercontinental Medical Book Corp., New York, 1973, p. 527.
15. Payne, L. N. The lymphoid system. In: Physiology and Biochemistry of the Domestic Fowl. D. J. Bell and B. M. Freeman Eds., Academic Press, New York, 1971, p. 985.
16. Lucas, A. M., et al. Production of so-called normal lymphoid foci following inoculation with lymphoid tumor filtrate. 1. Pancreas. 2. Liver and Spleen. Poultry Sci. 33: 562 (1954).