Induction of Hepatocellular Carcinoma in Nonhuman Primates by the Food Mutagen 2-Amino-3-Methylimidazo[4,5-*f*]quinoline

Richard H. Adamson,[1] Shozo Takayama,[1,2] Takashi Sugimura,[2] and Unnur P. Thorgeirsson[1]

[1]Division of Cancer Etiology, National Cancer Institute, National Institutes of Health, Bethesda, MD 20892 USA; [2]National Cancer Center Research Institute, Tokyo, Japan 104

The heterocyclic aromatic amine 2-amino-3-methylimidazo[4,5-*f*]quinoline (IQ) was evaluated for carcinogenic effects in macaques, primarily cynomolgus monkeys. IQ was administered by gavage five times a week at doses of 10 or 20 mg/kg. IQ induced hepatocellular carcinoma in 55% of the animals at the low dose and in 95% of the animals at 20 mg/kg. The average latent period at the high dose level was 43 months and that at the low dose was 60 months. Generally, the tumor nodules exhibited a well- to moderately well-differentiated hepatocellular carcinoma, and a trabecular pattern was most frequently seen. Pulmonary metastases were also found in several of the monkeys. Thus, IQ is a potent carcinogen in nonhuman primates and is a potential carcinogen for humans. *Key words:* 2-amino-3-methylimidazo[4,5-*f*]quinoline, hepatocellular carcinoma, heterocyclic amines, nonhuman primates. *Environ Health Perspect* 102:190–193(1994)

2-Amino-3-methylimidazo[4,5-*f*]quinoline (IQ) is one of 19 heterocyclic aromatic amines (HAAs) formed during the cooking of fish, fowl, pork, and beef and isolated as mutagens using the Ames *Salmonella typhimurium* assay (*1,2*). Although the HAAs thus far identified are present in the Western diet in only small amounts (nanograms per gram), they are among the most potent mutagens identified and may be of importance in the etiology of some human cancers (*3*). Ten of these food mutagens including IQ have been shown to be carcinogenic when administered to mice and rats (*4–8*). IQ was found to induce tumors of the liver, lung, and forestomach in mice and of the small and large intestine, mammary gland, liver, oral cavity, and Zymbal gland in rats (*4,5,8*). Based on chemical structure, mutagenic activity *in vitro*, concentration in cooked foods, carcinogenic activity in rodents, and availability, we selected three compounds for study in nonhuman primates: IQ, 2-amino-3,8-dimethylimidazo[4,5-*f*]quinoxaline (8-MeIQx), and 2-amino-1-methyl-6-phenylimidazo[4,5,*b*]pyridine (PhIP) (*9*). Our initial report described tumors induced in three macaques by IQ as part of an ongoing study (*10*). This paper reports on hepatocellular carcinoma induced in a high percentage of macaques by IQ after oral administration.

Materials and Methods

Macaques assigned to this study were born in a closed colony, reared by their mothers, and were assigned to this study as they became approximately 1 year of age. The monkeys were primarily cynomolgus (*Macaca fascularis*), but two rhesus (*M. mulatta*) were also used at the high dose. The animals were housed in individual stainless-steel cages that were wall mounted and equipped with an automatic watering device. Purina High Protein Monkey Chow #5045 was offered twice daily, and the animals also received a vitamin sandwich and a portion of an apple daily. IQ was purchased from the Nard Institute Ltd. (Osaka, Japan) and kept refrigerated in a desiccator until use. IQ was prepared daily as a suspension in hydroxypropylcellulose (HPC) and administered by gavage five times a week (Monday–Friday) at a dose of 10 or 20 mg/kg body weight. Twenty animals were assigned to each dose. The monkeys receiving 10 mg/kg IQ were all cynomolgus and consisted of 12 males and 8 females. Two rhesus females and 18 cynomolgus (8 males and 10 females) monkeys received 20 mg/kg IQ.

There were three sources of controls: 9 concurrent HPC cynomolgus monkeys dosed by gavage, 3 historical HPC cynomolgus monkeys fed HPC in a prune for over 16 years and still on HPC treatment, and 5 cynomolgus untreated concurrent controls.

We observed all IQ treated and control animals daily and measured body weight weekly. Blood was drawn every 3 months for routine hematology and clinical chemistry values as well as α-fetoprotein (AFP) measurements, which were determined by radioimmunoassay using monkey AFP as antigen. Liver palpation and laparoscopy were performed at 3- to 6-month intervals. The tumor bearing animals were euthanized with an overdose of sodium pentobarbital and carefully necropsied. Tissues from all the organs were subjected to histopathological examination.

Results

Table 1 summarizes the number of macaques with tumors induced by IQ as of 1 July 1993. Eleven monkeys (55%) had liver tumors induced at the 10 mg/kg dose level and 19 (95%) at the 20 mg/kg dose level. Both male and female monkeys were susceptible to the compound. Table 2 summarizes the average total dose from time of initiation of treatment until time of tumor development (as indicated by histopathology following biopsy or at necropsy). The animals at 20 mg/kg received a higher average total dose (45.1 g) than the 10 mg/kg group (39.7 g) and also had a shorter latent period for tumor induction (i.e., 43 months versus 59 months; Table 2). The shortest latent period was 27 months at the 20 mg/kg dose level, and thus far the longest latent period was 83 months at the 10 mg/kg dose (Table 2). However, several animals at the 10 mg/kg dose level have exceeded 83 months of exposure to IQ and are alive without evidence of tumor. One animal at the 20 mg/kg dose level remains on study with no evidence of gross liver pathology after 91 months and a total dose of 110 g. Seven animals remain on the study at the 10 mg/kg dose level without evidence of tumor. Two of the monkeys at the 10 mg/kg level have died without tumor. One died as a result of bloat which was not compound related, and the other died as a result of thrombocytopenia. At the present time, it cannot be ruled out that the low platelet counts were compound related. Generally, liver function tests were not helpful for diagnosing liver cancer, and abnormal values were found subsequent to tumor detection by laproscopic examinations.

All the IQ-induced primary tumors were found in the liver. As indicated in Table 1, neither the HPC concurrent controls, the historic HPC controls, nor the

Address correspondence to R.H. Adamson, Division of Cancer Etiology, National Cancer Institute, Building 31, Room 11A03, Bethesda, MD 20892 USA.

This work was supported in part by National Cancer Institute contract no. NO1-CP-51013 to Hazleton Laboratories America, Inc., Vienna, VA, and by a Grant-in-Aid from the Ministry of Health and Welfare for a Comprehensive 10-Year Strategy for Cancer Control, Japan; and by the Foundation for Promotion of Cancer Research, Japan.

Received 2 August 1993; accepted 23 November 1993.

Table 1. Malignant liver tumors induced by IQ in nonhuman primates

Compound	No. treated	No. with tumors	% with tumors
IQ,10 mg/kg	20	11 (3 females, 8 males)	55
IQ, 20 mg/kg	20	19 (11 females, 8 males)	95
HPC concurrent controls	9	0	0
HPC historical controls	3	0	0
Untreated controls	5	0	0

HPC, hydroxypropylcellulose.

Table 2. Dose and latent period for induction of hepatocellular carcinoma in nonhuman primates

Compound	Average total dose of IQ at tumor diagnosis (g)	Average latent period for tumor induction (months)
IQ, 10 mg/kg	39.7 (22–55)[a]	59.6 (36–83)
IQ, 20 mg/kg	45.1 (19–82)[b]	43.4 (27–68)[b]

[a]Ranges in parentheses .
[b]Figures are for the cynomolgus monkeys; the values for the two rhesus females with hepatocellular carcinoma are 76 g and 91 g total dose with a 56-month and 51-month latent period for tumor inductions.

untreated concurrent controls had tumors of any type. Furthermore, the tumor incidence for all types of malignant neoplasms in the breeders, solvent and untreated controls of this colony during the past 32 years was 1.5% for cynomolgus monkeys (total of 130 animals) and 2.8% for rhesus monkeys (total 181 animals). None of these tumor were hepatocellular carcinomas.

The extent of malignant tumor involvement of the liver varied, ranging from a solitary, well-circumscribed nodule (Fig. 1) to a massive destruction of all lobes of the liver by numerous tumor nodules (Fig. 2). Most of the tumor nodules were well defined and soft with areas of necrosis and hemorrhage. In one of the cases, there was gross evidence of tumor invasion of the superior vena cava. Lung metastases were detected in two of the animals (both males) at the 10 mg/kg dose and four (two males and two females) at the 20 mg/kg dose. In the first animal that was diagnosed with metastatic hepatocellular carcinoma after a latent period of 27 months, there was evidence of local invasion into the muscular layer of the stomach, in addition to metastases to lungs and hilar lymph nodes.

Microscopically, all the malignant liver tumors were of hepato-biliary origin. The majority of the tumor nodules were hepatocellular carcinomas, with trabecular pattern being the most common (Fig. 3). However, among the five cases with massive tumor involvement, as depicted in Figure 2, the histological growth pattern of hepatocellular carcinoma (Fig.4) and the lung metastasis (Fig.5) was moderately to poorly differentiated and showed little resemblance to normal liver cells. In several of the livers with multiple tumors, individual nodules were composed of mixed hepatocellular and cholangiocarcinoma. Histological variants, such as clear cell and scirrhous types of hepatocellular carcinomas,

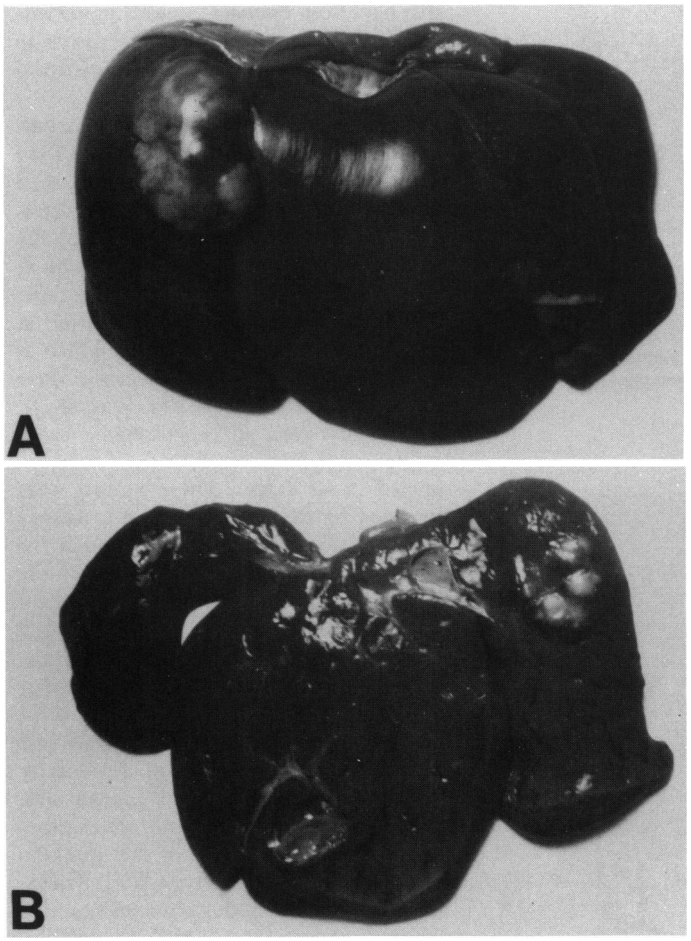

Figure 1. Gross appearance of the anterior surface (A) and cross section (B) of the liver from case no. 1416CC. Two well-defined nodules of hepatocellular carcinoma were present; the larger one (3.5 cm in diameter) is seen protruding from the anterior surface of the right superior lobe.

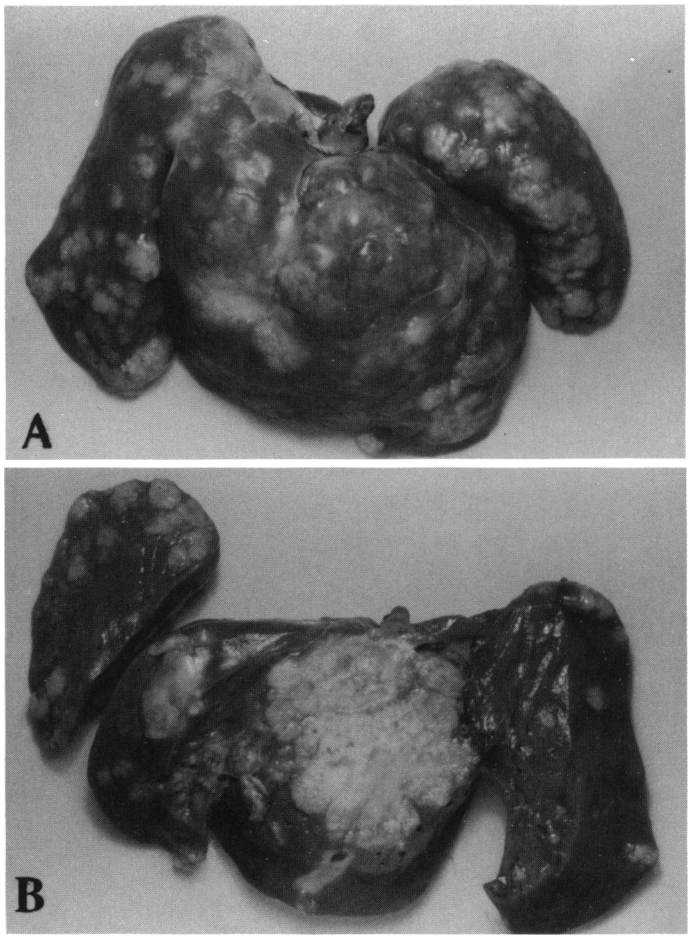

Figure 2. Gross appearance of the anterior surface (A) and cross section (B) of the liver from case no. 1423CC. The liver shows massive involvement by hepatocellular carcinoma. The largest mass (7 cm in diameter) is located in the right superior lobe, and numerous smaller nodules are present throughout the liver.

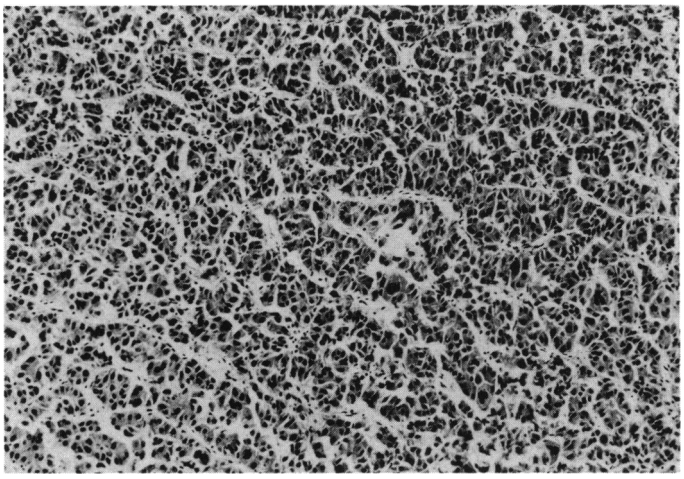

Figure 3. Microscopic appearance of a liver tumor nodule from case no. 1416CC showing a trabecular pattern of well-differentiated hepatocellular carcinoma (100×, hematoxylin-eosin).

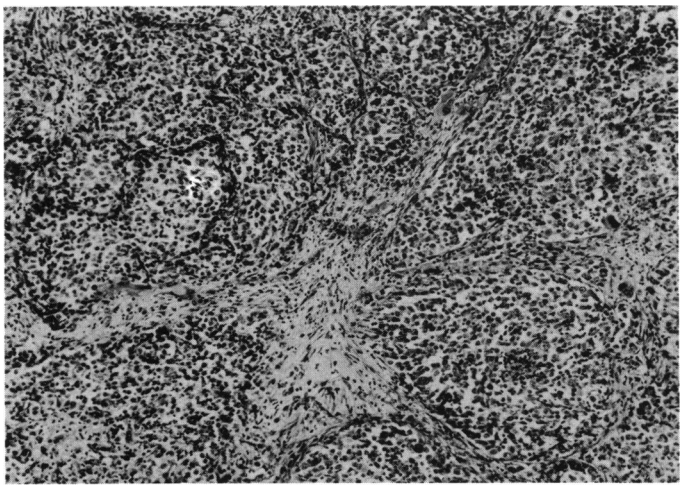

Figure 4. Microscopic appearance of a representative tumor nodule from case no. 1423CC. Solid nests of moderately to poorly differentiated hepatocellular carcinoma are surrounded by bands of connective tissue (100×, hematoxylin-eosin).

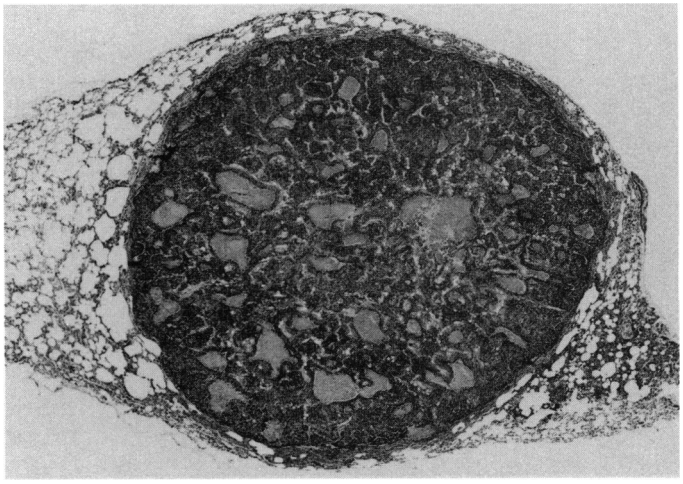

Figure 5. Microscopic appearance of a lung nodule from case no. 1423CC, showing metastatic hepatocellular carcinoma (50×, hematoxylin-eosin).

were detected in rare instances. There was microscopic evidence of intrahepatic vascular invasion in approximately 50% of the cases, and in the livers with massive tumor involvement extensive intravascular tumor thrombi were seen. In contrast to rodent hepatocarcinogenesis models, hyperplastic nodules were not identified before gross tumor development. In the IQ-treated monkeys, pinpoint 1–2 mm light-tan lesions were seen during laparoscopic examination and at necropsy. Microscopically, these lesions were composed of glycogen-filled hepatocytes with small eccentric nuclei. It remains to be determined if these clear-cell foci have any relationship with the carcinogenic process.

Discussion

During the past decade, several highly mutagenic HAAs have been identified in cooked beef, pork, fish, and fowl (*1,2*). These compounds are formed during normal cooking practices such as frying, broiling, or grilling. The three compounds selected for study in nonhuman primates, IQ, 8-MeIQx, and PhIP, are representative of the most prevalent class of HAAs present in the Western diet. Ten of the HAAs that have been evaluated in rodents are carcinogenic, including IQ, but the degree to which these data should be extrapolated to the human population is debatable.

Results presented in this paper demonstrate convincing evidence that the food mutagen IQ is carcinogenic to cynomolgus and rhesus monkeys after oral administration. IQ induced tumors in 55% of the animals at the 10 mg/kg dose level, and in 95% of the animals at the 20 mg/kg dose. In addition, the average latent period at the high dose was 43 months, which is about one-seventh of the life span of these animals (25- to 30-year life expectancy). The tumors were all hepatocellular carcinomas, and metastases to the lungs occurred in six cases. These tumors were induced by doses that were not overtly toxic and the high dose used was not the maximum tolerated dose. Generally, the tumor nodules in the animals exhibited a well- to moderately well-differentiated hepatocellular carcinoma. The liver parenchyma that was not involved with neoplastic changes was relatively normal, except for clear-cell foci, which were commonly seen. With the exception of moderately enlarged lymph nodes of the colonic submucosa and mesentery, no other gross abnormalities were seen in the monkeys receiving IQ necropsied to date. Microscopically these nodes showed reactive hyperplasia and large lymphoid follicles. The only other microscopic abnormalities that have been demonstrated in these IQ-treated monkeys are focal myocardial

lesions consistent with the initial stages of toxic cardiomyopathy (*11*).

Although the doses used in these experiments are much higher than those reported in several studies (*2*) of fried ground beef (0.02–0.6 ng/g) or broiled sardines (4.9–20 ng/g), IQ is only 1 of 19 HAAs identified in cooked meat. In addition, the tumors induced by IQ in nonhuman primates occurred in a high percentage of the treated animals in only about one-seventh of their life span. Furthermore, two of the other HAAs occurring in greater amounts in cooked meats, MeIQx and PhIP, are carcinogenic in rodents and are currently also under evaluation for carcinogenic activity in nonhuman primates (*6,7,9,12*). Thus, we conclude that the food mutagen IQ is a potent hepatocarcinogen when administered to nonhuman primates and is a potential carcinogen for humans.

References

1. Sugimura T. Carcinogenicity of mutagenic heterocyclic amines formed during the cooking process. Mutat Res 150:333–412(1985).
2. Felton JS, Knize MG. Heterocyclic amine mutagens/carcinogens in foods. In: Handbook of experimental pharmacology (Cooper CS, Grover PL, eds). Berlin:Springer-Verlag, 1990;471–502.
3. Adamson RH. Mutagens and carcinogens formed during cooking of foods and methods to minimize their formation. In: Cancer prevention (De Vita VT Jr., Hellman S, Rosenberg SA, eds). Philadelphia:J.B. Lippincott, 1990;1–7.
4. Ohgaki H. Kusama K, Matsukura N, Morino K, Hasegawa H, Sato S, Takayama S, Sugimura T. Carcinogenicity in mice of a mutagenic compound, 2-amino-3-methylimidazo[4,5-*f*]quinoline, from broiled sardine, cooked beef and beef extract. Carcinogenesis 5:921–924(1984).
5. Takayama S, Nakatsuru Y, Masuda M, Ohgaki H, Sato S, Sugimura T. Demonstrations of carcinogenicity in F344 rats of 2-amino-3-methylimidazo[4,5-*f*]quinoline from broiled sardine, fried beef and beef extract. Jpn J Cancer Res 75:467–470(1984).
6. Ohgaki H, Takayama S, Sugimura T. Carcinogenicities of heterocyclic amines in cooked foods. Mutat Res 259:399–410(1991).
7. Ito N, Hasegawa R, Sano M, Tamano S, Esumi H, Takayama S, Sugimura T. A new colon and mammary carcinogen in cooked food, 2-amino-1-methyl-6-phenylimidazo[4,5*b*]pyridine (PhIP). Carcinogenesis 12:1503–1506(1991).
8. Tanaka T, Barnes WS, Williams GM, Weisburger, JH. Multipotential carcinogenicity of the fried food mutagen 2-amino-3-methylimidazo[4,5-*f*]quinoline in rats. Jpn J Cancer Res 76:570–576(1985).
9. Adamson RH, Snyderwine EG, Thorgeirsson UP, Schut HAJ, Turesky RJ, Thorgeirsson SS, Takayama S, Sugimura T. Metabolic processing and carcinogenicity of heterocyclic amines in nonhumans primates. In: Xenobiotics and cancer (Ernster L. Esumi H, Fujii Y, Gelboin HV, Kato R, Sugimura T, eds). Tokyo:Japan Scientific Societies Press, 1990; 289–301.
10. Adamson RH, Thorgeirsson UP, Snyderwine EG, Thorgeirsson SS, Reeves J, Dalgard DW, Takayama S. Sugimura T. Carcinogenicity of 2-amino-3-methylimidazo[4,5-*f*]quinoline in nonhuman primates:induction of tumors in three macaques. Jpn J Cancer Res 81:10–14 (1990).
11. Thorgeirsson UP, Farb A, Virmani R, Adamson, RH. Cardiac damage induced by 2-amino-3-methylimidazo[4,5-*f*]quinoline (IQ) in nonhuman primates. Environ Health Perspect 102:194–199(1994).
12. Kato T, Ohgaki H, Hasegawa H, Sato S, Takayama S, Sugimura T. Carcinogenicity in rats of a mutagenic compound, 2-amino-3, 8-dimethylimidazo[4,5-*f*]quinoxaline. Carcinogenesis 9:71–73(1988).

Volume 102, Supplement 1, January 1994

Environmental Health perspectives Supplements

Biostatistics in the Study of Toxicology

Volume 102, Supplement 1, presents the proceedings of the International Biostatistics Conference on the Study of Toxicology held May 23–25, 1991, at Sanjo Kaikan, University of Tokyo, Japan. Because the importance of statistical methods in toxicology is recognized and methodologies are rapidly developing, the main objective of this meeting was to discuss the application of statistical methods for the evaluation of toxicological data. Sponsors for the conference are the Biometric Society, Japanese Region; Environmental Mutagen Society of Japan; National Institute of Hygienic Sciences, Japan; and the National Institute of Environmental Health Sciences, USA.

To order your copy, contact:
Government Printing Office
Washington, DC 20402
or call 202-512-2406.