Clin. exp. Immunol. (1989) **78**, 67–74

Cellular immune response in *Echinococcus multilocularis* infection in humans. II. Natural killer cell activity and cell subpopulations in the blood and in the periparasitic granuloma of patients with alveolar echinococcosis

D. A. VUITTON, S. BRESSON-HADNI, L. LAROCHE,* D. KAISERLIAN,* S. GUERRET-STOCKER,† J. L. BRESSON & M. GILLET‡ *Groupe de Recherche sur l'Echinococcose Alvéolaire (AREA) Faculté de Médecine, Besançon; and *Unité 25, INSERM Paris, and †Unité de Pathologie Cellulaire du Foie, Institut Pasteur, Lyon; and ‡Service de Chirurgie Viscérale et Vasculaire, C.H.U. Besançon, France*

(Accepted for publication 12 June 1989)

SUMMARY

In animal models, the development of *Echinococcus multilocularis* larvae has been shown to correlate with the immune status of the host, and particularly with cellular immunity. In humans, a defect in immune regulation may explain the persistence of cellular infiltration and fibrogenesis. We assessed natural killer (NK) activity in the peripheral blood mononuclear cells (PBMC) of patients with alveolar echinococcosis, and compared in 12 patients who underwent a surgical procedure the cell populations in the PBMC with those present in the periparasitic granuloma. The results indicated that (i) the NK cell activity of the PBMC was significantly altered at the lower NK cell: target cell ratios; (ii) the percentage of CD8+ cells was significantly decreased in the PBMC with an increased CD4:CD8 cell ratio; (iii) inversely, the $CD8^+$ cells constituted the main population of T cells in the liver of most patients; and (iv) the periparasitic granuloma was mainly composed of macrophages, T cells and myofibroblasts in close association with the developing fibrosis. A relatively high number of $CD4^+$ cells in the periparasitic granuloma of two patients with 'abortive' parasitic lesions suggested that, as it is observed in experimental *E. multilocularis* infection, differential evolution of the phenotypic pattern of the periparasitic granuloma could be related to resistance or sensitivity to infection by *E. multilocularis* in humans.

Keywords human alveolar echinococcosis *Echinococcus multilocularis* electron microscopy peripheral blood mononuclear cells subpopulations natural killer activity granuloma

INTRODUCTION

Alveolar echinococcosis (AE) is a rare and often fatal parasitic disease, caused by the larvae of *Echinococcus multilocularis*; the disease is observed in alpine countries, and in the USSR, Alaska, China and Japan (Wilson & Rausch, 1980; Bresson-Hadni *et al.*, 1988). Mononuclear cell infiltration and extensive fibrosis are predominant pathological features of the disease (Bresson-Hadni *et al.*, 1988), and animal experiments have suggested the influence of cellular immunity on the development of the lesions (Ali-Khan, 1978). We have shown that total circulating lymphocytes and percentage of B lymphocytes (assayed by surface immunoglobulins) were significantly lower in patients with AE (Vuitton *et al.*, 1984). Moreover, an impairment of functional activity of T lymphocytes was demonstrated, despite a normal percentage of T cells, assayed by sheep red blood cells (SRBC) rosettes (Vuitton *et al.*, 1984). These results suggested that human AE was associated with important immunological disturbances.

Correspondence: Professor Dominique A. Vuitton, Immunologie Clinique, Centre Hospitalier Regional, F-25030 Besançon, France

In animal models, the development of *E. multilocularis* larvae has been shown to correlate with the immune status of the host; it was increased by thymectomy, irradiation or anti-lymphocyte serum (Baron & Tanner, 1976) and decreased by BCG therapy (Rau & Tanner, 1975). Differences in susceptibility of natural or experimental hosts (Lukashenko, 1968; Ali-Khan, 1974) to infection by larvae may be due to genetically determined natural or acquired immunity. We have shown that mice of the C57BL6 strain were particularly sensitive to infection after an intra-hepatic injection of larvae, while C57BL10 mice were quite resistant (Liance *et al.*, 1984). In endemic areas, the number of patients with AE is relatively low despite a high prevalence of infection in intermediate and definitive hosts (Delattre *et al.*, 1988). This epidemiological observation suggests that humans are particularly resistant to infection by *E. multilocularis*. The occurence of AE in humans could be related to quantitative or qualitative abnormalities in

Table 1. Clinical features and levels of specific antibodies in 14 patients with alveolar echinococcosis

Patient no	Type of investigation*	Age	Sex	Volume of the parasitic lesions†	Jaundice	Portal hypertension	Specific antibodies: Indirect haemagglutination (titre)	Specific antibodies: *Em*2-ELISA (%)
1	ABC	24	M	4	+	−	1:640	63
2	ABC	47	M	4	+	−	1:2560	71
3	ABC	48	F	3	+	−	1:5120	79
4	AB	76	M	4	+	+	1:2560	—
5	ABC	21	F	1	−	+	1:320	05
6	ABC	31	M	3	−	+	1:2560	38
7	ABC	37	M	2	−	+	1:10240	77
8	ABC	39	M	2	−	−	1:320	53
9	AB	54	F	3	−	+	1:280	69
10	BC	55	M	3	+	−	1:10240	89
11	BC	39	M	4	−	+	1:640	66
12	BC	60	M	3	−	−	1:40	63
13	BC	48	F	3	−	−	1:80	04
14	BC	37	F	2	−	−	1:320	07

*A, Assay for NK cytotoxicity; B, evaluation of T cell subpopulations in PBMC; and C, Study of cell-populations in the periparasitic granuloma.

†Semi-quantitative assessment of parasitic material in the liver was made from CT scan and surgical observations as follows: 1, <15% of hepatic volume; 2, >15%<30%; 3, >30%<50%; and 4, >50%±metastases.

T cells or in cells of the 'natural' immune system. However, pathological evidence in animals (Liance *et al.*, 1984) and in humans (Vuitton *et al.*, 1986) indicates that the immune granulomatous reaction involving lymphocytes and macrophages is mainly responsible for the development of the dense and definitive fibrosis which is a characteristic feature in this disease. A defect in immune regulation may explain the persistence of cellular infiltration and fibrogenesis in patients with a clinically expressed AE.

In order to test these hypotheses, we assessed natural killer (NK) activity in circulating mononuclear cells of patients with AE, since these cells have been proven to exert cytotoxic functions in some parasitic diseases (Attalah *et al.*, 1980). In 12 patients who underwent a surgical procedure, the characterization of the cell populations in the periparasitic granuloma was performed using both immunohistochemical staining with mononuclear antibodies and ultrastructural analysis. These cell populations were compared with those present in the peripheral blood mononuclear cells (PBMC) of patients with AE.

MATERIALS AND METHODS

Patients

We studied 14 patients (nine men and five women; mean age 44 years, range 21–76). All patients were from Franche-Comté, France. Diagnosis of AE was confirmed by histological examination of the liver. The clinical features of these patients are shown in Table 1. They had not received any drugs and had been operated on for the two months prior to the study of the PBMC. At the time of the study, they did not present any clinical symptoms of bacterial infection. Biliary obstruction is the main complication of the disease: jaundice was present in five patients (patients 1–4 and 10) and anicteric cholestasis (alkaline phosphatase > 200 IU/*l*) in four patients (patients 5–7 and 11). Evaluation of T cell subpopulations in PBMC was performed in the 14 patients, evaluation of cell populations in the liver parasitic lesions was determined in 12 patients (Table 1) and NK activity of PBMC was assessed in nine patients (six men and three women; mean age 42 years, range 21–76) (patients 1–9) (Table 1). Twelve healthy age- and sex-matched blood donors were used as normal controls. Twelve consecutive patients submitted to an endoscopic retrograde cholangiopancreatography were studied to assess the potential effect of obstructive cholestasis not related to a parasitic disease on T cell phenotypes and NK activity. Specific antibodies against *E. multilocularis* were assessed in patients, using the *Em*2-ELISA (Gottstein, Eckert & Fey, 1983), an indirect haemagglutination technique and immunoelectrophoresis (Capron *et al.*, 1970). Individual values of specific antibodies evaluated using *Em*2-ELISA and indirect haemagglutination are shown in Table 1.

Assay for NK cytotoxicity

NK cell activity was measured in a 4-h Cr release assay using the myelogenous human cell line K562 as target cells according to a previously described procedure (Kaiserlian, Savino & Bach, 1983).

Monoclonal antibodies (MoAbs)

MoAbs of the OKT series (Ortho Diagnostic systems Raritan, NJ) were used for evaluating PBMC subpopulations: the OKT3, OKT4 and OKT8 MoAbs. Six MoAbs were used for the immunohistological staining procedures: the above mentioned OKT4 and OKT8, Leu 2a+3b (Becton Dickinson, Erembodegem, Belgium) Leu 3a+b (Becton Dickinson), B1 (Coulter-Clones, Hialeah, FL), and OKM1 (Ortho Diagnostic Systems).

Assessment of PBMC subpopulations

Fresh PBMC were isolated from the interface of a Ficoll-telebrix

Table 2. NK cell activity against ^{51}Cr-labelled K562 cells in PBMC of patients with alveolar echinococcosis (AE) and of control subjects

	PBMC: target cell ratio			
Subjects	100:1	50:1	25:1	12·5:1
Patients with AE				
Median	48·5	43·0	31·5*	19·0*
Range	16·7–57·5	16·5–55·2	8·0–39·1	3·0–32·5
Age-and sex-matched healthy controls				
Median	47·6	49·5	41·7	25·8
Range	36·9–66	30·5–68	17·0–52·6	9·8–42·8
Patients with non-parasitic biliary disease				
Median	72·5	64·3	55·2	43·9
Range	42·0–86·5	28·0–84·5	23·0–79·6	18·0–65·9

*Significantly different from the values obtained in both control groups ($P < 0·05$).

gradient, according to Böyum's technique (Böyum, 1966). The indirect immunofluorescence method was performed as previously described (Laroche & Bach, 1981).

Immunohistological staining procedures
Surgical liver biopsy specimens were obtained in the granulomatous areas, closely adjacent to parasitic lesions. Tissue was immediately snap-frozen in liquid nitrogen. Cryostat sections (5 μm) were cut, fixed in acetone and air-dried. Staining with MoAb was performed using an indirect immunofluorescence technique (Montaño *et al.*, 1983). All the biopsy specimens were observed in parallel using routine techniques.

Ultrastructural analysis of the granuloma
The tissues were fixed in 4% glutaraldehyde, buffered in 0·3 M cacodylate, followed by postfixation in 1% osmic acid at 4°C for 60 min. Dehydration was carried out in ethanol and propylene oxide followed by embedding in Epoxy resin. Ultra-thin sections were stained with uranyl-acetate and lead citrate solutions and observed on a Philips EM 300 microscope, Philips, Holland. Semi-thin sections were used to choose the granulomatous areas surrounding parasitic lesions.

Statistical analysis
The non-parametric Mann–Whitney two-tailed *U*-test, the Spearman rank sum test, and the χ^2 test were used to test comparisons and correlations.

RESULTS

NK cell activity in PBMC of patients with AE
Mean values of NKcell cytotoxicity were lower in patients with AE than those in control subjects (Table 2). This decrease in NK activity was significant ($P < 0·05$) at the lowest PBMC: target cell ratios. The values of NK activity obtained in patients with AE were significantly lower than those obtained in patients with non-parasitic biliary disease for all the PBMC: target cell ratios under study ($P < 0·02$). In the latter group, values of NK activity were significantly higher than in the group of healthy subjects ($P < 0·05$). In patients with AE, the levels of NK activity at any PBMC: target cell ratio did not correlate with clinical status or prognosis and with the titres of specific antibodies, or percentage of T cells.

T cell subpopulations in PBMC of patients with AE
In patients with AE, although the total number of cells of the CD3 phenotype was normal, the percentage of CD8$^+$ cells was significantly lower than that observed in normal controls and in patients with biliary disease (Table 3). The percentage of cells of the CD4$^+$ phenotype was not significantly different from that observed in controls. The T cell subpopulation imbalance resulted in a significant increase in the CD4:CD8 ratio ($P < 0·001$). These abnormalities were not correlated with the presence or absence of jaundice. There was no correlation between percentages of T cell subpopulation or CD4:CD8 ratios and the titres of specific antibodies, or the amount of parasitic material in the liver.

Immunohistochemical analysis of the periparasitic granuloma (Fig. 1)
The periparasitic granuloma obtained from the surgical liver biopsies of the 12 patients with AE was predominantly composed of CD3$^+$ cells and M1$^+$ cells (Fig. 1 C, G, H). The B1$^+$ lymphocytes were very rare. Cells identified as macrophages by the OKM1 MoAb were mainly located in the centre of the granuloma, adjacent to the parasitic vesicles; however, their number was markedly lower than that of the 'histiocytes' observed on the slides stained with haematoxylin–eosin–safran. T lymphocytes were mostly distributed at the periphery of the granuloma. In ten cases, the CD8$^+$ lymphocytes predominated largely in the periparasitic infiltrate (Fig. 1 D, F, I, K) where only a few CD4$^+$ lymphocytes were seen. In comparison, in the liver specimens of two patients (patients 13 and 14), the lymphocyte infiltrate was composed mostly of CD4$^+$ cells (Fig. 1 E).

Ultrastructural analysis of the periparasitic granuloma (Fig. 2)
Immunocompetent cells were relatively scarce in the granuloma. Their localization confirmed immunohistochemical observations: macrophages were scattered inside the granuloma and at the vicinity of the parasitic vesicles; clusters of lymphocytes were

Table 3. T cell subpopulations characterized by OKT monoclonal antibodies in PBMC of 14 patients with alveolar echinococcosis (AE) and of control subjects

	OKT3*	OKT4*	OKT8*	OKT4†	OKT8†	OKT4/OKT8
Patients with AE						
Mean ± s.d.	71 ± 12·8	50 ± 12·2	18 ± 5·2‡	71 ± 10·3	26 ± 8·2	2·9 ± 1·0‡
Median	68	49	18	73	25	2·9
Range	48–87	35–67	12–30	52–85	15–45	1·2–5·1
Age- and sex-matched healthy controls						
Mean ± s.d.	70 ± 6·3	47 ± 4·2	25 ± 4·7	67 ± 7·0	35 ± 6·1	1·9 ± 0·3
Median	69	48	25	67	34	1·8
Range	57–81	38–53	20–36	59–82	29–50	1·5–2·3
Patients with non-parasitic biliary disease						
Mean ± s.d.	64 ± 13·1	40 ± 9·6	24 ± 6·6	63 ± 16·3	39 ± 13·4	1·7 ± 0·5
Median	64	41	21	65	33	1·8
Range	42–83	17–53	14–36	40–92	23–64	0·6–2·8

*Percentage of PBMC reactive with OKT3, OKT4, and OKT8 monoclonal antibodies as referred to total PBMC.

†Percentage of PBMC reactive with OKT4, and OKT8 monoclonal antibodies as referred to total T lymphocytes reactive with OKT3.

‡Significantly different from the values obtained in both control groups ($P < 0·05$).

observed at the periphery of the granuloma (Fig 2a,b). In addition, some eosinophils (Fig 2 c) and plasma cells were also observed. However, the myofibroblast was the main cell type in the developing fibrosis (Fig. 2 e, f). Fibrosis was made of typical collagen bundles in every sample, associated with elastin deposits in some of them (Fig 2 d). In more central areas of parasitic lesions, acellular necrosis and fibrosis completely replaced the liver parenchyma: cellular remnants of fat-storing cells (Ito cells) were the only cell components observed in this area (Fig. 2 h). Old parasitic vesicles were delineated by the so-called 'laminated layer': it consisted of laminated amorphous electron-dense concentric deposits without collagen structure, lining degenerating cells of the granuloma (Fig 2 g).

DISCUSSION

Our results were obtained from a relatively low number of patients; however, it should be noted that AE is a very severe but relatively rare disease: the annual incidence of operated cases does not exceed five, even in hyperendemic areas (Bresson-Hadni *et al.*, 1988).

NK cells have been shown to have spontaneous ability to lyse a variety of tumor cells (Herberman, 1981). The involvement of NK cells has been shown in granulomatous diseases such as infection caused by BCG (Wolfe, Tracey & Henney, 1977) and *Listeria monocytogenes* (Holmberg, Springer & Ault, 1981), and their role in parasitic diseases has been pointed out in trypanosomiasis (Hatcher & Kuhn, 1982). In schistosomiasis Gastl *et al.* (1984) have demonstrated a severe impairment of NK-mediated lysis of K562 target cells despite a normal number of lymphocytes expressing the HNK1 phenotype, considered as a good marker for the NK cells (Abo & Balch, 1981). We observed a less severe decrease in the NK activity of the PBMC of our patients with AE, as compared with healthy subjects; however, it was significant at the lowest killer cell:target cell ratios and it was significantly lower than that observed in patients with a similar bile duct obstruction, without hepatic parasitic disease. In our study, identification of PBMC with HNK1 phenotype using the Leu 7 MoAb (Becton-Dickinson) was performed only in five patients tested for NK cells activity (data not shown); the results suggest that the low NK activity observed in our patients could be in part related to a low percentage of NK cells in circulating blood; however, homing of NK cells in the liver, or presence of serum inhibitory factors such as immune complexes or antibodies (Sibbit, Froelich & Bankhurst, 1983) may be complementary explanations.

The phenotype pattern of T cell subpopulations in the peripheral blood of patients with AE was significantly altered. So far, little is known about the quantitative relation among lymphocyte subpopulations in the blood of patients with helminthic diseases, and particularly larval cestodoses. Colley *et al.* (1983) and Gastl *et al.* (1984) reported a decreased percentage of $CD4^+$ cells in patients with Schistosomiasis with a decreased CD4:CD8 ratio significantly correlated with the parasite load. We have previously demonstrated a normal percentage of peripheral blood T cells using SRBC-rosettes (Vuitton *et al.*, 1984). Our results obtained by using the OKT3 MoAb as marker confirmed the normal percentage of T cells; however, the results obtained with OKT4 and OKT8 showed that the percentage of subpopulations exhibiting these phenotypes were quite different from those observed in schistosomiasis. The observed decrease in $CD8^+$ PBMC was unlikely to be related to the clinical status of the patients: no relation was found between CD4:CD8 ratios and clinical or biological symptoms. Moreover, the results obtained in patients with AE were not found in the control patient with non-parasitic biliary disease. In the other hepatic diseases studied until now, the CD4:CD8 ratios of circulating lymphocytes have been shown to be unrelated to clinical or biological symptoms of liver dysfunction, but significantly correlated to the aetiology of the disease (Barnaba *et al.*, 1983; Montaño *et al.*, 1983). The decreased $CD8^+$ subpopulation in PBMC could be due to a preferential homing of the cells around the parasitic larvae.

In fact, our results in 10 out of the 12 patients indicated a high percentage of $CD8^+$ cells in the liver lesions. Similar observations have been made in granulomatous diseases such as

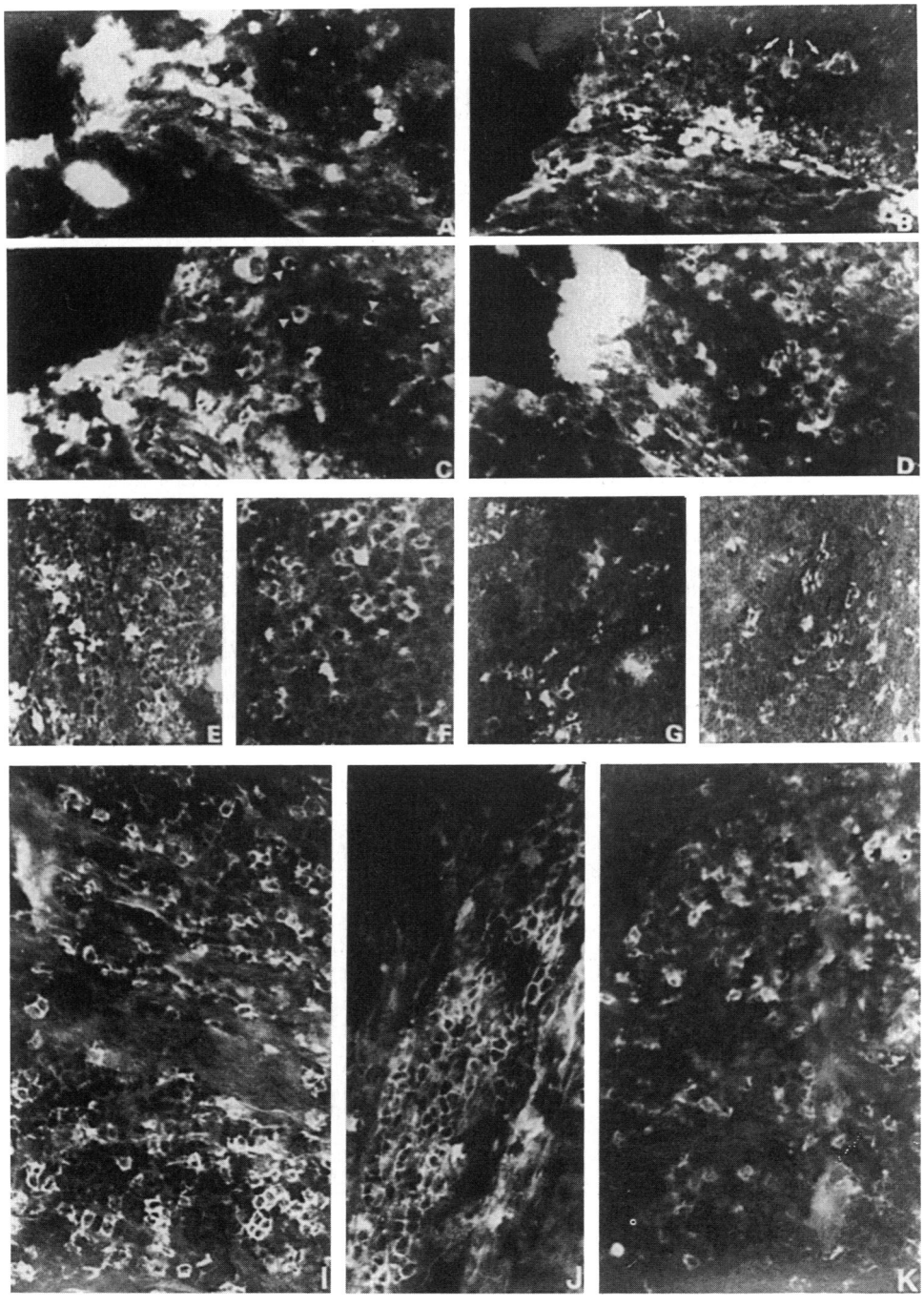

Fig. 1. Immunocytochemical analysis with monoclonal antibodies (MoAb) of the granuloma surrounding parasitic vesicles in human alveolar echinococcosis (× 200). A–D, Comparison of staining on contiguous sections (patient no 1) (*: artefacts due to bile pigment deposits); A, Control section without MoAB; B, Few B lymphocytes (B1 MoAb) (arrows); C, Several $CD3^+$ T lymphocytes (Leu 2+3 MoAb) (arrows); D, T lymphocytes are mostly $CD8^+$ cells (OKT8 MoAB); J, CD3+ T lymphocytes (Leu 2+3 MoAb) (patient 1); F, I, K, Dense infiltrate of $CD8^+$ cells (patients 1, 2, and 13); E, $CD4^+$ infiltrate in one of the 2 particular cases with abortive lesions (Leu 3 MoAb) (patient 13); G–H: Macrophages (OKMI MoAb) (patient 2 and 11) (arrows).

sarcoïdosis (Semenzato *et al.*, 1982) and tuberculosis (Shiratsuchi & Tsuyuguchi, 1984). However, in the biopsy specimens from two patients, the lymphocyte infiltrate was mostly composed of $CD4^+$ cells. Interestingly, these two patients had a particular form of AE: the titres of specific antibodies were low and the histopathological examination of the parasitic tissue showed an 'abortive' aspect. Recent reports from Alaska indicate also the possibility of a spontaneous death of *E. multilocularis* at a relatively early stage of infection (Rausch *et al.*, 1987). It would be interesting to analyse the phenotype

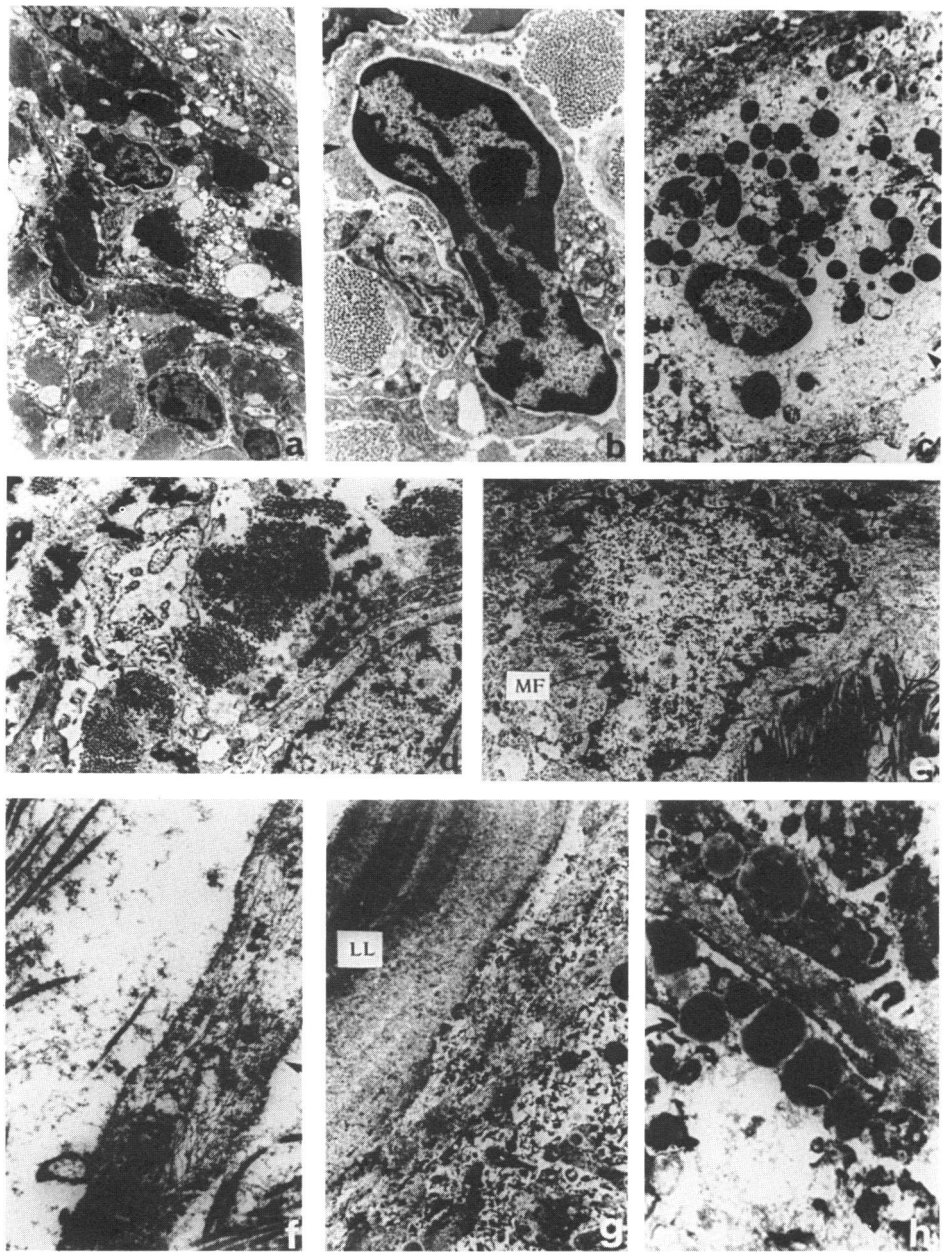

Fig. 2. Ultrastructural features of the granuloma surrounding parasitic vesicles in human alveolar echinococcosis. a, Relation between collagen bundles (*) and cells of the granuloma: macrophages, lymphocytes and fibroblasts (× 1900); b, Lymphocyte (arrow) (× 6500); c, Eosinophil (arrow) (× 5300); d, Fibroblast surrounded by collagen (*) and elastin (arrows) deposits (× 3600); e, Typical aspect of a myofibroblast (MF) (× 6500); f, Bundles of parallel fibrils in the cytoplasm of a myofibroblast (arrow) (× 12 000); g, The 'laminated layer' (LL) limiting an old parasitic vesicle, surrounded (and induced?) by cell necrosis (× 2000); and h, Fat-storing (Ito) cell remnants (arrow) inside necrosis and fibrosis in an acellular area of the parasitic lesions.

pattern of cells that constitute the periparasitic infiltrate in a higher number of such particular forms. In any case, the functional interpretation of our observations made using a phenotypic analysis of the cells is difficult: controversial results have been obtained when testing the functional properties of T cells in AE (Vuitton *et al.*, 1984; Bresson-Hadni *et al.*, 1989). However, functional tests using cells of the periparasitic granuloma should be done, in order to test the *in situ* functional properties of the $CD4^+$ and $CD8^+$ cells in both populations of patients, with active and abortive parasitic lesions, respectively. Preliminary results obtained in experimental murine AE support the T cell dependence of the resistance or sensitivity to infection by *E. multilocularis*.

Electron microscopic examination of the periparasitic granuloma confirmed the close association between the cells of the immune response and the collagen fibres and relatively low number of the cells identified as macrophages, using MoAbs. In fact, most of the cells described as 'histiocytes' with conventional stainings were myofibroblasts. This cell type has been shown to play an important role in fibrogenesis (Gabbiani,

1986), and to be present in hepatic schistosomal fibrosis which is also related to a granulomatous immune response against parasitic antigens (Grimaud & Borojevic, 1977). The role of cytokines in the proliferation of fibroblasts and regulation of collagen synthesis has been well demonstrated (Martinet & Crystal, 1987). The presence of myofibroblasts in the lesions of both AE and schistosomiasis suggest that the differentiation of fibroblasts into myofibroblasts may be mediated by factors originating from *in situ* activated cells of the immune system, and could be involved in the particular severity and irreversibility of the fibrosis in both diseases.

ACKNOWLEDGMENTS

We wish to thank Dr Jean-Paul Deschamps, Dr Jean-Alexis Grimaud and Professor Jean-Philippe Miguet for their help in this study, and Roslyn Young and Chantal Rollier for the preparation of the manuscript. We would like to express our gratitude to the patients and nursing staff without whom this study would not have been possible.

This work was supported by the Institut National pour la Santé et la Recherche Médicale (Grant no. 853009).

REFERENCES

ABO, T. & BALCH, C.M. (1981) A differentiation antigen of human NK and K cells identified by a monoclonal antibodies (HNK-1). *J. Immunol.* **127**, 1024.

ALI-KHAN, Z. (1974) Host parasite relationship in echinococcosis. I. Parasite biomass and antibody response in three strains of inbred mice against graded doses of *Echinococcus multilocularis* cysts. *J. Parasitol.* **60**, 231.

ALI-KHAN, Z. (1978) *Echinococcus multilocularis*: cell-mediated immune response in early and chronic alveolar murine echinococcosis. *Exp. Parasitol.* **46**, 157.

ATTALAH, A.M., LEWIS, F.A., URRITA-SHAW, A., FOLKS, T. & YEATMAN, T.J. (1980) Natural Killer (NK) and antibody-dependent cell-mediated cytotoxicity (ADC) components of *Schistosoma mansoni* infection. *Int. Arch. Allergy appl. Immunol.* **63**, 351.

BARNABA, V., MUSICA, A., CORDOVA, C., LEVRERO, M., RUOCCO, G., ALBERTINI-PETRONI, V. & BALSANO, F. (1983) Relationship between T cell subsets and suppressor cell activity in chronic hepatitis B virus (HBV) infection. *Clin. exp. Immunol.* **53**, 281.

BARON, R.W. & TANNER, C.E. (1976) The effects of immunosuppression on secondary *Echinococcus multilocularis* infection in mice. *Int. J. Parasitol.* **6**, 37.

BÖYUM, A. (1966) Separation of leukocytes from blood and bone-marrow. *Scand. J. clin. Lab. Invest.* **21**, (Suppl. 97), 77.

BRESSON-HADNI, S., MIGUET, J.P., VUITTON, D., MEYER, J.P., BECKER, M.C., DIDIER, D., COCHE, G., WEILL, F., CARBILLET, J.P., LANDECY, G., MANTION, G. & GILLET, M. (1988) L'échinococcose alvéolaire hépatique humaine. Revue générale à propos de quatre vingt cas *Sem. Hop. Paris*, **64**, 2691.

BRESSON-HADNI, S., VUITTON, D.A., LENYS, D., LIANCE. M. RACADOT, E. & MIGUET, J.P. (1989) Cellular immune response in *Echinococcus multilocularis* infection in humans. I. Lymphocyte reactivity to *Echinococcus* antigens in patients with alveolar echinococcosis. *Clin. exp. Immunol.* **77**, 61.

CAPRON, A., YARZABAL, L., VERNES, A. & FRUIT, J. (1970) Le diagnostic immunologique de l'échinococcose humaine. Bilan personnel à propos de 400 observations. *Pathol. Biol (Paris)* **18**, 357.

COLLEY, D.G., KATZ, N., ROCHA, R.S., ABRANTES, W., DA SILVA, A.L. & GAZINELLI, G. (1983) Immune response during human schistosomiasis mansoni. IX. T-lymphocyte subset analysis by monoclonal antibodies in hepatosplenic disease. *Scand. J. Immunol.* **17**, 287.

DELATTRE, P., PASCAL, M., LE PESTEUR, M.H., GIRAUDOUX, P., & DAMANGE, P. (1988) Caractéristiques ecologiques et épidémiologiques d*Échinococcus multilocularis* Leuckart dans un paysage de moyenne montagne. Analyse du cycle complet d'un hôte intermédiaire (*Microtus arvalis*). *Can. J. Zool.* **66**, 2740.

GABBIANI, G. (1986) Cytoskeletal and cytocontractile features of myofibroblasts. In *Marker Proteins in Inflammation* (ed. by J. Bienvenu, J. Grimaud & P. Laurent) p. 375. Walter de Gruyter, Berlin.

GASTL, G.A., FELDMEIER, H., DOEHRING, E., KORTMAN, C., DAFFALLA, A.A. & PETER, H.H. (1984) Numerical and functional alterations of lymphocytes in human schistosomiasis. *Scand. J. Immunol.* **19**, 469.

GOTTSTEIN, B., ECKERT, J. & FEY, H. (1983) Serological differenciation between *Echinococcus granulosus* and *E. multilocularis* infections in man. *Z. Parazitenkd.* **69**, 347.

GRIMAUD, J.A. & BOROJEVIC, R. (1977) Myofibroblasts in hepatic schistosomal fibrosis. *Experientia*, **33**, 890.

HATCHER, F.M. & KUHN, R.E. (1982) Destruction of *Trypanosoma cruzi* by natural killer cells. *Science*, **218**, 295.

HERBERMAN, R.B. (1983) Possible role of natural killer cells in host resistance against tumours and other diseases. *Clin. Immunol. Rev.* **1**, 1.

HOMBERG, L.A., SPRINGER, T.A. & AULT, K.A. (1981) Natural killer activity in the peritoneal exudates of mice infected with *Listeria monocytogenes*: characterization of the natural killer cells by using a monoclonal rat anti-murine macrophage antibody (M1/70). *J. Immunol.* **127**, 1792.

KAISERLIAN D., SAVINO, W. & BACH, J.F. (1983) Studies of the thymus in mice bearing the Lewis lung carcinoma. I. Thymic natural killer cell activity in 3 LL tumor-bearing mice. *Cell. Immunol.* **80**, 187.

LAROCHE, L. & BACH, J.F. (1981) T-cell imbalance in nonleukemic and leukemic cutaneous lymphoma defined by monoclonal antibodies. *Clin. Immunol. Immunopathol.* **20**, 278.

LIANCE, M., VUITTON, D., GUERRET-STOCKER, S., CARBILLET, J.P., GRIMAUD J.A. & HOUIN, R. (1984) Experimental alveolar echinococcosis. Suitability of a murine model of intrahepatic infection by *Echinococcus multilocularis* for immunological studies. *Experientia*, **40**, 1436.

LUKASHENKO, N.P. (1968) Comparative biologic and pathologic studies of *Alveococcus multilocularis*. *Arch. Environ. Health*, **17**, 676.

MARTINET, Y. & CRYSTAL, R.G. (1987) Pathogenesis of tissue fibrosis: inflammatory cell modulation of mesenchymal cell accumulation. In *Tissue Fibrosis: Immune Cells and Mediators* (ed. by J.P. Revillard & N. Wierzbicki) p. 13, Fondatino Franco-Allemande, Suresnes.

MONTANO, L., ARANGUIBEL, F., BOFFILL, M., GOODALL, A., JANOSSY, G. & THOMAS, H.C. (1983) An analysis of the composition of the inflammatory infiltrate in autoimmune and hepatitis B virus-induced chronic liver disease. *Hepatology*, **3**, 292.

RAU, M.E. & TANNER, C.E. (1975) BCG suppresses growth and metastasis of hydatid infections. *Nature*, **256**, 318.

RAUSCH, R.L., WILSON, J.F., SCHANTZ, P.M. & MAHON, B.J. (1987) Spontaneous death of *Echinococcus multilocularis*: cases diagnosed serologically (by Em 2-ELISA) and clinical significance. *Am. J. trop. Med. Hyg.* **36**, 576.

SEMENZATO, G., PEZZUTTO, A , CHILOSI, M. & PIZZOLO, G. (1982) Redistribution of T-lymphocytes in the lymph nodes of patients with sarcoidosis. *N. Engl. J. Med.* **306**, 48.

SHIRATSUCHI, H. & TSUYUGUCHI, I. (1984) Analysis of T-cell subsets by monoclonal antibodies in patients with tuberculosis after *in vitro* stimulation with PPD. *Clin. exp. Immunol.* **57**, 271.

SIBBIT, W.L., FROELICH, C.J. & BANKHURST, A.D. (1983) Natural cytotoxicity in systemic lupus erythematosus: mechanisms of suppression by inhibitory serum factors. *Clin. exp. Immunol.* **53**, 363.

VUITTON, D.A., GUERRET-STOCKER, S., CARBILLET, J.P., MANTION, G., MIGUET, J.P. & GRIMAUD, J.A. (1986) Collagen immunotyping of the

hepatic fibrosis in human alveolar echinococcosis. *Z. Parasitenkd.* **72,** 97.

VUITTON, D.A., LASSÉGUE, A., MIGUET, J.P., HERVÉ, P., BARALE, T., SEILLES, E. & CAPRON, A. (1984) Humoral and cellular immunity in patients with hepatic alveolar echinococcosis. A 2 years follow-up with and without flubendazole treatment. *Parasite Immunol.* **6,** 329.

WILSON, J.F. & RAUSCH, R.L. (1980) Alveolar hydatid disease. A review of clinical features of 33 indigenous cases of *Echinococcus multilocularis* infection in alaskan eskimos. *Am. J. trop. Med. Hyg.* **29.** 1340.

WOLFE, S.A., TRACEY, D.E. & HENNEY, C.S. (1977) BCG-induced murine effector cells II. Characterization of natural killer cells in peritoneal exudates. *J. Immunol.* **119,** 1154.