Lateral Thoracic Radiographs

Evaluation of Their Use as a Routine Procedure In Roentgen Examination of the Chest

DENIS C. ADLER, *M.D.*, WALTER L. STILSON, *M.D.*, and KITMAN AU, *M.D.*, Los Angeles

• A thousand cases of consecutive radiographic examinations of the chest, consisting of postero-anterior and left lateral views, were reviewed.

In seven cases (0.7 per cent) the lateral view revealed clinically significant lesions which were not seen on the postero-anterior view.

In 30 cases (3 per cent) the lateral view demonstrated clinically significant added information permitting more definite diagnosis.

Addition of the lateral view to the routine roentgen study of the chest gives a more thorough and complete examination at minimal expense and permits a more definite diagnosis in a significant number of cases.

ROENTGEN EXAMINATION of the chest in the lateral projection is a generally accepted procedure in selected abnormal cases. In evaluating a pathological process seen on the postero-anterior film of the chest, an additional lateral view is often made to obtain added information about the lesion. The need for an additional lateral film is also accepted by some radiologists in cases in which disease of the lung is strongly suspected but no abnormality is visible in the postero-anterior film.

There are certain basic anatomical facts which would indicate the value of the lateral film as a routine procedure. In the postero-anterior view a large portion of the posterior part of the lower lungs is hidden by the diaphragm, and on the left side a portion of the lung is covered by the heart. The mediastinum, spine and retrosternal area are obscured by superimposition. All these areas are separately visible on a lateral roentgenogram (Figure 1).

This concept of the value of the lateral view is by no means new. In 1928, Brown and Weiss[1] considered that lesions behind the heart that were missed on the postero-anterior view would be visible on the lateral view and that even if seen on the postero-anterior view the exact location and probable nature of a lesion might be better determined by the lateral projection. In 1930, Warfield[2] stated: "Obscure pathology in the base of either lung field is best studied in the lateral view. . . . Lesions behind the heart are practically always missed in the ordinary postero-anterior chest film." Although many investigators advocate the lateral roentgenogram as a special diagnostic procedure, so far as could be determined there is in the English literature no evaluation of its routine use.

In an attempt to make such an evaluation, the authors reviewed the films that had been taken in a thousand consecutive examinations of the chest. The patients were either ambulatory patients observed in clinic or patients in the hospital for whom x-ray films of the chest were requested. The examinations were divided into four classes: (1) Those in which there were clinically significant findings on the lateral view that were not seen at all on the postero-anterior film, were classified as 3 plus. (2) Those in which there was some indication of a lesion on postero-anterior film, but in which the lateral gave added information of definite clinical significance, were classified as 2 plus. (3) Those in which the lateral gave added anatomical information which was considered of no definite clinical significance were classified as 1 plus. (4) Those in which the lateral view gave no added information were classified as zero.

Specifically excluded from classification were incidental lesions of the chest wall, spine or mediastinum. A lateral film will demonstrate a pathological process of those areas, but since specific examina-

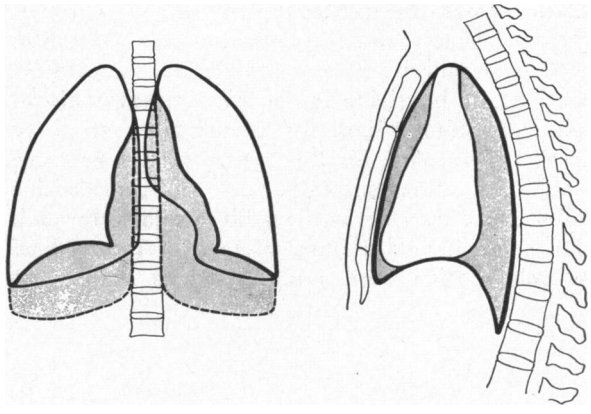

Figure 1.—Note that the shaded areas of the lungs would be visible only on the lateral view.

Presented before the Section on Radiology at the 84th Annual Session of the California Medical Association, San Francisco, May 1-4, 1955.

From the Department of Radiology, College of Medical Evangelists, Los Angeles 33.

tions to visualize them would probably be made when indicated, these incidental findings were not considered in evaluation of the lateral film as a routine procedure.

In the study it was noted that the appearance of the retrosternal anterior costophrenic sinus was extremely variable, which the authors are at present unable to evaluate. Further radiological anatomical correlation seems necessary (Figure 2).

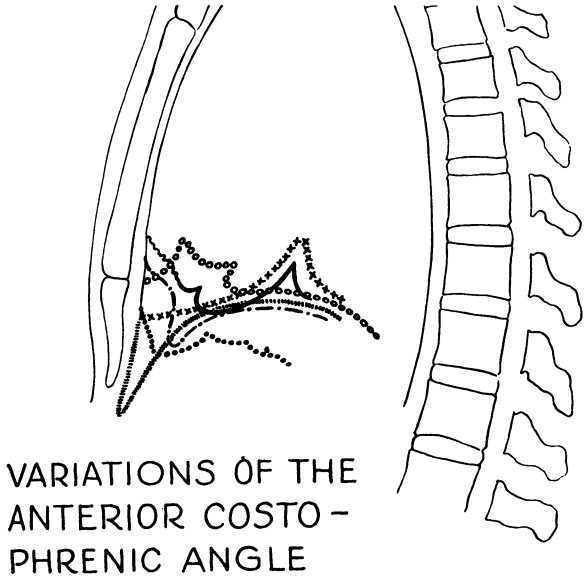

Figure 2.—The pleural reflection of the anterior costophrenic sinus varies greatly in clinically asymptomatic individuals. This figure shows a number of representative tracings.

Seven of the thousand cases in the series (0.7 per cent) were in the 3 plus group. In three of the patients the lesion was obscured on the postero-anterior roentgenogram by the diaphragm (Figure 3). The side of involvement could be determined only by clinical evidence. In two other patients the heart covered the lesion on the postero-anterior film (Figure 4). In one patient the disease was hidden by the mediastinum or hilum, and in one a middle lobe consolidation was obscured on the postero-anterior film by the overlying breast.

(There were two additional cases in which definite radiological changes were seen on the lateral but not on the postero-anterior view. These cases are excluded from the classification because the histories were not available and, therefore, the significance of the shadows could not be determined.)

Thirty cases (3.0 per cent) were classified in the 2 plus group. The largest subgroup of these 2 plus cases was made up of cases in which a pathological process was suspected in the lung bases on the postero-anterior radiograph. A lateral view in this group served to show in some cases that there was no lesion and in other cases to demonstrate the lesion conclusively. Hazy shadows at the left base in two asymptomatic cases of this group were not present on the lateral view, which thereby diminished suspicion of a lesion. In a group of nine cases

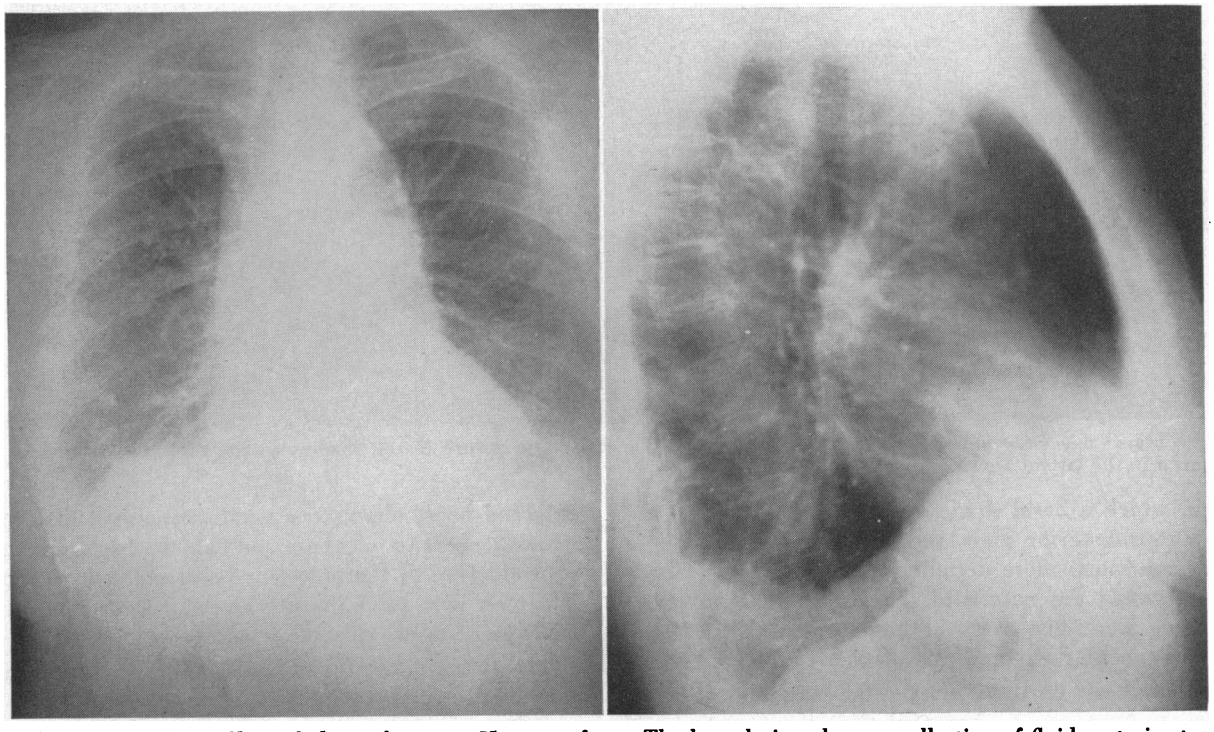

Figure 3.—X-ray films of chest of woman 75 years of age. The lateral view shows a collection of fluid posterior to the dome of the diaphragm which obviously would not be visible on the postero-anterior view.

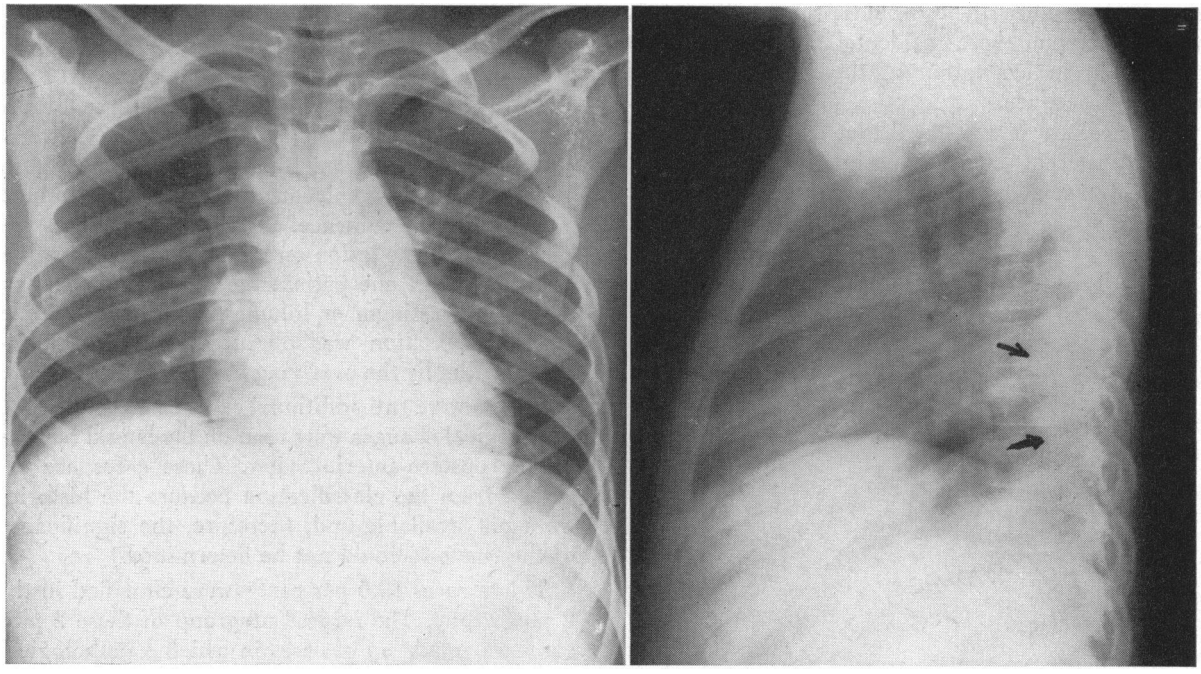

Figure 4.—X-ray films of chest of boy, aged 10 years. Posterior encapsulation of effusion seen on the lateral view only, probably hidden by the heart on the postero-anterior radiograph.

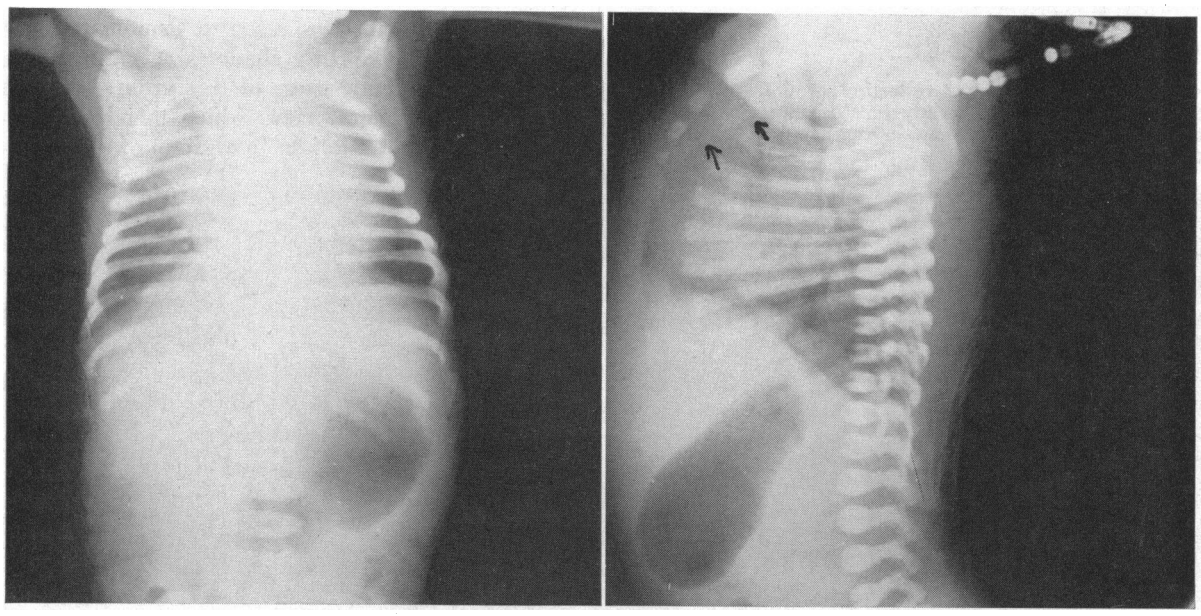

Figure 5.—X-ray films of chest of five-day-old boy. The atelectatic nature of the shadow in the right upper lobe is seen in the lateral view.

in which a basal shadow was demonstrated on the postero-anterior view, the lateral view showed the lesion much more definitely and in some instances suggested the nature of the lesion. In this group there were five cases of basal pneumonitis, three of bronchiectasis and one of pleural thickening.

The heart partially masked the pathological process in three cases—bronchiectasis in one case and pneumonitis in another; and the third case a greatly enlarged heart obscured a small amount of pleural effusion. In two of these patients in early life a consolidation of the posterior basal segment of the left lower lobe was only seen on the postero-anterior chest film because of inadvertent overpenetration.

The authors have found the lateral view helpful in examination of patients with hilar prominence, especially when it is unilateral. In some of these cases a slight rotation of the patient's chest may account

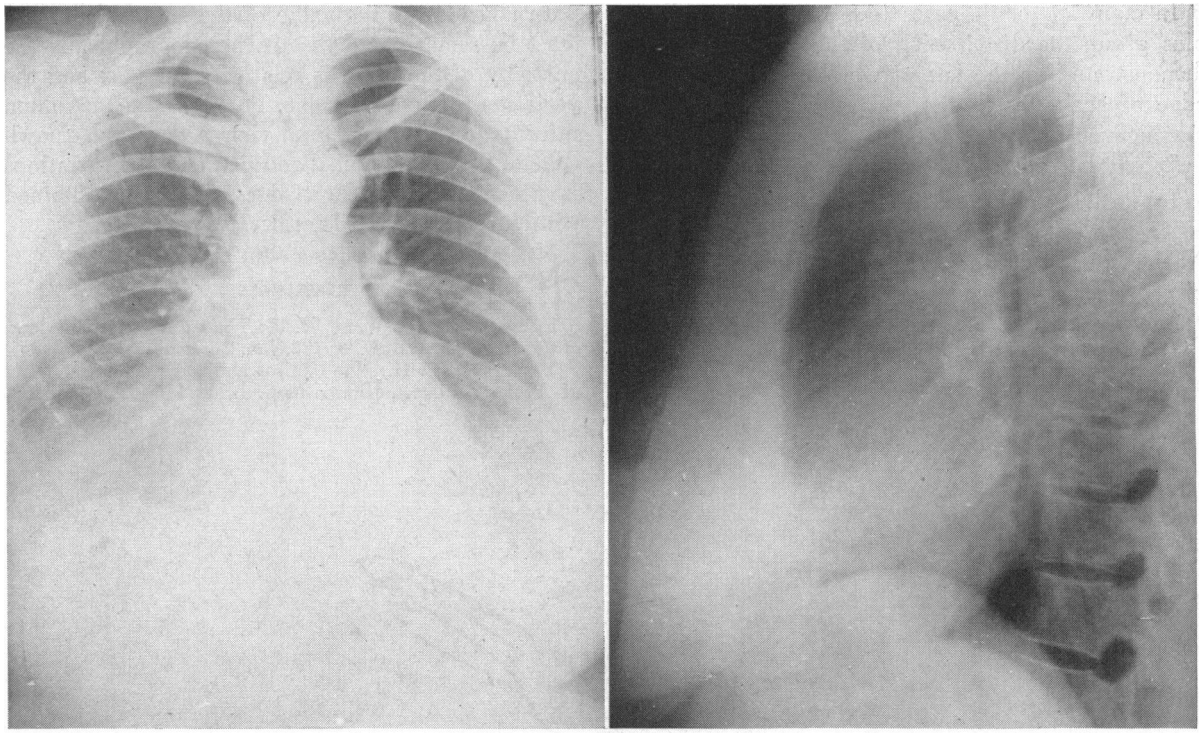

Figure 6.—X-ray films of chest of woman 43 years of age. The lung bases obscured in the postero-anterior view by the heavy breasts are demonstrated to be clear on the lateral projection.

for the unilateral prominence resembling bronchogenic carcinoma. The lateral view is frequently helpful in the anatomical evaluation of these changes. There were five such cases in the present series.

The rest of the 2 plus group had lesions in various areas of the lung. In all of these cases analysis of the lateral view permitted a more definite diagnosis, principally through the additional anatomical information as to whether the shadows were pulmonary or pleural and whether there was any interlobar pleural involvement.

There were two cases of pneumonia resembling fluid and one of pneumonia resembling a mediastinal mass. Three cases of encapsulated fluid and two of atelectasis resembled pneumonia (see Figure 5). In all of these the lateral view revealed the true nature of the lesion.

In one patient with pulmonary infarction the shadow was seen on the postero-anterior film but the characteristic triangular appearance with wide base on the interlobar pleura was seen only on the lateral view. Likewise, the lateral view demonstrated clearly, in a case of achalasia, the shadow of the widened esophagus located in the posterior mediastinum.

Forty-eight cases (4.8 per cent) were classified as 1 plus. In 35 of them the lateral view gave information on anatomical distribution of the pathological process which was not available on the postero-anterior view. In most of these cases the disease was pneumonia, in several it was bronchiectasis and in a few cases tuberculosis and pleural disease.

In nine cases in the 1 plus group the lateral view demonstrated anatomical information which could not be obtained from the postero-anterior film. In most of these cases the lesion was thickened pleura. In one case of unusual interest the postero-anterior film showed calcification in the lower left lung field and the lateral view showed it to be actually in the breast. A large breast shadow obscured the lung base in four cases and the clearness of the lower lung as seen on the lateral film gave assurance that no underlying pathological process was missed (Figure 6).

The 0.7 per cent of cases classified in the 3 plus group may not appear impressive, but it must be considered that a pathological process was diagnosed in these cases through the addition of a single radiograph and without significant added effort or expense. This compares rather favorably with the yield of other routine diagnostic procedures.

As to the 2 plus group, which made up 3 per cent of the series, it is noteworthy that these patients were dismissed from the Department of Radiology with a rather complete radiological diagnosis and the need of recalling them for additional studies was avoided. It must be realized that the expense of recalling a patient is considerable and the effort is not always successful.

In many of the 48 cases (4.8 per cent) in the 1 plus group the distribution of the lesion was well demonstrated on the lateral view. Although knowledge of such distribution might be of no clinical significance in a disease like pneumonia, it would definitely be valuable in bronchiectasis.

In evaluation of the series of 1,000 cases an attempt was made to avoid controversial diagnosis. In the opinion of some observers, the lateral view gives considerable information regarding chronic pulmonary emphysema. In recognition of the controversial nature of such an interpretation, it was avoided.

In considering the value of the routine lateral it must be remembered that roentgenographically the anatomy of the chest is relatively complex and the variations are considerable. To obtain the maximum information from a lateral view a thorough knowledge of these anatomical and pathological variations is necessary. The knowledge cannot be obtained without utilizing the lateral view routinely.

2010 Wilshire Boulevard, Los Angeles 57.

REFERENCES
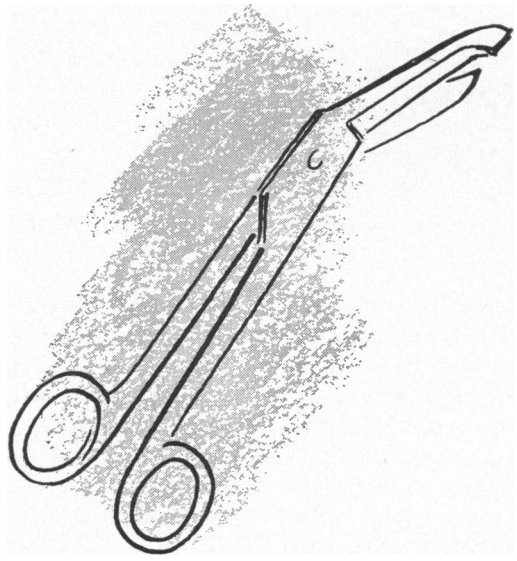
1. Brown, S., and Weiss, H. B.: The value of lateral views of the thorax, J.A.M.A., 90:187, Jan. 21, 1928.
2. Warfield, C. H.: The clinical and roentgenologist value of the lateral chest, Illinois Med. J., 58:461-463, Dec. 1930.