Pain in the Neck and Arm

Diagnosis by History and Examination

RENE CAILLIET, M.D., *Los Angeles*

■ *The cause of pain in the neck or pain in the arm coming from the neck can be accurately diagnosed by proper clinical examination. This requires knowledge of normal functional anatomy and understanding where pain can originate and what factors initiate the pain. The examination consists of testing for these abnormalities of motion and reproducing the symptoms by these motions.*

Weighing the history, both of trauma and indications of deep-seated tension or anxiety, against the conditions observed on physical examination, is important to correct diagnosis.

Recognizing abnormal neck posture and activities reproducing pain in the neck and arm examination reveals the mechanism of pain. Treatment becomes evident.

A BASIC KNOWLEDGE of functional anatomy is required for the proper diagnosis and treatment of pain in the neck or in the arm originating in the neck. The examination must recognize the faulty function and the symptoms must be correlated with this abnormality. If the characteristic pain can be reproduced by a position or a movement and the exact nature of that position or movement is understood, the mechanism of pain production can then be appreciated.[1]

The cervical spine is an aggregate of superimposed functional units, with all units from the second cervical vertebra down to the first thoracic being similar one to another. A functional unit consists of two vertebral bodies separated by an intervertebral disk. This is the anterior weight-bearing part. The disks are wider anteriorly than posteriorly and are responsible for the lordotic shape of the cervical spine.[4] The disks are compressible and permit flexion, extension, lateral flexion and rotation of the neck.

The posterior portion of the functional unit consists of the pedicles, lamina, the transverse and posterior processes and the posterior articulations. These articulations are not primarily weight-bearing but act in a gliding manner to direct and limit the extent of neck motion.

The intervertebral foramen is bounded anteriorly by the posterior border of the disk annulus, the posterior longitudinal ligament, and the uncovertebral joints of von Luschka. The superior and inferior margins of the foramen are formed by the pedicles, and the posterior margin by the posterior articulations (facets). Through this foramen passes the spinal root (Figure 1). As the nerve root together with its sleeve of dura and arachnoid enters and passes through the intervertebral foramen, it is accompanied by small blood vessels and sympathetic nerves. The nerve root and its dural sleeve

Chairman's Address: Presented before the Section on Physical Medicine at the 96th Annual Meeting of the California Medical Association, April 15 to 19, 1967.

Reprint requests to: 4900 Sunset Boulevard, Los Angeles 90027.

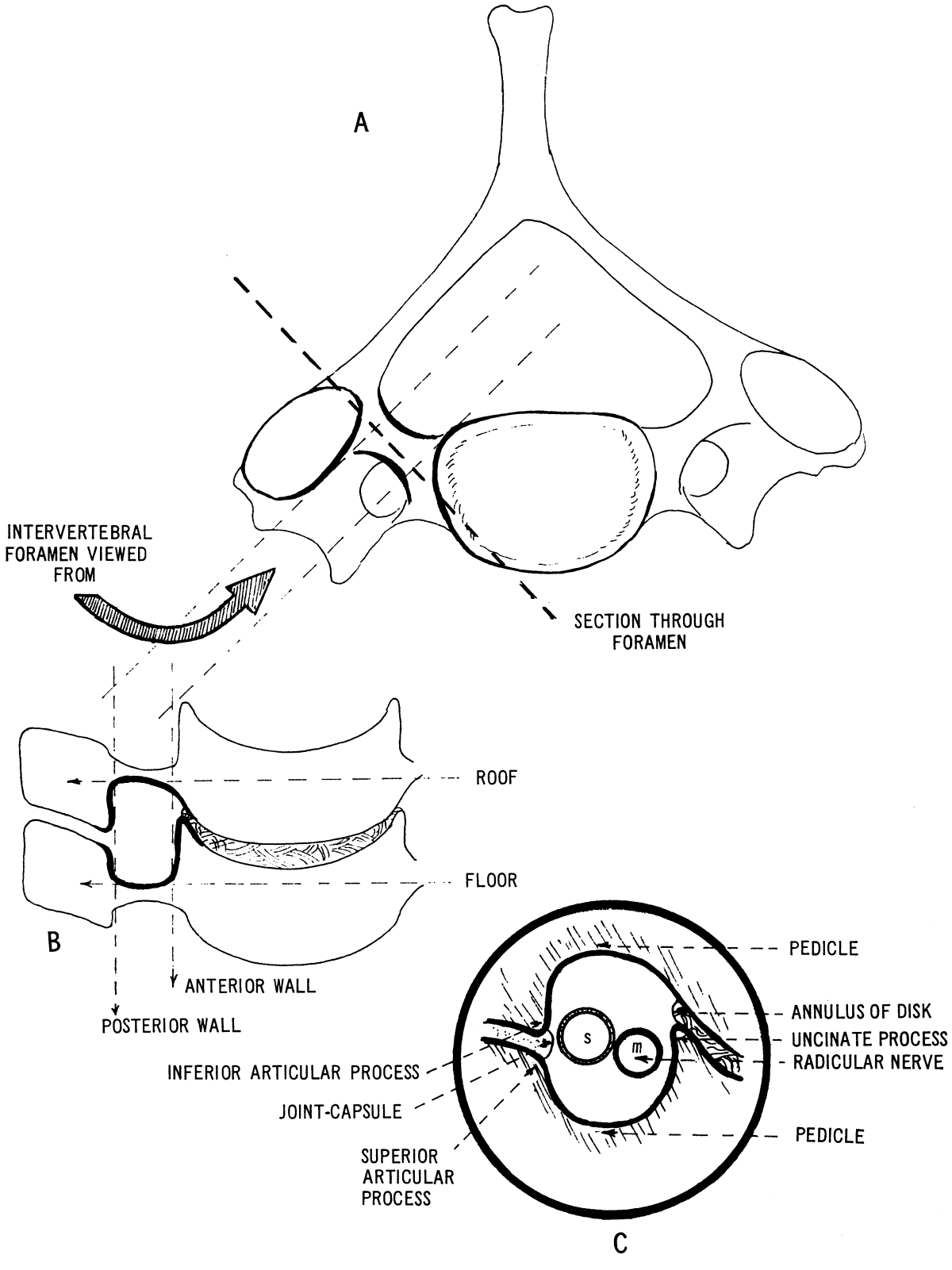

Figure 1.—Anatomical boundaries of the intervertebral foramen. As viewed from outside (arrow in A) the boundaries are shown in B. The relationship of the sensory (s) and motor (m) root components to the foramen are shown in C.

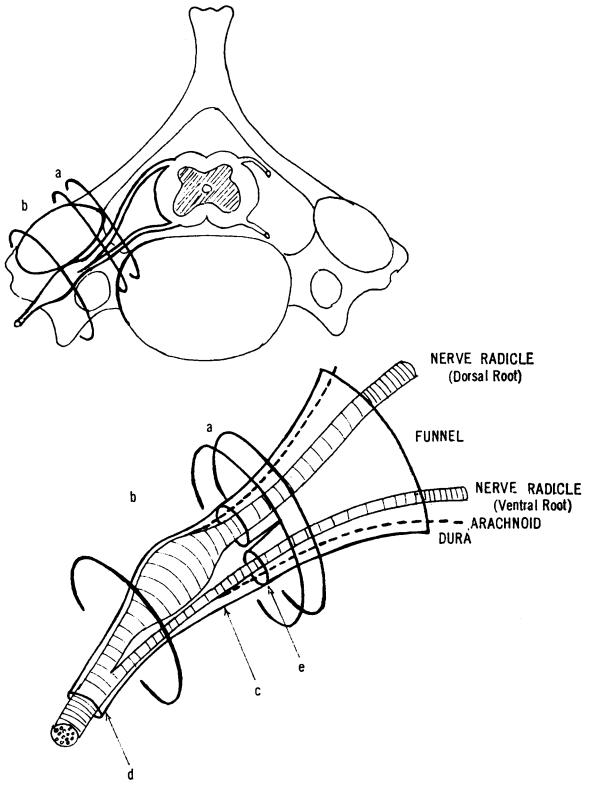

Figure 2.—The root "sleeve" in the intervertebral canal: A is the intervertebral foramen, B the gutter of the transverse process, C the termination of the attachment of the arachnoid.

(Figure 2) fill nearly half of the foramen and thus the root is susceptible to compression and inflammation if there is any impingement upon or narrowing of the foramen.[3]

Movement of the cervical spine below the second cervical vertebra is that of gliding, in which the second glides upon the third, the third upon the fourth, and so on.[8] As the spine flexes forward, the posterior facets separate and the foramina open (Figure 3). As the neck extends the foramina narrow. Rotation of the neck closes the foramen on the side toward which the head turns and opens them on the other side. External rotation and lateral flexion, as well as extension, are motions which may compress the nerve root where it passes through its foramen.

The spinal nerves are formed by numerous fila that merge into the roots which become enclosed in a dural sleeve.[3] The nerve emerges in the interspace above its similarly numbered vertebra with the exception of the eighth cervical which emerges above first thoracic. Each nerve has a specific motor and sensory function in the head, neck and upper extremity.

Figure 3.—"Gliding" motion of the cervical vertebrae. Motion of the third cervical through the seventh vertebra occurs by forward gliding in flexion and backward gliding on extension. Flexion (B) opens the intervertebral foramen.

The first two vertebrae are not structurally or functionally similar to the other functional units of the neck. There is no disk and no posterior facets between the occiput and the first cervical vertebra (atlas) nor between the first and second (axis). Therefore, the nerves that emerge at these levels do not pass through intervertebral foramina. They also do not innervate any sensory or motor component of the upper extremity. Their function is mostly sensory to the scalp and face. They are often involved in headaches which are caused by cervical tension in which they are irritated by muscular entrapment rather than by foraminal entrapment.

The movement of the occiput upon the atlas is one of slight flexion and extension as in a "nodding" motion of approximately 30°. No rotation or lateral flexion occurs at this joint. Motion between the atlas and the axis is one of rotation of 45° to either side and slight flexion-extension. In the absence of motion below the second cervical vertebra, the head is able to flex and extend 45° and to rotate 90°. This amount of motion remains in the severly fused neck of Marie-Strümpell spondylitis. The composite of motion possible in the cervical spine is illustrated in Figure 4.

Pain felt in the neck and in the arm originating in the neck has been attributed to arthritis and trauma. This may be a true assumption but it is more correct to attribute the cause of pain to encroachment on space and impairment of movement.

The tissues within the functional unit that are pain-sensitive are the posterior longitudinal ligament, the nerve root and its dural sleeve, and the posterior articular facets. All of these are in the region of the intervertebral foramen. The mechanism of pain production must therefore reside in abnormalities occurring here.

Disk herniation will encroach upon the posterior

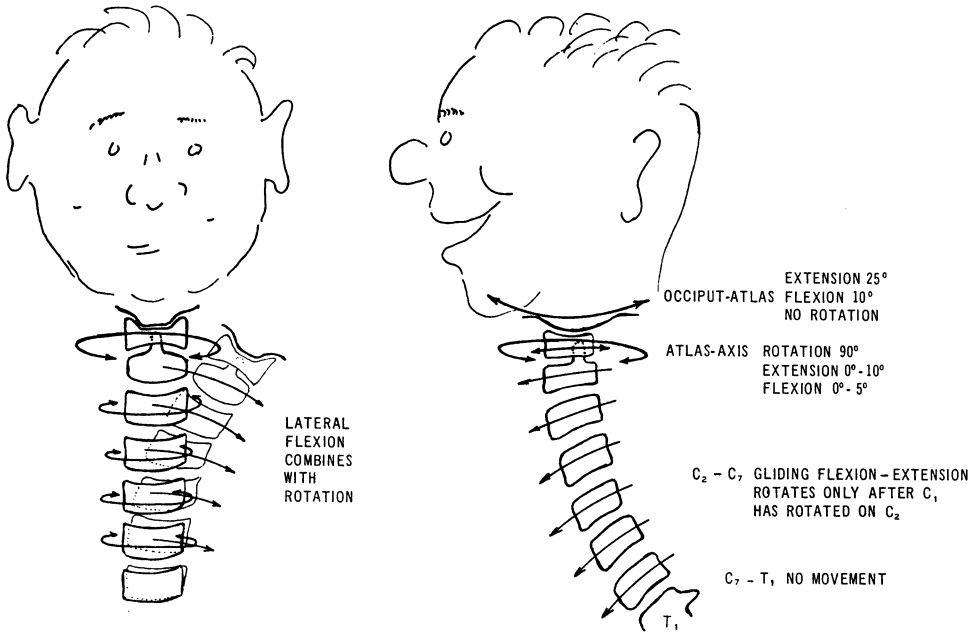

Figure 4.—Composite movements of the cervical spine.

longitudinal ligament or the nerve root and its sleeve, or on both. Degenerative disk disease will narrow the intervertebral space and thus decrease the foraminal opening.[6,11] Cervical spondylosis, so-called degenerative arthritis, encroaches on the foramen. Trauma may overstretch the supporting ligaments and cause excessive mobility and thus cause irritation of its enclosed tissues. Hyperextension of the neck from bad posture or from a position necessary in one's occupation may cause weight-bearing on the posterior articulations, which which in turn may cause synovitis or degenerative changes in the facets. History and examination of the patient will reveal the offending factors.

History and Examination

The history will elicit the activities or trauma or postures which initiated the pain and which will reproduce it.[7] The examination consists of determining the restriction of motion, the evaluation of the nerve roots involved and the reproduction of the painful symptoms by passive movement and positioning of the head and neck.

The examination begins with a viewing of the patient's posture. A "rounded" shoulder posture, excessive dorsal kyphosis or a "forward head" posture will cause an increase in the cervical lordosis. This attitude of the neck will approximate the posterior facets which may cause pain or may narrow the foramen and cause nerve root impingement. If this foraminal closure is repeated and aggravated by physical or emotional tension, the nerve roots and their sleeves become inflamed and swollen and they then occupy a greater portion of the already narrowed foramen. The nerve becomes edematous and engorged and pain occurs both in the neck and its place of referral, usually around the shoulder. Paresthesia and hypasthesia may be felt in the hand and arm.

The "tense person" — tense from emotional causes or physical postural fatigue — will have the erector spinae muscles in a state of sustained hypertonus. The muscles become painful and tender, the myofascial attachment to the occiput becomes painful and the entrapped greater superior occipital nerve becomes inflamed. Occipital vertex headaches supplement the cervical tension symptoms. Examination of patients of this kind will reveal the signs of deep-seated tension or anxiety. The neck does not move freely in any direction, and diffuse tenderness of all the neck muscles is palpable.

In post-traumatic sprain, as elicited by the history, the same "guarding" of neck motion will be noted. The spasm of the neck muscles will alter the curve of the cervical spine and will be seen roentgenographically as a "straightening." Initially, it is difficult to differentiate from the "tension" state, except for the history of trauma. When the patient is seen soon after the traumatic incident, especially

when the stress involved caused hyperextension of the neck, a reflex weakness of the neck flexors may be noted, with the patient unable to lift his head from the bed or examining table.[9] Ultimately in the post-traumatic sprain the limitation of motion persists only in extension and flexion, whereas in the emotional cervical "tension" state, motion in any direction is limited.

Pain may be referred from the neck into the shoulder area and the upper extremities. It consists of interscapular pain or of paresthesia into the arm, hand and fingers. As the encroachment on the nerve occurs in the foramen, specific neck movements should reproduce the symptoms. Neck extension and rotation of the neck toward the involved side will close the foramen there. This motion thus compresses the entrapped nerve and should reproduce the symptoms in the arm, hand and fingers. If a protrusion of an intervertebral disk is suspected, flexion may cause an aggravation of the symptoms by placing traction upon the nerve.

The cutaneous area supplied by a single nerve root is known as a dermatome. The pain or paresthesia claimed by the patient is referred to the specific dermatome.[5] The group of muscles supplied by a single nerve root is known as a myotome. The clinical examination of the upper extremity by evoking deep tendon reflex and by muscle testing reveals the specific nerve root and differentiates the lesion as a root envolvement rather than a peripheral nerve lesion.[6]

The most frequently involved nerve roots are the sixth, seventh and eighth cervicals since the greatest motion and greatest degree of disk degeneration occurs between the fifth and sixth and the sixth and seventh. Encroachment upon the sixth cervical nerve root will cause paresthesia and hypasthesia of the thumb and index finger, weakness of the biceps muscle and reduction of the biceps jerk. Pain may be referred to the interscapular and shoulder area. Pressure on the seventh cervical nerve root will cause sensory changes of the index and middle finger, weakness of the triceps and depression of the triceps tendon reflex. Similar encroachment on the eighth nerve will bring about sensory changes in the little finger but there will be no reflex changes and whatever muscular weakness there is will be in the small muscles of the hand.

Clinical examination based on concepts of functional anatomy can reveal the pathological mechanism by which pain is caused. Roentgenograms, studies with contrast medium (Pantopaque®) and other tests such as electromyography can merely confirm the clinical impression.

Treatment

Treatment based on functional anatomical and physiological concepts can be directed toward alleviating the offending mechanisms.[10] Immobilization to permit abatement of ligamentous strain, muscle spasm or nerve root entrapment must place the neck in slight flexion. This position separates the posterior facets and opens the foramen. Posture training in daily living and in occupational situations must keep this concept in mind. Traction, to be effective, must also flex the spine rather than attempt merely to distract the vertebrae.[2] Exercise must have a specific intent. Active motion when the entrapped nerve is edematous and fills the greater portion of the foramen must be avoided. Ultimately exercise must increase range of motion but it must always be done with the neck in the slightly flexed neutral position.

Whatever pathologic changes may have taken place in the cervical spine as a result of degenerative changes called "arthritis," will remain. The symptoms caused by trauma, whether from sudden injury, from bad posture or from emotional stress to the neck, can be relieved.

Figures are reproduced from: Neck and Arm Pain, R. Cailliet, F. A. Davis Company, Philadelphia 1964.

REFERENCES

1. Cailliet, R.: Neck and Arm Pain, F. A. Davis Company, Philadelphia, 1964.
2. Colachis, S. C., and Strohm, B. R.: A study of tractive forces and angle of pull on vertebral interspaces in the cervical spine, Arch. Phys. Med. and Rehab., 46:820-830, Dec. 1965.
3. Frykholm, R.: Cervical Nerve Root Compression Resulting from Disc Degeneration and Root Sleeve Fibrosis; A Clinical Investigation, Acta Chir. Scandinav., Supp. 160, 1951.
4. Hadley, L. A.: The Spine: Anatomica-Radiographic Studies, Development and the Cervical Region, Charles C Thomas, Springfield, Ill., 1956.
5. Haymaker, W., and Woodhall, B.: Peripheral Nerve Injuries, 2nd Ed., W. B. Saunders Co., Philadelphia, 1953.
6. Holt, S., and Yates, P. O.: Cervical spondylosis and nerve root lesions, J. Bone and Joint Surg., 48-B: No. 3, 407-423, Aug. 1966.
7. Jackson, R.: Cervical Syndrome, Charles C Thomas, Springfield, Ill., 1958.
8. Jones, M. D.: Cineradiographic studies of the normal cervical spine, Cal. Med., 93:293-296, Nov. 1960.
9. Krout, R. M., and Anderson, T. P.: Role of anterior cervical muscles in production of neck pain, Arch. Phys. Med. and Rehab., 47:603-611, Sept. 1966.
10. Rubin, D.: Head, neck, and arm symptoms subsequent to neck injuries; physical therapeutic considerations, Arch. Phys. Med. and Rehab., 40:387-389, Sept. 1959.
11. Teng, P.: Spondylosis of the cervical spine with compression of the spinal cord and nerve roots, J. Bone and Joint Surg., 42-A:392-407, Apr. 1960.