Artificial Dermis for Major Burns

A Multi-Center Randomized Clinical Trial

DAVID HEIMBACH, M.D.,* ARNOLD LUTERMAN, M.D.,† JOHN BURKE, M.D.,‡ ALBERT CRAM, M.D.,§ DAVID HERNDON, M.D.,‖ JOHN HUNT, M.D.,¶ MARION JORDAN, M.D.,# WILLIAM McMANUS, M.D.,** LYNN SOLEM, M.D.,†† GLENN WARDEN, M.D.,‡‡ and BRUCE ZAWACKI, M.D.,§§

This communication presents an 11-center prospective randomized trial using the artificial dermis invented by Burke and Yannas. Patients with life-threatening burns who underwent primary excision and grafting within 7 days of injury had comparable sites randomized to receive either the artificial dermis (study site) or the investigator's usual skin grafting material (control site). Control materials were autograft, allograft, xenograft, or a synthetic dressing. Epidermal grafts were applied to the study site during a second operation, and surviving patients were followed for 1 year after grafting. One hundred thirty-nine sites on 106 patients were studied. Mean burn size was 46.5 ± 15% mean total body surface (TBSA). Overall mortality was 13%, and mean hospital stay was 68 ± 45 days. Median artificial dermis take was 80% compared with 95% for all comparative sites, but the take was equivalent to that of all nonautograft control materials. Results with the artificial dermis improved slightly as the investigators became more familiar with the material. Donor site thickness for the study site averaged .006″ ± .002″ compared to .013″ ± .018″ for control ($p < .0001$) and the epidermal donor site healed an average of 4 days sooner (10 ± 6 *vs.* 14 ± 8 days) ($p < .0001$). As the wounds matured during the first year, both patients and surgeons felt that both sites became more comparable in appearance and function. At the completion of the study, there was less hypertrophic scarring of the artificial dermis, and more patients preferred the artificial dermis to the control graft. Artificial dermis with an epidermal graft provides a permanent cover that is at least as satisfactory as currently available skin grafting techniques, and uses donor grafts that are thinner and donor sites that heal faster.

From the University of Washington, Seattle, Washington, the University of South Alabama, Mobile, Alabama,† Harvard University, Cambridge, Massachusetts,‡ the University of Iowa, Iowa City, Iowa,§ University of Texas at Galveston, Galveston, Texas,‖ the University of Texas at Dallas, Dallas, Texas,¶ George Washington University, Washington, D.C.,# US Army Institute of Surgical Research, San Antonio, Texas,** St. Paul-Ramsey,†† University of Cincinnati, Cincinnati, Ohio,‡‡ and the University of Southern California, Los Angeles, California§§*

EARLY EXCISION and grafting of burns in patients with major thermal injury has shortened hospital stay and decreased infectious complications.[1] Unfortunately survival has not been clearly improved by early excision in the patient with massive burns, because, although the burn can be removed, the patient does not have enough autologous skin to cover the resulting massive wounds. In 1981, Burke and Yannas published preliminary clinical results of the use of a bilayer "artificial skin" as a permanent wound cover after the excision and grafting of burns.[2] This communication presents the results of an 11-center clinical trial comparing this artificial dermis to conventional grafting techniques after the early excision of the burns of patients with major thermal injury.

Material and Methods

The artificial dermis is composed of a porous collagen-chondroitin 6-sulfate fibrillar mat covered with a thin sheet of silastic (Fig. 1). The details of manufacture are described by Burke and Yannas, who state, "the material is designed to contain physicochemical properties providing optimal 'wetting' and 'draping' properties, leading to elimination of dead space, surface adherence, control of bacterial invasion and fluid loss, while inducing cellular and vascular invasion, which would synthesize a dermal matrix while biodegrading the artificial implant".[2] The material used in this trial was manufac-

Presented at the 108th Annual Meeting of the American Surgical Association, San Francisco, California, May 2–4, 1988.

Supported in part by a grant from Marion Laboratories, Kansas City, MO.

Reprint requests and correspondence: David M. Heimbach, M.D., Department of Surgery ZA 16, Harborview Medical Center, 325 Ninth Avenue, Seattle, WA 98104.

Submitted for publication: May 5, 1988.

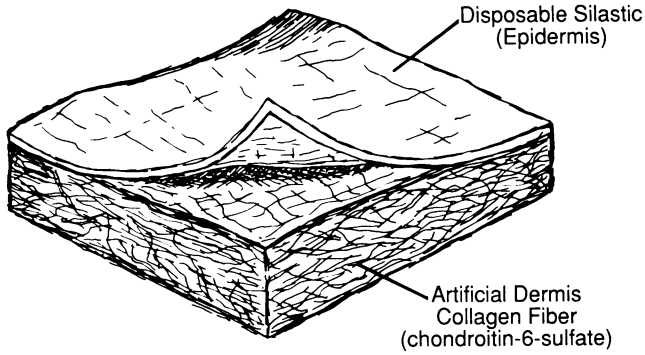

FIG. 1. Diagram of the Burke and Yannas bilaminar artificial dermis used in this study.

tured by Marion Laboratories, Kansas City, MO, in accordance with Burke and Yannas's specifications.

The study was a matched-pair comparison of wounds covered with artificial dermis to meshed autograft, or, if donor sites were not available, to wounds covered by other conventional temporary wound coverings, followed by definitive autograft. Comparisons were performed in the same patient with wounds of similar site and size, randomized to receive either artificial dermis or the conventional cover used at the study burn center. Conventional covers included meshed autograft, allograft, xenograft, and synthetic dressings. All patients had completed case report forms that were monitored by Marion Laboratories, and final statistical analysis of the comparative data was performed by statisticians at Marion Laboratories.

Patient Selection

Patients were eligible if hospitalized with extensive flame or scald burns that were considered to be life-threatening and, in the opinion of the investigator, would not heal within 3 weeks and were amenable to early excision and grafting. All patients gave their written informed consent as dictated by the study burn center's Institutional Review Board. The initial excision of the wounds had to be performed within the first 7-days postburn. Symmetrical wounds were randomized to either left-right for symmetrically burned extremities, or left-right, top-bottom for wounds that were adjacent.

Surgical Technique

Burns were excised to living tissue either by tangential (sequential) excision or en bloc excision to the investing muscle fascia. After randomization, artificial dermis was applied to the study site and sutured or stapled in place. Comparison sites were covered with meshed autograft (if available) or if donor sites were not available, with other temporary dressings, as outlined above. The wounds were dressed according to the standard techniques of the study burn center. When the artificial dermis had become vascularized (usually by 14 days) and donor sites were available, the artificial dermis was grafted with epidermal grafts taken at the thinnest dermatome setting that would produce a translucent graft with minimal dermis attached. These grafts were meshed at 3:1 or 1.5:1, depending on donor site availability, and were placed on the artificial dermis after the silastic had been peeled from the vascularized collagen matrix. The wounds were again dressed according to the usual techniques of the study burn center. If the control sites were covered with materials other than autograft, the temporary dressing was removed and replaced as necessary, and eventually autografted according to the usual protocols of the study burn center.

Evaluation

In the initial short-term study, artificial dermis was compared to the control site (nonautograft and autograft) for "take" of the collagen mat and then for "take" of the subsequent epidermal graft. Control and study sites were compared for infection, mechanical problems, time to wound closure, and, at discharge from the burn center, function and appearance of the wounds. At discharge, the surgeons were asked to make a subjective assessment of the usefulness of the artificial dermis compared to conventional techniques. After discharge, patients entered into a long-term study and were followed for 1 year after discharge at 3-month intervals to compare the study and control sites for joint function, skin function (scaliness, dryness, itching, perspiration, pigmentation, and elasticity), the general appearance of the comparative sites, and physician and patient "preference."

Results

Patients

Eleven centers participated in the study, contributing from two to 40 patients. A total of 149 patients entered into the study originally (Fig. 2). Of these, six died before results could be determined, and 37 had some violation of protocol that eliminated them from final efficacy analysis. At the conclusion of the study, complete efficacy data was available for 136 sites in 106 patients. Of these, 14 patients died after "take" had been determined, and ten dropped from the study either for logistic reasons or because all artificial dermis had been lost and no long-term assessment could be made. Eighty-two patients entered into the long-term study, 59 of which have been followed for at least 9 months and 26 of which have been followed for at least 1 year after complete wound healing.

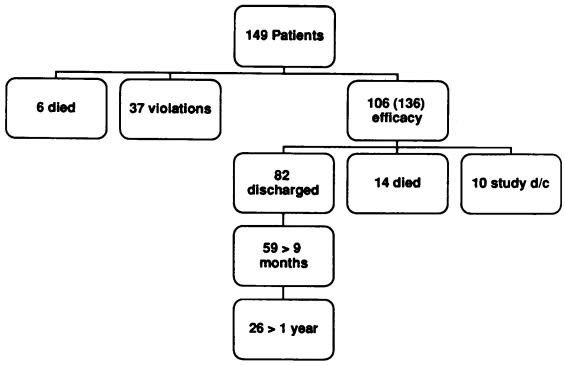

FIG. 2. Tree chart of patients entered into the multi-center trial.

Demographics

Of the 106 patients with complete data, 75% were male. Caucasians accounted for 61%, blacks for 25%, and hispanics for 11%. Twenty-five per cent of patients were younger than 15 years old, and 19% were older than 60 years of age. Mean total body surface (TBSA) burned was 46% ± 19% (standard deviation), mean deep (full thickness) burn size was 32% ± 20% TBSA, and the mean hospital stay was 64 ± 34 days. Fourteen patients died after "take" could be evaluated, with a mortality of 13% for males. Overall mortality was 20 of 149, also 13%.

Graft "Take"

The percentage of "take" of skin grafts in general and, as expected, in this series follows a bimodal distribution. For bimodally distributed data statistical, analysis was performed using the Wilcoxin Rank Sum Test. Median artificial dermis "take" was 80%, compared with the median take of all controls of 95%. Distribution of percentage of "take" of artificial dermis compared with all controls is shown in Figure 3, and, with a p value of <0.0001, was significantly less by Wilcoxin test. The "take" of artificial dermis differed somewhat from burn center to burn center, and there appeared to be a learning curve in centers who contributed more than 10 patients ($r = 0.23$, $p < 0.03$), obtaining better "take" as the surgeons became more experienced in the use of the artificial dermis. Although widely meshed autograft "took" more readily than the sheets of artificial dermis, when artificial dermis was compared with allograft there was no difference in "take" (Fig. 4). Epidermal graft "take" on the artificial dermis is shown in Figure 5; mean epidermal take was 86% (median 90%), but because of the spreading capabilities of the epidermis, with "take" of >50%, patients usually did not require another operation to close the wound.

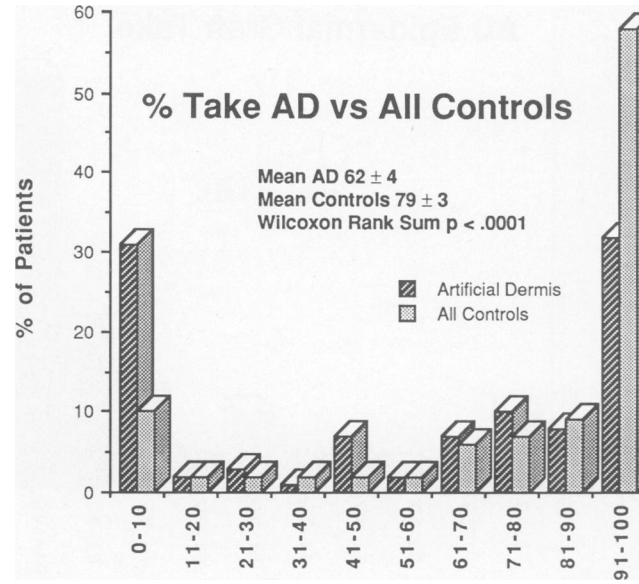

FIG. 3. Graphic representation of "take" of artificial dermis compared with all control sites.

Donor Sites

Donor site thickness mean was 0.013″ ± 0.018″ for control sites and 0.006″ ± 0.0025″ for epidermal grafts over artificial dermis, by *t* test a significant difference with a p value of <0.001. As would be expected, the thinner artificial dermis donor sites healed significantly faster, in 10.6 ± 5.8 days compared 14.3 ± 6.9 days of with control sites ($p < 0.001$ by *t* test). It should be noted that the artificial dermis donor sites were often recropped sites from previous autografting, and that re-

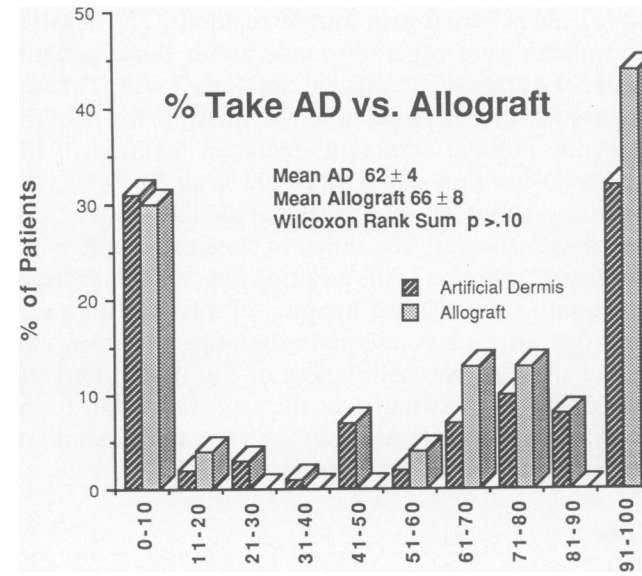

FIG. 4. Graphic representation of "take" of artificial dermis compared with cadaver allograft.

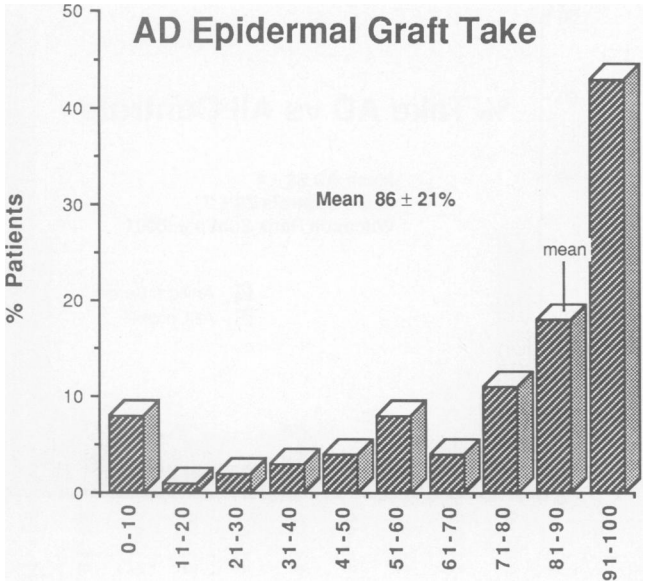

FIG. 5. Graphic representation of "take" of epidermal grafts on artificial dermis.

cropped donor sites heal more slowly than primary ones.

Surgeon's Overall Evaluation

A subjective critique of the artificial dermis on 74 patients was provided by the operating surgeon at the conclusion of the "short-term" study. In response to the question, "Was artificial dermis advantageous in the management of this particular patient?" 47 (63%) of the comments were affirmative. In 27 patients (36%), the acute results were believed to be no better than could have been achieved with routine methods. The negative comments were generally made about those patients where the artificial dermis did not "take" well. The surgeons provided no response to that question for 15 of the patients. Positive comments included mention of the ability to use thin donor sites that healed quickly, the handling characteristics of the artificial dermis compared with allograft, the ability to close the wound without fear of rejection while awaiting donor healing. Negative comments included mention of the need for a second operation, less adequate drainage of serum and blood through the solid sheet of Silastic™, and the seemingly poor resistance of the artificial dermis to infection. In this evaluation, appearance and function of the final cover were not considered.

Long-term Evaluation

Of the 82 discharged patients, 59 have been followed for more than nine months, and 26 have completed the study, being at least 1 year from discharge. Itching, rated on a scale of 1–5 was significantly less (Wilcoxin Rank Sum test $p < 0.02$) in the artificial dermis site. Dryness, scaliness, elasticity, sweating, sensation, and erythema were similar at both control and artificial dermis sites. There was less hypertrophic scarring in artificial dermis sites 42% of the time, and equivalent on study and control sites 57% of the time. No patient felt the artificial dermis site had more hypertrophy than the control site. Although the artificial dermis donor sites had often been recropped, 72% of patients still felt the artificial dermis donor site was "more normal," and 17% felt there was no difference; 11% felt the control donor site was "more normal." Overall evaluation and preference of the patients revealed that 26% preferred the artificial dermis, 64% finding the sites equivalent, and 10% preferring the control site. Physician ratings were similar, with 39% preferring the artificial dermis, 45% finding the sites equal, and 16% preferring the control site.

Discussion

The functional result from grafting with 1.5:1 meshed autograft is equivalent to that obtained by sheet grafts. The grafted dermis, however, does not reproduce itself to fill the interstices, so the meshed pattern is permanent, and to many patients, it is not as cosmetically appealing as sheet autograft. Because skin grafts shrink, donor sites must be larger than the excised burn if sheet grafts are to be used, and if the burn is more than approximately 10% TBSA, the donor sites can rarely be hidden on the buttocks, hips, and lower back. After taking grafts at .012″ to .020″ hypertrophic scarring, and pigmentation changes are not uncommon in donor sites, especially in children and patients with considerable skin pigmentation, such as Blacks, Hispanics, and Orientals. When burns are between 20% and 30% TBSA, 1.5:1 meshed autografts are usually used to provide complete wound coverage, but when the burns are larger than 30% TBSA, there are usually not enough donor sites to use 1.5:1 mesh, except in grafting the hands. In this circumstance, widely spread meshed autografts (3:1 or 6:1) are commonly used, but they provide neither an acceptable cosmetic or functional cover, nor do they close the wounds, as the wide interstices are still thousands of small, open wounds. When the area to be excised exceeds 40% TBSA, it is not usually possible to cover the entire excised area, primarily without subsequent recropping of the original donor sites. It takes at least 2 weeks for the original donor sites to heal, during which time alternate plans must be made to prevent infection in the nongrafted burns. Delaying further excision until donor sites become available leaves eschar in an already immunocompromised patient and risks burn

wound sepsis, so current thought is generally to excise all full thickness eschar and close the resulting wound with an alternative cover.

Frozen cadaver allograft is the most commonly used temporary cover. The quality and safety of the skin depends on the skin bank from which it comes. Bacterial infection, hepatitis, and transmission of other viruses are not imagined problems. While the banked skin is metabolically active,[3,4,5] there is doubt whether the epidermal cells can reproduce themselves. Allograft is often used as an overlay on widely spread autografts in order to close the wound;[6] as the autografted epidermis spreads, it gradually dislodges the allograft. This successfully provides a closed wound, yet the final cosmetic and functional results remain poor. Although burn patients are immunocompromised, allografts may still be rejected if left in place for more than 2 weeks. Rejection creates a temporarily ungraftable bed that is subject to infection. Additional drug-induced immunosuppression was successful in improving mortality in children by prolonging fresh allograft "take" when the children were treated in laminar flow isolators,[7] but the results of this study have not since been duplicated. More recently, prolonged allograft "take" has been reported, using cyclosporine immunosuppression in rats[8] and a patient,[9] but the fear of overwhelming sepsis remains. Heck and Baxter report that frozen allograft dermis from which the epidermis has been stripped is not rejected and can form a permanent dermal support for thin autografts.[10] Unfortunately, the same fears of disease transmission pertain.

A number of combination allograft-autograft techniques have been used to expand epithelial cover. The Chinese take large sheets of fresh allograft and insert tiny pinch autografts into thousands of little holes cut in the sheets of allograft,[11] but to date, Western physicians have lacked the patience to attempt this technique. Other surgeons have alternated strips of allograft and autograft,[12,13] but the technique is tedious and provides results not much different from widely spread meshed autograft.

Although with some difficulty, keratinocytes can now be grown in tissue culture, and expansion by 10,000 times the original specimen is possible in about 3 weeks. An initial enthusiastic report for the clinical use of this fragile cover in children prompted several surgeons to duplicate the experiment.[14] Unfortunately, the patient must still be kept alive for 3 weeks while the cells are growing, the cultured cell "take" is rather poor,[15] the resulting cover is very fragile for several months, and the lack of an underlying dermis creates severe scarring. Allograft epidermal cells cultured after removal of the highly antigenic Langerhans' cells were reported to provide a permanent epidermal cover,[16] but it is not clear in this report whether the final epidermal cover was allografted keratinocytes or regrown autologous epidermis.

For a short time (7 days), pig xenograft will works as well as allograft in preparing a wound bed,[17] but xenografts do not vascularize, and, therefore, they offer little resistance to infection if left in place for more than a few days. A myriad of "plastic" synthetic materials have been developed and are well reviewed by Davies.[18,19] For brief periods, they seem to work as well as allograft as a temporary (*i.e.*, for a few days) wound cover,[20] but they also do not vascularize, their conformability varies, they have little resistance to infection, and they often do not adhere to the wounds.

Because of the physical and physiologic limitations of the available wound covers, Burke and Yannas's report of a permanent artificial dermis offered great hope for the patient with extensive burns. The material may act as a structured collagen template, so as it becomes populated with native cells, the fibroblasts replace the bovine collagen to produce a final result resembling dermis more than it does scar. The use of ultra-thin epidermal grafts as a final wound cover has important implications. Donor site scarring is proportional to donor thickness and to donor site infection; the deeper the donor site, the longer it takes the donor site to heal and the greater the risk of infection. The dermis that is removed when taking standard autografts does not regenerate, so each cropping creates a thinner dermis on the donor site with fewer appendages from which the wounds epithelialize. By the third or fourth cropping, the dermis has been entirely removed, and the donor site becomes a full-thickness wound. Furthermore, as the dermis gets thinner, the donor sites take longer to heal; so it is not uncommon for recropped donor sites to take 3–6 weeks to heal. Epidermal grafts would permit limitless recropping of donor sites with healing taking place within a few days. A final, but as yet untested, potential use for an artificial dermis is for small burns or for reconstructive surgery in patients with a known propensity for forming hypertrophic scars in grafted areas or donor sites.

The artificial dermis tested in this study generally functioned well. "Take" was as good as all comparative materials, save autograft. Meshed autograft "takes" well because it conforms perfectly to the wound and the interstices provide ample drainage for blood and serum. The impermeable sheet of Silastic over the artificial dermis put it at greater risk for fluid collection beneath the collagen mat; these collections can either mechanically dislodge the artificial dermis or, if contaminated, provide a rich pablum for bacteria, which melts the artificial dermis over several days. Meshing the artificial dermis without expanding it might solve this problem.

When the artificial dermis "took," the Silastic gener-

FIG. 6. Control site of 3:1 meshed autograft at 1 year on the thigh of a 4-year-old.

ally remained adherent, and if the second operation was delayed for at least 14 days, the adherence of the collagen mat to the excised bed was greater than to the Silastic, so the Silastic was not difficult to remove. Occasionally bits of the collagen mat remained adherent to the Silastic. The clinical impression is that these denuded areas led to small scars in the final result. Getting the epidermal grafts to "take" was not a problem if the collagen mat had been well vascularized. Harvesting epidermal grafts does require some experience, accounting for the thicker than necessary epidermal donor grafts of 0.006″ reported in this initial clinical trial. As surgeons become familiar with taking them, donor grafts can successfully be taken at 0.002″–0.003″, ensuring a transparent graft with virtually no white dermis attached. Even when these epidermal grafts are meshed, in the absence of a meshed dermis, the final appearance and texture of the artificial dermis is smooth and flat, rather than having a meshed appearance. In the well-nourished patient, purely epidermal donor sites heal in about 4 days. In this study, the donor healing time of 10 days is accounted for by the donor thickness, and because it was often necessary to recrop donor sites that had been used for the initial autografting.

FIG. 7. Artificial dermis at 1 year on the other thigh of the child shown in Figure 6.

For the most part, the artificial dermis either worked well or not at all. One patient with an 85% TBSA burn had artificial dermis in place for 75 days, with the Silastic intact, while his meager donor sites were multiply recropped. On the other hand, in several patients, the artificial dermis rapidly became infected and melted away, leaving an infected wound bed.

Because final wound closure was delayed for at least 14 days, by the time of discharge from the hospital, the artificial dermis site was always less mature than the control site if autograft had been the initial comparison material. Nonetheless, rarely did the patient prefer the control site to the artificial dermis site. As time passed and both wounds matured, both patients and surgeons tended to believe that the two sites were equivalent, although over twice as many patients and physicians preferred the artificial dermis to the control site (Figs. 6 and 7). Junctures between sheets of artificial dermis and at the wound edges still formed scars, and areas where artificial dermis "take" was not perfect resembled the control site scarring.

Advantages

The artificial dermis makes a better-appearing wound than widely meshed autograft when the artificial dermis has "taken" well. Compared to allograft, it is easier to use, "takes" as well, does not carry the risk of viral infection inherent in allograft, does not reject, and does not need to be removed. Donor grafts can be taken as thin as the dermatome will permit, leading to rapid donor site-healing, a more normal final donor site appearance, and frequent recropping can be performed, if necessary. For the patient with an extensive burn, the requirement for a second operation does not increase hospital stay because sufficient donor sites are not available to provide total coverage without subsequent recropping. When recropping is necessary, thin donors, which can soon be recropped, may actually shorten the time to obtain definitive coverage.

Disadvantages

Meshed autograft "take" is better than artificial dermis "take", probably because of the better conformability and drainage of the autograft. Developing infection may be subtle and, under the artificial dermis, is not noticed until it has spread. For patients with moderate

burns who could be covered in one sitting by conventional methods, the second operation delays definitive coverage and could lengthen hospital stay.

Conclusion

In patients with major burns, artificial dermis permits early wound closure with as good a take as allograft, and when covered with a subsequent epidermal graft it provides a permanent cover that is at least as satisfactory as currently available skin grafting techniques and uses donor grafts that are thinner and leave donor sites that heal faster.

References

1. Gray DT, Pine RW, Harnar TJ, et al. Early surgical excision *versus* conventional therapy in patients with 20 to 40 percent burns: a comparative study. Am J Surg 1982; 144:76–80.
2. Burke JF, Yannas IV, Quinby WC, et al. Successful use of a physiologically acceptable artificial skin in the treatment of extensive burn injury. Ann Surg 1981; 194:413–428.
3. May SR, DeClement FA. Skin banking: Part III. Cadaveric allograft skin viability. J Burn Care and Rehab 1981; 2:128–133.
4. Berry RB, Hackett MEJ. A comparative evaluation of lyophilized homograft, lyophilized pig skin and frozen pigskin biological dressings. Burns 1980; 7:84–89.
5. Banes AJ, Dingledein P, Thiet M, et al. Wound dressings: A biochemical comparison of viable and nonviable allografts in control and burned rats. J Burn Care and Rehab 1983; 4:165–170.
6. Alexander JW, MacMillan BG, Law E, Kittur DS. Treatment of severe burns with widely meshed skin autograft and meshed skin allograft overlay. J Trauma 1981; 21:433–438.
7. Burke JF, Quinby WC, Bondoc CC, et al. Immunosuppression and temporary skin transplantation in the treatment of massive third degree burns. Ann Surg 1975; 182:183.
8. Black KS, Hewitt CW, Smelser S, et al. Cyclosporine and skin allografts for the treatment of thermal injury. II. Development of an experimental massive third-degree burn model demonstrating extensive graft survival. Transplantation 1988; 45:13–16.
9. Achauer BM, Hewitt CW, Black KS, et al. Long-term skin allograft survival after short-term cyclosporin treatment in a patient with massive burns. Lancet 1986; 1(8471):14–15.
10. Heck EL, Bergstresser PR, Baxter CR. Composite skin graft: frozen dermal allografts support the engraftment and expansion of autologous epidermis. J Trauma 1985; 25:106–112.
11. Zhang M, Wang C, Chang Z, et al. Microskin grafting. II. Clinical report. Burns 1986; 12:544–548.
12. Zawacki BE, Asch M. A technique for autografting very large burns from very limited donor sites. Surgery 1973; 74:774.
13. Chih-Chun Y, Tsi-Siang S, Te-An C, et al. The intermingled transplantation of auto- and homografts in severe burns. Burns 1980; 6:141.
14. Gallico GG, O'Conner NE, Compton CC, et al. Permanent coverage of large burn wounds with autologous cultured human epithelium. New Engl J Med 1984; 311:448–451.
15. Eldad A, Burt A, Clarke JA. Cultured epithelium as a skin substitute. Burns 1987; 13:173–180.
16. Madden MR, Finkelstein JL, Staiano-Coico L, et al. Grafting of cultured allogeneic epidermis on second- and third-degree burn wounds on 26 patients. J Trauma 1986; 26:955–962.
17. Wang HJ, Yeap CL, Heimbach DM. Allograft *versus* Xenograft in preparation of wounds for autografting. J Burn Care & Rehab 1984; 5:116–121.
18. Davies JWL. Synthetic materials for covering burn wounds: progress towards perfection. Part 1. Short-term dressing materials. Burns 1983; 10:94.
19. Davies JWL. Synthetic materials for covering burn wounds: progress towards perfection. Part II. Longer term substitutes for skin. Burns 1983; 10:104.
20. Purdue GF, Hunt JL, Gillespie RW, et al. Biosynthetic skin substitute *versus* frozen human cadaver allograft for temporary coverage of excised burn wounds. J Trauma 1987; 27:155–157.

Discussion

Dr. Fred T. Caldwell (Little Rock, Arkansas): I congratulate Dr. Heimbach and his large number of co-investigators on the completion of a very difficult, and important multicenter clinical evaluation of an artificial dermis.

I have had the opportunity to review the manuscript and it clearly outlines in great detail the advantages and disadvantages of the use of this material.

There are several things that are clear. One, this is no humbug. I believe this is a real addition to our armamentarium. This material is easier to use and safer than allografted tissue as demonstrated by these data. It allows the use of much thinner autografts. Therefore, recropping can be performed at short intervals and in some of these cases this is tantamount to living or dying. Although the initial take is not as good as with meshed autograft, the end result both from physician's and patient's standpoint is at least equal.

I believe the authors are on the right track. Early elimination of the burn wound eliminates a multitude of problems associated with burn injury with a major exception of inhalation injury.

I have two questions for Dr. Heimbach. The patient sample includes many children and older adults, and I just wondered if age makes a difference in the result obtained with this material? Although I realize it was not a primary goal of this study, I would like to know if Dr. Heimbach and his co-authors have any feeling as to whether or not this material could have an impact on the survival of patients with what are now lethal thermal injuries.

Dr. Boyd Withers Haynes Jr. (Richmond, Virginia): What we have heard today is a milestone in the progress toward control of burn wound healing. This presentation recalls the Association's meeting in 1981 when Dr. Burke first presented the concept, and I observed at that time that it was reminiscent of the rejection process for skin allograft. Once epidermis rejects, there remains a dermis that will often accept autografted skin.

I believe that the allograft dermis survives because of low antigenicity, or because it is biodegraded and replaced by body collagen, as is the case with the artificial dermis.

I would like Dr. Heimbach to tell us if normal sensation returns after epidermal healing, and whether itching occurs.

Dr. F. William Blaisdell (Sacramento, California): I enjoyed the paper, and I have just one question. The practical point raised by having artificial dermis is: would you defer grafting of the patient in deference to using the artificial dermis? In other words, if you had limited donor sites, would you defer using those donor sites initially so that when you did graft, you might ensure a take; and under these circumstances, would you use artificial dermis instead?

Dr. Milton T. Edgerton (Charlottesville, Virginia): Certainly the major burn continues to be a challenge to all burn centers. I am convinced that Dr. Heimbach, expanding on Dr. Burke's earlier initiatives, may be about to open a new major chapter in burn care.

A few years ago, a small group of American plastic surgeons were