Environmental Health Perspectives
Vol. 9, pp. 241–252, 1974

Interaction of Asbestos with Alveolar Cells

by Yasunosuke Suzuki*

A number of electron microphotographs are presented showing the various aspects of phagocytosis of fibers in lung tissue.

The fibers were rapidly phagocytosed by alveolar macrophages, by polymorphonuclear leucocytes, and less frequently by alveolar epithelial cells. They were also found in the cytoplasm of the alveolar stromal macrophages. In the late stage of the disease, macrophages containing the minerals were recognized in the fibrous submesothelial connective tissues. In this stage, a cell intermediate in structure between the epithelial cell and the macrophage was observed in the alveolar lining. This cell showed strong phagocytic activity against the fibers.

The process of phagocytosis of the fibers was quite similar to that of other microparticles such as Thorotrast and India ink. It had been suggested that phagosomes containing the fibers became transformed into secondary lysosomes.

The fate of the phagocytosed fibers varied. Some were partly dissolved or digested with marked reduction in the thickness of the wall of the chrysotile fibril. Many became coated by hemosiderin which accumulated in the cytoplasm of the phagocytic cells. This coating transformed the fibers into asbestos bodies. Finally many fibers were released because of the death of the host cell. Uncoated fibers as well as various stages of phagocytosis were observed in all animals, including those 1 to 2 years after the instillation of asbestos. This strongly suggests that fibers may be repeatedly phagocytosed, released and rephagocytosed, inducing a continuous response of the alveolar cells and maintaining the disease.

My work has been concerned with the reaction of alveolar cells from the lung with asbestos, rather than with the gastrointestinal tract. It was carried out at the Mt. Sinai Medical School in New York, and some of the animal experimentation was done under the direction of Dr. W. E. Smith.

Despite a large number of reports, the details of interaction between the asbestos minerals and the alveolar cells such as macrophages and the alveolar epithelial cells are not well known. To study this interaction 60 male hamsters were given a single intratracheal instillation of 1–2 mg of asbestos (chrysotile or amosite or crocidolite) suspended in 0.1 ml of normal saline. Chrysotile fibers have a rather constant diameter (approximately 300 Å) and a characteristic tubular structure which is easily recognized under the electron microscope, though the other two types of asbestos have no unique ultrastructure.

The hamsters were sacrificed in the early stages of the experimental disease (1 to 28 days after instillation) or in the late stage (6 months to 2 years), and the lungs were examined by light and electronic microscopy. Though the instilled asbestos were fairly large in size (average 6–10 μm), the minerals observed on the alveolar lining surface were mainly of submicroscopic length (under 1 μm).

Cellular aggregates of macrophages and polymorphs in the alveolar space are striking by light microscopy in the early stage. This acute inflammatory reaction is replaced later by proliferative changes as shown by

*Fujita-Gakuen University, School of Medicine, Toyoka, Japan.

hypercellularity of the alveoli, the appearance of multinucleated giant cells including hemosiderin granules, and, 6 months to one year afterwards, asbestos bodies and pulmonary fibrosis.

Figure 1 shows submicroscopic alterations of the alveolar wall and destruction of the alveolar capillary wall. Desquamated cells containing asbestos fibrils and a bare basement membrane can be seen. The desquamated cells are from the alveolar epithelium and the fibrils are found in the basement membrane.

Figure 2 is of the surface of a macrophage forming a pseudopod, to which chrysotile fibrils are attached. This phenomenon is said to be common as the first step of phagocytosis of various foreign substances.

If we are lucky, we can see, as in Figure 3, the various processes of phagocytosis: (1) direct contact of fibrils with the plasma membrane; (2) formation of a recess containing fibrils; (3) phagosome formation after pinching off of the recess from the plasma membrane; and (4) movement of the vacuole into the deeper portion of the cytoplasm.

In Figure 4 we have a huge multinucleated macrophage. In pulmonary asbestosis giant cells are quite common. It is known that such giant cells are formed by the fusion of several macrophages. This mechanism may be important to form a large phagosome which can contain thick or long fibers and can form a large asbestos body, as in Figure 5. In this picture the phagosome is being transformed into an immature asbestos body.

Various cell types participate in phagocytosis of asbestos minerals. In Figure 6 a neutrophil is seen to be active. In Figure 7 a stromal macrophage contains the fibers, and in Figure 8 the alveolar epithelium is involved in the process.

The reaction of the alveolar epithelium

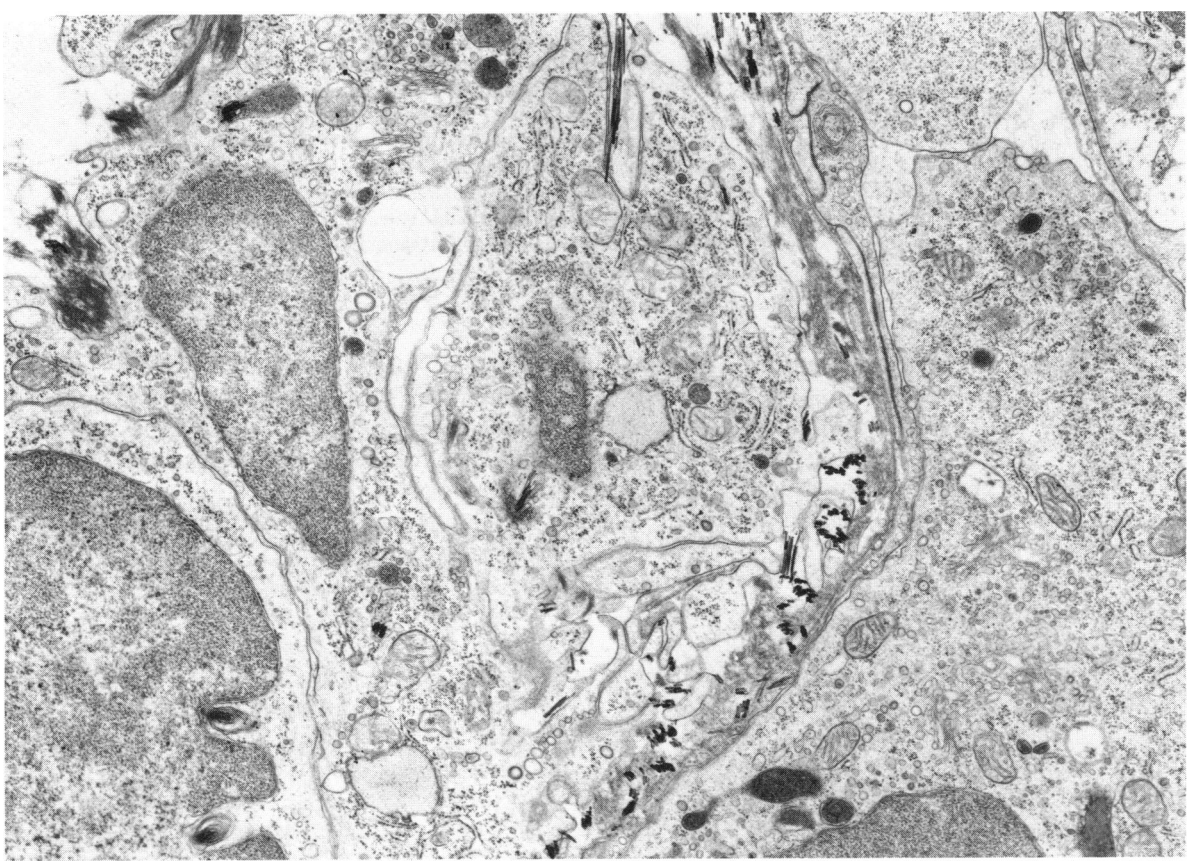

FIGURE 1. Desquamation of an alveolar epithelium.

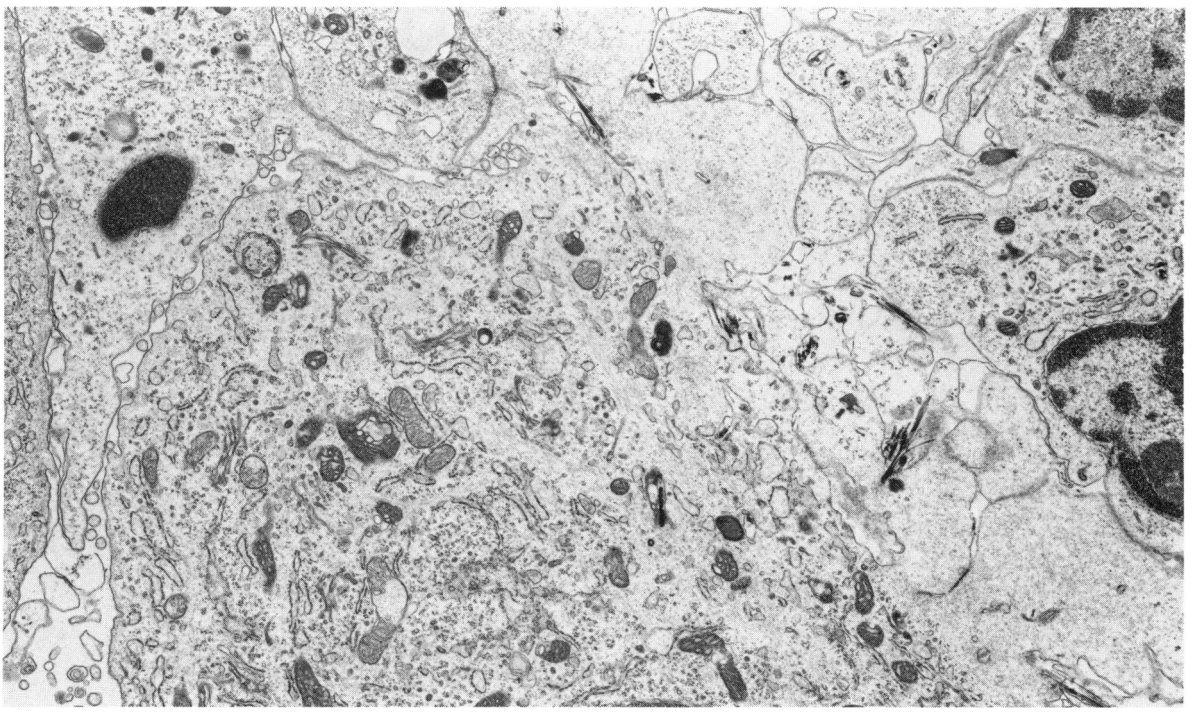

FIGURE 2. A macrophage forming pseudopods.

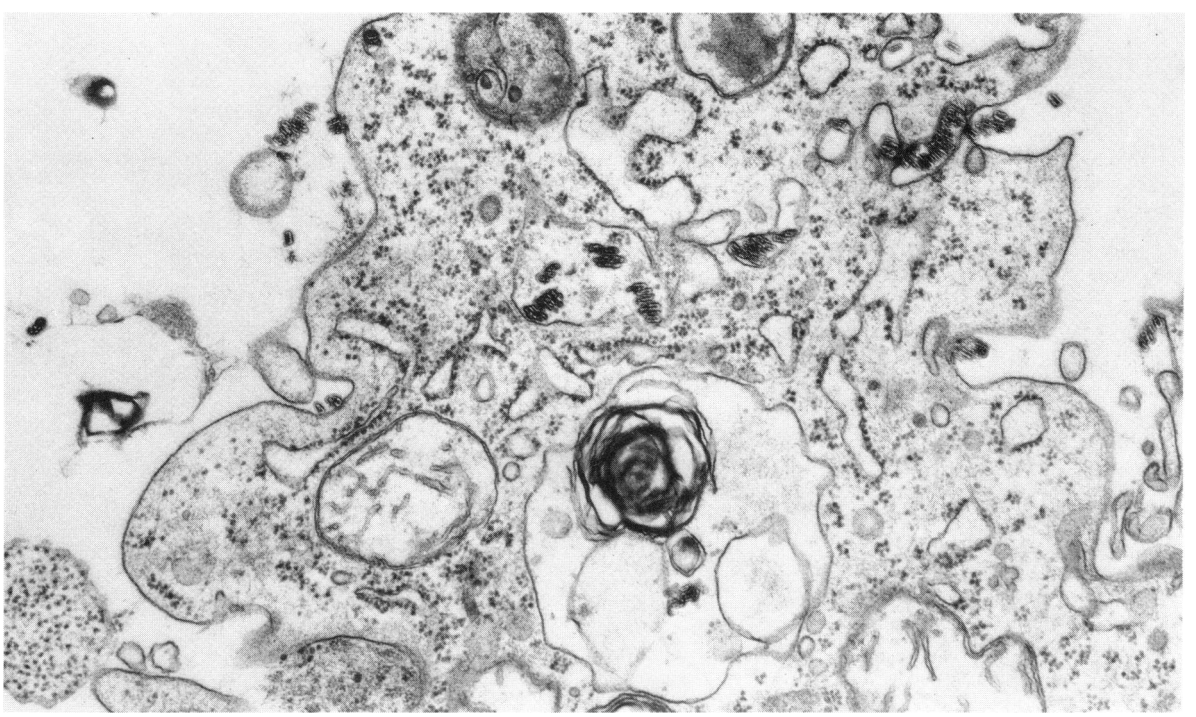

FIGURE 3. Various processes of phagocytosis.

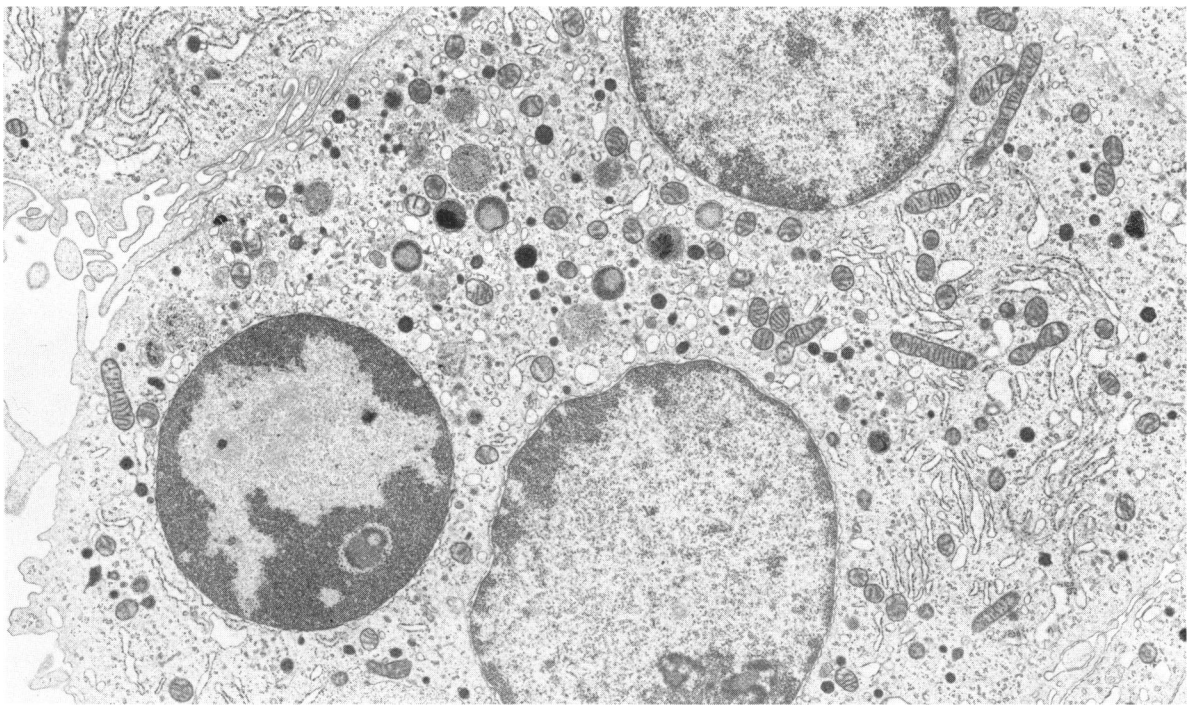

FIGURE 4. A multinucleated macrophage.

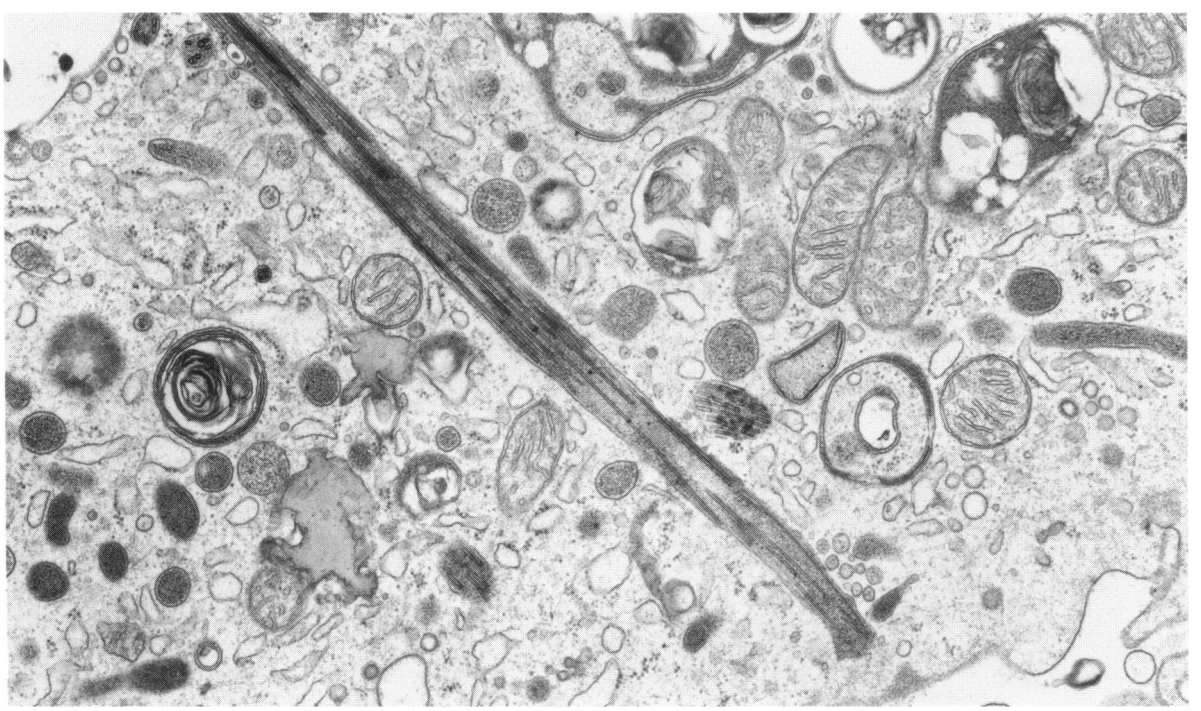

FIGURE 5. Thick and long chrysotile in a large phagosome.

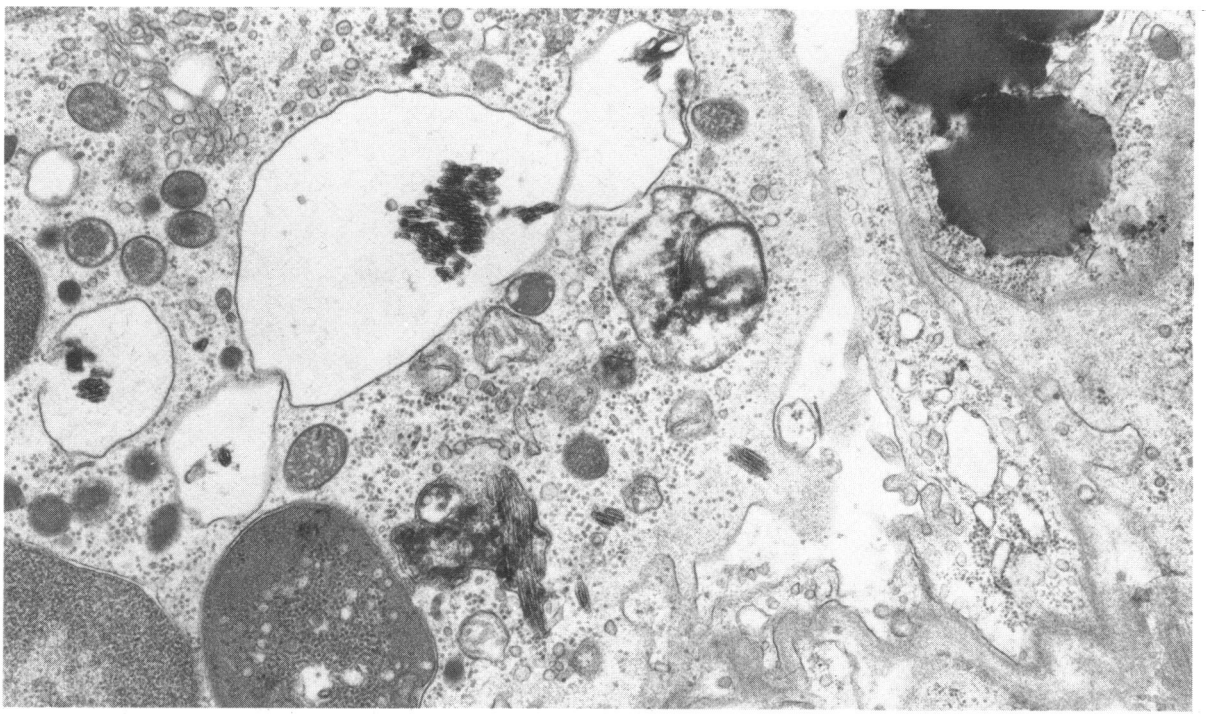

FIGURE 6. A neutrophil containing chrysotile.

FIGURE 7. Asbestos fibrils observed in a stromal macrophage.

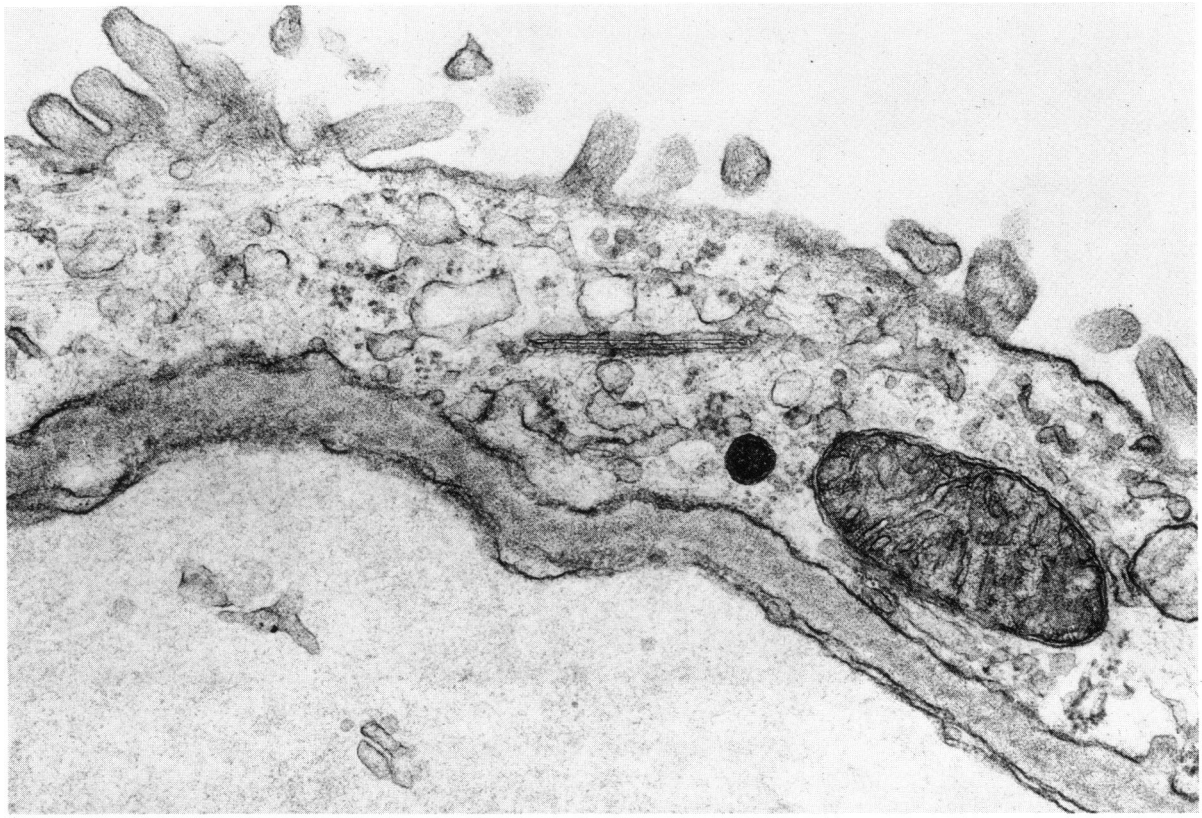

FIGURE 8. A single chrysotile fibril in an alveolar epithelium.

against asbestos fibers is interesting. At first sight, the cell shown in Figure 9 looks like a giant cell macrophage, but if part of the picture is enlarged, as in Figure 10, it is obvious that the cell still possesses some of the structural characteristics of an epithelial cell. Here and there can be seen "terminal bars" or "tight junctions" which are never seen in macrophages or blood monocytes. This finding strongly suggests that the alveolar epithelium can transform into phagocytic cells, similar to the macrophages, under certain conditions such as those that prevail in asbestosis.

Electron microscopy findings in the early cellular reactions of pulmonary alveoli exposed to asbestos may be summarized: (1) the cell aggregates in the alveolar space are composed of macrophages and polymorphonuclear leucocytes actively participating in the phagocytosis of the fibers; (2) desquamation of the alveolar epithelium in the focal area and exudation of blood plasma from the capillary lumen is taking place; (3) phagocytosis of asbestos fibers is performed by several cell types, although the macrophage is the most active.

The next question concerns the fate of phagocytosed fibers. This seems to vary. Figure 11 shows a few phagosomes containing fibrils of chrysotile, one of which is extremely reduced in thickness, suggesting partial digestion. It is quite possible that a lysosome plays a role in this digestion or dissolution. As is seen in Figure 12, the appearance of lysosomal granules is quite common in the macrophage and the lysosomes contain asbestos fibrils.

Another development is coating of the fiber by a substance containing iron micelles, which gradually accumulate around phagocytosed fibers to form an asbestos body. Immature asbestos bodies have been found as early as 16 days after tracheal instillation. Figures 13*a*, 13*b*, and 13*c* show successive stages in formation of the asbestos body. In Figure 14 fusion of

FIGURE 9. A giant phagocytic cell.

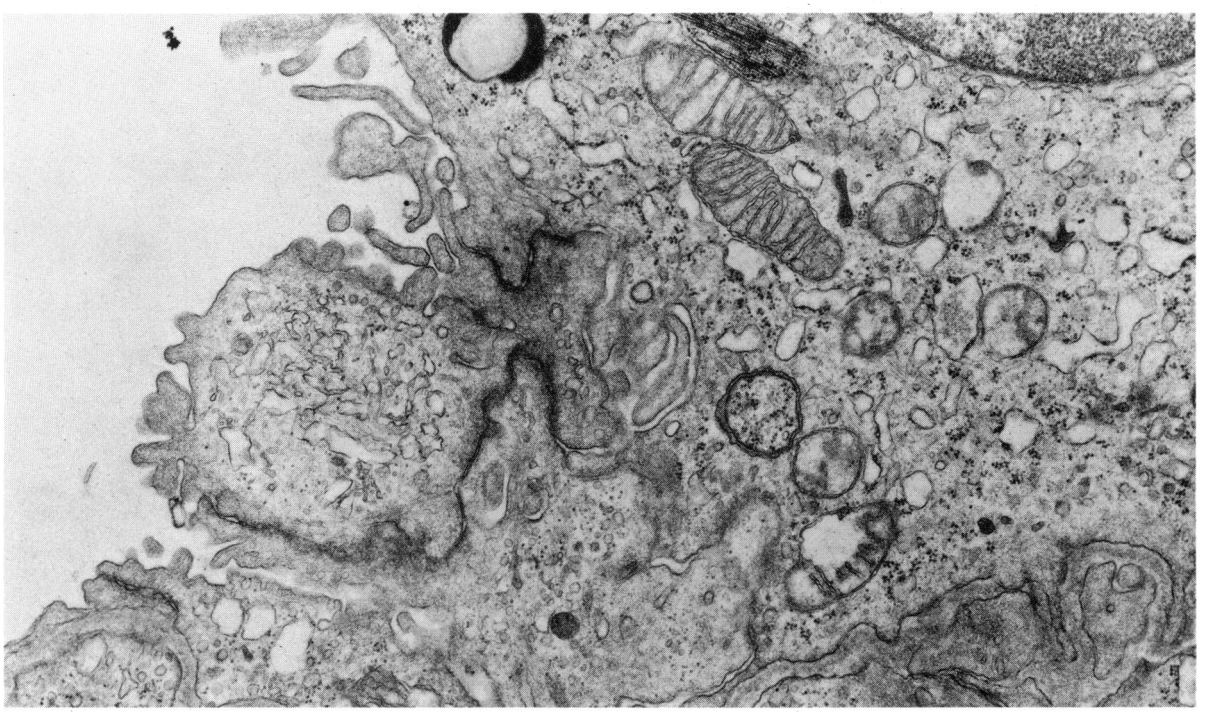

FIGURE 10. Junctional structures of the giant phagocytic cell.

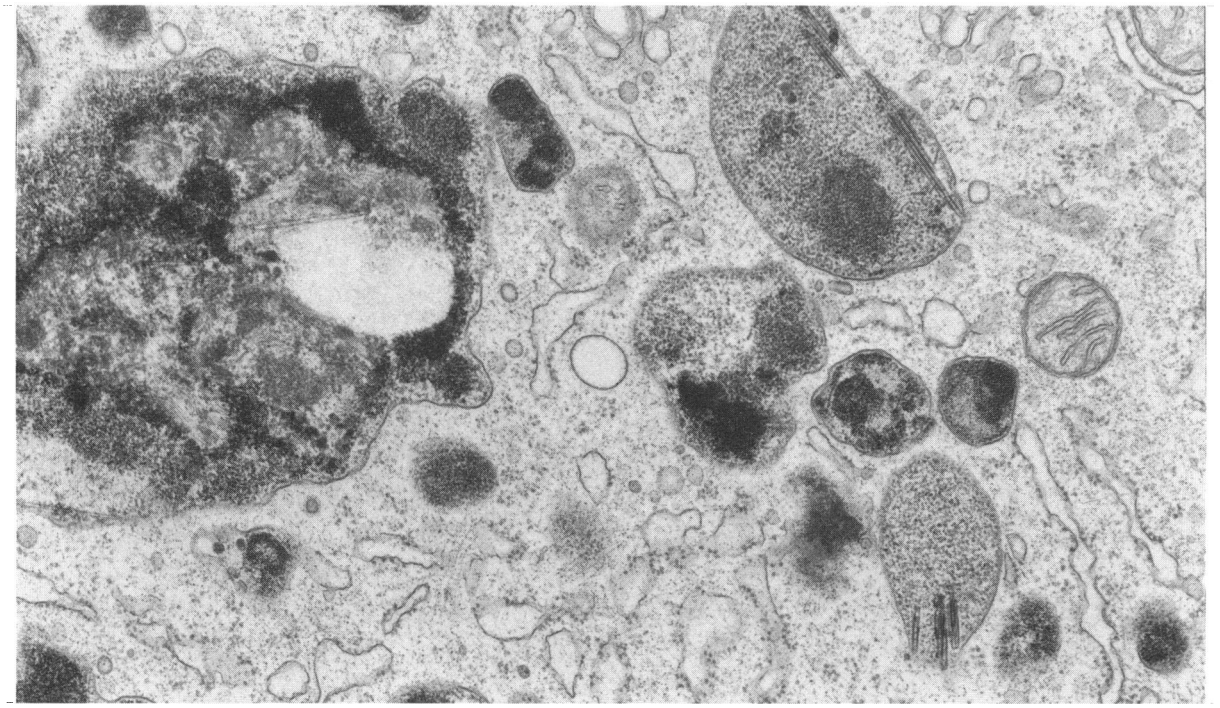

FIGURE 11. A chrysotile fibril reduced in thickness (in the upper left phagosome).

FIGURE 12. A lysomome containing asbestos.

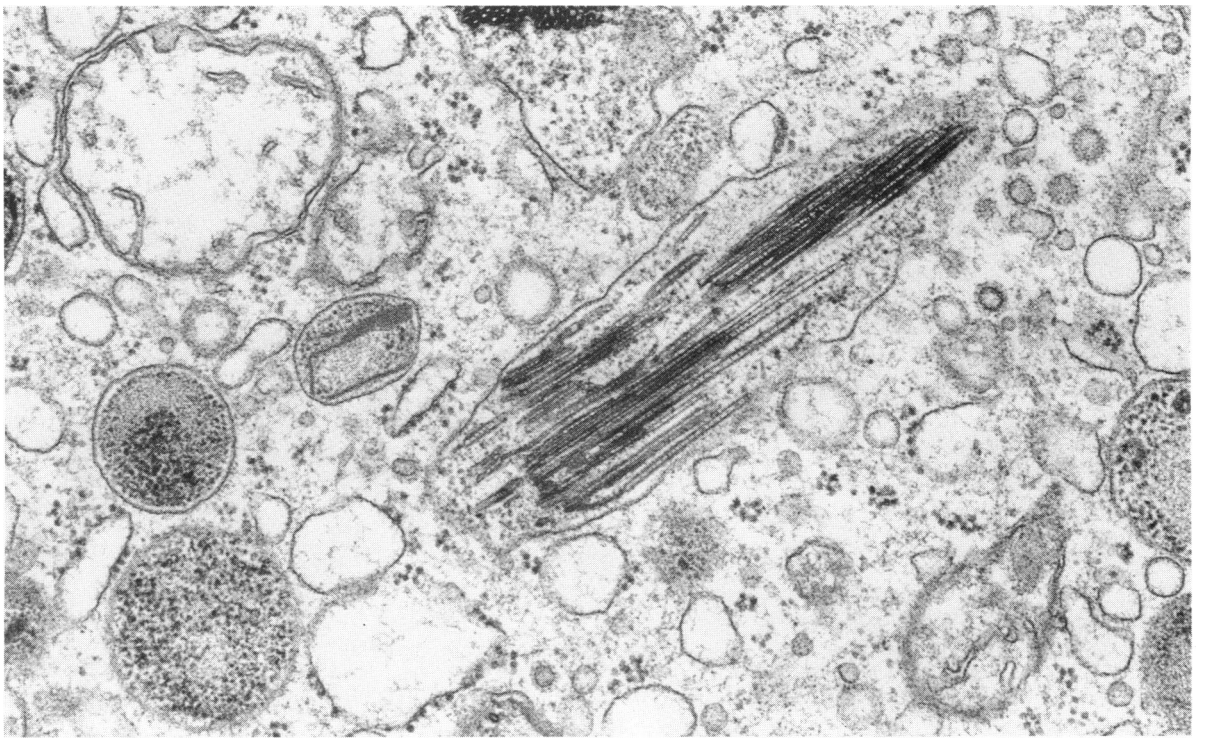

(a)

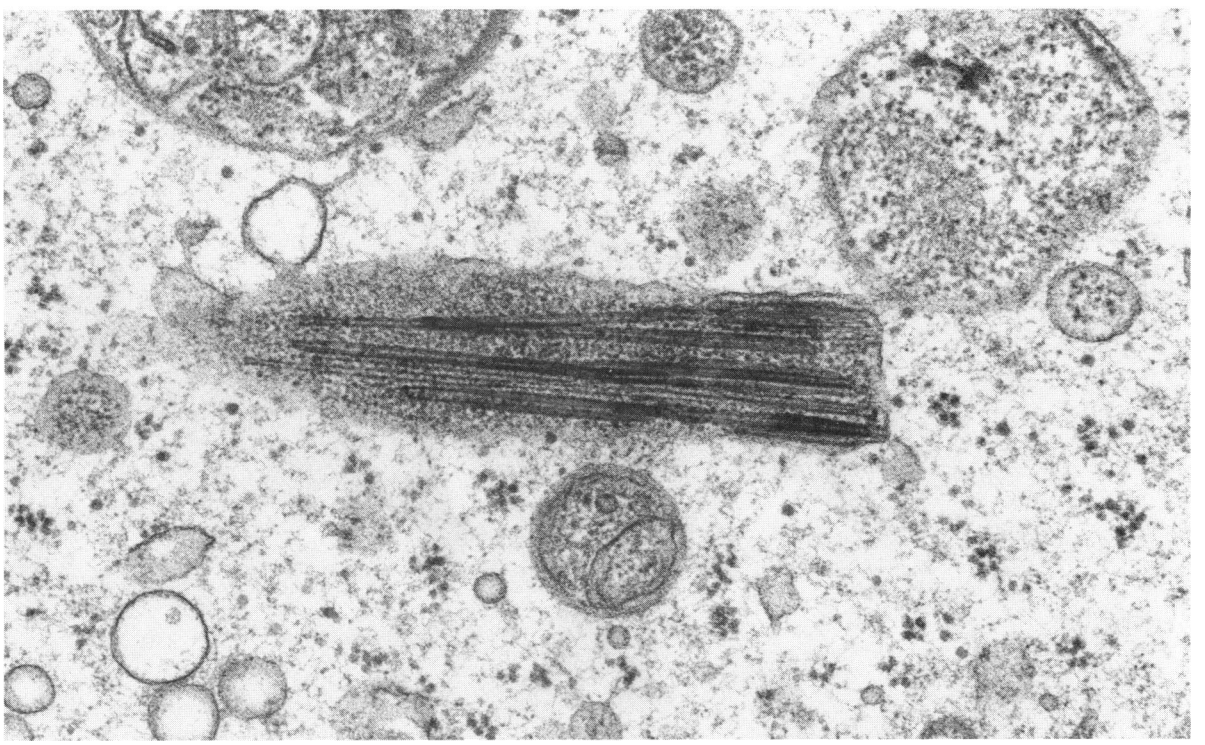

(b)

FIGURE 13. Various stages of asbestos body formation.

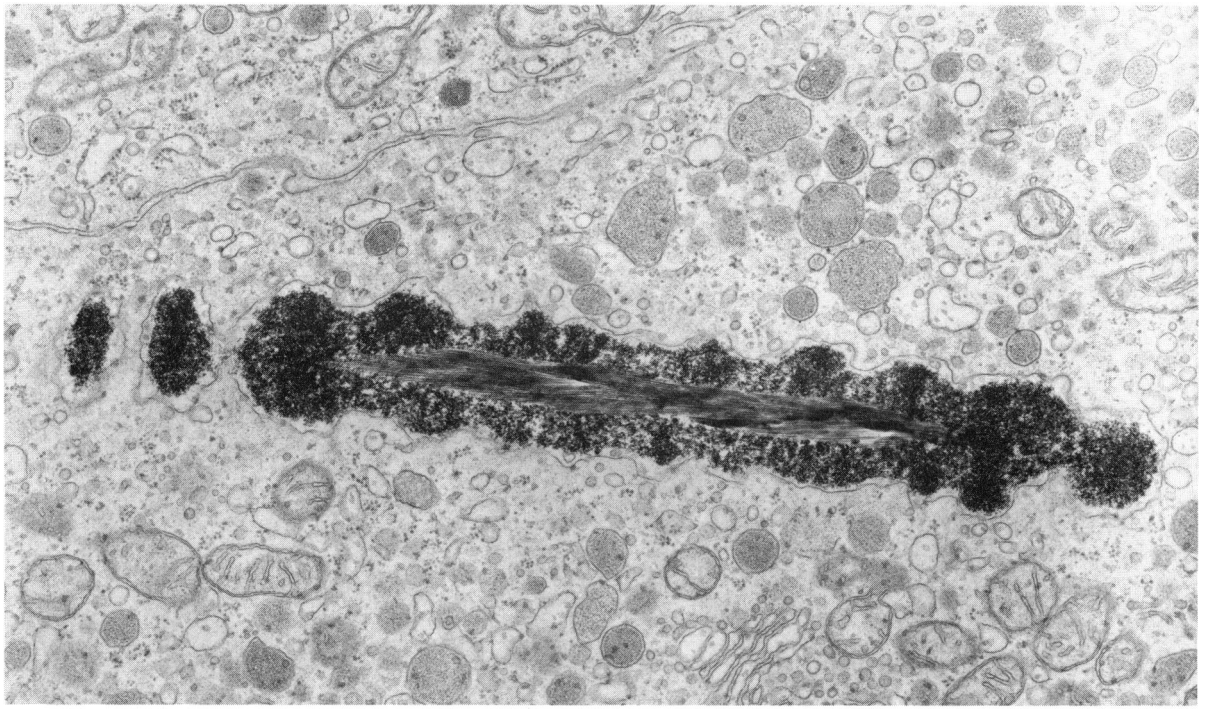

(c)

FIGURE 13. Various stages of asbestos body formation (Continued).

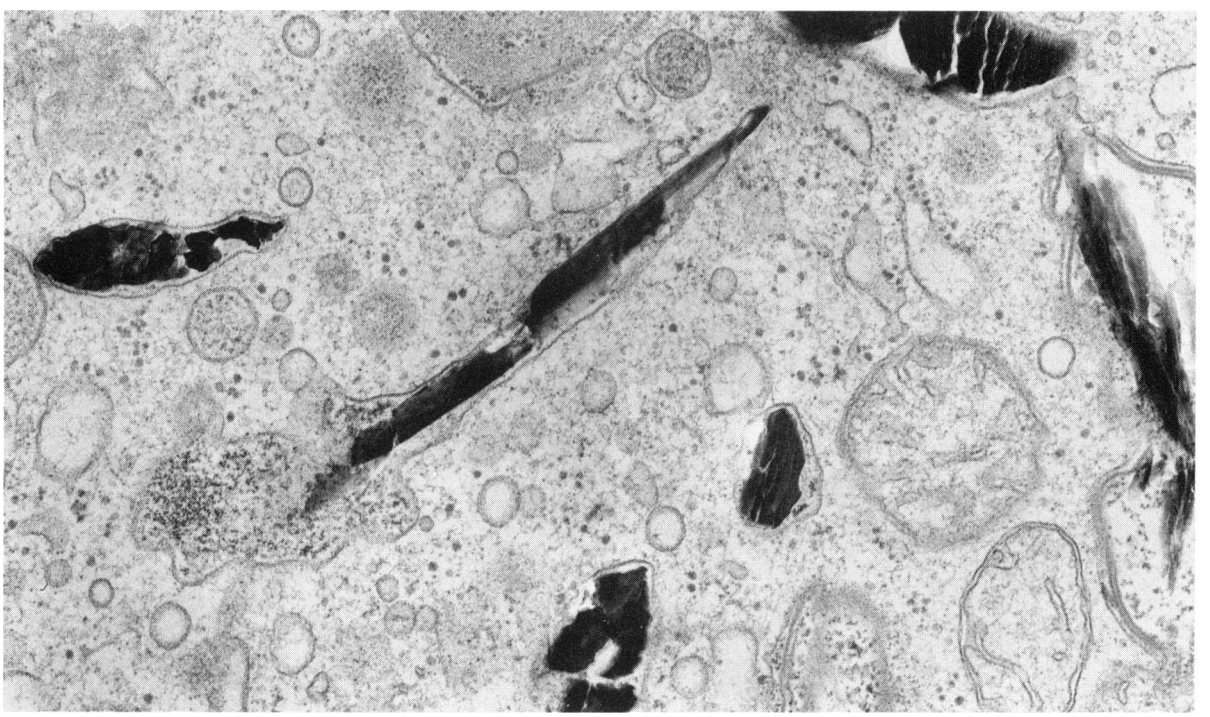

FIGURE 14. Fusion of amosite containing phagosome to hemosiderin granules.

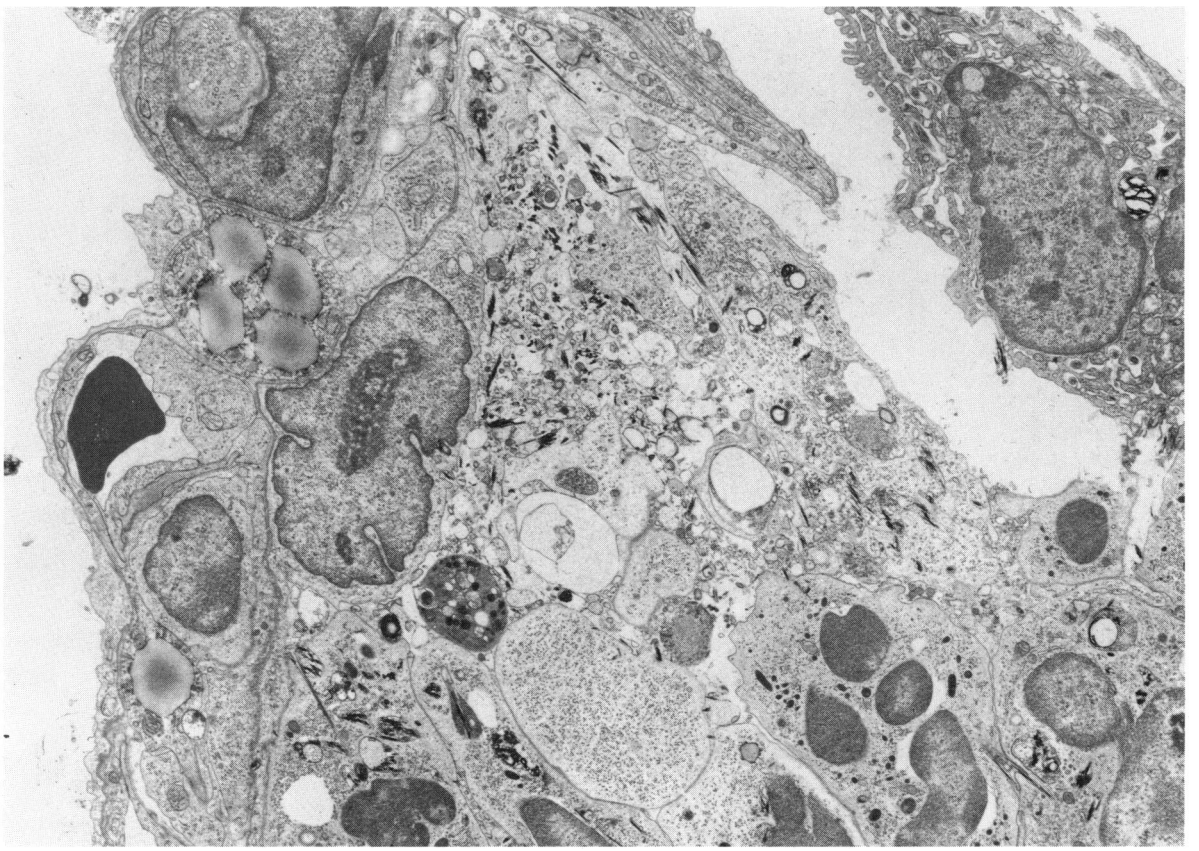

FIGURE 15. Chrysotile fibrils released from a macrophage.

a hemosiderin granule to the asbestos-containing phagosome is seen, and it is strongly suggested that hemosiderin is the source of the coating substance that forms the body.

A third occurrence is rapid death of the host cell and release of the virtually unaltered fibers, as is seen in Figure 15. The fate of the phagocytosed fiber may then be summarized: (1) digestion or dissolution; (2) coating and conversion into an asbestos body; or (3) release following death of the cell and rephagocytosis by another cell.

Figure 16 shows uncoated fibrils still present one year after tracheal instillation. Here they are attached to the surface of a type II alveolar cell, which suggests that they are undergoing the first step of rephagocytosis. Various stages of phagocytosis and of asbestos body formation can be seen in the same tissue, as in Figure 17. This suggests that the mechanism persists over a long period of time and induces a continuous response of the alveolar cells, maintaining and advancing the process of pulmonary asbestosis.

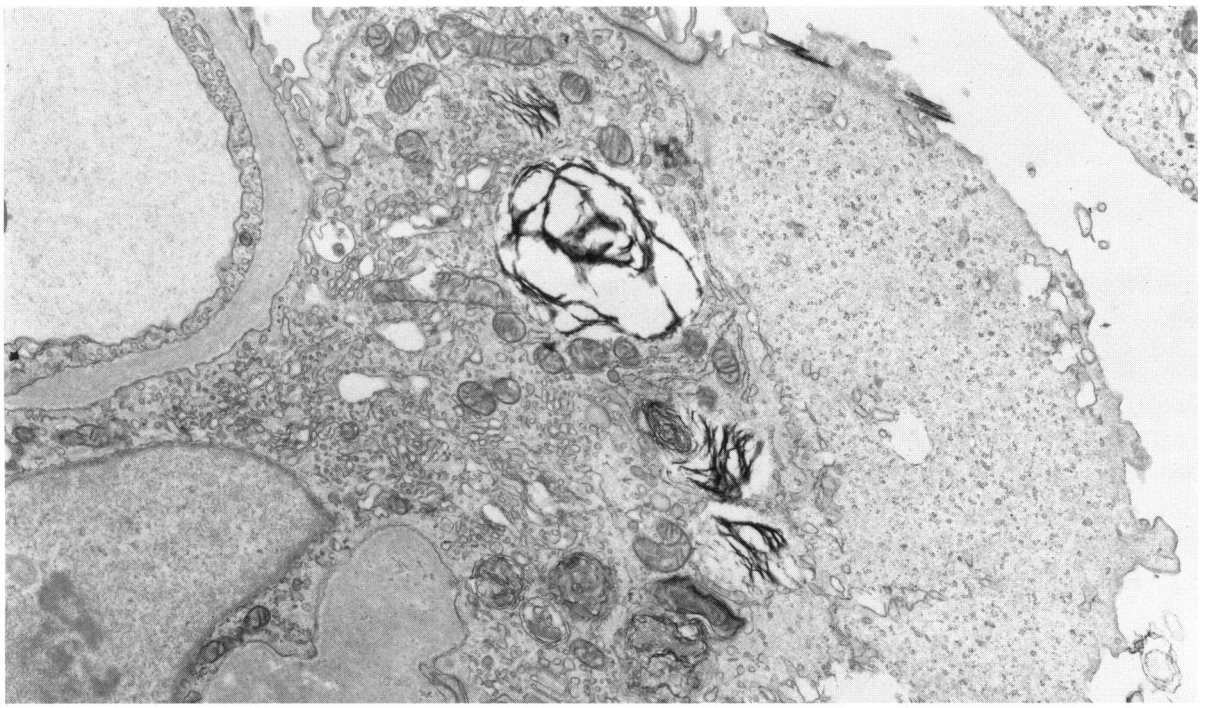

FIGURE 16. Uncoated chrysotile on the surface of type II alveolar epithelium.

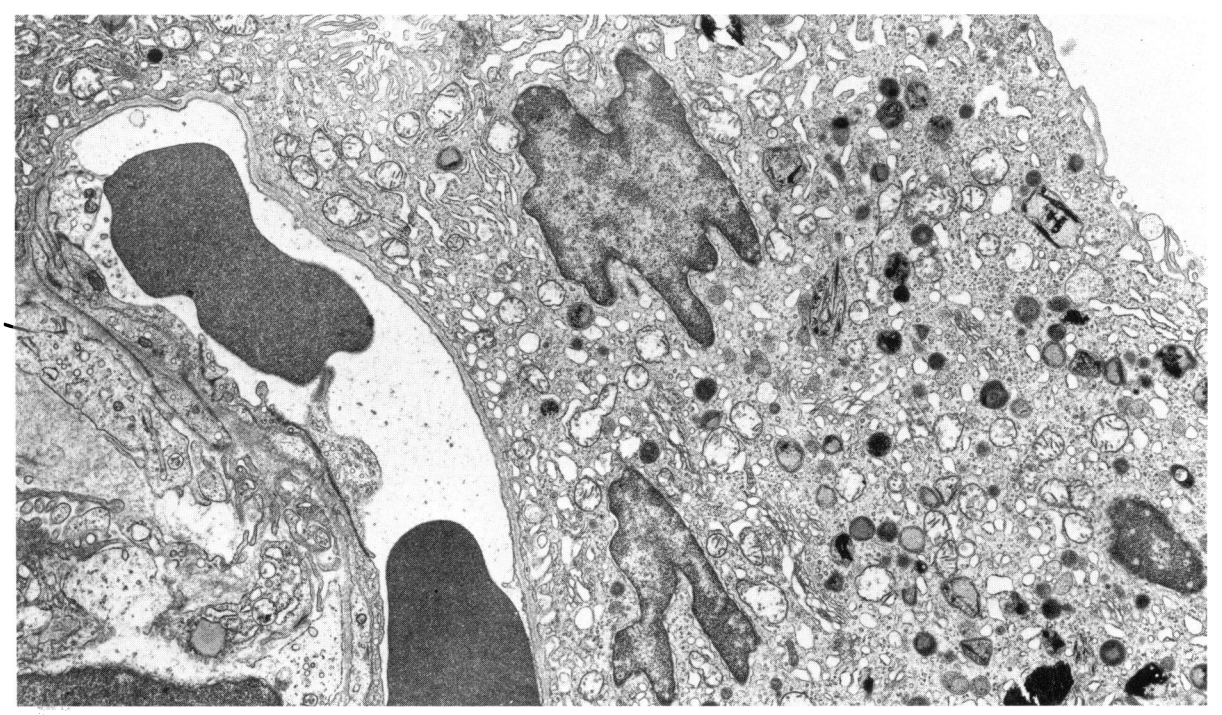

FIGURE 17. A phagocytic cell containing coated and uncoated asbestos.