*Environmental Health Perspectives*
*Vol. 11, pp. 227–233, 1975*

# Acute Liver Injury by Vinyl Chloride: Involvement of Endoplasmic Reticulum in Phenobarbital-Pretreated Rats

by Edward S. Reynolds,* Rudolph J. Jaeger,† and Sheldon D. Murphy†

**A single 6-hr exposure to vinyl chloride monomer (5%) produces extensive vacuolization of centrolobular liver parenchyma and focal midzonal necrosis in the hepatic lobuole in phenobarbital-pretreated rats. Ultrastructurally, vacuolization consists of dilation of cysternae of rough endoplasmic reticulum and in the same cells smooth endoplasmic reticulum coalesces into discreet aggregates resembling denatured membranes. The findings support the hypothesis that vinyl chloride is hepatotoxic because it is converted into a toxic metabolite by components of the mixed function oxidase system of liver endoplasmic reticulum.**

## Introduction

Acute liver injury after vinyl chloride (VCM) has been noted briefly in earlier reports (*1,2*). Mastromatteo et al. (*1*) reported the appearance of fatty infiltration but could not demonstrate fat on frozen sections in guinea pigs exposed to 30% VCM for 30 min. Lester et al. (*2*) described the livers of rats exposed to 5% VCM for 8 hr on 19 consecutive days as containing marked swelling of cells, large irregular "vacuoles," and compressed sinusoids either focal or widespread.

We recently reported that 6 hr exposure to 5% VCM produces acute, biochemical and histologic injury in phenobarbital (PBT)-pretreated rats, but not in nonpretreated rats (*3*). Animals were pretreated with PBT because PBT induces certain components of the mixed function oxidase system located within the membranes of the endoplasmic reticulum and is responsible for the hepatotoxic activation of other halogenated hydrocarbons (*4,5*). This report is the first detailed ultrastructural description of acute liver injury by VCM.

## Materials and Methods

Male Holtzman rats (250–300 g), housed in suspension cages, were provided Purina Lab Chow *ad libitium*. One group of animals was given *ad libitium* access to drinking water containing 0.1% sodium phenobarbital, 7 days prior to their initial VCM exposure and thereafter until sacrifice. Others, nonpretreated rats, were given tap water alone. Daily consumption of PBT was approximately 10 mg/100 g rat, which produces striking increases in smooth endoplasmic reticulum and doubling of cytochrome P-450 content and oxidative-*N*-demethylase activity (*6,7*).

PBT-pretreated and non-PBT-pretreated animals in groups of four were exposed to 5% VCM for 6 hr once, or to 5% VCM for 6 hr each on five consecutive days. Exposures were

* Pathology Department, Peter Bent Brigham Hospital and Harvard Medical School, Boston, Massachusetts 02115.
† Kresge Center for Environmental Health, Harvard School of Public Health, Boston, Massachusetts 02115.

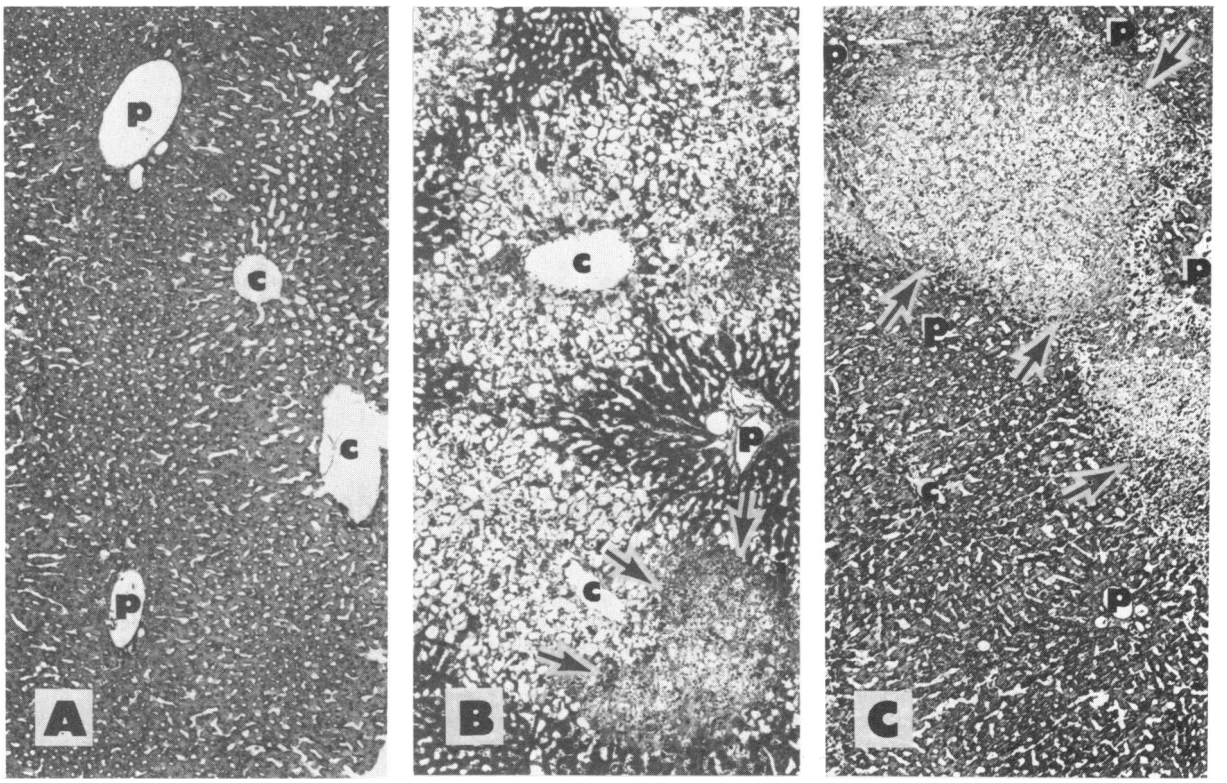


FIGURE 1. Micrographs of liver (c = central vein, p = portal vein), ×50. (*A*) Non-PBT-pretreated animals 24 hr following onset of a single 6 hr exposure to 5% VCM; liver is histologically normal. (*B*) PBT pretreated animals 24 hr following onset of a single 6-hr exposure to 5% VCM. The centrolobular two-thirds of the liver lobules show diffuse vacuolization; and area of focal midzonal necrosis is shown at the bottom right (arrows). (*C*) Liver of PBT-pretreated animals immediately following the fifth 6-hr exposure to 5% VCM at 24 hr intervals. Large area of stroma of hepatic lobule depleted of parenchyma is at top (arrows). Liver at bottom appears normal.

conducted from 10 A.M. to 4 P.M. in a dynamic inhalation chamber modeled after Leach (*8*). Concentrations of VCM were adjusted and monitored by gas chromatography (*9*).

For morphologic examination of the liver, animals were anesthetized with pentobarbital 24 hr after the beginning of a single exposure, or immediately after the fifth exposure, portal veins were cannulated, and the liver was briefly perfused with Ringer's lactate containing Isuprel, 1 mg/l., at 37°C, followed by buffered 1% glutaraldehyde. Following fixation, the liver was sliced and tissues for electron microscopy post-fixed in $OsO_4$ and uranyl acetate and embedded in Epon. Appropriately stained sections were examined by light and electron microscopy. Liver slices, embedded in paraffin, were also examined following sectioning and staining by conventional histologic techniques.

## Results and Discussion

Twenty-four hours following the onset of a single exposure of 5% VCM, there is diffuse vacuolization of the cytoplasm of centrolobular liver parenchyma and focal areas of necrosis of midzonal parenchyma in PBT-pretreated rats (Fig. 1*B*). Vacuolization involves approximately two-thirds of the hepatic parenchyma, and midzonal necrosis is focal throughout most of the liver and becomes extensive and confluent toward the dorsal aspect. In contrast, livers of animals exposed to VCM who were not pretreated with PBT appeared normal (Fig. 1*A*).

Livers of PBT-pretreated animals exposed to 5% VCM on five consecutive days contained broad "tracts" of stroma depleted of parenchymal cells which correspond in distribution

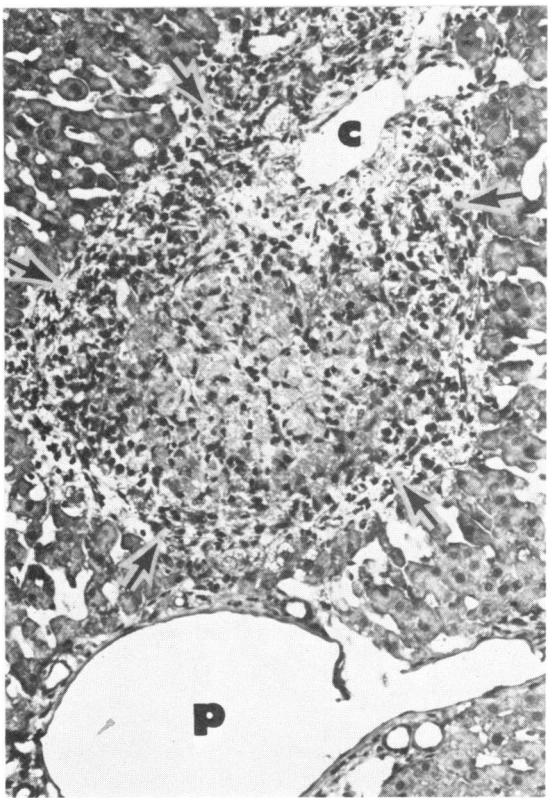


FIGURE 2. Liver of PBT pretreated animal, treatment same as Figure *1C*. Round nodule of parenchymal cell depopulated stroma "bridges" central vein and portal area. Round cells and macrophages abound in interface between normal parenchyma and residual stroma (arrows). ×138.

and extent to the areas of necrosis seen at 24 hr (Fig. 1*C*). These tracts, more prominent about central veins, often extend to portal areas (Fig. 2). The interfaces between these regions and more normal-appearing parenchyma are heavily infiltrated by macrophages. In spite of the fact that these animals were killed immediately following the fifth exposure to VCM and 24 hr following the fourth, no vacuolization of viable hepatic parenchyma was observed—a finding suggesting that injury following the first exposure to VCM protects against recurrent acute injury following the second and subsequent exposures—allowing the nonlethal vacuolar or cellular injury to resolve, and necrosis to heal by reconstitution or scarring. This may be analogous to the protection afforded by a small dose of $CCl_4$ against injury from a large dose of $CCl_4$ subsequently administered (*10*). In contrast, livers of animals exposed to VCM on five consecutive days and who were not pretreated with PBT appeared normal.

Vacuolated liver parenchymal cells in PBT-pretreated rats 24 hr after the onset of exposure to 5% VCM revealed extensive dilation of the cysternae of the rough endoplasmic reticulum and coalescence of the smooth into discrete aggregates of smooth-surfaced tubules conspicuously flecked with areas of increased electron opacity (Figs. 3 and 4). As such, these resemble the labyrinthine tubular aggregates of denatured endoplasmic reticulum which appear as a consequence of poisoning with $CCl_4$ and $CHI_3$ (*6,11*) toxins whose capacities for cellular injury are linked to their reactivity in free-radical reactions (*11*). Although neutral lipid droplets do not appear to be increased, relatively large numbers of chylomicra are seen in the dilated cysternae of the rough endoplasmic reticulum (Figs. 4 and 5). Mitochondria occasionally show "punched out" areas of electron lucency of the mitochondrial matrix (Fig. 4). Golgi are unrecognizable, and nuclei—aside from showing effects of external compression from vacuolar dilitation of the endoplasmic reticulum—appear normal.

Electron-opaque material in aggregates of smooth endoplasmic reticulum 24 hr following VCM exposure appear to be applied to the outer surfaces of tubular profiles and as such, resemble those seen following $CCl_4$ (*6*). Similar changes may also be seen in pellets of microsomes allowed to undergo lipid peroxidation *in vitro* (*12*). Thus, these morphologic changes observed following VCM exposure may result from the initiation of lipid peroxidation by a homolytically cleavable toxin within the membranes of the endoplasmic reticulum. Although numerous ribosomes may be seen in relation to the walls of the vacuoles considered to be dilated cysternae of the rough endoplasmic reticulum (Fig. 5), their relationship to this membrane and their degree of aggregation remain unclear in the relatively thick sections obtained so far.

The ultrastructural observations that the acute liver lesion produced by VCM primarily involves components of the endoplasmic reticulum coupled with the fact that PBT (which is

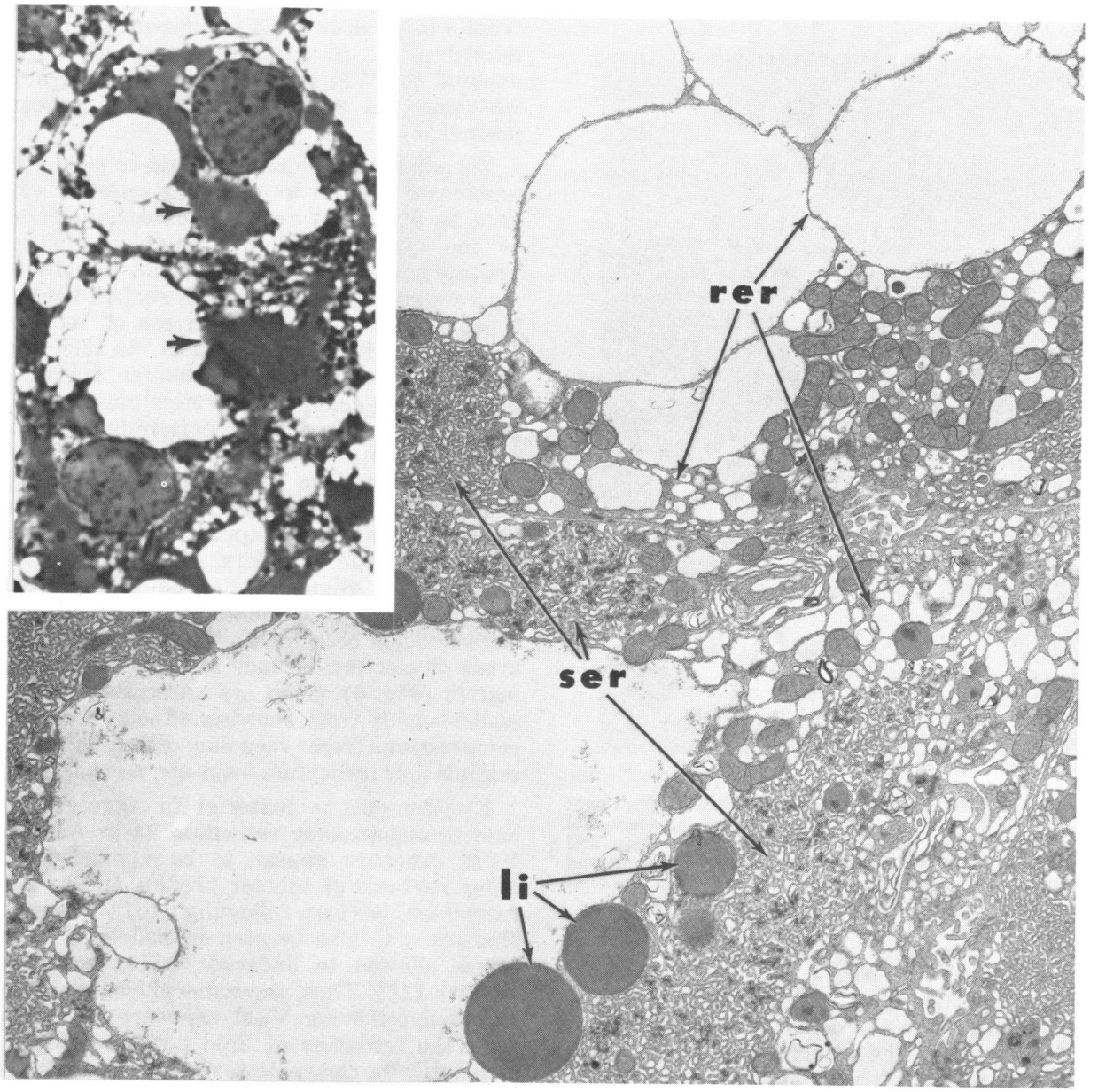


FIGURE 3. Light (inset) and electron microscopic appearance of vacuolated liver parenchymal cells 24 hr following a single 6-hr 5% VCM exposure in a PBT-pretreated animal. Membranes of rough endoplasmic reticulum (RER) form walls of large vacuoles which are essentially free of visible content. Smooth endoplasmic reticulum (SER) forms compact masses which are flecked with areas of increased electron opacity. Several lipid droplets (LI) are seen. ×8000. Inset: Nuclei appear normal. Condensed SER form discrete cytoplasmic masses (arrows). ×3000.

an inducer of mixed function oxidase activity in the endoplasmic reticulum) enhances injury suggests that this organelle is the primary site of generation of toxic metabolites from VCM. Toxic metabolites generated from VCM by the mixed function oxidase system may include epoxides and be responsible for both acute cellular injury and VCM's tumorogenic potential (*13*).

Although this morphological picture of acute injury is distinctive for VCM and indicative of primary injury to the membranes of the

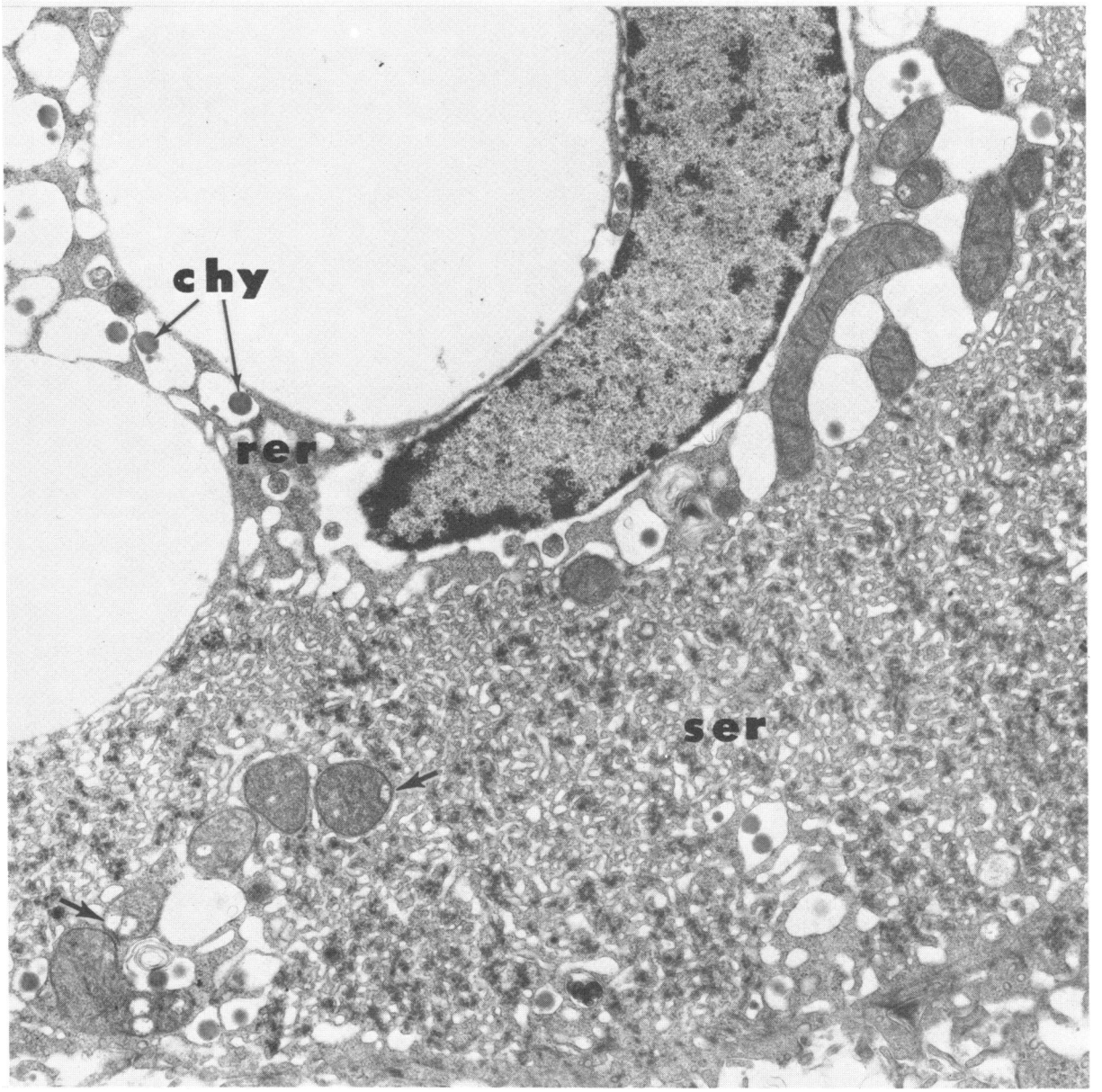


FIGURE 4. Liver of PBT-pretreated animal, treatment same as in Figure 3. Nuclear chromatin is normal. Chylomicra (CHY) are present within dilated cysternae of rough endoplasmic reticulum. Arrows at lower left point to "punched out" electronlucent areas in mitochondrial matrices. ×12,000.

endoplasmic reticulum, this mechanism of toxic action cannot be generalized to all members of the chloroethylene family. Morphologically, the lesion following 1,1-dichloroethylene is totally dissimilar; it seems to involve primarily nuclear chromatin and mitochondria and spare endoplasmic reticulum (*14*).

## Acknowledgements

This investigation was supported by Grants ES–00002, OH–00315, AM–16183, and HL–06370 from the National Institutes of Health. E.S.R. is an NIH Research Career Development Awardee (GM–07309).

FIGURE 5. Liver of PBT-treated animal; treatment same as in Figure 3. Abundant ribosomes are present in cytoplasmic matrix adjacent to membranes lining dilated cysternae of RER. In a focal area of increased electron opacity present in SER, opaque material appears applied to the outer surfaces of tubules of reduced diameters. ×20,000.

## REFERENCES


1. Mastromatteo, E., et al. Acute inhalation toxicity of vinyl chloride to laboratory animals. Am. Ind. J. Hyg. Assoc. J., 22: 354 (1961).
2. Lester, D., Greenberg, L. A., and Adams, W. R. Effects of single and repeated exposure of humans and rats to vinyl chloride. Am. Ind. Hyg. Assoc. J., 24: 265 (1963).
3. Jaeger, R. J., et al. Acute hepatic injury by vinyl chloride in phenobarbital pretreated rats. Nature, in press.
4. Remmer, H. The role of the liver in drug metabolism. Am. J. Med., 49: 617 (1970).
5. Maugh, T. H. Chemical carcinogenesis: a long-neglected field blossoms. Science, 183: 940 (1974).
6. Reynolds, E. S., Ree, H. J., and Moslen, M. T. Liver parenchymal cell injury; IX. Phenoarbital potentiation of endoplasmic reticulum denaturation following $CCl_4$. Lab. Invest. 26: 290 (1972).
7. Reynolds, E. S., and Moslen, M. T. Liver injury following halothane anesthesia in phenobarbital pretreated rats. Biochem. Pharmacol., 23: 189 (1974).
8. Leach, L. J. A laboratory test chamber for studying air-borne materials. AEC Research and Development Report, UR–629, 1 (1963).
9. Jaeger, R. J., Conolly, R. B., and Murphy, S. D. Effect of 18 hr fast and glutathione depletion on 1,1-dichloroethylene-induced hepatotoxicity and lethality in rats. Exptl. Molec. Path. 20: 187 (1974).
10. Glende, E. A., Jr. Carbon tetrachloride-induced protection against carbon tetrachloride toxicity: The role of the liver microsomal drug-metabolizing system. Biochem. Pharmacol., 21: 1697 (1972).
11. Sell, D. A., and Reynolds, E. S. Liver parenchymal cell injury; VIII. Lesions of membranous cellular components following iodoform. J. Cell Biol., 41: 736 (1969).
12. Arstila, A. V., Smith, M. A., and Trump, B. R. Microsomal lipid peroxidation: Morphological characterizations. Science 175: 530 (1972).
13. Block, J. B. Angiosarcoma of the liver following vinyl chloride exposure. J. Am. Med. Assoc. 229: 53 (1974).
14. Jaeger, R. J., et al. Biochemical toxicology of unsaturated halogenated monomers. Environ. Health Perspect. 11: 121 (1975).