of fairly modern design, but the wall plaster was badly cracked and huge flakes of old paint threatened to fall from the ceiling. The x-ray equipment was all antiquated and it was impossible to get replacements for worn parts.

As we walked down the stairs, we noticed that all the metal treads had been removed from the edges of the terrazzo steps. When I inquired about the reason for this, the professor smiled and said quite slowly, "They went into our last big scrap drive—over a year ago!"

Japan, December 3, 1945.

CLINICAL NOTES AND CASE REPORTS

FOOT STRAIN: A VALUABLE SIGN

LEWIS COZEN, M. D.
Los Angeles

THE following is a simple test for the diagnosis of foot strain. Although the sign is well known among orthopedists, other practitioners are generally not familiar with it. Tenderness is felt over the center of the medial border of the longitudinal arch. If pain is present on moderate pressure here a diagnosis of foot strain can usually be made.

It may seem presumptuous to mention so simple a test. The clinical value of the sign has nevertheless not been sufficiently emphasized. The diagnosis of foot strain is often difficult to make. Indeed it is frequently made by exclusion. The examiner eliminates the possibility of peripheral vascular disease, of inflammatory disease and of trauma, and thus static strain is left as the cause of the patient's painful feet. It is evident that if a positive sign for the diagnosis of foot strain could be made rather than a diagnosis by exclusion we would have a more conclusive diagnosis. The presence of valgus deformity of the foot is itself insufficient evidence for a diagnosis of foot strain. Anyone who has examined many human feet has noted many flat feet that caused no symptoms. Therefore, a patient may have flat feet, yet the pain in his feet is not necessarily a result of the deformity. Furthermore, he may have pain in his legs or pain in his back without any pain directly in his foot, and yet all his symptoms may be caused by foot strain. What is the cause of this tenderness in the center of the inner border of the foot? In this area the tendons of insertion of both the Tibialis Anticus and of Tibialis Posticus are very superficial. On dissection of the insertions of these two tendons one will find the tendoosseaus junction surrounded by thin connective tissue having the appearance of a bursa. This filmy connective tissue is both superficial to and deep to the tendinous insertion, and it is probable that this tissue undergoes slight non-specific inflammatory changes. Why should there be irritation at the insertion of these two tendons, the Tibialis Anticus and Tibialis Posticus? Because the entire weight of the body with each step stretches the tendinous insertion. Because the tendons can be easily pressed and irritated between the tarsus and the shoe. (Illustrations of cross sections of the tarsus, appearing in volumes on anatomy, show the superficial position of the tendons of the tibialis anterioris and posterioris.)

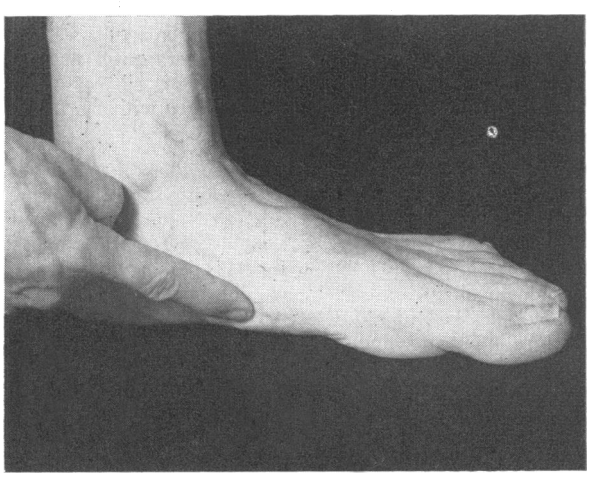

Fig. 1.—Palpation for tenderness to determine presence of strain.

The feet of twenty individuals were used as controls. These twenty adults had no complaints referable to their extremities or to their back. In none of these twenty people was any tenderness present on pressure over the medial border of the foot.

SUMMARY

A simple test for foot strain is emphasized. It consists of point tenderness over the center of the inner border of the tarsal area.

2007 Wilshire Boulevard.

OBSCURE LYMPHOSARCOMA

HOWARD A. BALL, M. D.
San Diego

THIS case is reported not only because it seems to offer a fair opportunity to correlate changes in the differential blood count with the x-ray therapy administered but also to raise a question concerning therapeutic procedure under similar circumstances.

REPORT OF CASE

A white female of 53 years, presented herself with multiple nodular swellings in the neck, axillae and groins and a complaint of generalized abdominal pain and swelling which followed a fall on the abdomen two months previously. She had lost 20 pounds during this two months. She was found to have a left post-pharyngeal swelling, generalized discrete lymphadenopathy and a palpable tender spleen. The lymph nodes were only moderately enlarged. The initial blood count showed 10,150 WBC with 64 per cent lymphocytes, equivalent to about 6,500 lymphocytes per cu. mm. Normally with a 10,000 cell count and a maximum of 35 per cent lymphocytes we would see that 3,500 would be about the high level of normal. Thus her circulating lymphocytes were not quite double the figure but no immature forms were recognized.

An inguinal node was removed for study and findings reported "compatible with leukemic lymphadenosis but they do not warrant a diagnosis of lymphosarcoma."

X-ray therapy was given on the basis of the tissue diagnosis, treating the spleen, both sides of the neck, both axillae and both groins in a system of rotation. Five days after 100 r over the spleen the circulating lymphocytes had dropped from 6,500 to 1,600 per cu. mm.—a rather dramatic change. Four days later, however, this low figure had more than doubled to 3,535 per cu. mm., but at no time subsequently did it ever significantly exceed this figure.

During the first four months a total of 1,500 r were given, 300 r of this over the spleen. At four and one-half months a sudden reversal in the differential count occurred. Nine counts during the initial period had shown an average of 60 per cent of the circulating white blood cells to be lymphocytes. Fourteen counts during the next year and one-half showed an average of only 33 per cent. At one time a year after treatment was instituted the treated glands had disappeared and the intern who saw the patient in good condition in the clinic recorded that

"with this blood count I am skeptical patient ever had leukemia."

During the next four months the patient had some discomfort over the left side and groin and tenderness over the coccyx, and was not seen again for nearly a year when she entered the hospital with bleeding from the nose, anorexia, weakness, loss of weight and migrating skeletal pains. The spleen and a few small inguinal nodes were palpable and the white count showed a total of only 2,000 cells per cu. mm., 68 per cent of which were lymphocytes. Death occurred three weeks later.

The autopsy showed scattered foci of neoplasm along the spine and ribs, about the celiac axis and in the hilus of the spleen and along the abdominal aorta. The spleen and liver were moderately enlarged and the kidney parenchyma adjacent to the pelves was infiltrated with tumor. Both the sternal and femoral bone marrow were almost white from neoplastic involvement.

Final diagnosis: lymphosarcoma.

COMMENT

It may be observed that those areas of most extensive involvement at autopsy are almost without exception those areas not subjected to radiation previously. The spleen is the only exception, and this area was not treated on the presumption of neoplasm. We are faced, then with the question of whether in a case of systemic lymphadenopathy that responds well to external radiation we should not also include treatment to the visceral gland-bearing areas lying chiefly along the midline of the thorax and abdomen, even in the absence of symptoms referable to them. I am inclined to believe that we should.

233 A. Street.

VINCENT'S ANGINA—SOME DIAGNOSTIC PITFALLS*

CAPTAIN NICHOLAS P. POPOV
MEDICAL CORPS, ARMY OF THE UNITED STATES
San Francisco

THE usual symptoms of Vincent's angina of the tonsils are acute or subacute tonsillitis. Temperature ranges from normal to 103° F. Patient complains of headaches, chilly sensations, generalized malaise, sore mouth and gums and pain in swallowing. Some patients have no constitutional disturbances and the condition is recognized only on objective examination. Other patients may exhibit most violent symptoms, submaxillary and cervical gland enlargements, tenderness and severe pain on talking or swallowing. All have fetid breath. The ulcer may be single or multiple, commonly involving one tonsil, most frequently at its upper part. At other times both tonsils are involved or the ulcers may spread to the soft palpate, pharynx and the gums. As a rule, the ulcers are grayish-white, surrounded by a red, inflamed areola and bleed easily after palpation or removal of the membrane. A debilitated state of health, decayed teeth, oral uncleanliness and inflamed gums, favor the development of the disease.

The clinical diagnosis is confirmed by microscopic examination of a fresh smear taken directly from the ulcer, or a section of the pseudomembrane, and discovery of the fusiform bacillus and spirillum which are the typical Vincent's angina bacteria.

The disease is acute, subacute or chronic and is subject to recurrence.

AUTHOR'S SERIES

During the period of a year, 164 patients were admitted 176 times to the Station Hospital, DAAB, DeRidder, Louisiana, with diseases of the tonsils. Some of the patients came in with chief complaints other than referable to the tonsils.

Disease	*No. of Patients*	*No. of Admissions*
Vincent's angina, tonsillar	17	18
Tonsillitis, hypertrophic, acute	26	30
Tonsillitis, hypertrophic, chronic	78	79
Tonsillitis, follicular, acute	36	41
Tonsillitis, follicular, chronic	7	8
Total	164	176

Some 10.5 per cent of all admissions for disease of the tonsils were tonsillar Vincent's angina; 4.2 per cent of all tonsillectomies, or 4 out of 98 operations, were performed as a result of tonsillar Vincent's angina.

Vincent's angina is frequently confused with follicular (Lacunar) tonsillitis, diphtheria, syphilis and acute leukemia. Each case of disease of the tonsils that was admitted in which Vincent's angina, tonsillar, was suspected, received a Kahn test to rule out syphilis, and a smear to confirm clinical diagnosis of Vincent's angina, and to positively rule out follicular tonsillitis and diphtheria. Acute leukemia was excluded by a complete blood count.

One case of infectious mononucleosis had acute follicular tonsillitis that clinically had a characteristic appearance of Vincent's angina. A smear was taken three times, but each time was unsatisfactory for microscopic examination.

Another case of Vincent's angina of the tonsils had extensive ulcerative lesions on the mucous membranes of the mouth.

Three cases were complicated by stomatitis, ulcerative, due to Vincent's organisms.

One case of acute hypertrophic tonsillitis and three cases of acute follicular tonsillitis were complicated by peritonsillar abscess.

Most of the patients were treated by their squadron surgeons first, and if they failed to improve, were sent into the Nose and Throat Clinic where they were hospitalized.

The diagnosis of acute and chronic hypertrophic tonsillitis and of chronic follicular tonsillitis constituted no diagnostic problem, but most of the Vincent's angina cases were diagnosed by squadron surgeons as acute follicular tonsillitis. Some patients were treated in their organizations as long as 10 days for acute follicular tonsillitis until they were referred to the Ear, Nose and Throat Clinic and diagnosed as Vincent's angina of the tonsils.

Of the acute suppurative tonsils, there were 41 admissions with acute follicular tonsillitis and 18 with Vincent's angina of the tonsils. From that study of acute tonsils with suppuration, 30.5 per cent were Vincent's angina.

COMMENT

Of all the admissions for diseases of the tonsils, 10.5 per cent were diagnosed as tonsillar Vincent's angina, and 30.5 per cent of all acute suppurative diseases of the tonsils were similarly diagnosed.

Because of the high incidence of Vincent's angina of the tonsils and its easy transmission from one person to another by dishes, towels, kissing, etc., it is urged that all cases suggestive of Vincent's angina be more closely inspected by means of a smear for more accurate diagnosis.

With greater alertness on the part of every physician for possible Vincent's angina, the incidence of this disease could be reduced both in armed forces and among civilian population, saving thousands of people from temporary disability.

AAF Regional Hospital, Drew Field, Tampa, Fla.

---

* This article has been released for publication by the Review Branch, War Department Bureau of Public Relations. The opinions and views set forth in this article are those of the writer and are not to be considered as reflecting the policies of the War Department, or the military service at large.