J. Anat. (1999) **195**, pp. 27–38, with 4 figures Printed in the United Kingdom

Ultrastructural study of the relationship between the morphogenesis of filiform papillae and the keratinisation of the lingual epithelium in the rat

S. IWASAKI[1], H. YOSHIZAWA[2] AND I. KAWAHARA[2]

[1] *Advanced Research Centre, The Nippon Dental University School of Dentistry at Niigata, and* [2] *Department of Biology, Matsumoto Dental College, Shiojiri, Japan*

(*Accepted 2 March 1999*)

ABSTRACT

Tongues were removed from rat fetuses on d 16 of gestation (E16) and from newborn (P0) and juvenile rats on d 7 (P7) and d 21 (P21) postnatally for examination by light and transmission electron microscopy. In the fetuses at E16, no rudiments of filiform papillae were visible on the dorsal surface of the tongue. No evidence of keratinisation could be recognised over the entire dorsal lingual epithelium. At P0, rudiments of filiform papillae showed a similar distribution to that seen in the adult, but had a more rounded appearance. The columnar structure of cells in the epithelium, with the different degrees of keratinisation as observed in the mature adult, was indistinct, but a keratinised layer was clearly located at the tip of each filiform papilla. In juveniles at P7, the filiform papillae on the anterior part of the tongue were long and slender, and the anterior and posterior cell columns of the filiform papillae and the interpapillary cell columns were clearly distinguishable. In juveniles at P21, the structure of filiform papillae was identical to that in the adult. These results indicate that, in rats, the morphogenesis of filiform papillae advances in parallel with keratinisation of the lingual epithelium from just before birth to a few weeks after birth.

Key words: Tongue; mucosa; morphogenesis.

INTRODUCTION

The lingual dorsal epithelium of adult mammals is generally composed of regularly ordered columns of cells with different degrees of keratinisation, namely, the anterior cell columns of the filiform papillae, the posterior cell columns of the filiform papillae and the interpapillar cell columns (Farbman, 1970; Iwasaki & Miyata, 1989, 1990). In most mammals, keratohyalin granules are recognisable only in the anterior region of the filiform papillae (Farbman, 1970; Iwasaki & Miyata, 1989; Iwasaki, 1992*a*; Iwasaki et al. 1992*a*) but the details of the morphogenesis of these papillae during development and growth remain to be clarified.

Iwasaki et al. (1996*a*, 1997*a*) have demonstrated, in rats and mice, that the rudiments of fungiform and circumvallate papillae, which are related to the sense of taste, are visible earlier than those of the filiform papillae, which are not involved in this phenomenon. Furthermore, many studies have shown that sensory nerves play an important role in the formation of gustatory papillae (e.g. Farbman & Mbiene, 1991; Whitehead & Kachele, 1994) and this role has been confirmed by the results of denervation experiments (Olmsted, 1922; Torrey, 1934; Guth, 1957, 1971; Farbman, 1965; Whitehead et al. 1987; Hårdd af Segerstad et al. 1989). By contrast, there have been very few studies of the morphogenesis of filiform papillae (e.g. Baratz & Farbman, 1975) and of the changes in filiform papillae during their development and growth (e.g. Iwasaki, 1993). These studies have not provided any evidence that the existence of gustatory nerves is important for the formation of filiform papillae. The factors that control the morphogenesis of filiform papillae remain to be determined.

The present study was designed to provide basic data for studies of the relationship between the

Correspondence to Dr Shin-ichi Iwasaki, Advanced Research Centre, The Nippon Dental University School of Dentistry at Niigata, 1–8 Hamaura-cho, Niigata 951-8580, Japan. Tel: +81-25-267-1500 (ext. 447); fax: +81-25-267-1134; e-mail: iwasaki@ngt.ndu.ac.jp

morphogenesis of the filiform papillae and the progress of keratinisation of the lingual epithelium. We used both light and transmission electron microscopy to clarify the histological and ultrastructural changes that occur during the morphogenesis of the filiform papillae in the development of rats. A discussion is also presented of the morphogenesis of filiform papillae.

MATERIALS AND METHODS

Sprague-Dawley rats (SPF; Japan SLC, Hamamatsu City, Japan) were used for observations. 16-wk-old females were caged with breeding males of the same age and examined for vaginal plugs; the day that a plug was observed was considered to be the first day of gestation (E1). The gestation period in this strain of rats is 21 d. Fetuses were removed on E16 from pregnant female rats after slaughter with an intraperitoneal overdose of sodium pentobarbital (200 mg/kg body weight). The tongues were also removed from rats at different postnatal stages: just after birth (P0); on d 7 (P7); and on d 21 (P21). Five fetuses or juveniles were used in each group.

The isolated tongues were immediately fixed in half-strength Karnovsky solution that contained 2% paraformaldehyde and 1.25% glutaraldehyde (pH 7.4). After rinsing in 0.1 M cacodylate buffer, some of the samples for transmission electron microscopy were postfixed in a phosphate-buffered solution (pH 7.4) of 1% osmium tetroxide at 4 °C for 1.5 h. This procedure was followed by dehydration, embedding in epoxy resin, ultrathin sectioning and contrasting with lead citrate and uranyl acetate. The specimens were then observed under a transmission electron microscope (JEM-1200 EX; JEOL, Tokyo). Semithin sections ($\sim$ 1 μm) from blocks of tissue embedded in epoxy-resin were stained with 0.2% toluidine blue in 2.5% Na_2CO_3. Photomicrographs of sections were taken under a light microscope (BH-2; Olympus, Tokyo).

RESULTS

Fetuses at E16

Light microscopy revealed that the dorsal lingual epithelium was composed of several layers of non-keratinised cells. Each cell from the basal layer to the intermediate layer was round in shape, and had a large round nucleus. Cells on the free-surface side were somewhat flattened. The lamina propria was located beneath the epithelium (Fig. 1*A*).

Transmission electron microscopy revealed that each cell from the basal layer to the intermediate layer was cuboidal or oval with a similarly shaped nucleus. A large number of free ribosomes was distributed in the entire cytoplasm of these cells. Small round mitochondria and tonofibrils were dispersed in the cytoplasm of cells located from the basal layer to the intermediate layer. The basal lamina was intercalated between the basal cells of the epithelium and the lamina propria (Fig. 1*B*, *C*). Cells in a layer on the free-surface side were significantly flattened. These cells had lost most of their organelles apart from fibrous structures, and the nuclei had disappeared (Fig. 1*D*).

Newborns at P0

Light microscopy revealed that rudiments of filiform papillae showed a similar distribution to that seen in the adult, but had a more rounded appearance. The epithelial cells from the basal layer to the deep intermediate layer were cuboidal. They became flatter from the shallow intermediate layer to the surface layer, and cells in the surface layer were significantly flattened. In addition, the cells in the surface layer stained metachromatically with toluidine blue and their nuclei had almost all disappeared. These features indicated a tendency towards keratinisation (Fig. 2*A*).

Transmission electron microscopy showed that each cell in the basal layer was cuboidal with a cuboidal nucleus. Relatively large numbers of free ribosomes were distributed in the cytoplasm, as in fetuses at E16. There were more tonofibrils than in fetuses at E16 and mitochondria were relatively dispersed (Fig. 2*B*). These features remained almost the same from the basal layer to the deep intermediate layer in all of the anterior and posterior cell columns of filiform papillae, as well as in the interpapillary cell columns. These columns were clearly distinguishable from the shallow intermediate layer to the surface layer. The most significant feature was the presence of keratohyalin granules in the cytoplasm of cells of the intermediate layer in the anterior cell columns of the filiform papillae. Tonofibrils increased in number from the deep intermediate layer to the shallow intermediate layer. In the shallow intermediate layer, there was a scattering of round keratohyalin granules, their longest axes varying from 50 nm to 800 nm. A large number of free ribosomes was widely distributed in the cytoplasm, and tonofibrils were seen between the ribosomes (Fig. 2*C*). The surface layer was

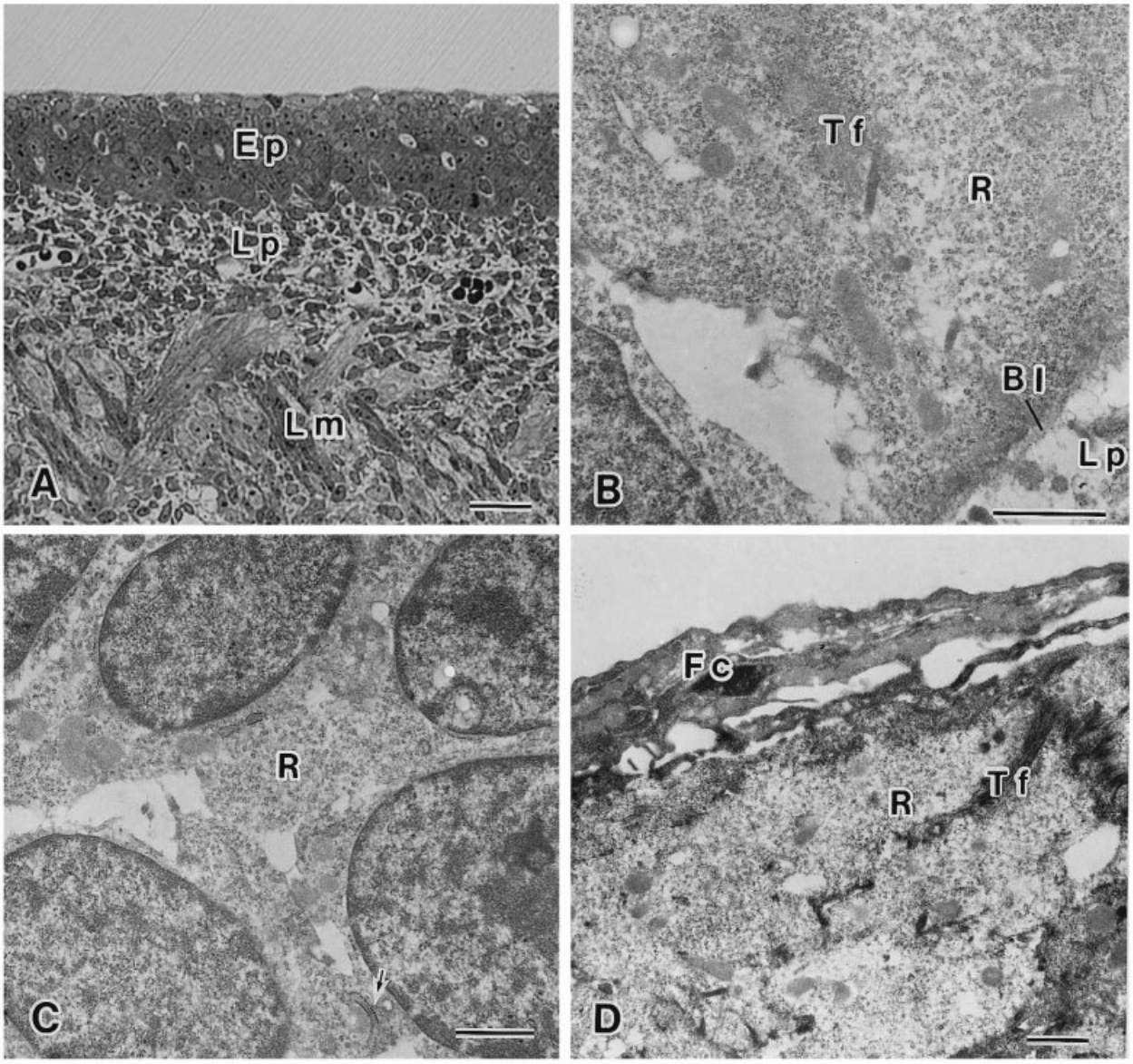

Fig. 1. Light and transmission electron micrographs of dorsal lingual epithelium of fetal rats at E16. (*A*) Light micrograph of the dorsal lingual mucosa. Ep, lingual epithelium; Lp, lamina propria; Lm, lingual muscle. Bar, 10 μm. (*B*) Transmission electron micrograph of basal layer cell of dorsal epithelium of lingual body. R, free ribosomes; Tf, tonofibrils; Bl, basal lamina; Lp, lamina propria. Bar, 1 μm. (*C*) Transmission electron micrograph of epithelial cells of intermediate layer of epithelium of lingual body. R, free ribosomes; arrow, desmosomes. Bar, 1 μm. (*D*) Transmission electron micrograph of epithelial cells on the free-surface aspect of epithelium of lingual body. R, free ribosomes; Tf, tonofibrils; Fc, significantly flattened cells. Bar, 1 μm.

keratinised and composed of several layers of cells. Most organelles apart from keratin fibres had disappeared (Fig. 2*D*). The cells located just under the keratinised surface layer contained large numbers of tonofibrils. In the posterior cell column of the filiform papillae, no keratohyalin granules were observed in the shallow intermediate layer. Instead, the cells in this layer were filled with tonofibrils. Degenerating mitochondria and free ribosomes were scattered between the bundles of tonofibrils, and the nuclei had begun to disappear. A typical layer of keratinised cells was located on the surface aspect and was several cells thick. These cells were filled with electron-dense keratin fibres and contained almost no other organelles or nuclei (Fig. 2*E*). In the interpapillary cell columns, the cells were relatively large in the deep intermediate layer as compared with those in the anterior and posterior cell columns of the filiform papillae. A large round nucleus was also located at the centre of each cell. Most of the cytoplasm of these cells was filled with free ribosomes. Mitochondria were also seen in the cytoplasm (Fig. 2*F*). In the shallow intermediate layer, most cells were somewhat flattened. However, the nucleus was relatively round

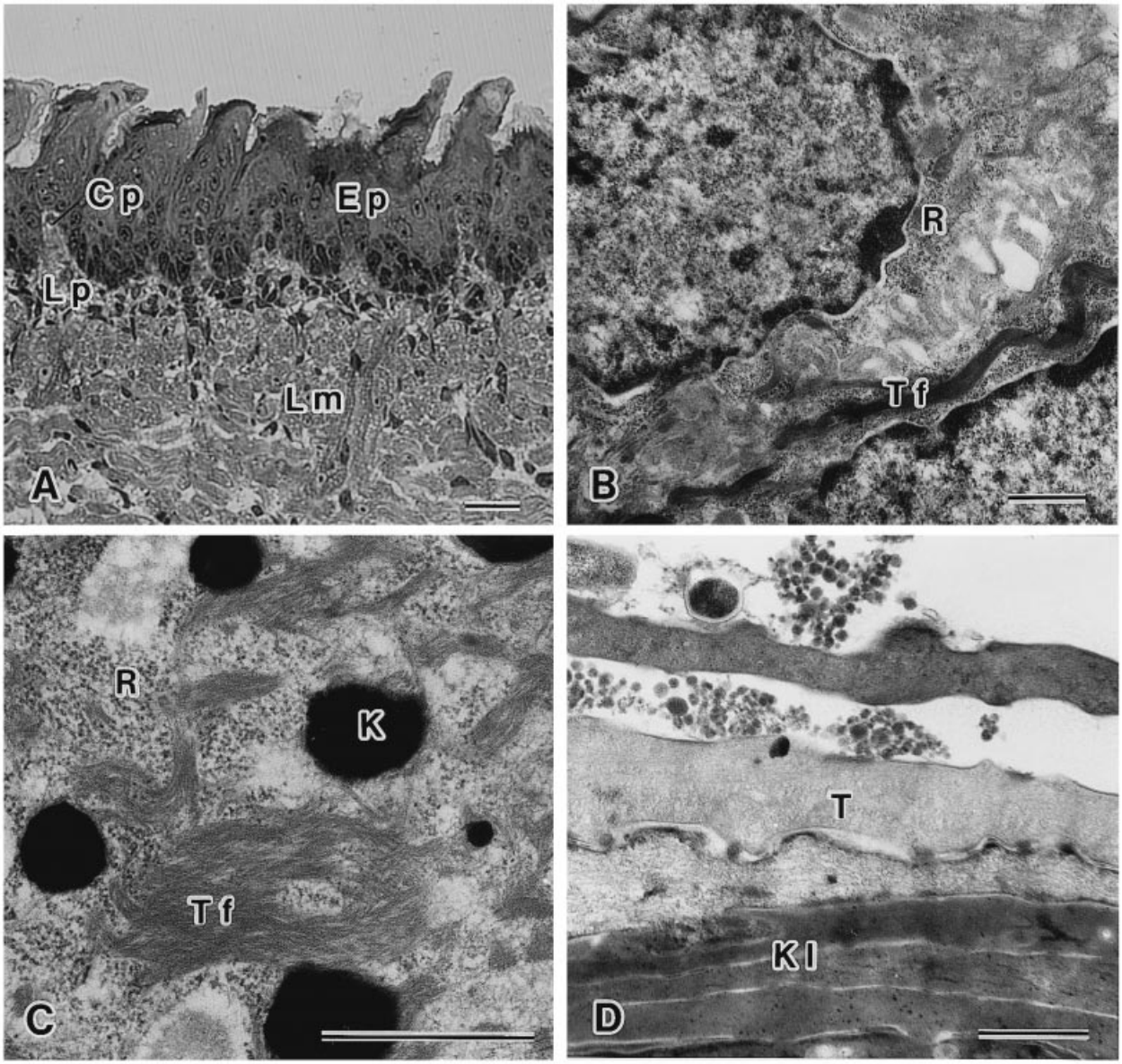

Fig. 2. For legend see opposite.

and was located in the centre of each cell. Most of the cytoplasm of these cells was filled with tonofibrils and free ribosomes. Degenerating mitochondria were scattered between tonofibrils. A few cells had lost their nuclei and were filled with relatively electron-dense tonofibrils. Desmosomes were often intercalated between neighbouring cells (Fig. 2*G*). The surface layer of the interpapillary cell column did not contain the typical keratinised cells. The outlines of the cells located on the free-surface aspect were not as flattened and were filled with tonofilaments rather than keratin fibres. Other organelles were rarely observed. Microridges were better developed as far as the surface layer than in the anterior and posterior cell columns of the filiform papillae (Fig. 2*H*). Large numbers of desmosomes were intercalated between neighbouring cells from the basal layer to the surface layer (Fig. 2*B–H*). The distribution pattern of desmosomes showed no significant changes between all stages of postnatal development observed.

Juveniles at P7

Light microscopic observations of the dorsal epithelium of the middle area of the body of the tongue revealed that filiform papillae showed a similar distribution to that seen in newborns at P0, but came to be conical in shape, differing somewhat from those in the adult. The tips of the filiform papillae were still rounded and any inclination of their apices in the

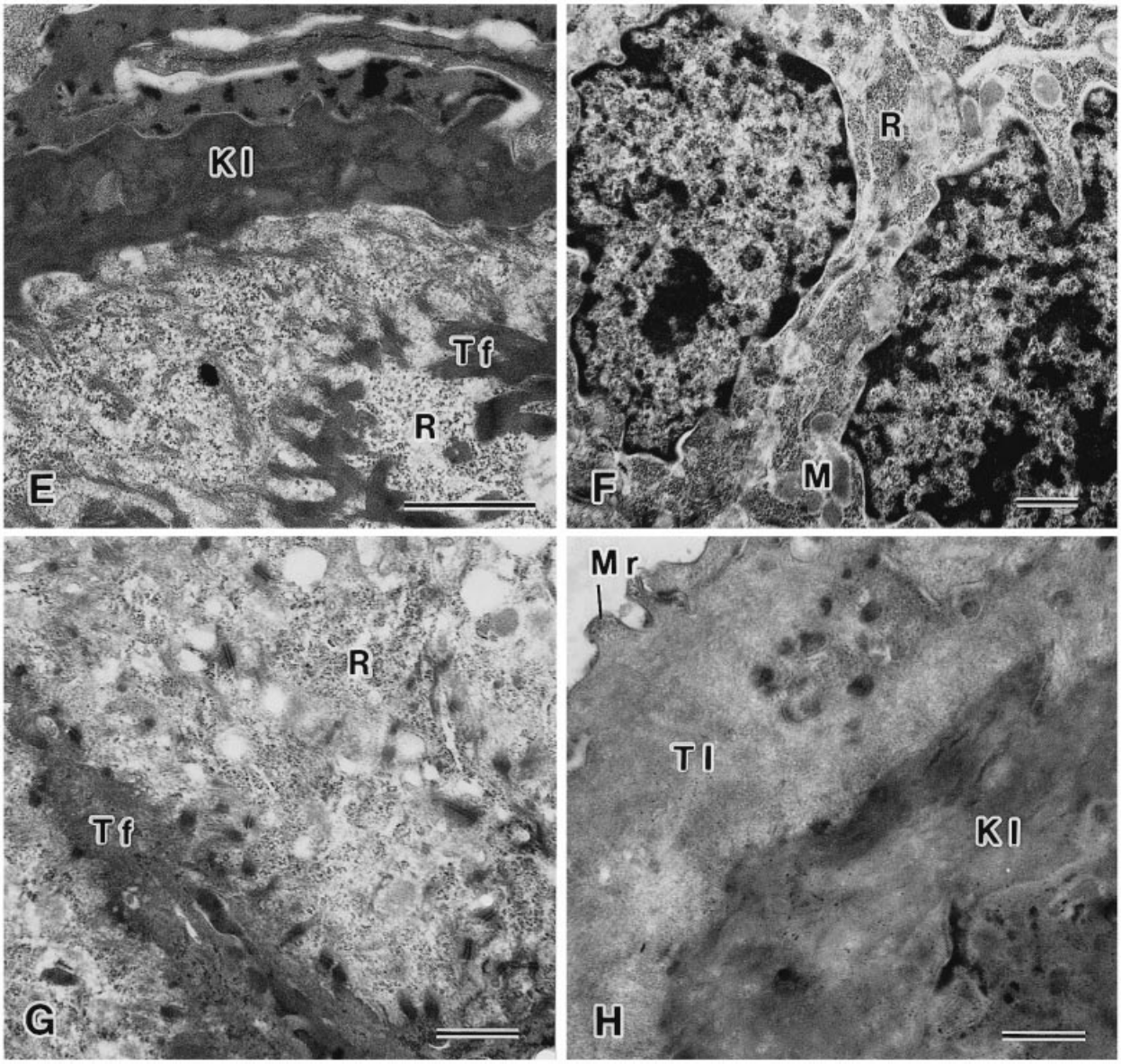

Fig. 2. Light and transmission electron micrographs of dorsal lingual epithelium of newborn rats (P0). (*A*) Light micrograph of dorsal lingual mucosa. Ep, lingual epithelium; Lp, lamina propria; Cp, connective tissue papilla; Lm, lingual muscle. Bar, 10 μm. (*B*) Transmission electron micrograph of cells of the deep intermediate layer of the dorsal epithelium of the lingual body. R, free ribosomes; Tf, tonofibrils. Bar, 1 μm. (*C*) Transmission electron micrograph of epithelial cells from the shallow intermediate layer to the surface layer of the anterior cell column of a filiform papilla. R, free ribosomes; Tf, tonofibrils; K, keratohyalin granule. Bar, 1 μm. (*D*) Transmission electron micrograph of epithelial cells of the surface layer of the anterior cell column of a filiform papilla. T, tonofilaments; Kl, keratinised surface layer. Bar, 1 μm. (*E*) Transmission electron micrograph of epithelial cells in border region from the shallow intermediate layer to the surface layer of the posterior cell column of a filiform papilla. R, free ribosomes; Tf, tonofibrils; Kl, keratinised surface layer. Bar, 1 μm. (*F*) Transmission electron micrograph of epithelial cells in the deep intermediate layer of an interpapillary cell column. M, mitochondria, R, free ribosomes. Bar, 1 μm. (*G*) Transmission electron micrograph of epithelial cells in the shallow intermediate layer of an interpapillary cell column. R, free ribosomes; Tf, tonofibrils. Bar, 1 μm. (*H*) Transmission electron micrograph of epithelial cells in the surface layer of an interpapillary cell column. Tl, tonofilaments; Kl, keratinised surface layer; Mr, microridges. Bar, 1 μm.

direction of the root of the tongue was indistinct. Anterior and posterior cell columns of filiform papillae and interpapillary cell columns were distinguishable. The cells of all 3 types of column became flatter from the shallow intermediate layer to the surface layer and this tendency was significant in the surface layer. Furthermore, the cells in the surface layer stained strongly or metachromatically with toluidine blue and their nuclei had almost completely disappeared. Keratohyalin granules were observed in the intermediate layer of the anterior cell columns of filiform papillae, and the cells of the posterior cell columns of the papillae were significantly flattened from the intermediate to the surface layers. The

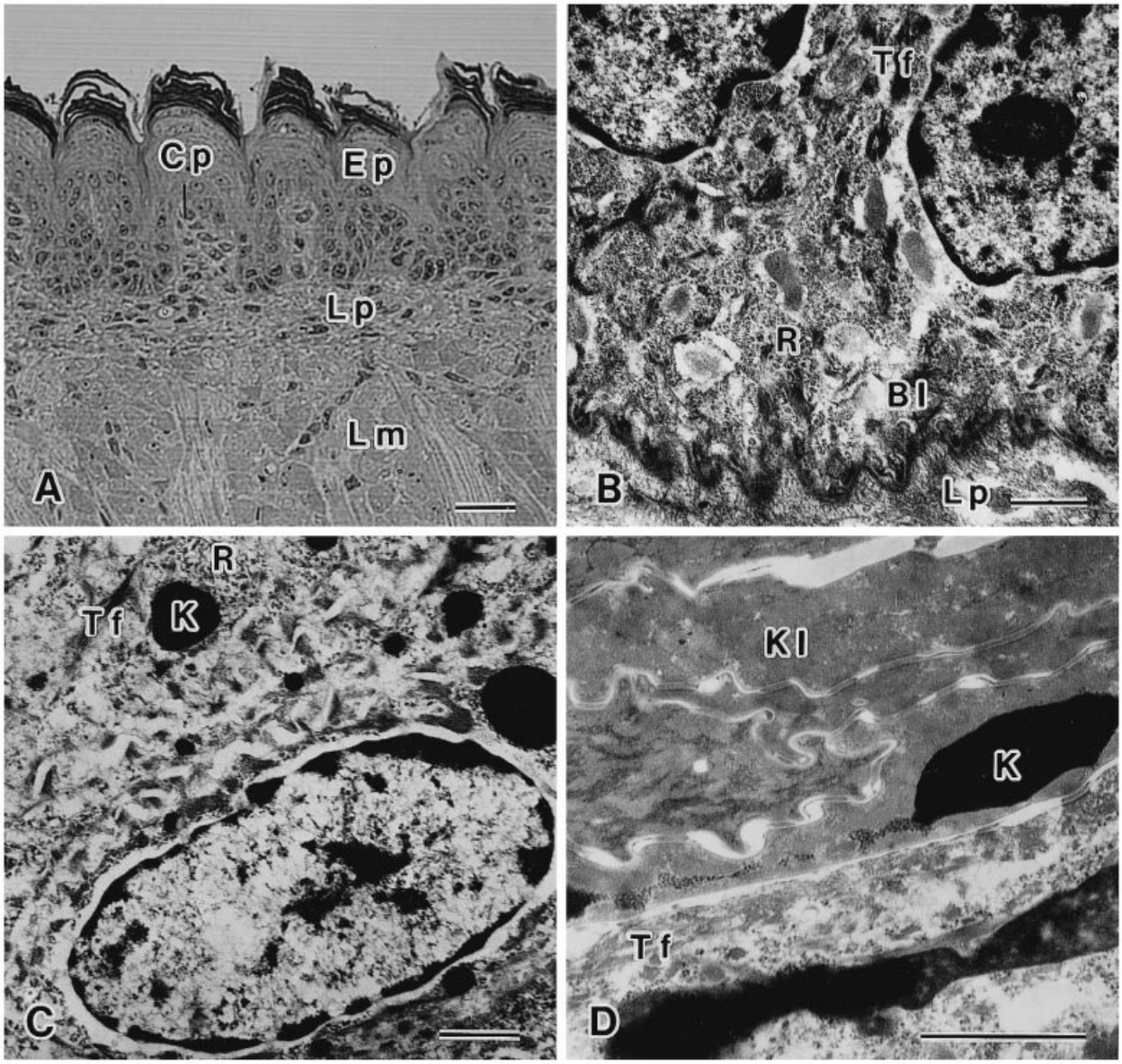

Fig. 3. For legend see opposite.

interpapillary epithelium was restricted to a relatively narrow area (Fig. 3*A*).

Under the transmission electron microscope, the features of cells from the basal layer to the deep intermediate layer in the anterior and posterior cell columns of filiform papillae and in the interpapillary cell columns were almost the same as in fetuses at E16 and in newborns at P0 (Fig. 3*B*). Keratohyalin granules were evident in the border area between the deep intermediate layer and the shallow intermediate layer of the anterior cell columns of the filiform papillae. Large numbers of round keratohyalin granules, varying in diameter from 0.1 μm to 1.5 μm, were widely distributed in the cytoplasm. Some were elongated with a long axis > 2 μm. Tonofibrils were scattered between keratohyalin granules and free ribosomes (Fig. 3*C*). The cells located just under the keratinised surface layer contained large numbers of tonofibrils among round keratohyalin granules, and free ribosomes were widely distributed. The surface layer was composed of several layers of keratinised cells as in newborns at P0. Most organelles, apart from keratin fibres, had been lost (Fig. 3*D*). In the posterior cell columns of filiform papillae, very few keratohyalin granules were observed in the shallow intermediate layer. Instead, the cells in this layer were filled with large numbers of tonofibrils both in the deep and the shallow intermediate layers. A few degenerating mitochondria and free ribosomes were scattered between these fibrillary bundles, and nuclei began to disappear in the shallow intermediate layer. Very few keratohyalin-like granules were recognisable

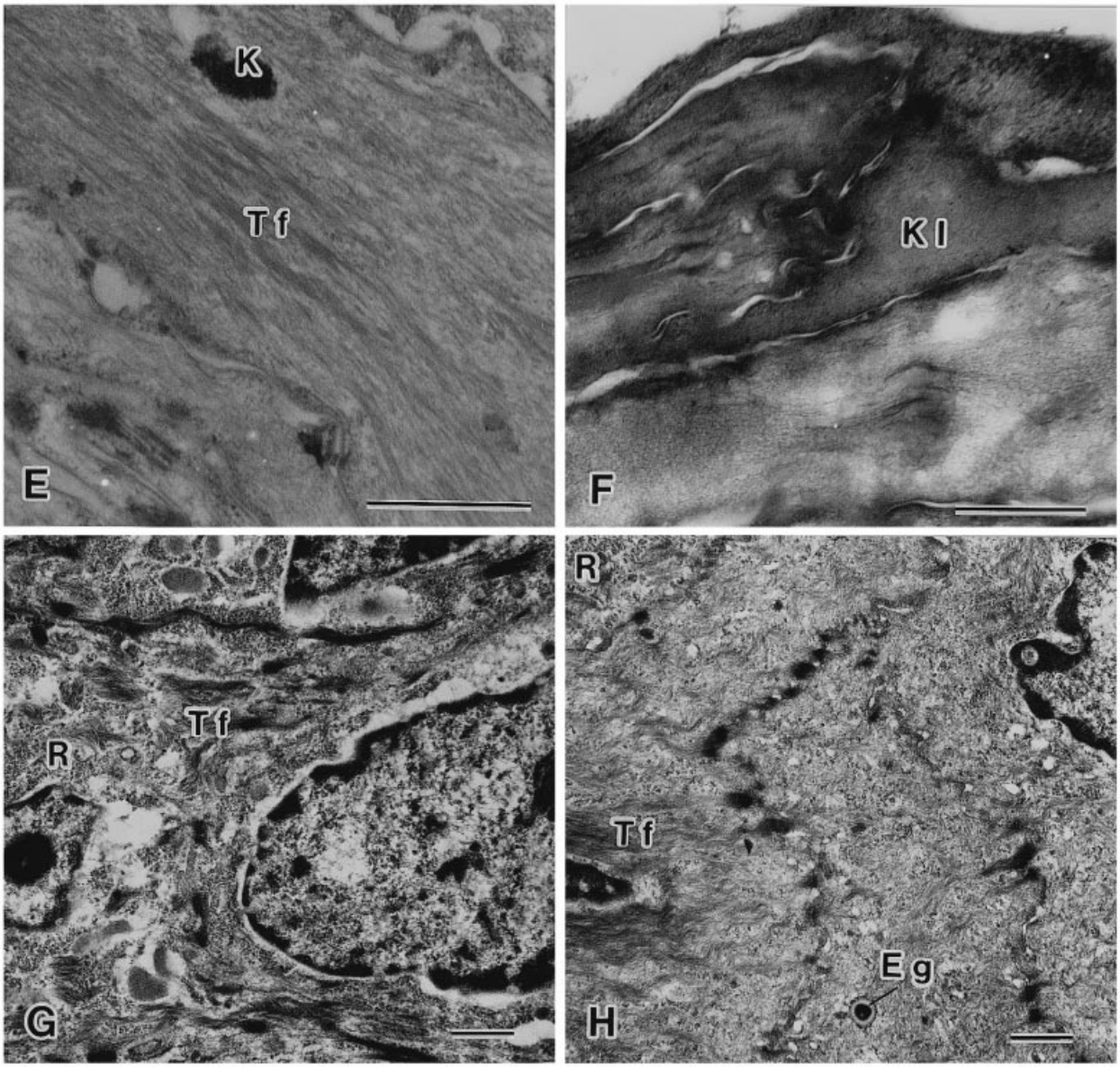

Fig. 3. Light and transmission electron micrographs of dorsal lingual epithelium of juvenile rats at P7. (*A*) Light micrograph of the dorsal lingual mucosa. Ep, lingual epithelium; Lp, lamina propria; Cp, connective tissue papilla; Lm, lingual muscle. Bar, 10 μm. (*B*) Transmission electron micrograph of basal layer cells of the anterior cell column of a filiform papilla. Tf, tonofibrils; R, free ribosomes; Bl, basal lamina; Lp, lamina propria. Bar, 1 μm. (*C*) Transmission electron micrograph of epithelial cells in the shallow intermediate layer of the anterior cell column of a filiform papilla. R, free ribosomes; Tf, tonofibrils; K, keratohyalin granule. Bar, 1 μm. (*D*) Transmission electron micrograph of epithelial cells in the surface layer of the anterior cell column of a filiform papilla. Tf, tonofibrils; K, keratohyalin granule; Kl, keratinised surface layer. Bar, 1 μm. (*E*) Transmission electron micrograph of epithelial cells in the shallow intermediate layer of the posterior cell column of a filiform papilla. Tf, tonofibrils; K, keratohyalin granules. Bar, 1 μm. (*F*) Transmission electron micrograph of epithelial cells in the surface layer of the posterior cell column of a filiform papilla. Kl, keratinised cell layer. Bar, 1 μm. (*G*) Transmission electron micrograph of epithelial cells in the deep intermediate layer of an interpapillary cell column. R, free ribosomes; Tf, tonofibrils. Bar, 1 μm. (*H*) Transmission electron micrograph of epithelial cells in the shallow intermediate layer of an interpapillary cell column. R, free ribosomes; Tf, tonofibrils; Eg, membrane-enclosed granule. Bar, 1 μm.

(Fig. 3*E*). A typical keratinised layer was located on the surface aspect and was more than 10 cells thick. These cells were filled with electron-dense keratin fibres and contained almost no other organelles and nuclei. Microridges were not recognised on the cell membranes on the free surface aspect (Fig. 3*F*). In the interpapillary cell columns, the size of cells was significantly larger in the intermediate layer compared with the anterior and posterior cell columns of the filiform papillae (Fig. 3*G*, *H*). A large round or oval nucleus was located at the centre of each cell in the deep intermediate layer. Tonofibrils, free ribosomes and mitochondria were observed in the cytoplasm (Fig. 3*H*). The cells became elongated or irregular in shape as compared with those in the deep intermediate layer, and the profiles of nuclei were irregular. Most of

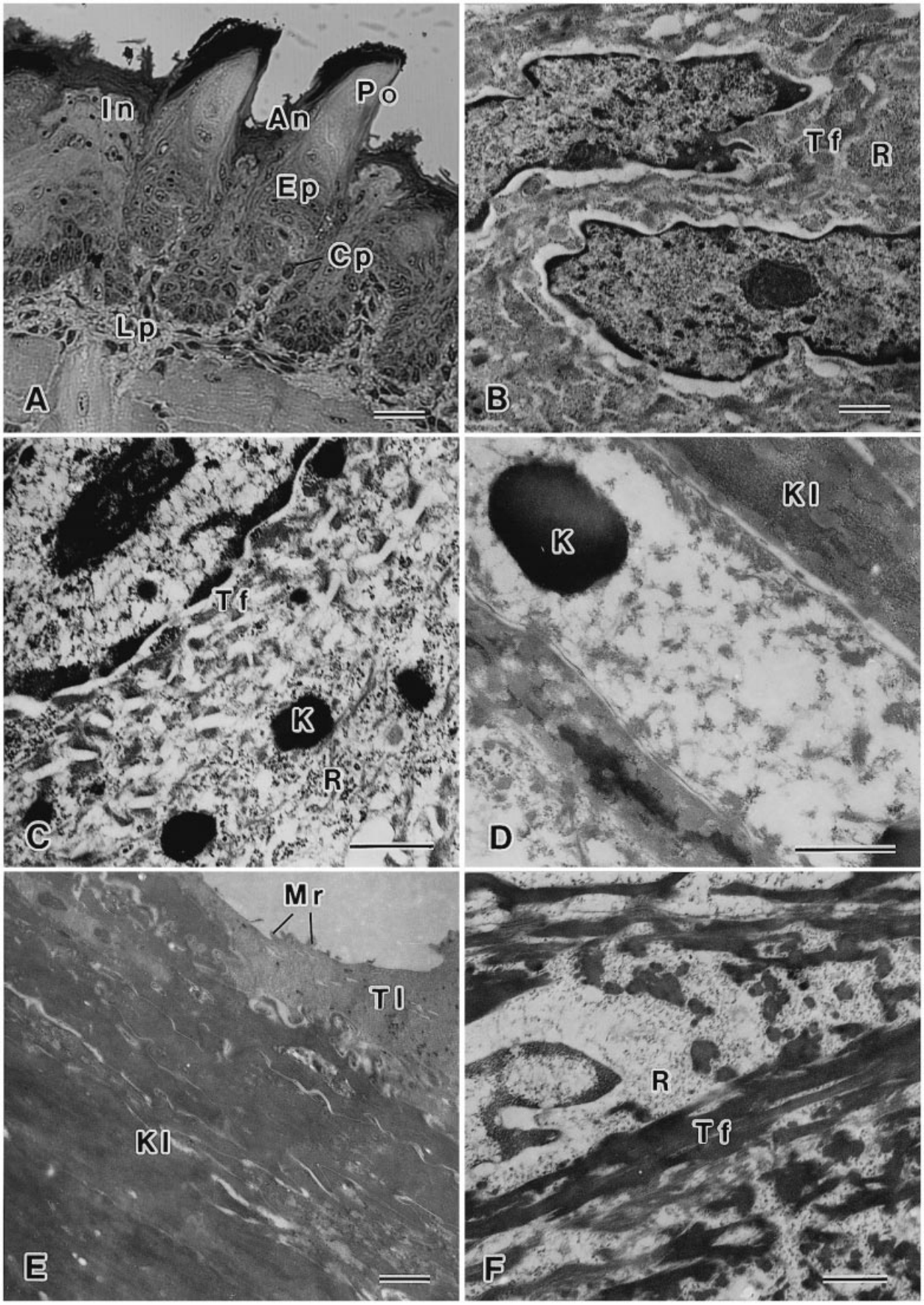

Fig. 4. For legend see opposite.

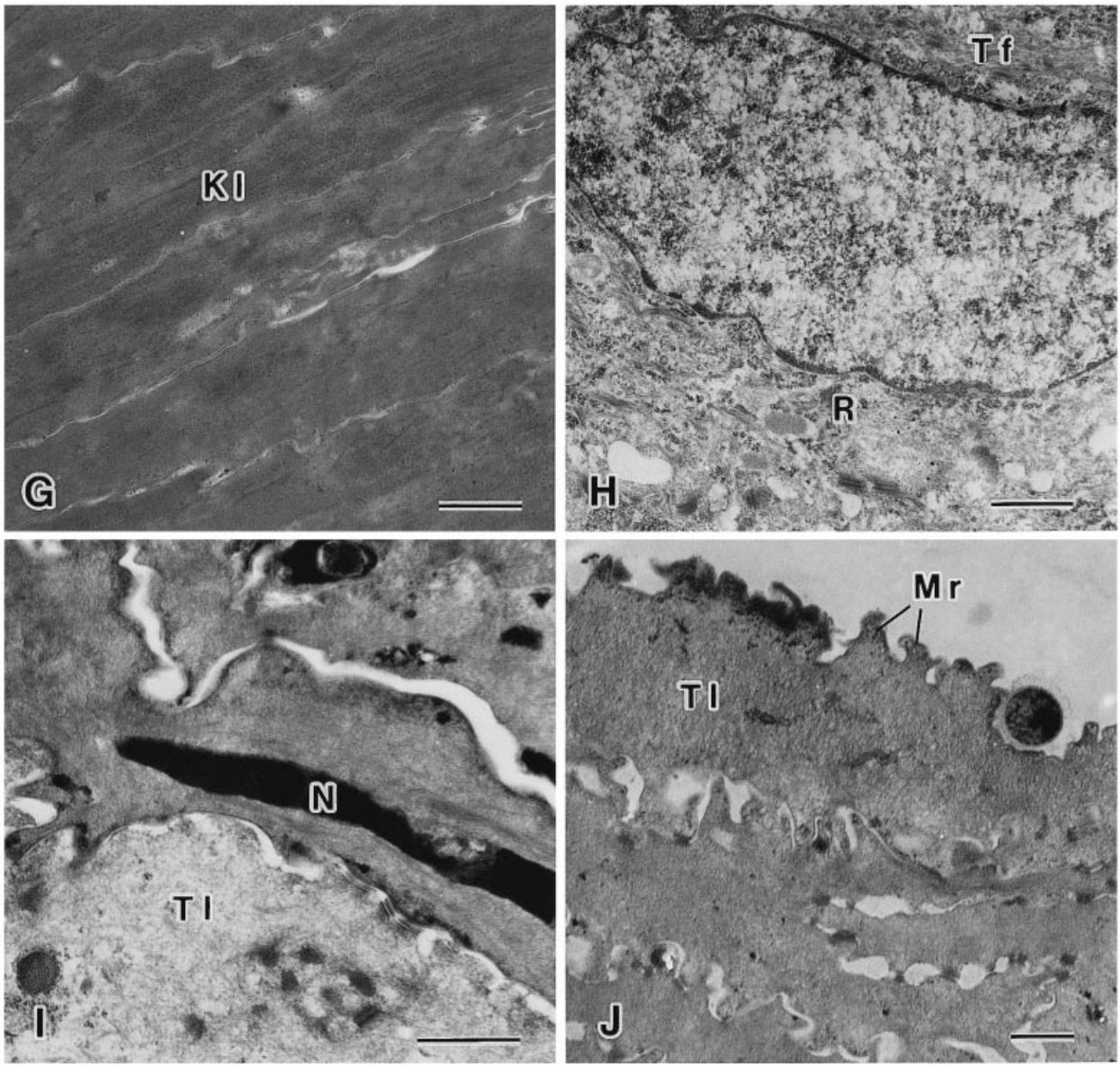

Fig. 4. Light and transmission electron micrographs of dorsal lingual epithelium of juvenile rats at P21. (*A*) Light micrograph of the dorsal lingual mucosa. Ep, lingual epithelium; Lp, lamina propria; Cp, connective tissue papilla; An, anterior side of a filiform papilla; Po, posterior side of a filiform papilla; In, interpapillary area. Bar, 10 μm. (*B*) Transmission electron micrograph of epithelial cells in the deep intermediate layer of the anterior cell column of a filiform papilla. Tf, tonofibrils; R, free ribosomes. Bar, 1 μm. (*C*) Transmission electron micrograph of epithelial cell in the shallow intermediate layer of the anterior cell column of a filiform papilla. R, free ribosomes; Tf, tonofibrils; K, keratohyalin granule. Bar, 1 μm. (*D*) Transmission electron micrograph of epithelial cells in the border region between the shallow intermediate layer and the keratinised surface layer of the anterior cell column of a filiform papilla. K, keratohyalin granule; Kl, keratinised layer. Bar, 1 μm. (*E*) Transmission electron micrograph of epithelial cells in the keratinised surface layer of the anterior cell column of a filiform papilla. Tl, tonofilaments; Kl, keratinised layer; Mr, microridges. Bar, 1 μm. (*F*) Transmission electron micrograph of epithelial cells in the shallow intermediate layer of the posterior cell column of a filiform papilla. R, free ribosomes; Tf, tonofibrils. Bar, 1 μm. (*G*) Transmission electron micrograph of epithelial cells in the keratinised surface layer (Kl) of the posterior cell column of a filiform papilla. Bar, 1 μm. (*H*) Transmission electron micrograph of epithelial cells in the deep intermediate layer of an interpapillary cell column. Tf, tonofibrils; R, free ribosomes. Bar, 1 μm. (*I*) Transmission electron micrograph of epithelial cells in the surface layer of the interpapillary cell column. N, condensed nucleus; Tl, tonofilaments. Bar, 1 μm. (*J*) Transmission electron micrograph of epithelial cells located on the free-surface aspect of the surface layer of an interpapillary cell column. Tl, tonofilaments; Mr, microridges. Bar, 1 μm.

the cytoplasm of these cells was filled with tonofilaments or tonofibrils in the shallow intermediate layer, and electron-dense round granules enclosed by a membrane were scattered throughout. Scarcely any keratohyalin granules were observed in the cytoplasm. Other organelles, such as mitochondria, were barely recognisable (Fig. 3*H*). In the surface layer of the interpapillary cell column, some weakly keratinised cells were recognisable. However, these cells were very thin. Most of their cytoplasm was filled with filamentous structures, which were not as electron-dense as those in the strongly keratinised cells. In

addition, the cells on the free-surface side were flattened. Microridges were well developed as far as the surface layer, as compared with those in the anterior and posterior cell columns of the filiform papillae.

Juveniles at P21

Light microscopy revealed that filiform papillae were more conical than those in juveniles at P7. The tips of the filiform papillae were pointed, and their apices were distinctly inclined towards the root of the tongue. The interpapillary cell columns were more distinct than at P7. In these columns, cells in the intermediate layer were relatively large and abruptly became flattened at the surface layer. The cells in the surface layer of the anterior cell columns of the filiform papillae and in the interpapillary cell columns stained strongly with toluidine blue, while those in the posterior cell columns of the filiform papillae stained metachromatically with toluidine blue. The nuclei of cells in the surface layer of all 3 types of column had almost disappeared. These features revealed a tendency towards keratinisation. Keratohyalin granules were observed not only in the intermediate layer of the anterior cell columns of the filiform papillae but also in that of the interpapillary cell columns. Those granules were not seen in the cells in the posterior cell columns of the filiform papillae (Fig. 4*A*).

Under the transmission electron microscope, each cell in the basal layer appeared round or somewhat elongated along the connective tissue papillae (Fig. 4*B*). Both in the basal layer and in the deep intermediate layer, there were relatively large numbers of free ribosomes in the cytoplasm, as in tongues at P7. Tonofibrils were distributed throughout the cytoplasm. These features were almost the same from the basal layer to the deep intermediate layer in the anterior and posterior cell columns of filiform papillae, and in the interpapillary cell columns (Fig. 4*B*). Keratohyalin granules appeared in the region from the deep intermediate layer to the shallow intermediate layer of the anterior cell columns of the filiform papillae, and tonofibrils and free ribosomes were densely distributed in the cytoplasm. The nuclei were oval or elongated (Fig. 4*C*). Cells in the shallow intermediate layer of the anterior cell columns of the filiform papillae were elongated. The cytoplasm was filled with tonofibrils, free ribosomes, and amorphous material. Large numbers of round or oval keratohyalin granules, the diameters of which varied from 50 nm to 800 nm, were widely distributed among them. At the border between the shallow intermediate layer and the surface layer, cells with tonofibrils, ribosomes and keratohyalin granules and typical keratinised cells were layered on top of one another (Fig. 4*D*). The surface layer was keratinised, and was composed of several layers of cells, as at P7. Most organelles, apart from keratin fibres, had been lost. Microridges were recognisable on the cell surface as far as the free-surface aspect (Fig. 4*E*). In the posterior cell columns of the filiform papillae, no keratohyalin granules were observed in the shallow intermediate layer. Instead, the cells in this layer were filled with a large number of tonofibrils in both the deep and shallow intermediate layers. Nuclei were recognised both in the deep and the shallow intermediate layers. However, they were condensed and then disappeared in the shallow intermediate layer near the surface layer (Fig. 4*F*). A thick layer of typical keratinised cells was located at the surface. These cells were filled with electron-dense keratin fibres and electron-dense amorphous material, with almost no other organelles and no nuclei (Fig. 4*G*). In the interpapillary cell columns, the cells were significantly larger in the intermediate layer than in the anterior and posterior cell columns of the filiform papillae, as at P7. Most of the cytoplasm of these cells was filled with tonofilaments and tonofibrils, and large numbers of ribosomes were distributed between the filamentous structures. A few mitochondria were also seen (Fig. 4*H*). In the shallow intermediate layer, cells were somewhat flattened. The tonofibrils were more compactly distributed in the cytoplasm than in the deep intermediate layer. Small numbers of keratohyalin granules were recognisable, and a few small granules with a limiting membrane were observed. Fine projections of the cell membrane were clearly seen all around the cells. In the surface layer of the interpapillary cell columns, weakly keratinised cells were recognisable and formed several layers of cells. Most of their cytoplasm was filled with filamentous structures, the electron density of which was not as high as that in the strongly keratinised cells. A few cells still contained condensed nuclei (Fig. 4*I*), and cells located at the free surface were not as flattened. Microridges were well developed as far as the surface layer, as compared with those in the anterior and posterior cell columns of the filiform papillae (Fig. 4*J*).

DISCUSSION

There have been many studies of the morphology and distribution of fungiform papillae on the tongue of adult mammals (Fish et al. 1944; Mistretta, 1972; Miller & Preslar, 1975), as well as studies of differences

in numbers of taste buds on each papilla among mammalian species (Fish et al. 1944; Farbman, 1965; Miller & Preslar, 1975; Arvidson & Friberg, 1980; Arvidson et al. 1981; Zahm & Munger, 1985). Furthermore, the morphogenesis of the fungiform papillae and the relationship between the morphogenesis of the fungiform papillae and that of the taste buds has been well described. Studies on morphogenesis and the growth of other lingual papillae with taste buds, such as foliate and circumvallate papillae, have been relatively limited (Miller & Smith, 1988; Mistretta & Haus, 1996) and few studies have focused on the morphogenesis of filiform papillae (Baratz & Farbman, 1975). As demonstrated in mice and rats by scanning electron microscopy, gustatory papillae such as fungiform and circumvallate papillae can be detected in the middle period of gestation, while the nongustatory papillae, the filiform papillae, are formed later, just before birth (Iwasaki et al. 1996*a*, 1997*a*). The present study demonstrates that the dorsal epithelium of the tongue at the middle or late period of gestation (E16) has no rudiments of filiform papillae and no signs of keratinisation. In contrast, the rudiments of filiform papillae are clearly recognisable in the dorsal epithelium of the tongue of newborn rats just after birth. Thus the morphogenesis of the filiform papillae of rats seems to occur rapidly during only 2 or 3 d just before birth, in parallel with the keratinisation of the epithelium. As shown in the present study, both keratohyalin granules and keratinised cells are present in newborn rats at P0. However, the earliest stages of the morphogenesis of filiform papillae and of the keratinisation of the dorsal lingual epithelium could not be identified. Observations between E16 and P0 should be made to clarify the relationship between the early morphogenesis of filiform papillae and the keratinisation of the dorsal lingual epithelium.

Studies by scanning electron microscopy (Iwasaki et al. 1996*a*, 1997*a*) showed that filiform papillae at P0 are distributed similarly to those observed in the mature adult. However, their shapes clearly differ from those of corresponding papillae in the adult. Between P0 and P7, the shapes of these lingual papillae change significantly to become similar to those in adults. For example, the round heads of filiform papillae become pointed. The present study revealed the clear differentiation of epithelial cells to form the basal, intermediate and surface layers in newborn rats, at the same time as the papillary cell columns and the interpapillary cell columns become distinguishable. Although, at this stage, penetration by connective tissue papillae into the centre of the rudiments of filiform papillae is clearly visible, differentiation of anterior and posterior cell columns of the filiform papillae, as observed at P7, is not yet distinguishable. Therefore, these 2 cell columns differentiate later, after formation of the rudiments of filiform papillae, during postnatal development, as do the anterior and posterior surfaces of the filiform papillae whose differentiation was analysed by scanning electron microscopy in mice and rats (Iwasaki et al. 1996*a*, 1997*a*). In parallel with the differentiation of the cell columns, differences in patterns of keratinisation between these 2 types of column also become evident after birth, as shown by the present study. From these results, it appears that different factors might affect the morphogenesis of the rudiments of filiform papillae or the differentiation of the anterior and posterior cell columns of the filiform papillae, respectively. Thus agents such as growth factors and hormones should be examined for their role at different stages before and after birth to clarify the mechanism of morphogenesis of filiform papillae and the differentiation of cells with different degrees of keratinisation.

A tongue is found in all vertebrates except fishes and some amphibia, and the undulations of the dorsal lingual surface, the lingual papillae, are recognisable as a common feature of the tongues of most animals from amphibia to mammals (Iwasaki et al. 1987, 1988, 1996*a*, *b*, 1997*a*, *b*, Iwasaki, 1990, 1992*a*, *b*, *c*), with some exceptions, such as snakes (Iwasaki et al. 1996*c*). Keratinisation of the dorsal lingual epithelium has been recognised in higher vertebrates. Among reptiles (Iwasaki, 1990, 1992*b*; Iwasaki & Kobayashi, 1992; Iwasaki et al. 1992*b*, 1996*b*, *c*; Iwasaki & Kumakura, 1994) the keratinisation of the lingual epithelium occurred, in evolutionary terms, in conjunction with adaptation to dry land from a fresh-water environment. The results of the present study indicate that the keratinisation of the lingual epithelium of rats occurs just before birth. Thus the changes in the lingual epithelium at birth also correspond to adaptation to a 'dry' environment. By contrast, the dorsal epithelium of the human tongue becomes keratinised in the middle period of gestation (Sawaf et al. 1991). One reason for this discrepancy in timing might be the difference in the duration of gestation, which is significantly longer in humans than in rodents.

The results obtained in the present study provide basic data for future studies of the morphogenesis of the lingual papillae and of the differentiation of cells in the lingual mucosa of mammals by, for example, immunohistochemical investigations of the distribution of various growth factors and their receptors.

ACKNOWLEDGEMENTS

The authors thank Professor Tsuneo Fujita, Department of Histology, The Nippon Dental University School of Dentistry at Niigata, for his encouragement and for many helpful suggestions. The authors are also grateful to Ms Yuka Okumura, Department of Histology, The Nippon Dental University School of Dentistry at Niigata, for technical assistance. The research was supported by Grants-in-Aid for Scientific Research (C) from the Ministry of Education, Science and Culture of Japan (nos 06671840 and 08672102).

REFERENCES

ARVIDSON K, FRIBERG U (1980) Human taste: response and taste bud number in fungiform papillae. *Science* **209**, 907–908.

ARVIDSON K, COTTLER-FOX M, FRIBERG U (1981) Taste buds of the fungiform papillae in Cynomolgus monkey. *Journal of Anatomy* **133**, 271–280.

BARATZ RS, FARBMAN AI (1975) Morphogenesis of rat lingual filiform papillae. *American Journal of Anatomy* **143**, 283–302.

FARBMAN AI (1965) Electron microscope study of the developing taste bud in rat fungiform papillae. *Developmental Biology* **11**, 110–135.

FARBMAN AI (1970) The dual pattern of keratinisation in filiform papillae on rat tongue. *Journal of Anatomy* **106**, 233–242.

FARBMAN AI, MBIENE J-P (1991) Early development and innervation of taste bud-bearing papillae on the rat tongue. *Journal of Comparative Neurology* **304**, 172–186.

FISH HS, MALONE PD, RICHTER CP (1944) The anatomy of the tongue of the domestic Norway rat. *Anatomical Record* **89**, 429–440.

GUTH L (1957) The effects of glossopharyngeal nerve transection on the circumvallate papilla of the rat. *Anatomical Record* **128**, 715–731.

GUTH L (1971) Degeneration and regeneration of taste buds. In *Handbook of Sensory Physiology*, vol. 4, *Chemical Senses 2* (ed. Beidler LM), pp. 63–74. Berlin: Springer.

HÅRDD AF SEGERSTAD C, HELLEKANT G, FARBMAN AI (1989) Changes in number and morphology of fungiform taste buds in rat after transection of the chorda tympani or chorda-lingual nerve. *Chemical Senses* **14**, 335–348.

IWASAKI S (1990) Fine structure of the dorsal lingual epithelium of the lizard, *Gekko japonicus* (Lacertilia, Gekkonidae). *American Journal of Anatomy* **187**, 12–20.

IWASAKI S (1992*a*) Fine structure of the dorsal lingual epithelium of the domestic, newborn kitten, *Felis catus*. *Annals of Anatomy* **174**, 293–300.

IWASAKI S (1992*b*) Fine structure of the dorsal epithelium of the tongue of the freshwater turtle, *Geoclemys reevesii* (Chelonia, Emydinae). *Journal of Morphology* **211**, 125–135.

IWASAKI S (1992*c*) Fine structure of the dorsal lingual epithelium of the little tern, *Sterna albifrons* Pallas (Aves, Lari). *Journal of Morphology* **212**, 13–26.

IWASAKI S (1993) A study of the filiform papilla of the newborn domestic kitten *Felis catus* by scanning electron microscopy. *Journal of Mammalogical Society of Japan* **18**, 33–38.

IWASAKI S, MIYATA K (1989) Fine structure of the filiform papilla of beagle dogs. *Journal of Morphology* **201**, 235–242.

IWASAKI S, MIYATA K (1990) Fine structure of the dorsal epithelium of the mongoose tongue. *Journal of Anatomy* **172**, 201–212.

IWASAKI S, KOBAYASHI K (1992) Fine structure of the dorsal lingual epithelium of the Japanese lizard, *Takydromus tachydromoides*. *Acta Anatomica Nipponica* **67**, 214–225.

IWASAKI S, KUMAKURA M (1994) An ultrastructural study of the dorsal lingual epithelium of the rat snake, *Elaphe quadrivirgata*. *Annals of Anatomy* **176**, 455–462.

IWASAKI S, MIYATA K, KOBAYASHI K (1987) Comparative studies of the dorsal surface of the tongue in three mammalian species by scanning electron microscopy. *Acta Anatomica* **128**, 140–146.

IWASAKI S, MIYATA K, KOBAYASHI K (1988) Scanning-electron-microscopic study of the dorsal lingual surface of the squirrel monkey. *Acta Anatomica* **132**, 225–229.

IWASAKI S, YOSHIZAWA H, SUZUKI K (1992*a*) Fine structure of the dorsal lingual epithelium of the Japanese monkey *Macaca fuscata fuscata*. *Acta Anatomica* **144**, 267–277.

IWASAKI S, ASAMI T, ASAMI Y, KOBAYASHI K (1992*b*) Fine structure of the dorsal epithelium of the tongue of the Japanese terrapin, *Clemmys japonica* (Chelonia, Emydinae). *Archives of Histology and Cytology* **55**, 295–305.

IWASAKI S, YOSHIZAWA H, KAWAHARA I (1996*a*) Study by scanning electron microscopy of the morphogenesis of three types of lingual papilla in the mouse. *Acta Anatomica* **157**, 41–52.

IWASAKI S, ASAMI T, WANICHANON C (1996*b*) Fine structure of the dorsal lingual epithelium of the juvenile Hawksbill turtle, *Eretmochelys imbricata bissa*. *Anatomical Record* **244**, 437–443.

IWASAKI S, YOSHIZAWA H, KAWAHARA I (1996*c*) Three-dimensional ultrastructure of the surface of the tongue of the rat snake, *Elaphe climacophora*. *Anatomical Record* **245**, 9–12.

IWASAKI S, YOSHIZAWA H, KAWAHARA I (1997*a*) Study by scanning electron microscopy of the morphogenesis of three types of lingual papilla in the rat. *Anatomical Record* **247**, 528–541.

IWASAKI S, ASAMI T, CHIBA A (1997*b*) Ultrastructural study of the keratinisation of the dorsal epithelium of the tongue of Middendorff's bean goose, *Anser fabalis middendorffii* (Anseres, Anatidae). *Anatomical Record* **247**, 149–163.

MILLER IJ, PRESLAR AJ (1975) Spatial distribution of rat fungiform papillae. *Acta Anatomica* **181**, 679–684.

MILLER IJ, SMITH DV (1988) Proliferation of taste buds in the foliate and vallate papillae of postnatal hamsters. *Growth, Development and Aging* **52**, 123–131.

MISTRETTA CM (1972) Topographical and histological study of the developing rat tongue, palate and taste buds. In *Third Symposium on Oral Sensation and Perception: The Mouth of the Infant* (ed. Bosma JF), pp. 163–187. Springfield, IL: C.C. Thomas.

MISTRETTA CM, HAUS LF (1996) Temporal and spatial patterns of tenascin and laminin immunoreactivity suggest roles for extracellular matrix in development of gustatory papillae and taste buds. *Journal of Comparative Neurology* **364**, 535–555.

OLMSTED JMD (1922) Taste fibers and the chorda tympani. *Journal of Comparative Neurology* **34**, 337–341.

SAWAF MH, SHABANA AH, PELISSIER A, FOREST N, OUHAYOUN JP (1991) Characterization of cytokeratin patterns in the developing human tongue. *International Journal of Developmental Biology* **35**: 91–100.

TORREY TW (1934) The relation of taste buds to their nerve fibers. *Journal of Comparative Neurology* **59**, 203–220.

WHITEHEAD MC, KACHELE DL (1994) Development of fungiform papillae, taste buds, and their innervation in the hamster. *Journal of Comparative Neurology* **340**, 515–530.

WHITEHEAD MC, FRANK ME, HETTINGER TP, HOU L-T, NAH H-D (1987) Persistence of taste buds in denervated fungiform papillae. *Brain Research* **405**, 192–195.

ZAHM DS, MUNGER BL (1985) The innervation of the primate fungiform papilla—development, distribution and changes following selective ablation. *Brain Research Review* **9**, 147–186.